

Duplex ultrasound in the assessment of lower extremity venous insufficiency

Martin Necas

Waikato Hospital, Vascular Laboratory, Hamilton, Tristram Vascular Ultrasound, Tristram Clinic, Hamilton and Unitec New Zealand, School of Health, Postgraduate Studies – Ultrasound, Waitakere Campus, Ratanui St, Henderson, Auckland, New Zealand.

Correspondence to author via ASUM. Email authors@asum.com.au.

Introduction

The purpose of this paper is to provide a focused overview of the key concepts in the assessment of lower limb chronic venous insufficiency (CVI) with an emphasis on specific techniques which can assist the sonographer or sonologist in achieving an accurate and time-efficient examination. In the context of this paper, CVI will pertain to lower extremity superficial and/or deep venous incompetence of any degree leading to the classic clinical signs of venous disease including: varicose veins, peripheral swelling and skin changes. This paper is by no means a comprehensive review of all issues surrounding CVI and duplex scanning. Interested readers are directed to the reference section for a selection of landmark papers and further reading.

Patients presenting for CVI duplex ultrasound

The vast majority of patients referred for CVI duplex scan present with primary superficial varicose veins¹. Less commonly, lower extremity venous disease is complicated by previous thrombotic events (deep or superficial) resulting in a range of problems in various venous segments including: occlusive or non-occlusive chronic thrombotic residua, venous wall fibrosis and incompetence of the affected segments. Another distinct group of patients are those representing with recurrent varicose veins following past interventions. The spectrum of clinical presentations in patients with CVI is broad, ranging from minor asymptomatic telangiectasiae and reticular veins, swelling, itching, venous eczema, symptomatic but small varicose veins, asymptomatic but large varicose veins, post-phlebotic leg through to lipodermatosclerosis and ulceration^{2,3}.

What the specialist needs to know

As with other duplex examinations, the information which is sought on the duplex scan is predominantly dictated by what the specialist needs to know in order to treat the patient. Duplex ultrasound scan is generally the only imaging test in these patients. The individual who performs the diagnostic duplex scan should have specific training in venous hemodynamics, the basics of clinical assessment, high level of training in vascular duplex ultrasound and should have completed a minimum of 250–400 supervised CVI examinations^{4,5}. The operator is usually a vascular sonographer, but it could also be a general sonographer with advanced vascular experience or a vascular surgeon, phlebologist, radiologist or interventionalist with sufficient duplex ultrasound expertise to carry out the examination^{1,6}. Any of these operators will henceforth be referred to as “sonographers”. In clinical

practice, the sonographer usually directly reports to the specialist who is will be treating the patient. The sonographer should answer the following questions:

Are the deep veins normal?

What is the source (or sources) of reflux?

What is the path of reflux including tributaries affected, their communication and size?

If catheter-based techniques (such as endovenous laser ablation) were to be used:

Is there any obvious problem which would prevent passage of a guide wire (such as thrombotic residua or tortuous course of any venous segment along the expected wire path)?

Is the saphenous vein contained within its fascial envelope?

What the examination includes

Sonographers may be compelled to bring the patient into the scanning laboratory, turn off the lights and start scanning. This would be a big mistake in CVI assessment. The sonographer should first obtain detailed history followed by a visual assessment of the leg with the patient standing under bright light^{1,6,7}. Having an appreciation for the location of problematic veins, symptomatic areas and skin changes can help the sonographer target the examination better and save valuable scanning time. It also ensures that no varicose tributaries are overlooked during scanning. A complete CVI examination therefore contains both indirect and direct (scanning) components⁷:

Patient's history

Visual assessment

Duplex ultrasound scan

Deep system

Superficial system

Search for perforators

Examination extended if required to include

Iliac veins

Ovarian veins.

Interpretation and production of a detailed graphical report

The role of the sonographer is to gain a thorough understanding of the venous hemodynamics and varicose vein distribution in the patient. No questions should remain unanswered and the source of all varicose veins should be determined. Finally, the findings of the examination must be communicated in a clear graphical report to the specialist.

Time allocation for the examination

CVI examinations need not be lengthy and arduous. On

occasion, however, these exams can be difficult especially in patients with non-truncal varicose veins, complex patterns of recurrence or when the examination needs to be extended into the abdomen to assess the pelvic veins. The Society for Vascular Ultrasound⁷ recommends 65–75 minutes for the performance of a bilateral lower extremity venous examination. In our local public and private vascular laboratories (Hamilton, New Zealand), we allocate 30–45 minutes for a unilateral study and 60–75 minutes for a bilateral examination depending on operator experience.

Patient preparation and positioning

The best examination of lower extremity veins is achieved when the veins are under full distension. The patient should be instructed not to wear stockings on the day of the examination, the patient should arrive warm if possible and the examination room and gel should also be comfortably warm. The examination should be performed with the patient in a reverse Trendelenburg position or upright so that hydrostatic pressure in the veins is at its peak to aid venous distension. If possible, patients with minor varicose veins or cosmetic concerns should be scheduled in the later parts of the day⁸. If the specialist suspects pelvic venous incompetence on the basis of patient's history and clinical examination, the patient should also be fasted for 6–8 hours in order to limit overlying bowel gas and peristalsis so that ovarian veins and internal iliac veins can also be examined.

The patient can be positioned for scanning in a variety of ways: standing on an elevated platform, combination of standing and sitting, recumbent position or lying on a tilt-table in reverse-Trendelenburg position at $\geq 30^\circ$ or $\geq 60^\circ$ incline. The leg under examination should be relaxed, slightly flexed at the knee and externally rotated^{1,6,7,8,9,10}. Which of the above setups the sonographer employs largely depends on the equipment available in the laboratory. I strongly recommend a good-quality, hard, narrow tilt-table with hydraulic tilt and up/down movements. The tilt table has two principal advantages:

- The sonographer can remain in an ergonomic position¹¹ at a constant height and facing the machine while the table with the patient are maneuvered to the desired tilt and height with a push of a button.
- Tilt-tables are comfortable for the patients and help prevent patient falls. When patients are examined standing, they have a tendency to get tired and faint. Because the patient's centre of gravity is invariably above the sonographer, a sudden faint can be dangerous for the patient and the sonographer alike^{10,12}.

Characteristics of lower extremity veins

Normal deep and superficial veins of the lower extremity should meet the following criteria:

- Thin, smooth walls.
- Complete compressibility.
- Spontaneity: Flow observed at quiescence. This may be difficult to observe in small vessels of the calf.
- Consistent color fill: Absence of color filling defects.
- Smooth flow contour: No flow disturbance.
- Presence of flow disturbance can signal irregularity of venous wall or thin fibrinous strands which can be overlooked on 2D examination.
- Phasicity: Respiratory variation. Fall in venous flow velocity with inspiration, rise with expiration.

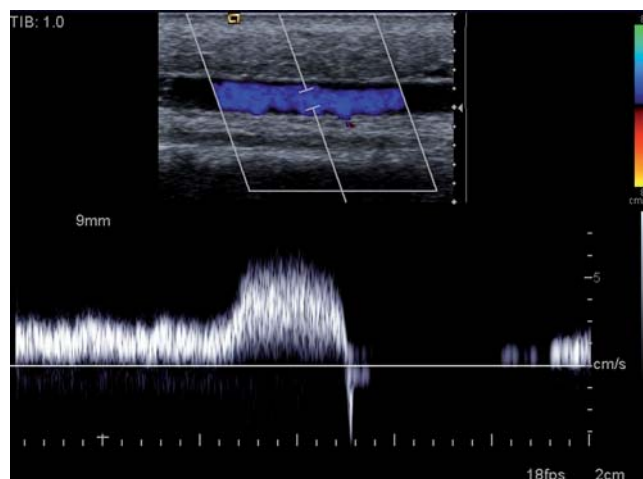


Fig. 1: Competent superficial vein. Well optimised duplex image of flow in a competent superficial vein. Wide color box was used in order for a long segment of the vein to be visualised. Spectral waveform is large and clear. Spontaneous venous flow is seen in the left side of the spectral trace, followed by manual augmentation. There is a sharp “click” or “snap” of venous valve closure followed by a period of absent flow. Once arterial inflow refills the peripheral vascular bed, normal antegrade flow resumes again on the right side of the spectral Doppler trace.

- Augmentability: prompt increase in venous flow velocity at the sampled location with distal augmentation.
- Competence: cephalad, unidirectional flow maintained by venous valves (Fig. 1).
- Non-pulsatility: compliance of normal veins results in the effective absorption of cardiac pulsatility which is seen at the level of the right atrium, and upper inferior vena cava (IVC).

Valves, competence, incompetence

In a normal lower extremity vein, venous competence is maintained by venous valves. Venous valves act as mechanical gates allowing blood to flow centrally, but preventing flow from coursing peripherally^{8,13}. Valves come in a thicker reinforced form or a thin transparent form and usually feature two cusps. Because hydrostatic pressure in the lower extremity increases peripherally, veins are equipped with increasing number of valves in the dependent regions of the leg. In the deep system, there is one valve above the CFV level, two to four in the femoral vein and about twelve valves in the deep calf veins. In the superficial system, there is a terminal and subterminal valve at the top of the great saphenous vein (GSV), additional one to two valves in the thigh section and about 10 to 12 valves in the calf section of the GSV and small sphenous vein (SSV). Despite their thin and inconspicuous nature, normal valves are capable of withstanding tremendous venous pressures without failing. Why venous valves sometimes fail resulting in varicose veins without any secondary insult is not entirely understood. It is likely a combination of endothelial dysfunction, genetic predisposition, hormonal influences as well as other factors such as volume-mediated dysfunction, venous hypertension and lifestyle factors. When valves do fail, they may demonstrate a variety of reflux patterns including a reluctant tendency “leak” at the cusp tips or profound, obvious and spontaneous incompetence⁸. The important observation is that normal valves will not fail at high physiologic pres-

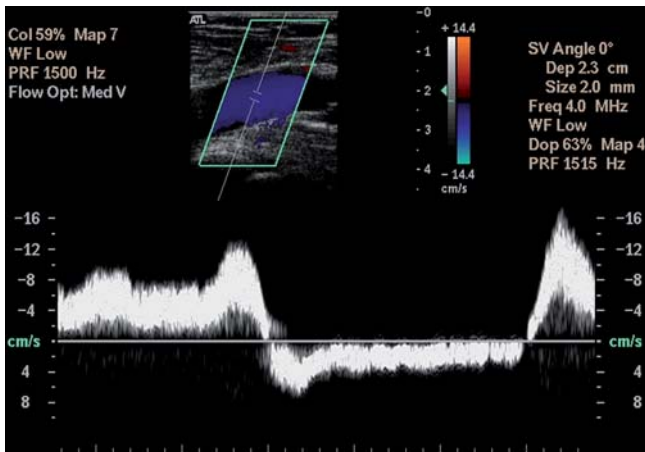


Fig. 2: Refluxing deep vein. Reflux in the femoral vein elicited with a sustained valsalva or simulated valsalva manoeuvre lasting three seconds.

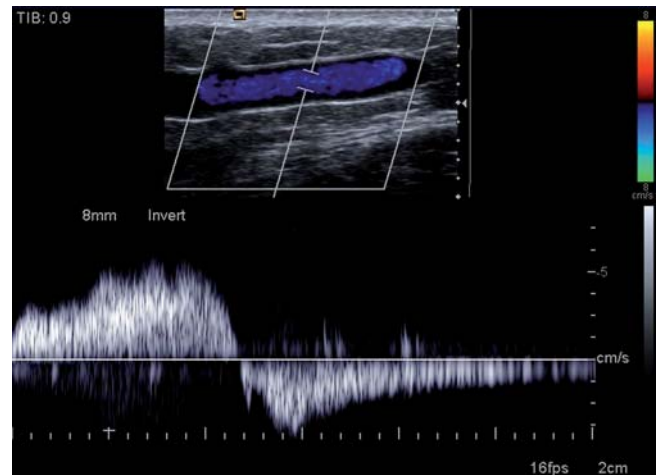


Fig. 4: Refluxing superficial vein. Reflux in the GSV is seen following augmentation. The reflux time can be measured or compared to the time-scale of the spectral Doppler window. In this case, continuous reflux is seen over a period greater than four seconds.

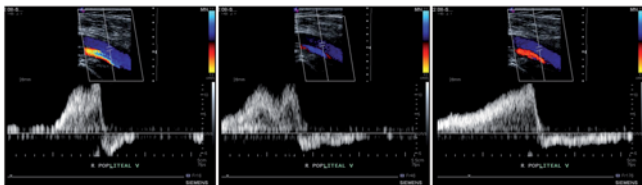


Fig. 3: Variability of reflux response. The effect of the length of augmentation on the tendency of lower extremity veins to reflux. All images are obtained from the same sample site in the popliteal vein of the same patient. Left image: short augmentation resulting in reflux time of only 0.7 seconds. Middle image: longer augmentation resulting in reflux time of 1.5 seconds. Right image: prolonged augmentation resulting in continuous reflux for many seconds.

tures. It is therefore logical to assess veins for incompetence by stressing them as much as possible. This is especially the case in patients presenting early in the spectrum of varicose vein disease or those who present with minor cosmetic problems and require exclusion of underlying venous incompetence.

In case of primary venous reflux of the superficial veins, the pattern of refluxing veins is always “from top down”. That is, once the terminal and subterminal saphenous valves fail, the upper GSV dilates, pressure on the next valve down increases and this valve will fail also. This domino-effect then continues down the lower extremity along the path of least resistance. As veins dilate, they also lengthen and their normal straight course transforms into tortuous varicose vein.

Testing for venous incompetence

Venous incompetence (reflux) can be elicited in several ways. It is important that the sonographer achieves a high pressure gradient across the venous segment under examination in order to create favourable conditions for reflux to occur. The most common techniques include:

- Valsalva manoeuvre
- Simulated Valsalva
- Manual distal augmentation
- Distal augmentation with an automatic pressure cuff
- Activation of the calf muscle pump with plantar-flexion.

Testing of the common femoral vein (CFV), sapheno femoral junction (SFJ) and upper femoral vein (FV) can

be achieved using the Valsalva manoeuvre^{1,13}. The patient should be encouraged to Valsalva forcefully and for a sustained period of time (two to three seconds is usually sufficient)⁸. Unfortunately, some patients (such as older patients, non-English speakers) find it difficult to perform the Valsalva manoeuvre adequately. In these patients, a simulated Valsalva can be easier to achieve. The sonographer instructs the patient to take a deep breath and hold. The sonographer then pushes on the patient’s abdomen with the free hand by firmly leaning into the patient. The patient should be encouraged to resist (guard against) the pressure, hence creating an excellent simulated Valsalva manoeuvre (Fig. 2). Below the level of the SFJ, testing for reflux is usually performed by using distal manual augmentation¹. The augmentation should be gradual, firm, prolonged and followed by swift release. This technique ensures that a large volume of venous blood is emptied out of the calf in order to create a high pressure gradient on release. Augmentation of the ankle or foot is not so effective because little venous volume is found in these locations.

The techniques described above are clearly patient and operator dependent. For instance, the strength of the Valsalva manoeuvre and the resultant pressure gradient will vary from patient to patient and are basically unknown. Also, a sonographer with a large strong hand will be able to perform distal augmentation more effectively than a sonographer with a small weaker hand. The strength and duration of distal augmentation as well as the speed of release can have a significant influence on whether reflux is or is not observed and for what duration (Fig. 3). Patient’s body position during the scan also plays a role⁹. In an attempt to introduce at least some level of standardisation into the augmentation procedure and to assist the sonographer in performing distal augmentation, some laboratories use an automated cuff applied on the lower leg or foot which the operator can inflate with a push of a button. The cuff inflates to a desired peak pressure and then then rapidly deflates. The take-up of this method has been modest. This is partly due to the fact that manual augmentation is very effective and the cuff method may not be suitable for patients with fragile, sensitive skin or ulcers.

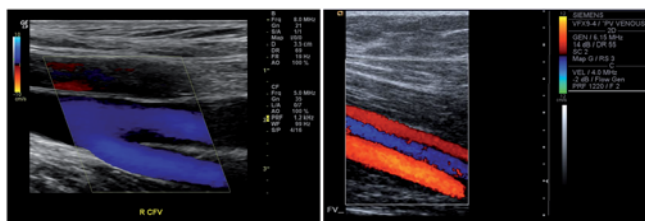


Fig. 5: Color Doppler survey. High-end ultrasound systems with multiple beam formers afford acceptable temporal resolution with large color boxes. Left image: confluence of the PFV and FV. Right image: femoral vein duplication in the region of the adductor canal.

Closure of normal valves under physiologic conditions or under provocative manoeuvres is very rapid. Small amount of retrograde flow can be seen during valve closure before the valve leaflets snap shut (Fig. 1). The diagnosis of reflux is usually made if the retrograde flow exceeds 0.5 seconds^{1,6} in duration (Fig. 4), although some labs use reflux time of > 1 second^{8,10}. Superficial venous reflux is most often continuous over several or many seconds, so both of the above criteria are satisfied¹⁰. While simple measurement of reflux time may seem like an unsophisticated way of diagnosing venous incompetence, the method is well accepted and highly practical. Some investigators have evaluated the usefulness of other parameters such as reflux waveform surface area or adding the parameter of reflux velocity¹⁰. Ultimately, the discriminatory boundary where reflux is diagnosed is a matter of accepted definition and agreement between the specialist and the sonographer. Introducing more rigid hemodynamic criteria for the definition of reflux is difficult given the tremendous anatomical variations in the venous system, the subjectivity of the ways in which reflux is elicited and the variability of reflux response in different patients (Fig. 3).

Duplex imaging, system settings and optimisation

Adequate CVI examination can be achieved on most medium-level portable ultrasound systems. However, the level of diagnostic detail and overall system performance does generally increase with the cost of the system. Ideally, a vascular laboratory performing a large volume of CVI examinations will feature a high-end ultrasound scanner. Examination of the deep system should be performed with a medium to low frequency linear array transducer in the region of 5–8 MHz (centre frequency) whereas superficial veins should be examined with a high frequency linear transducer in the region of 10–12 MHz (centre frequency). Most of the hemodynamic information the sonographer requires to make the diagnosis of reflux can be obtained in color Doppler. Color Doppler should be used as an efficient surveillance tool. High-end ultrasound systems operate multiple beam formers resulting in faster acquisition of image frames. This allows the sonographer to comfortably operate with large color boxes, or full-screen color even at considerable depth while still achieving acceptable frame rates (Fig. 5). Another advantage of color Doppler is its ability to pin-point the exact location of refluxing valve jets in “leaking” but not grossly refluxing valves (Fig. 6). Eccentric refluxing jets are commonly encountered at the SFJ and spectral Doppler sampling without careful color Doppler guidance can result in a chaotic bidirectional signal or can completely miss the presence of a slow valvular leak. While

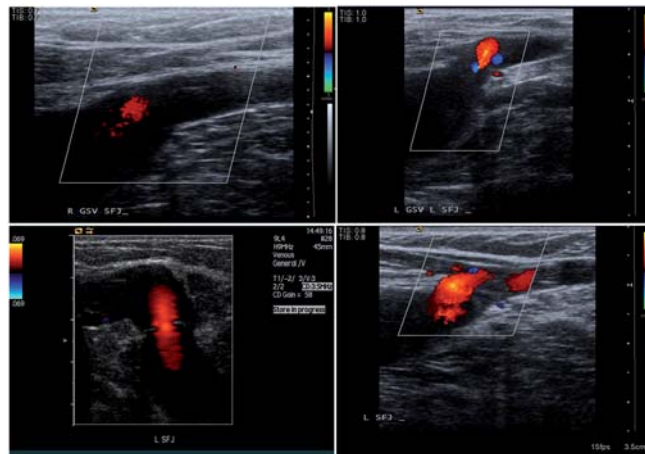

Fig. 6: Refluxing flow jets at incompetent SFJs. Refluxing terminal valves resulting in incompetent flow jets at a variety of SFJs. Color Doppler should be used first to establish the presence of reflux and the location of the refluxing flow jet. Effective targeted sampling on spectral Doppler can then be performed.

color Doppler allows the sonographer to observe flow and eye-ball reflux, color does not allow for effective measuring of reflux times. For this reason, spectral Doppler recordings will need to be made in representative sections of the veins.

Good system optimisation practices are key to an efficient CVI examination. Both color and spectral Doppler imaging should be performed at favourable Doppler angle $\leq 60^\circ$. In color Doppler, low scale and high gain settings should be used. Spectral Doppler should also be well optimised (low scale, low wall filter) in order to display large Doppler shifts and clearly interpretable large Doppler waveforms. When recording venous waveforms with flow augmentation in apparently normal vessels, it is a good practice to wait for the resumption of normal venous flow to ensure that delayed reflux does not develop (Fig. 1).

Some sonographers or sonologists have described scanning for reflux in transverse section. This approach may work well in the easy patient with gross incompetence. However, transverse color and spectral Doppler assessment does not allow the operator to ensure there is a favourable Doppler angle. In small vessels with slow reflux, poor Doppler angle will result in dramatic further reduction of the already small Doppler shifts making flow difficult to detect.

Deep vein survey

For the purposes of a CVI scan, deep vein survey should be performed similarly to a standard DVT scan but with the addition of testing for reflux in the distal CFV (below the SFJ), FV and popliteal (POP) vein⁷. Some labs limit the testing for reflux to the FV and POP vein only, recognising that CFV often refluxes even in normal subjects. If the deep veins reflux to the level of the POP vein, it is worthwhile to assess the distribution of reflux in the calf veins also. The sonographer should be mindful of anatomical duplications in the deep veins which are relatively common (20% POP, 10% FV). When duplications are encountered, both of the duplicated vessels require testing because one may reflux while the other may remain competent (Fig. 7). Spectral Doppler waveforms obtained in the deep veins can also provide other important diagnostic clues. Absence of respiratory phasicity in the waveform of the CFV should prompt

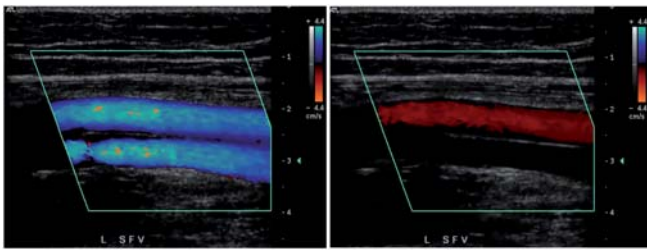


Fig. 7: Duplication of the femoral vein. Duplicated femoral vein during augmentation (left image) and following augmentation (right image). Reflux is seen in the more superficial of the two FVs.

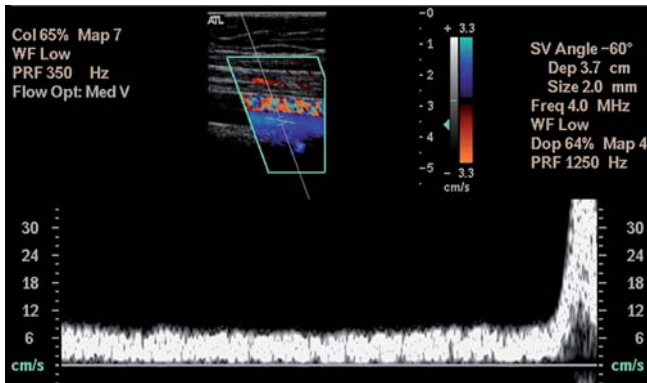


Fig. 8: Abnormal “flat” aphasic femoral vein waveform. A patient presenting for lower extremity venous duplex with clinical signs of chronic venous insufficiency demonstrates aphasic “flat” femoral waveform due to previously undiagnosed external iliac vein occlusion. On questioning, the patient reported a past history of motor vehicle accident with significant pelvic trauma.

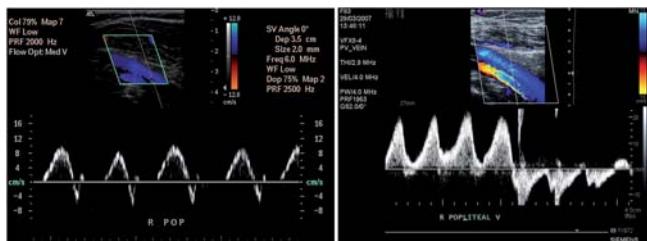


Fig. 9: Pulsatile venous waveforms in the popliteal (POP) vein in patients with congestive heart failure. Competent pulsatile POP vein (left image). Incompetent pulsatile popliteal vein (right image).

investigation of the Iliac system for presence of downstream venous obstruction which may be due to iliac DVT or iliac vein compression by a pelvic mass (Fig. 8). On the other hand, pulsatile peripheral venous waveforms can be found in individuals with increased central venous pressure most commonly associated with right heart failure. In these patients, increased central venous pressure results in the loss of peripheral venous compliance with transmission of cardiac pulsatility throughout the lower extremity venous system (Fig. 9).

Superficial vein anatomy

The greatest number of anatomical variants in the human body is found in the vascular system. No two patients are ever exactly alike in terms of the exact location and branching (more precisely convergence) pattern of the venous tree of the limbs^{14,15,16}. Some general observations can be made:

- The location of the SFJ is relatively constant at the groin crease.

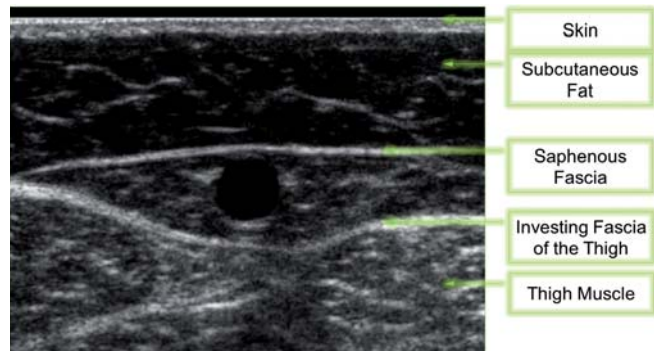


Fig. 10: The Saphenous Fascial Envelope. The normal fascial envelope of the GSV.

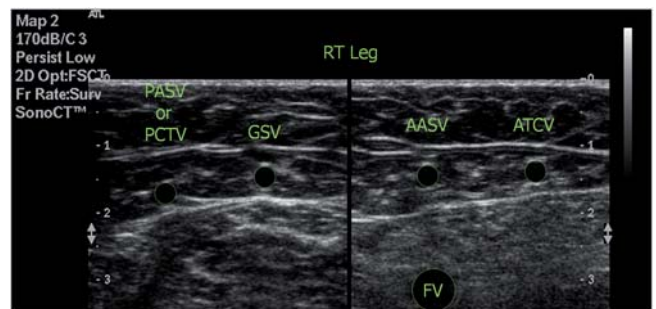


Fig. 11: Accessory saphenous and circumflex veins of the thigh. Multiple superficial veins are demonstrated in the right leg. The anterior accessory saphenous vein (AASV) is typically located directly superficial to the GSV.

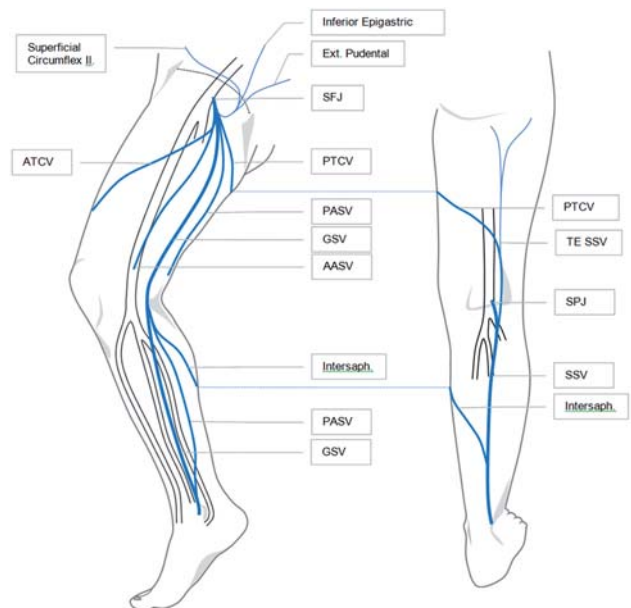


Fig. 12: Superficial veins of the leg. Sapheno-femoral junction (SFJ), great saphenous vein (GSV), AASV, posterior accessory saphenous vein (PASV), anterior thigh circumflex vein (ATCV), posterior thigh circumflex vein (PTCV) sapheno-popliteal junction (SPJ), small saphenous vein (SSV), thigh extension of the small saphenous vein (TE SSV), intersaphenous vein (Intersaph. V).

- The GSV and its tributaries are found within a well formed fascial envelope termed the “Saphenous eye,” “Egyptian eye” or “Cleopatra’s eye” (Fig. 10) although the veins may escape the fascial envelope into superficial subcutaneous regions anywhere along their course.
- There may be one or more accessory saphenous veins. The anterior accessory saphenous vein (AASV) is typically located superficial to the femoral vein. The true

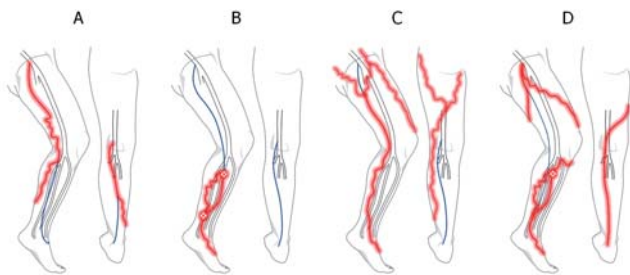


Fig. 13: Patterns of venous reflux, examples. A: Junctional incompetence (SFJ and SPJ); B: Isolated perforator incompetence; C: Pelvic venous incompetence causing lower extremity varices; D: Combination of SFJ reflux contributing to the reflux of the ATCV, vein of Giacomini and SSV with preservation of the GSV in the thigh.

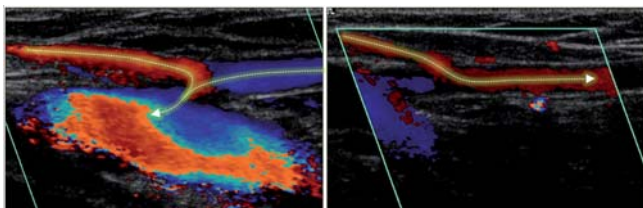


Fig. 14: Competent SFJ with GSV reflux supplied by the IEV. Left image: Normal competent SFJ showing the inferior epigastric vein (IEV) and great saphenous vein (GSV). Right image: The SFJ is competent, but flow from the IEV is seen to reflux down the GSV.

GSV lies medial to the AASV. (Figs. 11, 12)

- Short-course duplications of the GSV and SSV are not uncommon but full length duplications are rare.
- The location of the SPJ varies considerably (medial, lateral, at knee crease, above knee crease, absent, duplicated).
- The SPJ is often absent and the SSV may drain via a Thigh Extension (TE SSV) into other vessels. When the SPJ drains via the TE SSV and posterior thigh circumflex vein (PTCV) into the GSV, the vein is called the vein of Giacomini.
- The GSV and SSV communicate via intersaphenous connections especially in the calf. Intersaphenous connections may act as pathways for reflux.

Detailed diagram of the most common superficial veins and their accepted international nomenclature^{14,15} is provided in Fig. 12. It should be noted that not all the veins demonstrated in Fig. 12 are present in every patient.

Common patterns of superficial reflux

Most primary lower extremity varices are caused by reflux at the level of the SFJ or SPJ. Perforator incompetence can contribute to CVI or can be the consequence of underlying CVI¹⁷. Isolated primary perforator incompetence leading to lower extremity varices can occur but is less common. Another frequent cause of CVI especially in multiparous women is related to pelvic venous incompetence (Fig. 13). In these patients, refluxing pelvic veins communicate with lower extremity veins via pudental, inferior epigastric, gluteal and other connections. For instance, the SFJ can be competent, but an incompetent GSV may be supplied by the inferior epigastric (Fig. 14).

Simplifying the examination

The superficial venous system can be complex to assess especially in the presence of convoluted varices. It is

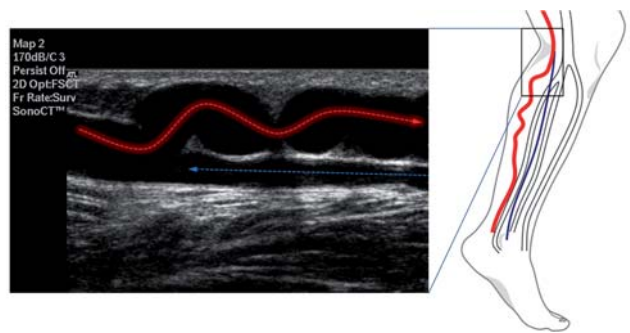


Fig. 15: Determining the path of reflux. The path of reflux at the confluence of GSV and posterior accessory saphenous vein in the calf. The 2D examination already suggests which channel is incompetent (the superficially located vessel is varicose). The varicose vein does not require testing. The smaller straight vessel (calf section of the GSV) requires assessment. It is sufficient to use color Doppler the majority of the time.

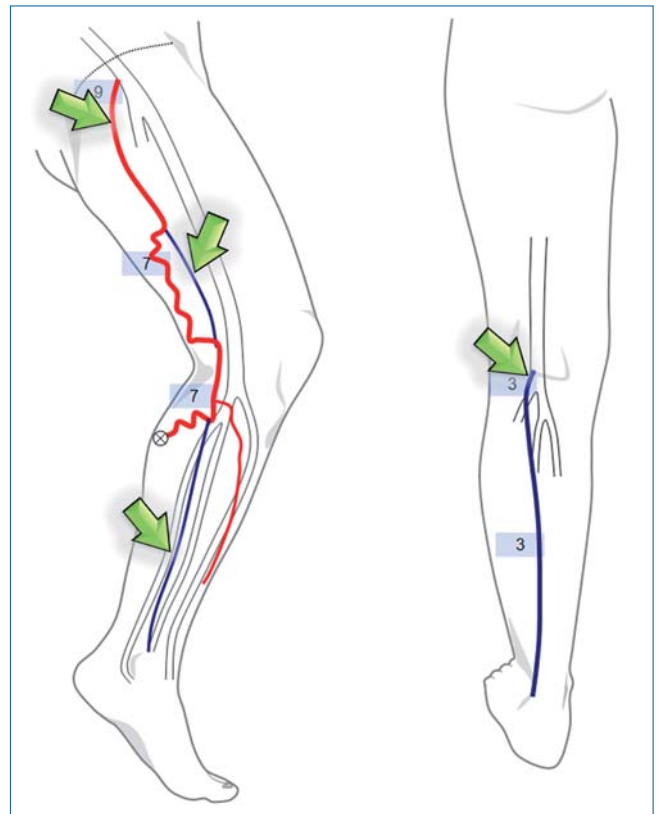


Fig. 16: Duplex sampling sites. Assessment for reflux can be easily targeted so that relatively few locations along the superficial venous tree require color or spectral Doppler sampling. The patient below demonstrates primary varicose veins in the GSV territory with several tributaries. Arrows indicate the few locations which need to be tested.

easy for sonographers who are new to CVI scanning to feel overwhelmed by the level of detail, sometimes to the point of diagnostic paralysis. While CVI scanning requires considerable skill and expertise, the examination is not difficult to perform. There are some general strategies which can help simplify even the most complex examination:

- Reflux always as a source and a path. The most important task is to locate the source or cause of reflux. The path is easy to follow once the source is determined (Fig. 15).
- It is best to get a general overview of the extent of the CVI first before assessing each individual tributary.

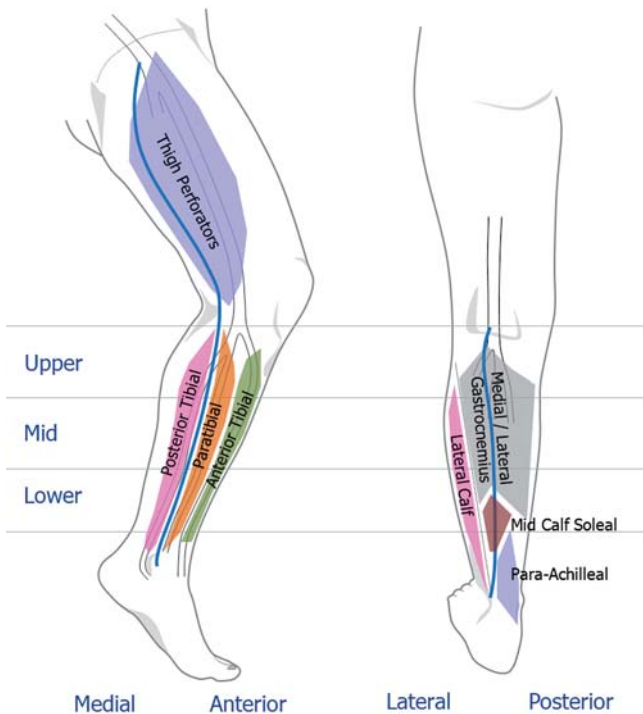


Fig. 17: Location and nomenclature of lower extremity perforators.

- Surveying veins and testing for reflux in color Doppler is far more efficient than testing with spectral Doppler. Spectral Doppler still needs to be used for recording of findings, but not for general survey.
- Size of the vessel is a good clue to the presence of reflux. In general, superficial veins > 5 mm nearly always reflux. Unfortunately it cannot be assumed that a small vessel does not reflux. For example, past superficial venous thrombosis may have rendered the vessel incompetent.
- Varicose veins always reflux and do not require testing. There is no such thing as a competent varicosity.
- Normal competent tributaries usually do not require further testing unless there are incompetent intercommunicating vessels.
- In complex cases, it is a good idea to make notes or a sketch during the examination in order to keep track of what has already been examined.

Fig. 16 shows that even in patients with multiple tributaries, the number of sampling sites required to demonstrate incompetence and determine its path can be relatively modest.

Perforators

A complete CVI examination should include a search for incompetent perforators (Fig. 17). With high-frequency transducers available today, it is relatively easy to see even normal competent perforators. Incompetent perforators are generally large (> 3 mm)¹⁸. Smaller perforators probably do not require testing. Because the interplay of venous flow between the perforator and surrounding varices can be complex and difficult to predict, the sonographer should test the perforator several times by applying augmentation at over different sites and especially over local varices in the vicinity of the perforator¹. The location and diameter of any incompetent perforators should be noted on the final report.

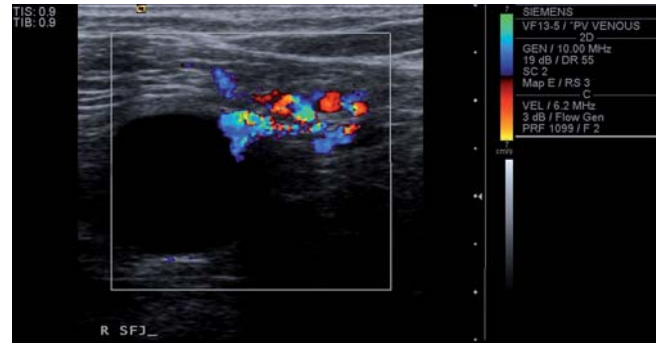


Fig. 18: Neovascularity at the site of previous SFJ ligation. The network of incompetent vessels can be clearly visualised on color Doppler under forceful Valsalva manoeuvre even though 2D examination was essentially unremarkable.

Recurrence

Patients presenting with recurrent varices can be examined using the same methods as first presenters. Recurrent varicose veins can be caused by primary technical failure of treatment, neovascularisation, progression of disease with new onset of primary varices in previously untreated vessels and perforator incompetence^{19,20,21}. Patients may present with failed SFJ or SPJ ligation, double SFJ or SPJ with past treatment of only one, recanalisation of previously sclerosed vessels, development of new perforator incompetence²¹, varicose veins related to a pelvic source, and other complications. A specific type of incompetence which may be difficult to visualise is neovascularisation of the SFJ. With neovascularisation, the region of a past successful SFJ ligation is traversed by a network of tiny incompetent veins which trail down peripherally away from the SFJ and converge onto larger, clinically obvious varices. The vessels involved in neovascularisation may be smaller than can be confidently resolved by 2D ultrasound. Furthermore, soft tissue scarring related to the past surgery may degrade 2D image quality at the level of the SFJ making neovascularisation even harder to appreciate on 2D ultrasound. When recurrent varicose veins exist in the GSV territory or when the cause of recurrence cannot be determined, purposeful testing of the SFJ ligation site with vigorous Valsalva using color Doppler on very low scale and high gain can reveal neovascularisation as the source of recurrent lower extremity varices (Fig. 18).

Pelvic and ovarian veins

Incompetence of the ovarian and internal iliac veins in women has been implicated as a contributing factor in the formation and recurrence of lower extremity varicose veins. It is beyond the scope of this article to discuss pelvic vein scanning. Suffice it to say that with modern ultrasound systems, direct assessment of the ovarian and internal iliac veins can be made very effectively in the vast majority of patients. Where suspicion of pelvic venous incompetence exists on clinical grounds or on the basis of the findings in the lower extremity veins, pelvic vein assessment incorporating transabdominal survey of the ovarian and internal iliac vein should be performed^{22,23}.

Reporting of results

Nearly all patients presenting for CVI duplex are being considered for treatment of varicose veins. The results of

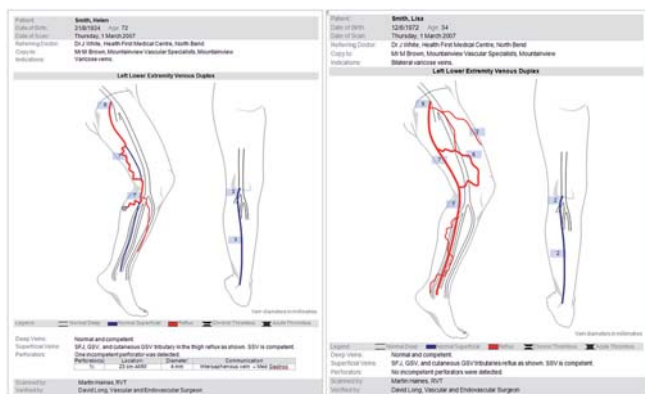


Fig. 19: Venous duplex reports. Examples of graphical reports generated electronically. (Personal details have been changed to ensure privacy).

the duplex scan have a considerable impact on the choice of treatment. It is therefore imperative that a CVI examination be accompanied by a high quality graphical report^{1,6,8,24,25,26,27}. The report should include detailed information about both superficial and deep veins, identification of refluxing veins and tributaries, the anatomical location of superficial varices, superficial vessel sizes and other relevant comments such as the presence of anatomical variants, thrombus, fibrin, phleboliths and other incidental findings. Some vascular sonographers are excellent artists producing detailed, hand-made, one-off sketches of the venous system on photocopied worksheets⁶. Another way of producing a more consistent and professional report is to use computer software designed for this purpose (Figs. 19, 20)^{24,25,26}. Text reports should be avoided as these are tedious to read, difficult to interpret and are generally disliked by most vascular specialists^{25,27}. While it is important to have sufficient record of the CVI examination in frozen images or video recordings, the end product of the examination which the treating specialist is going to refer to is the graphical sonographer's report.

Frequently asked questions

How many times should an incompetent vein be tested?

As few times as possible. Utilise color Doppler to examine, spectral Doppler to record. Once reflux is established, it is not usually necessary to re-test until the next tributary.

I can see the vein is incompetent in parts, but I cannot find the source of reflux. What now?

There is always a source of reflux. Segmental reflux can occur but it is exceptionally rare. Are incompetent tributaries entering in the elevation plane? Has junctional reflux been overlooked because of a slow or off-axis valvular leak? If this is a patient with recurrence, is there neovascularisation of the SFJ? Is there a pelvic source?

What about patients with minor cosmetic veins?

The smaller the veins the more difficult they are to assess. It is helpful to book patients with minor varicose veins towards the end of the day as incompetence usually worsens over the course of the day. The room should be warm. Ask patient to identify any problem veins and test for competence there. If incompetent, follow these up to source.

The patient presents with clinical signs of chronic venous insufficiency, but there is no deep or superficial incompetence on the duplex examination at all

Most of these types of patients will either be obese or diabetic, often both. In New Zealand, Maori and Pacific Island

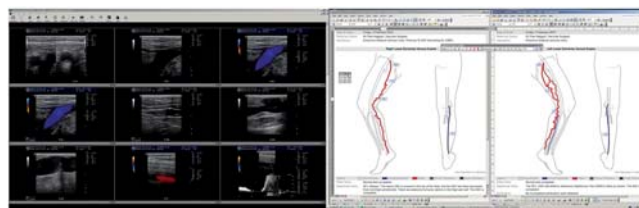


Fig. 20: Screen capture of a reporting PC. A simple, off-the-shelf, dual-screen computer set-up such as a laptop connected to an external monitor or dedicated reporting desktop computer allows the sonographer to review the images on the one monitor (left in this case) and compose reports on the other monitor.

people are often affected. A variety of mechanisms may contribute to the clinical picture including calf muscle pump deficiency, coexisting microvascular arterial disease, increased central venous pressure from underlying cardiac dysfunction and the recently described popliteal vein compression syndrome²⁸.

Conclusions

Vascular specialists rely on high-quality duplex examination in the planning of lower extremity venous interventions. It is therefore imperative that the vascular sonographer provides a complete indirect and direct assessment of the lower extremity veins and produces an accurate report. A detailed CVI examination need not be a tedious test. There are a number of strategies which can make this examination effective and time-efficient. From the sonographer's standpoint, CVI scans can be highly satisfying examinations. After all, each patient is unique, nearly all examinations will be abnormal and each patient's treatment strategies will be guided by the results of the sonographer's duplex scan.

Acknowledgments

I am grateful to the following colleagues for their review of this manuscript and their constructive feedback: Dr Isabel Wright, vascular sonographer; Bridget Boyle, vascular sonographer; Mai Snelgrove, vascular sonographer; Mr David Ferrar, vascular specialist.

References

- Coleridge-Smith P, Labropoulos N, Partsch H, Myers K, Nicolaides A, Cavezzi A. Duplex ultrasound investigation of the veins in chronic venous disease of the lower limbs – UIP consensus document. Part I. Basic Principles. *Eur J Vasc Endovasc Surg* 2006; 31: 83–92.
- Beebe HG, Bergan JJ, Bergqvist D, Eklöf B, Eriksson I, Goldman MP, *et al.* Classification and grading of chronic venous disease in the lower limbs: a consensus statement. *Vasc Surg* 1996; 30: 5–11.
- Eklöf B, Rutherford RB, Bergan JJ, Carpentier PH, Gloviczki P, Kistner RL, *et al.* Revision of the CEAP classification for chronic venous disorders: consensus statement. *J Vasc Surg* 2004; 40: 1248–52.
- Australasian Society for Ultrasound in Medicine. DMU vascular Examination Structure. Available online at http://www.asum.com.au/site/files/DMU/2010_Vascular_exam_structure.pdf. Rev 13/11/2004 [verified September 2010].
- The Society for Vascular Technology of Great Britain and Ireland. The accreditation document: Attaining & maintaining registration as an accredited vascular scientist (AVS). 2010; Document ID: EdCom AVS2010 v3. Page 7.
- Min RJ, Khilnani NM, Golia P. Duplex ultrasound evaluation of lower extremity venous insufficiency. *J Vasc Interv Radiol* 2003; 14: 1233–41.
- Lower extremity venous insufficiency evaluation. Society for Vascular Ultrasound. Available online at <http://www.svunet.org/files/positions/LEVenousInsufficiencyEvaluation.pdf>. 2007 [verified September 2010].

- 8 Coghlan D. Chronic venous insufficiency. *ASUM Ultrasound Bulletin* 2004; 4: 14–21.
- 9 Cairnduff M, Swan H, Barton B, Buckley AR. Assessing the variable of patient positioning when examining the lower limb veins for reflux using spectral and colour Doppler ultrasound. *ASUM Ultrasound Bulletin* 2007; 10 (3): 22–8.
- 10 Evans CH, Allan PL, Lee AJ, Bradbury AW, Ruckley CV Fowkes GR. Prevalence of venous reflux in the general population on duplex scanning: The Edinburgh Vein Study. *J Vasc Surg* 1998; 28: 767–76.
- 11 Industry standards for the prevention of work-related musculoskeletal disorders in sonography. Consensus conference on work-related musculoskeletal disorders in sonography. May 2003. Available online at <http://www.soundergonomics.com/pdf/WRMSDweb.pdf> [verified September 2010].
- 12 Morgan A. Emergencies in the phlebology laboratory – a sonographer’s role. Presentation at the Australasian College of Phlebology 13th Annual Scientific Meeting, 9th February 2010, Auckland, New Zealand.
- 13 Bemmelen PS, Beach K, Bedford G, Strandness DE. The mechanism of venous valve closure. *Arch Surg* 1990; 125: 617–19.
- 14 Cavezzi A, Labropoulos N, Partsch H, Ricci S, Ciggiati A, Myers K, Nicolaides A, Smith PC. Duplex ultrasound investigation of the veins in chronic venous disease of the lower limbs – UIP consensus document. Part II. Anatomy. *Eur J Vasc Endovasc Surg* 2006; 31: 288–99.
- 15 Caggiati A, Bergan JJ, Gloviczki P, Jantet G, Wendell-Smith CP, Partsch. Nomenclature of the veins of the lower limbs: an international interdisciplinary consensus statement. *J Vasc Surg* 2002; 36: 416–22.
- 16 Chen SS, Prasad SK. Long saphenous vein and its anatomical variations. *AJUM* 2009; 12 (1): 28–31
- 17 Danielsson G, Eklof B, Kistner RL. Association of venous volume and diameter of incompetent perforator veins in the lower limb – implications for perforator vein surgery. *Eur J Vasc Endovasc Surg* 2005; 30: 670–3.
- 18 Sandri JL, Barros FS, Pontes S, Jacques C, Salles-Cunha SX. Diameter-reflux relationship in perforating veins of patients with varicose veins. *J Vasc Surg* 1999; 30: 867–74.
- 19 Perrin M, Guex JJ, Ruckley CV, dePalma RG, Royle JP, Eklof B, *et al*. Recurrent varices after surgery (REVAS) a consensus document. *Cardiovasc Surg* 2000;8: 233–45.
- 20 Perrin MR, Labropoulos N, Leon LR. Presentation of the patient with recurrent varices after surgery (REVAS). *J Vasc Surg* 2006; 43: 327–34.
- 21 Van Rij AM, Hill G, Gray C, Christie R, Macfarlane J, Thomson I. A prospective study of the fate of venous leg perforators after varicose vein surgery. *J Vasc Surg* 2005; 42: 1156–62.
- 22 Ascianto G, Ascianto KC, Mumme A, Geier B. Pelvic venous incompetence: reflux patterns and treatment results. *Eur J Vasc Endovasc Surg* 2009; 38: 381–6.
- 23 Park, SJ, Lim JW, Ko YT, Lee DH, Yoon Y, Oh JH, Lee HK, Huh CY. Diagnosis of pelvic congestion syndrome using transabdominal and transvaginal sonography. *AJR* 2004; 182: 683–8.
- 24 Coghlan D. Computers in the Vascular Laboratory: A practical Approach. Presented at Australian and New Zealand Society for Vascular Surgery (ANZSVS) Vascular 2004 Conference 5th September 2004, Rotorua, New Zealand.
- 25 Necas M. Computer-Generated Vascular Worksheets and Reports. Presentation at the Australian and New Zealand Society for Vascular Surgery (ANZSVS) Vascular 2004 Conference, 5th September 2004, Rotorua, New Zealand.
- 26 Necas M. Reporting vein maps efficiently for the phlebologist. Presentation at the Australasian College of Phlebology 13th Annual Scientific Meeting, 9th February 2010, Auckland, New Zealand.
- 27 Frydman G. The changing role of the venous duplex scan in the era of endovenous thermal ablation, Presentation at the Australasian College of Phlebology 13th Annual Scientific Meeting, 9th February 2010, Auckland, New Zealand.
- 28 Lane RJ, Cuzzilla ML, Harris RA, Phillips MN. Popliteal vein compression syndrome: obesity, venous disease and popliteal connection. *Phlebology* 2009; 24 (5): 201–7.