



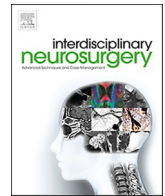
Since January 2020 Elsevier has created a COVID-19 resource centre with free information in English and Mandarin on the novel coronavirus COVID-19. The COVID-19 resource centre is hosted on Elsevier Connect, the company's public news and information website.

Elsevier hereby grants permission to make all its COVID-19-related research that is available on the COVID-19 resource centre - including this research content - immediately available in PubMed Central and other publicly funded repositories, such as the WHO COVID database with rights for unrestricted research re-use and analyses in any form or by any means with acknowledgement of the original source. These permissions are granted for free by Elsevier for as long as the COVID-19 resource centre remains active.



Contents lists available at ScienceDirect

Interdisciplinary Neurosurgery: Advanced Techniques and Case Management

journal homepage: www.elsevier.com/locate/inat

Serious and infrequent neurological complications in hospitalized patients with COVID19

Maira A. López-Hortúa^b, Pablo Andrés Rodríguez-Hernández^a, Kerly Alviarez-Chaustre^b,
Stefany Rivera-Hernández^d, Carlos Andrés Sánchez-Barrero^a, Nelson Valderrama-Mendoza^a,
Yeris Miranda-Acosta^b, Sergio Torres-Bayona^{a,b,c,*}

^a Department of Neurological Surgery and Spine Unit, Los Cobos Medical Center, Bogotá, Colombia

^b School of Medicine, Grupo de investigación básica y traslacional GIBAT, Universidad El Bosque, Bogotá, Colombia

^c Instituto Neurológico, Hospital Internacional de Colombia, Bucaramanga, Colombia

^d Department of General Internal Medicine, Los Cobos Medical Center, Bogotá, Colombia

ARTICLE INFO

Keywords

COVID-19
SARS-CoV-2
Neurosurgical manifestations
Central nervous system

ABSTRACT

Background: SARS-CoV-2 virus infection may affect other organs including the nervous system with variable neurological manifestations, even some research has reported that SARS-CoV-2 can be found in the brain parenchyma and / or in the cerebrospinal fluid (CSF). Although these reports of neurological involvement secondary to COVID-19 has increased, the clinical manifestations and the forms of neurological invasion is not fully understood.

Objectives: In this paper, we report a case series of patients with SARS-CoV-2 infection with involvement of the nervous system and its neurological complications. In addition, a bibliographic review was developed in different databases with the aim of expanding information on neurological complications and the pathophysiological mechanisms of invasion to the nervous system.

Case report: Case 1, a 79 year old male developed an infarct of the head of the caudate nucleus and thrombosis of the superior longitudinal sinus. Case 2, a 62 year old female developed an intraparenchymal hemorrhage in the left parietal lobe while hospitalized and COVID19 encephalitis was diagnosed. Case 3, a 59 year old healthy male developed a Fisher IV subarachnoid hemorrhage by aneurysmal origin of the right middle cerebral artery and right temporal intraparenchymal hematoma, due to rapid and severe neurological impairment new brain images was performed showing a right cerebellar ischemic stroke leading to compression of the cistern and brainstem. **Conclusions:** In these cases, the surgery goal was relieved symptoms, neurologic functional recovery, and life survival. We considered its diffusion and knowledge as imperative for all practitioners involved in the care of this patient.

1. Introduction

The Coronavirus disease 2019 (COVID-19) caused by the new coronavirus SARS-CoV-2, was first detected in Wuhan city, China, in December 2019. The virus has spread rapidly and caused a global pandemic declared by WHO only 3 months later (March 2020) [1–3]. Due to its high morbidity and mortality it has been the focus of multiple studies, however, the available information is still limited. The spectrum of the disease is wide, from asymptomatic, those with mild infection whose most common symptoms are fever, cough, fatigue, headache; to those who develop severe disease with pneumonia, severe acute

respiratory distress syndrome (SARS), cardiac problems, leading to multi-organ failure and death. [2–5,8] Although the predominant symptoms are respiratory, it has been identified that the virus can penetrate the nervous system generating variable neurological manifestations, such as: convulsions, alterations in mental status, cerebrovascular disease, meningitis, encephalitis, Guillain-Barré syndrome among other immune-based manifestations; neurological involvement is associated with greater frequency in patients with severe SARS-CoV-2 infection, who are in critical condition [1–4,7].

The SARS-CoV-2 virus genome encodes four structural proteins, including the spike (S) glycoprotein, which is critical for understanding

* Corresponding author at: Department of Neurological surgery and spine unit, Los Cobos Medical Center, Bogotá 110111, Colombia.

E-mail address: drsergioandrestorres@gmail.com (S. Torres-Bayona).

<https://doi.org/10.1016/j.inat.2022.101493>

Received 12 October 2021; Received in revised form 7 January 2022; Accepted 9 January 2022

Available online 12 January 2022

2214-7519/© 2022 The Authors. Published by Elsevier B.V. This is an open access article under the CC BY-NC-ND license (<http://creativecommons.org/licenses/by-nc-nd/4.0/>).

the mechanisms of viral infection. SARS-CoV-2 infects cells through the S protein, which binds to the angiotensin II-converting enzyme receptor (ACE2), which is widely distributed in the human body. [1,6,9] ACE2 receptors have been identified in neurons of the brainstem nuclei and in areas of the motor cortex, which would explain some neurological symptoms when infection is present. Once the cells are infected, an inflammatory cascade is generated that triggers the inflammatory response mediated by T Helper lymphocytes, this process is produced by the secretion of proinflammatory cytokines (interleukin 1, interferon gamma, monocyte attracting protein 1, among others), it is considered that the severity of symptoms may be related to a cytokine storm [1,6,9–11]. Neurological involvement can be caused by direct or indirect injury, either through direct viral replication in the nervous system or through the inflammatory cascade, immune dysregulation and metabolic alterations [9–11].

2. Clinical cases

We present case series of three patients with severe COVID-19 who developed neurological complications during hospitalization.

2.1. Case 1

79 year old male patient with a history of coronary artery disease revascularized five years ago, smoking, dyslipidemia, in postoperative three days after resection of right frontal brain tumor, readmitted to the emergency department (ED) for altered consciousness, a simple computed tomography of the brain showed acute epidural hematoma in the operative bed in the absence of mass effect, without requiring further surgery. No history of recent head trauma was documented.

The patient also had respiratory signs and symptoms; chest X-ray showed atelectasis and bronchial edema in both lung fields; blood biochemistry with mild leukocytosis, neutrophilia and elevated LDH, coagulation times and platelets with normal levels. Chest CT angiography showed an acute peripheral subsegmental pulmonary embolism and a small area of local distal infarction, confirming pulmonary thromboembolism, so full anticoagulation was initiated. The real-time reverse transcription-polymerase chain reaction (RT-PCR) test (gold standard for the diagnosis of COVID19) was positive.

On the tenth day of hospital stay he presented deterioration of consciousness, a new simple brain CT scan was performed showing a right frontal intraparenchymal hematoma in the surgical cavity (Fig. 1A). Urgent drainage of intracranial collections was performed (Fig. 1A), which led to an improvement in his state of consciousness. Two days after surgery, he presented deterioration of consciousness to coma. Initially, a stroke of the head of the caudate nucleus was documented on brain magnetic resonance imaging (MRI) (Fig. 1B), which did not explain his neurological status. Two weeks after surgical drainage, a new brain MRI + magnetic resonance angiography was performed, showing frontal, parietal and occipital bihemispheric infarcts and thrombosis of the superior sagittal sinus (Fig. 1C), probably secondary to COVID19. Currently, he is totally dependent for his activities of daily living with a Barthel index of 0.

2.2. Case 2

A 62 year old female patient with a history of arterial hypertension who was admitted to the ED with respiratory signs and symptoms, diagnosed with viral pneumonia by positive SARS-CoV-2 RT-PCR test, admission paraclinics with mild leukopenia, respiratory alkalosis, coagulation times and platelets at normal levels. On the third day of hospital stay he presented severe respiratory failure, requiring emergency invasive mechanical ventilation and vasopressor support. Five days later, sedation was gradually withdrawn to initiate awakening and spontaneous ventilation test, extubation was achieved on day seven. Upon awakening with altered state of consciousness, with a Glasgow

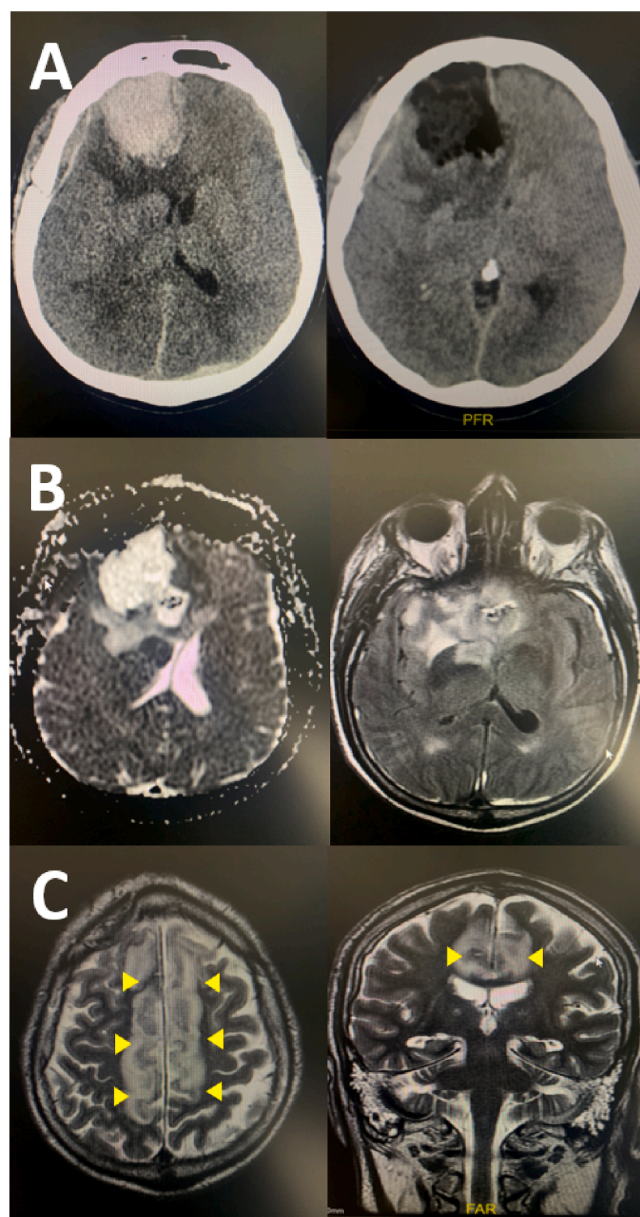


Fig. 1. Case 1. **A:** Pre and postoperative brain CT scan showing right frontal intraparenchymal hematoma associated to mass effect and after surgical drainage, respectively. **B:** Day 3 brain MRI showed a stroke of head of the caudate nucleus. **C:** Week 2 brain MRI showing frontal, parietal and occipital bihemispheric infarcts due to superior sagittal sinus thrombosis.

Coma Score (GCS) of 7/15, a simple computed tomography of the brain was performed (Fig. 2A) showing a supratentorial parenchymal hemorrhage in the left parietal lobe with perilesional edema that generated a midline shift. A brain MRI (Fig. 2B, 2C) found a filling defect in the left transverse sinus, although there was a distant contrast passage to the sigmoid sinus. On physical examination the response to nociceptive stimulus was decortication and anisocoria, due to dilation of the right pupil. The pupil dilation was right and the hematoma was located on the left, in addition, the hematoma was in the posterior region and there was no herniation of the temporal tonsil, at the time she was under thromboprophylaxis with low molecular weight heparin and coagulability paraclinics at normal levels. Due to the fact that the clinical signs did not correlate with the imaging findings, COVID19 encephalitis was suggested (Fig. 2C). On the seventh day after extubation, the neurosurgical board decided to perform surgery to drain the intracerebral collection

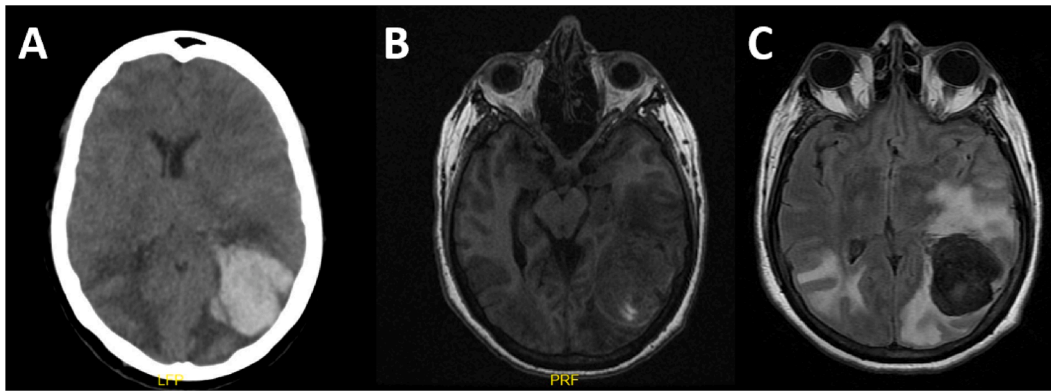


Fig. 2. Case 2. Brain images showing an intracerebral hemorrhage in the left parietal lobe measuring $4.6 \times 4.3 \times 3.6$ cm, perilesional edema and mass effect with 7.5 mm midline shift (A: Simple brain CT scan, B: T1 sequence MRI, C: T2-FLAIR sequence).

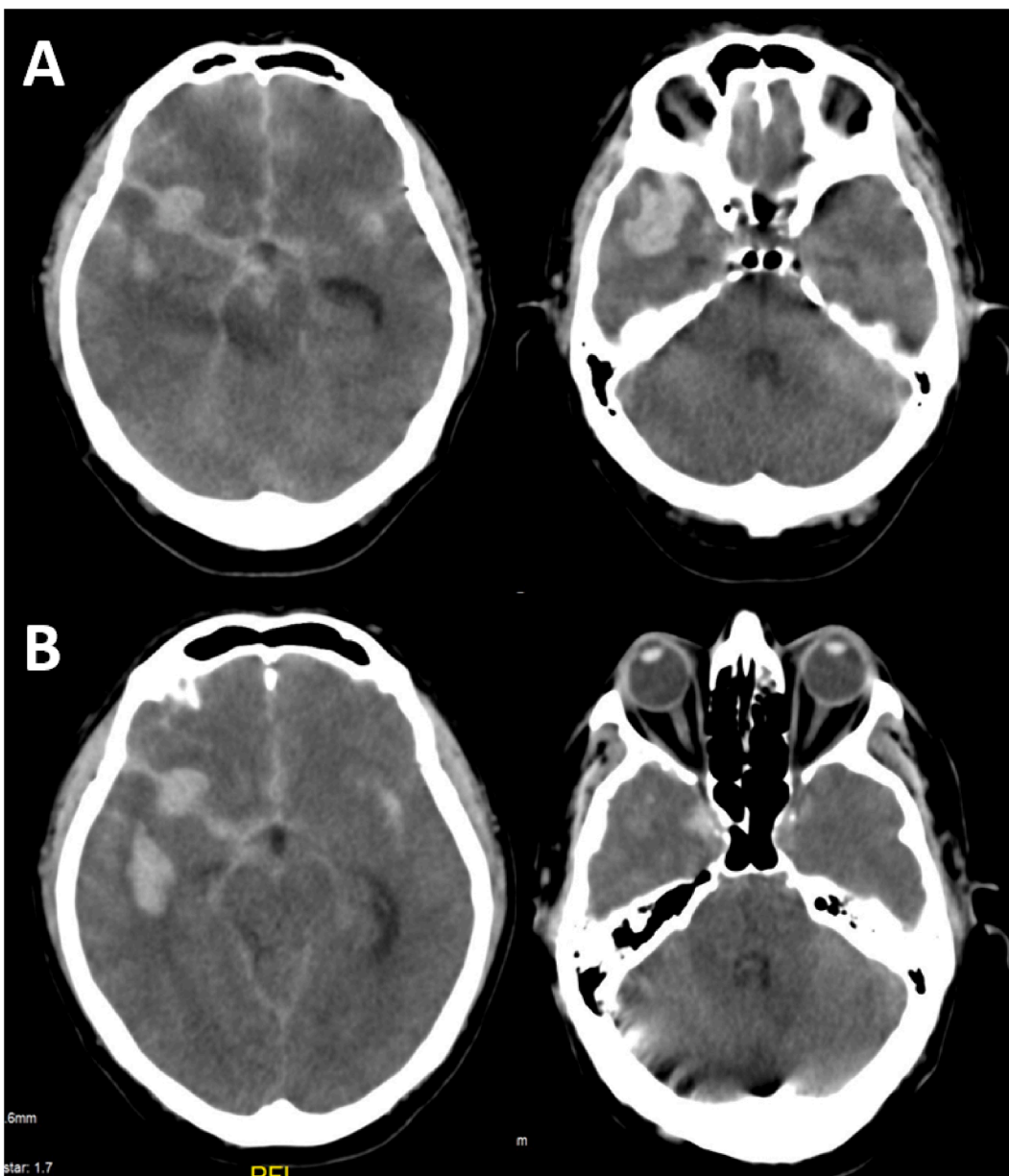


Fig. 3. Case 3. Brain CT scan showing a Fisher IV subarachnoid hemorrhage of aneurysmal origin (right middle cerebral artery), right temporal intraparenchymal hematoma (A) that generates mass effect with 4.8 mm midline shift and no ischemic lesions. (B) 3-hour later, a new CT scan showed an ischemic stroke in the right cerebellar hemisphere and compression of the cistern and brainstem.

and take a biopsy of the brain parenchyma, a sample processed at the national health institute, which was positive for SARS-CoV-2 infection, confirming the diagnostic hypothesis of viral meningoencephalitis. Two days after the surgical procedure, the patient improved her neurological status with GCS 14/15. Postoperatively she presented infectious symptoms, with seropurulent discharge from the surgical wound, leukocytosis of 19,000 with neutrophils of 80% and C-reactive protein (CRP) of 67, neuroimaging suggests brain abscess, so she was taken to surgery for drainage of the collection and antibiotics were started with coverage of the central nervous system.

2.3. Case 3

A 59 year old male patient, with no relevant medical history, was admitted to the ED for headache and vomiting of 6 h of evolution, associated with a paroxysmal episode of upward gaze deviation, without abnormal movements or loss of consciousness. Physical examination on admission revealed drowsiness, eye opening to verbal call, GCS 14/15, increased polygon of sustentation and ataxic gait. Simple brain CT scan (Fig. 3) showed a Fisher IV subarachnoid hemorrhage due to aneurysmal origin of the right middle cerebral artery, right temporal temporal intraparenchymal hematoma deviating the midline, and absence of ischemic lesions.

As per medical center protocol during the COVID-19 pandemic, a chest X-ray was performed, which showed a ground-glass pattern in the pulmonary base and right apex, confirming by RT-PCR the suspicion of SARS-CoV-2 viral pneumonia. Three hours after admission the patient deteriorated to a GCS 7/15 and pupillary dilatation not reactive to light, so airway protection and a new brain CT scan were performed. The latter revealed a new finding of right cerebellar ischemic stroke causing cisternal and brainstem compression, possibly secondary to cerebral venous sinus thrombosis. During the first 12 h, endovascular management with phenon 17 microcatheter that is located within the aneurysm of the right m1 segment of the middle brain, the aneurysm is embolized with 7x30, 5x15, 3x8 and 3x8 coils. Neuroprotective care is implemented, the patient is kept under sedation but due to the injuries and neurological status the patient dies.

3. Discussion

We reviewed recent literature in different databases on the mechanisms of invasion to the nervous system by SARS-CoV-2 virus, neurotropism and neurological manifestations. The research resulted in limited scientific evidence, so we wish to expand and share the information and our clinical experience. We have discussed three clinical cases of adult patients of different sexes with a diagnosis of SARS-CoV-2 viral infection, confirmed by PCR, with no risk factors for hypercoagulable state, who have a clinical presentation of cerebral thrombotic and hemorrhagic events requiring emergency neurosurgical intervention.

The pathophysiological mechanisms of the damage caused by SARS-CoV-2 in the nervous system are not clear; indirect and direct infection have been described [6,9–11]. Indirect infection occurs when the virus crosses the blood–brain barrier, there are two hypotheses of the mechanisms of neuroinfection: a first pathway is hematogenous through the angiotensin converting enzyme receptor (ACE2) found in the microvascular endothelium of the brain, which leads to alteration of binding complexes generating mitochondrial damage and/or activation of NADPH oxidase, favoring an increase in free radicals causing damage by oxidative stress, increasing the permeability of the blood–brain barrier and consequently the invasion of the virus into the central nervous system, triggering the release of cytokines and proinflammatory substances generating neuroinflammation, which would explain the diversity of symptoms [6,9,11]; On the other hand, hypoxic neuronal damage secondary to viral infection has also been described in the respiratory system damaging the respiratory alveoli generating vasodilation, hypercapnia, hypoxia and anaerobic metabolism, inducing

cellular edema, decrease of cerebral blood flow leading to cerebral ischemic events [9], this invasive mechanism could explain what happened in case 1 and case 3, which presented alteration of the state of consciousness due to multiple hemorrhagic and ischemic cerebral vascular damages, including thrombosis of the venous sinus.

The second mechanism described is related to the autoimmune response, related to the cross activation of antibodies and auto-sensitization of T leukocytes; the migration of leukocytes through the blood–brain barrier by means of a mechanism known as “Trojan Horse”, it is important to emphasize that T lymphocytes favor invasion but not viral replication [7,8].

The direct pathway is neuronal, through *trans*-synaptic transfer [5]. It has been suggested that one of the main entry points of the virus is the nasal cavity, through the olfactory epithelium; once the virus comes into contact with the olfactory nerve, it can enter the central nervous system through the cribriform plate of the ethmoid [5]. It has also been described that the virus can affect peripheral nerve endings, which it invades through synapses by anterograde or retrograde transport by a mechanism of endocytosis and/or exocytosis. Once the virus is inside the cerebrospinal fluid it easily affects more areas of the brain including the brainstem where there is greater ACE2 activity, this may be one of the reasons for acute respiratory failure [5,8–10]. Based on the current scientific literature it is hypothesized that the second invasive mechanism could have occurred in case 2, but it is not possible to clarify an exact mechanism, even several invasive mechanisms may be present in the same patient.

SarsCoV-2 infection is characterized by a hypercoagulable state generating thromboembolic events despite thrombotic prophylaxis, mainly pulmonary thromboembolism. Ischemic strokes, however, venous sinus thrombosis has been reported in 2% of patients with viral infection [12,13], a manifestation evidenced in case reports, which leads to neurological deterioration and are the main causes of surgical requirement.

Studies in the population of China categorized the neurological clinical manifestations in 3 categories: “manifestations of the central nervous system (CNS) (dizziness, headache, altered consciousness, acute cerebrovascular disease, ataxia and convulsions), manifestations of the peripheral nervous system (PNS) (altered taste, altered smell, altered vision, and nerve pain) and manifestations of muscle damage” [4]. Percentage-wise, 36.4% of the patients presented manifestations of the nervous system, of which 24.8% were patients with central nervous system involvement whose most frequent symptom was dizziness and headache, 19% with peripheral nervous system involvement, the most frequent symptomatology was alteration of taste and smell, and musculoskeletal lesion in 23% [4].

The neurological symptoms of COVID-19 may be due to the large number of ACE2 receptors expressed in neuronal and glial cells of structures such as the olfactory epithelium, cortex, striatum, substantia nigra and brainstem, but the proinflammatory state, metabolic alterations or immune mechanisms are also considered [1,4,6]. Neurological manifestations occur in a range of 22.5 to 36.4% of all patients with COVID19 among different studies [4,8]. Some cases with a diagnosis of SARS-CoV-2 viral encephalitis have been reported, however, many of them did not present changes in the images; most of the confirmed cases of viral infection in the parenchyma were postmortem [9–11], therefore the importance of documenting case 2 where the infection in the brain parenchyma is confirmed in a patient who is still alive.

4. Conclusion

COVID19 has presented a rapid spreading, declaring itself a pandemic in a short time generating a high mortality rate, therefore multiple mechanisms of invasion and viral tropism are still unknown, mechanisms by which the diverse symptoms that have been documented are generated. It is known that the main symptomatology is respiratory, however it is not exclusive of this system, virus invasion in the nervous

system has been documented as evidenced in Case 2 where meningo-encephalitis is confirmed by biopsy of brain parenchyma. Also, in the literature there are reports of viral infection in the cerebrospinal fluid, but the information is limited. It is important to perform neuropathological studies of patients infected by SARS-CoV-2 virus, and to evaluate acute symptoms in order to know the natural history of the disease and to generate best treatment algorithms. Long-term neurological sequelae have also been described; therefore, it is suggested to make reports of infected patients to clarify the pathophysiology of the disease and the potential for virus lesions in the central nervous system.

5. Authorship statement

M.A.-L.H., K.-A.C., P.A.-R.H., and S.-R.H., wrote the manuscript. M. A.-L.H., K.-A.C., P.A.-R.H., S.-R.H., N.-V.M., and C.A.-S.B., performed research, collected patient information, and helped to analyze data; Y.-M.A., performed bioinformatics and biostatistical analysis; and S.-T.B. designed the research, directed the work, analyzed data, provided funding and was the main surgeon.

Declaration of Competing Interest

The authors declare that they have no known competing financial interests or personal relationships that could have appeared to influence the work reported in this paper.

References

- [1] A.S. Zubair, L.S. McAlpine, T. Gardin, S. Farhadian, D.E. Kuruville, S. Spudich, Neuropathogenesis and Neurologic Manifestations of the Coronaviruses in the Age of Coronavirus Disease 2019: A Review, *JAMA Neurol.* 77 (8) (2020) 1018–1027, <https://doi.org/10.1001/jamaneurol.2020.2065>.
- [2] Y. Wu, X. Xu, Z. Chen, J. Duan, K. Hashimoto, L. Yang, C. Liu, C. Yang, Nervous system involvement after infection with COVID19 and other coronaviruses, *Brain Behav. Immun.* 87 (2020) 18–22, <https://doi.org/10.1016/j.bbi.2020.03.031>.
- [3] L.F. Arriola Torres, K.R. Palomino Taype, Manifestaciones neurológicas de COVID19: Una revisión de la literatura [Neurological manifestations of COVID-19: A literature review], *Neurología Argentina.* 12 (4) (2020) 271–274, <https://doi.org/10.1016/j.neuarg.2020.07.005>.
- [4] L. Mao, H. Jin, M. Wang, Y.u. Hu, S. Chen, Q. He, J. Chang, C. Hong, Y. Zhou, D. Wang, X. Miao, Y. Li, B. Hu, Neurologic Manifestations of Hospitalized Patients With Coronavirus Disease 2019 in Wuhan, China. *JAMA Neurol.* 77 (6) (2020) 683, <https://doi.org/10.1001/jamaneurol.2020.1127>.
- [5] J. Matías-Guiu, U. Gomez-Pinedo, P. Montero-Escribano, P. Gomez-Iglesias, J. PortaEtessam, J.A. Matias-Guiu, Should we expect neurological symptoms in the SARS-CoV-2 epidemic?. ¿Es esperable que haya cuadros neurológicos por la pandemia por SARS-CoV-2? *Neurología (Engl. Ed.)* 35 (3) (2020) 170–175, <https://doi.org/10.1016/j.nrl.2020.03.001>.
- [6] C. Iadecola, J. Anrather, H. Kamel, Effects of COVID-19 on the Nervous System, *Cell.* 183 (1) (2020) 16–27.e1, <https://doi.org/10.1016/j.cell.2020.08.028>.
- [7] A.A. Asadi-Pooya, L. Simani, Central nervous system manifestations of COVID-19: A systematic review, *J. Neurol. Sci.* 413 (2020) 116832, <https://doi.org/10.1016/j.jns.2020.116832>.
- [8] J.R. Berger, COVID-19 and the nervous system, *J. Neurovirol.* 26 (2) (2020) 143–148, <https://doi.org/10.1007/s13365-020-00840-5>.
- [9] J.I. Guerrero, L.A. Barragán, J.D. Martínez, et al., Central and peripheral nervous system involvement by COVID-19: a systematic review of the pathophysiology, clinical manifestations, neuropathology, neuroimaging, electrophysiology, and cerebrospinal fluid findings, Published 2021 Jun 2, *BMC Infect. Dis.* 21 (1) (2021) 515, <https://doi.org/10.1186/s12879-021-06185-6>.
- [10] E.E. Reza-Zaldívar, M.A. Hernández-Sapiéns, B. Minjarez, et al., Infection Mechanism of SARS-COV-2 and Its Implication on the Nervous System, Published 2021 Jan 29, *Front. Immunol.* 11 (2021), <https://doi.org/10.3389/fimmu.2020.621735>.
- [11] D.I. ElBini, Does coronaviruses induce neurodegenerative diseases? A systematic review on the neurotropism and neuroinvasion of SARS-CoV-2, *Drug Discov. Ther.* 14 (6) (2021) 262–272, <https://doi.org/10.5582/ddt.2020.03106>.
- [12] Dakay K. Cooper, Bloomfield J. Jared, Cerebral Venous Sinus Thrombosis in COVID-19 Infection: A Case Series and Review of The Literature, *Case Report.* 38 (2021), <https://doi.org/10.1016/j.jstrokecerebrovasdis.2020.105434>.
- [13] C. Lodigiani, G. Lapichino, L. Carenzo, Venous and arterial thromboembolic complications in COVID-19 patients admitted to an academic hospital in Milan, *Italy.* 191 (2020) P9–P14, <https://doi.org/10.1016/j.thromres.2020.04.024>.