



Case report

Opsoclonus-ataxia syndrome and mature ovarian teratoma in an adolescent

Emily M. Webster, Joan Tymon-Rosario, Johanna D'Addario, Burak Zeybek, Elena S. Ratner*

Department of Obstetrics, Gynecology, and Reproductive Sciences Yale University School of Medicine, CT 06520, USA

1. Introduction

Opsoclonus-ataxia syndrome is a rare clinical entity characterized by involuntary multidirectional ocular saccades and a loss of voluntary coordination (Desai and Mitchell, 2012). Behavioral disturbances may also be seen. Because the syndrome presents with a spectrum of symptoms that may include involuntary muscle movements, the terms opsoclonus-myoclonus syndrome and opsoclonus-myoclonus-ataxia syndrome may be used interchangeably with opsoclonus-ataxia syndrome. This report describes a case of opsoclonus-ataxia syndrome and mature ovarian teratoma in an adolescent.

2. Case description

A 16-year-old nulliparous female presented to the emergency department with the complaint of acute dizziness for six days. Two weeks prior to presentation, she developed nasal pruritis and congestion for which she was prescribed azithromycin for presumed sinusitis. Her medical history was notable for focal seizure-like episodes with a normal electroencephalogram. Such episodes resolved by age 8, and she was not taking any medications. She was not sexually active and had never had a gynecologic exam. She was admitted and treated with meclizine and intravenous fluids with minimal effect. A brain MRI was performed which was consistent with sinusitis alone. Her dizziness worsened, and she was transferred to a tertiary level care center.

Upon transfer, the patient reported vertigo, shakiness, double vision, nausea, gait instability, and frequent panic attacks. Neurology, ophthalmology, and psychiatry consultations were obtained. Social work and physical therapy were involved as well. Physical exam was notable for abnormal repetitive rapid eye movements, occasional tremulous movements, and inability to ambulate due to gait instability. She had full strength, normal sensation, normal reflexes, and no dysmetria. A repeat MRI of the brain was within normal limits without sinusitis. The differential diagnosis for her symptoms at this time included metabolic, infectious, postinfectious, autoimmune, and paraneoplastic etiologies.

On hospital day 4 following transfer, a lumbar puncture was performed which demonstrated a lymphocytic pleocytosis (485 cells/ μ L;

94% lymphocytes), elevated protein (74.3 mg/dL), and normal glucose (54 mg/dL). The infectious disease service was consulted, and infectious work up was otherwise negative. An antibody panel (NMDAR, VGKC-complex, LGI1-IgG, CASPR1-IgG, GAD65, GABA-B-R, AMPA-R, amphiphysin, CRMP-5, anti-gliar nuclear type 1, neuronal nuclear types 1–3, and Purkinje cell cytoplasmic types 1, 2, and Tr) was ultimately negative, though results were not available until time of discharge. She underwent an MRI of the chest, abdomen, and pelvis with and without contrast to evaluate for malignancy. MRI demonstrated a 5 × 5.3 × 4.1 cm heterogeneously enhancing pelvic lesion with solid and cystic components consistent with a right-sided ovarian teratoma (Fig. 1). Prior to MRI, her most recent pelvic imaging was three years earlier and demonstrated normal-appearing bilateral ovaries. Her clinical status worsened, and she developed tongue deviation and dysmetria on finger-nose-finger testing. She was started on high dose methylprednisolone for 5 days and intravenous immunoglobulin 1 g/kg daily for 2 days.

Due to the MRI finding of ovarian teratoma and concern for paraneoplastic syndrome, the gynecologic oncology service was consulted. On hospital day 6, she underwent a surgically uncomplicated exploratory laparoscopy, right salpingo-oophorectomy, and removal of the mass through a trocar site using a specimen retrieval bag. Survey of the abdomen and pelvis was notable only for enlarged right ovary. Pathology confirmed a 5 cm mature cystic teratoma that contained a substantial amount of disorganized neural elements associated with intense chronic inflammatory infiltrate. Pelvic washings were negative.

Perioperatively, the patient experienced new onset hypertension and intense pruritis. Pediatric nephrology consultation was obtained, and the etiology of her hypertension was felt to be due to anxiety, postoperative pain, steroids, and intravenous immunoglobulin. Her neurologic exam was notable for the development of clonus and dysphasia with unilateral vocal cord paralysis.

By hospital day 9, her symptoms were improving albeit present. She was initiated on a 6-week prednisone taper. By hospital day 14, her symptoms were thought to have plateaued, and rituximab was initiated. She was started on fluoxetine for anxiety. After 19 days of hospitalization, the patient was discharged to an acute rehabilitation facility. At the time of discharge her physical exam was notable for prominent

* Corresponding author at: Department of Obstetrics, Gynecology, and Reproductive Sciences, Co-Chief Gynecologic Oncology, Yale School of Medicine, 310 Cedar Street, FMB Room 328, New Haven, CT, 06520-8063, USA.

E-mail address: elena.ratner@yale.edu (E.S. Ratner).

<https://doi.org/10.1016/j.gore.2020.100601>

Received 7 May 2020; Received in revised form 7 June 2020; Accepted 9 June 2020

Available online 24 June 2020

2352-5789/ Published by Elsevier Inc. This is an open access article under the CC BY-NC-ND license (<http://creativecommons.org/licenses/by-nc-nd/4.0/>).

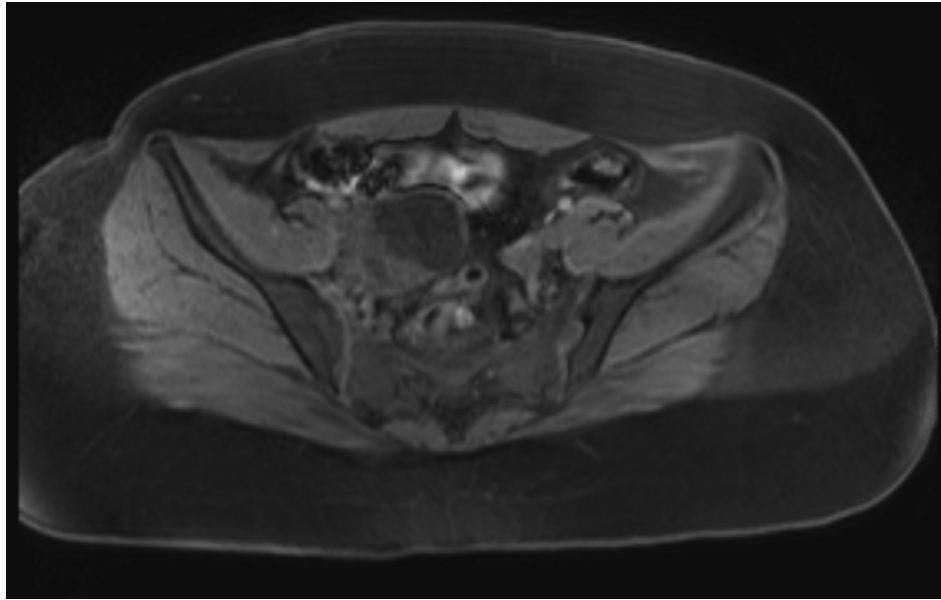


Fig. 1. Representative image of teratoma on MRI; transverse T1 series with contrast.

nystagmus, intermittent tremor, mild dysmetria, and mild hyperreflexia. She required 2-person assistance to ambulate.

Two weeks following discharge she was seen in the outpatient setting and was noted to have persistent symptoms. She ambulated with a walker and continued intensive rehabilitation therapy. She received intravenous immunoglobulin for a total of three months and continued rituximab therapy. Six months after her hospitalization, the patient returned to school with a modified schedule. At that point, she was walking independently and had little to no dysmetria and infrequent nystagmus. She continued to take fluoxetine for depression and anxiety.

Seven months following discharge, the patient presented to the emergency department with complaints of worsening involuntary eye movement, ataxic gait, daily headache, expressive aphasia, right-sided facial numbness, and labile mood. Neurology and ophthalmology consultations were obtained. Physical exam was notable for subtle dysarthria, mild tremor, and difficulty with tandem gait. MRI/MRA of the brain was within normal limits. Due to concern for teratoma recurrence, a pelvic ultrasound was obtained and found to be equivocal. Repeat MRI of the chest, abdomen, and pelvis were without evidence of tumor. Cerebrospinal fluid studies demonstrated slightly elevated nucleated cells (14 cells/ μ L) but were otherwise within normal limits, including the antibody screen. She underwent a 5-day steroid pulse with improvement in symptoms. She was discharged on hospital day 11. Nine months after her initial hospitalization, the patient is doing well with return of baseline function.

3. Discussion

Opsoclonus-ataxia syndrome classically affects children between the ages of 1–4 years old, though cases have been identified in children of all ages and adults (Desai and Mitchell, 2012). Nearly half of childhood cases of opsoclonus-ataxia syndrome are associated with occult neuroblastoma; however, parainfectious, idiopathic, and other paraneoplastic cases have also been identified (Desai and Mitchell, 2012; Brunklaus et al., 2012). In adults, there is an underlying malignancy in approximately 40% of cases, the most common being small cell lung cancer (Armangue et al., 2016). The precise pathophysiology of the syndrome is incompletely understood but is thought to be an immune-mediated encephalopathy. While anti-Ri (anti-neuronal nuclear autoantibody type 2 [ANNA-2]) antibodies have been associated opsoclonus-ataxia syndrome in adults with breast cancer, no specific antibody target has

been consistently identified in opsoclonus-ataxia syndrome (Armangue et al., 2016).

Aggressive multimodal treatment with tumor resection and immunomodulatory agents is the standard of care (Desai and Mitchell, 2012). High dose corticosteroids and intravenous immunoglobulin are first line agents, and other immunosuppressive agents such as rituximab and cyclophosphamide may be added based on symptom severity and response to treatment. Despite treatment, approximately half of children affected by opsoclonus-ataxia syndrome have residual neurologic deficits (Tate et al., 2005; Singhi et al., 2014; Hasegawa et al., 2015). Prompt diagnosis and treatment may improve long-term prognosis (Desai and Mitchell, 2012).

Ovarian teratomas are the most common germ cell tumor in adults and the most common ovarian tumor in pediatric patients. While mature teratomas are benign, they have been implicated in a number of paraneoplastic syndromes, including the well-characterized anti-N-methyl-D-aspartate receptor (NMDAR) encephalitis. Mature teratomas have also been associated with opsoclonus-ataxia syndrome in both children and adults, and one immature teratoma has been associated with opsoclonus-ataxia syndrome in an adult (Armangue et al., 2016; Fitzpatrick et al., 2008; Kanno et al., 2015; Park et al., 2020; Lou et al., 2010).

We identified three reported cases of teratoma-associated opsoclonus-ataxia syndrome in pediatric patients (Table 1). None of the patients reported gynecologic complaints suggestive of a pelvic mass. All patients had inflammatory cerebrospinal fluid, negative antibody screen, and normal brain MRI. Two patients ultimately had an oophorectomy for management of the teratoma, while one did well with cystectomy alone. Similar to the current case, the patients experienced a decreased symptom burden within a week following surgical management. All of the patients received immunosuppressive therapy, and none had an unexplained relapse such as in our patient's case.

We acknowledge uncertainty regarding whether our patient's opsoclonus-ataxia syndrome was definitively paraneoplastic, particularly in light of symptom relapse without teratoma recurrence. Our patient had an infectious illness preceding her presentation, as did two of the three patients previously reported. The possibility exists that opsoclonus-ataxia syndrome was parainfectious in nature with an incidental finding of teratoma. Alternatively, both clinical factors together could potentially result in an aberrant immune or inflammatory response causing opsoclonus-ataxia syndrome. While the patient's symptoms

Table 1
Characteristics current case and three pediatric patients with teratoma-associated opsoclonus-ataxia syndrome.

	Current Case	Fitzpatrick et al. (Fitzpatrick et al., 2008) (Fitzpatrick et al., 2008)	Kanno et al. (Kanno et al., 2015) (Kanno et al., 2015)	Park et al. (Park et al., 2020) (Park et al., 2020)
Age	16	15	16	16
Opsoclonus	Present	present	present	present
Myoclonus	Absent	present	present	present
Ataxia	Present	present	present	present
Presenting symptom(s)	vertigo, shakiness, unsteady gait	nausea, vomiting, anorexia, unsteadiness	vertigo, nausea	headache, expressive aphasia, nausea
Additional symptoms	psychiatric disturbances (labile mood, panic attacks), nausea, hyperreflexia	drowsiness, blurred vision	hyperreflexia, Glasgow coma scale E3V5M6	-
Preceding illness	acute sinusitis	upper respiratory tract infection	fever and diarrhea	none
MRI brain	Normal	normal	normal	normal
CSF cells	lymphocytic pleocytosis (485 cells/ μ L; 94% lymphocytes)	lymphocytic pleocytosis (37 cells/ μ L)	lymphocytic pleocytosis (38 cells/ μ L; 97% lymphocytes)	moderate leukocytosis (unspecified)
CSF protein	elevated (74.3 mg/dL)	elevated (64 mg/dL)	normal	normal
CSF antibodies	none identified	none identified	none identified	none identified
Teratoma identified by	MRI	CT	CT	MRI
Teratoma size	5 cm	7 cm	4 cm	2.8 cm
Surgical intervention	laparoscopic unilateral salpingo-oophorectomy	unilateral salpingo-oophorectomy (approach not specified)	laparoscopic cystectomy	laparoscopic ovarian-sparing partial oophorectomy followed by laparoscopic ipsilateral oophorectomy
Neural tissue present in teratoma	Yes	not specified	yes	yes
Peritoneal washings	Negative	-	negative	-
Immunosuppressive therapy during admission	high dose steroids, intravenous rituximab	high dose steroids, intravenous immunoglobulin	high-dose steroids, intravenous immunoglobulin	high dose steroids
Immunosuppressive therapy continued at discharge	Yes	no	yes	no
Relapse	yes, symptom recurrence at 7 months without evidence of recurrent teratoma on MRI	no	no	yes, teratoma and symptom recurrence at 4 weeks
Follow-up time	9 months	6 weeks	1 year	18 weeks
Return to baseline function by last follow-up	yes	no, though improved	yes	yes

began improving after teratoma resection, the surgery was concurrent with initiation of medical therapy. Thus, it is not clear if the teratoma resection or medical therapy led to clinical improvement, or if either approach alone would have been sufficient. Without the ability to unambiguously attribute the syndrome to a non-paraneoplastic etiology, failure to address a paraneoplastic etiology with teratoma resection would be inappropriate.

Opsoclonus-ataxia syndrome in a pediatric patient with mature ovarian teratoma appears to have a good prognosis with standard treatment. In the evaluation of this syndrome, providers should have a low threshold for CT or MRI imaging to identify occult tumors. Both oophorectomy and cystectomy appear to be acceptable surgical treatment options, depending upon the characteristics of the tumor and the desires of the patient and provider. Long-term immunosuppressive therapy may be warranted given the potential for symptomatic relapse as with our patient. Given the rarity and complexity of this disease process, a multidisciplinary team approach is essential for an optimal outcome in the treatment of patients with opsoclonus-ataxia syndrome.

Author contributions

Elena S. Ratner and Johanna D'Addario conceived of the presented ideas. Johanna D'Addario and Emily M. Webster abstracted the data from the medical records. Emily M. Webster, Joan Tymon-Rosario, and Johanna D'Addario wrote the manuscript in consultation with Burak Zeybek and Elena S. Ratner. All authors contributed to manuscript revisions and provided final approval.

Declaration of Competing Interest

The authors declared that there is no conflict of interest.

References

- Desai, J., Mitchell, W.G., 2012. Acute cerebellar ataxia, acute cerebellitis, and opsoclonus-myoclonus syndrome. *J. Child Neurol.* 27, 1482–1488.
- Brunklaus, A., Pohl, K., Zuberi, S.M., de Sousa, C., 2012. Investigating neuroblastoma in childhood opsoclonus-myoclonus syndrome. *Arch. Dis. Child.* 97, 461–463.
- Armangué, T., Sabater, L., Torres-Vega, E., Martínez-Hernández, E., Arino, H., Petit-Pedrol, M., et al., 2016. Clinical and immunological features of opsoclonus-myoclonus syndrome in the era of neuronal cell surface antibodies. *JAMA Neurol.* 73, 417–424.
- Tate, E.D., Allison, T.J., Pranzatelli, M.R., Verhulst, S.J., 2005. Neuroepidemiologic trends in 105 US cases of pediatric opsoclonus-myoclonus syndrome. *J. Pediatr. Oncol. Nurs.* 22, 8–19.
- Singhi, P., Sahu, J.K., Sarkar, J., Bansal, D., 2014. Clinical profile and outcome of children with opsoclonus-myoclonus syndrome. *J. Child Neurol.* 29, 58–61.
- Hasegawa, S., Matsushige, T., Kajimoto, M., Inoue, H., Momonaka, H., Oka, M., et al., 2015. A nationwide survey of opsoclonus-myoclonus syndrome in Japanese children. *Brain Dev.* 37, 656–660.
- Fitzpatrick, A.S., Gray, O.M., McConville, J., McDonnell, G.V., 2008. Opsoclonus-myoclonus syndrome associated with benign ovarian teratoma. *Neurology.* 70, 1292–1293.
- Kanno, K., Kin, S., Hirose, M., Suzuki, S., Watanabe, T., Fujimori, K., 2015. Opsoclonus-ataxia syndrome associated with ovarian mature teratoma. *J. Obstet Gynaecol. Res.* 41, 1149–1153.
- Park, C., Aljabban, I., Fanburg-Smith, J.C., Grant, C., Moore, M., 2020. Pediatric whole body MRI detects causative ovarian teratoma in opsoclonus myoclonus syndrome. *Radiol Case Rep.* 15, 204–209.
- Lou, E., Hensley, M.L., Lassman, A.B., Aghajanian, C., 2010. Paraneoplastic opsoclonus-myoclonus syndrome secondary to immature ovarian teratoma. *Gynecol Oncol.* 117, 382–384.