

Assessment of Tissue Perfusion Following Conventional Liposuction of Perforator-Based Abdominal Flaps

Zeynep Deniz Akdeniz Doğan¹, Bülent Saçak¹, Doğuş Yalçın¹, Özgür Pilancı², Fatma Betül Tuncer¹, Özhan Çelebiler¹

¹Department of Plastic, Reconstructive and Aesthetic Surgery, Marmara University School of Medicine, Istanbul; ²Department of Plastic, Reconstructive and Aesthetic Surgery, Bağcılar Teaching and Research Hospital, Istanbul, Turkey

Background The effect of liposuction on the perforators of the lower abdominal wall has been investigated in several studies. There are controversial results in the literature that have primarily demonstrated the number and patency of the perforators. The aim of this study was to determine the effect of liposuction on the perfusion of perforator-based abdominal flaps using a combined laser–Doppler spectrophotometer (O2C, Oxygen to See, LEA Medizintechnik).

Methods Nine female patients undergoing classical abdominoplasty were included in the study. Perforators and the perfusion zones of the deep inferior epigastric artery flap were marked on the patient's abdominal wall. Flap perfusion was quantitatively assessed by measuring blood flow, velocity, capillary oxygen saturation, and relative amount of hemoglobin for each zone preoperatively, after tumescent solution infiltration, following elevation of the flap on a single perforator, and after deep and superficial liposuction, respectively.

Results The measurements taken after elevation of the flap were not significantly different than measurements taken after the liposuction procedures.

Conclusions The liposuction procedure does not significantly alter the perfusion of perforator-based abdominal flaps in the early period. The abdominal tissue discarded in a classic abdominoplasty operation can be raised as a perforator flap and has been demonstrated to be a unique model for clinical research.

Keywords Perforator flap / Spectrophotometry / Lipectomy

Correspondence:

Zeynep Deniz Akdeniz Doğan
Department of Plastic, Reconstructive and Aesthetic Surgery, Marmara University School of Medicine, Fevzi Çakmak Mah. Muhsin Yazıcıoğlu Cad. No. 10, Üst Kaynarca, Pendik, Istanbul 34899, Turkey
Tel: +90-533-576-6329
E-mail: zeynepakdeniz@gmail.com

The article was presented at (1) The 12th Congress of the European Federation Societies for Microsurgery, 2014, Barcelona, Spain; (2) The 6th National Congress of the Turkish Society of Reconstructive Microsurgery, 2014, Antalya, Turkey.

No potential conflict of interest relevant to this article was reported.

Received: 20 May 2016 • Revised: 29 Sep 2016 • Accepted: 4 Oct 2016

pISSN: 2234-6163 • eISSN: 2234-6171 • <https://doi.org/10.5999/aps.2017.44.2.109> • Arch Plast Surg 2017;44:109-116

INTRODUCTION

Liposuction, primarily used for aesthetic body contouring, has been demonstrated to be a safe and effective method [1,2]. The use of liposuction for flap debulking and contouring has been described in reconstructive surgery practice as well [3-6]. There are studies in the literature that have investigated the effect of li-

posuction on the perforator vessels of the lower abdominal wall [7-12]. Although these studies have frequently evaluated the perforators following abdominal liposuction by either using microangiography in fresh cadavers or color Doppler ultrasound in patients, the immediate effect of liposuction on the perfusion of the tissue has not been demonstrated. In the present study, a perforator-based abdominal flap model was created in abdomi-

noplasty patients, to quantitatively evaluate the effect of liposuction on the perfusion of tissues. In order to do this, a combined laser–Doppler spectrophotometer (CLDS) was used. The CLDS device has been used in several studies to assess zonal perfusion patterns of the deep inferior epigastric artery perforator (DIEP) flap [13–15]. The aim of this study was to quantitatively assess the perfusion of an abdominal flap isolated on a single perforator using CLDS.

METHODS

Nine female patients undergoing classic abdominoplasty were included in the study. Each patient's age and operation time, as well as the amount of tumescent solution infiltrated and the amount of liposuction performed, were recorded. The patient's blood pressure and oxygen saturation were measured before anesthesia. Informed written consent was obtained from all abdominoplasty patients. This study was approved by our hospital's local Ethics Committee of Clinical Research (protocol no. 09.2012.0103).

Surgery

Excess tissue in the lower abdomen was marked on each patient in standing position. After the patient was placed under anesthesia, perforators were located using a hand-held Doppler ultrasound. Four zones of perfusion of the DIEP flap were marked, as described by Holm et al. [16] (Fig. 1). Gridlines were drawn to further divide each zone into 6 sub-zones to provide mean values

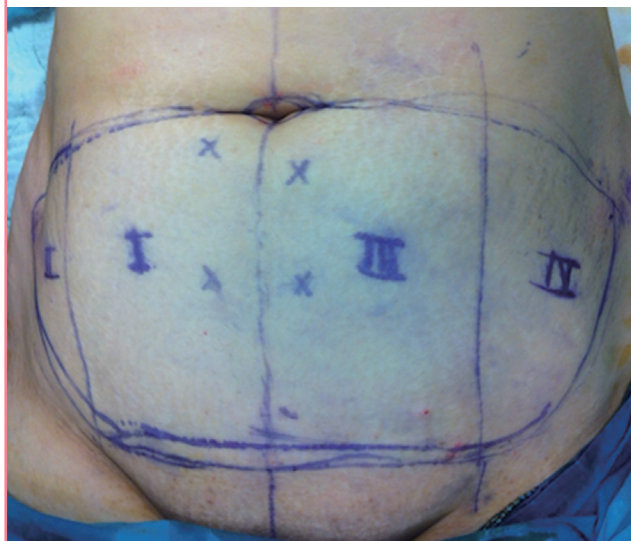
for each zone. The abdominal flap, above and below the Scarpa fascia, was infiltrated with tumescent solution (1:1,000,000 adrenalin). The flap was raised above the rectus fascia and the previously marked perforators were isolated (Fig. 2). The perforators were subjectively assessed using a hand-held Doppler ultrasound and the weaker perforators were ligated. The flap was anchored back on the abdomen using a stapler, and deep (beneath the Scarpa fascia) and superficial (above the Scarpa fascia) liposuction procedures were performed using a 3-mm blunt-tip three-hole cannula under 600 mm Hg negative pressure for 5 minutes or until 300-mL volume was reached. The amount of aspiration was recorded.

The probe of the CLDS (O2C, Oxygen to See, LEA Medizintechnik, Giessen, Germany) was placed on each sub-zone and measurements for 4 different parameters were arbitrarily recorded: capillary venous oxygen saturation (SO₂), relative amount of hemoglobin (rHb), relative blood flow (flow), and blood flow velocity (velocity). The mean value of each parameter was calculated for each zone. In addition, blood pressure and oxygen saturation of the patient were recorded. The patients all underwent operations in the same operation room. Core body temperatures were monitored. Measurements were taken at 5 different points in time: before and after tumescent solution injection, following isolation of the perforator vessel, and after deep and superficial liposuction procedures, separately.

After the measurements were completed, the perforator was ligated and the flap was excised. The operation was continued as a classic abdominoplasty with rectus muscle plication and abdominal flap suturation.

Fig. 1. Markings on the abdominal flap

Perforators were marked with a hand-held Doppler ultrasound device. The abdominally based perforator flap was divided into 4 zones as described by Holm et al. [16].

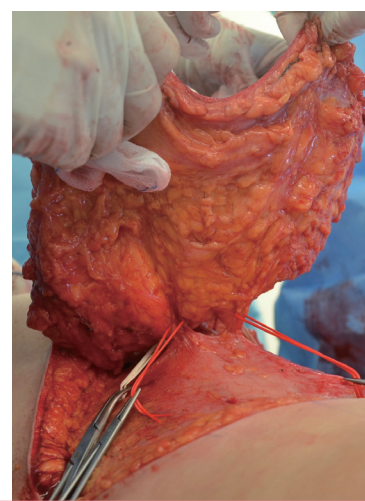


Statistical analysis

Statistical analysis was performed using Graphpad Instat ver.

Fig. 2. Elevation of the flap

Perforators were bilaterally preserved throughout flap elevation and the dominant perforator was subjectively determined with the help of a hand-held Doppler device. After ligation of the weaker perforators, the flap was raised on a single perforator.



3.05 (Graphpad Software Inc, La Jolla, CA, USA). According to data distribution, the repeated-measures analysis of variance (ANOVA) test or the Friedman nonparametric ANOVA test was used to compare measurements taken at different points in the surgical process. To further localize significant differences, the Student-Newman-Keuls multiple pairwise comparison test or the Dunn test was performed. A P-value < 0.05 was considered statistically significant.

RESULTS

The mean age of patients was 41.8 ± 6.5 years. The average amount of fat removed was 198.3 ± 56.2 mL. The average amount of tumescent solution injected was 716.7 ± 93.5 mL. The mean systolic blood pressure value was 103 ± 12.9 mm Hg; the mean diastolic blood pressure was 63 ± 8.6 mm Hg. Body temperature was maintained around 36.5°C .

Measurements taken after isolation of the flap on a single perforator were not significantly different compared to measure-

ments taken after deep or superficial liposuction in any of the zones. The results of measurements for each zone are summarized in Table 1.

For the purposes of this study, only significant differences after liposuction procedures are mentioned in the text and graphs.

Zone I

ANOVA showed significant differences at different time points for capillary venous oxygen saturation ($P = 0.005$), rHb ($P = 0.035$), blood flow ($P = 0.006$), and blood flow velocity ($P = 0.041$). Capillary venous oxygen saturation was significantly lower after deep ($P < 0.05$) and superficial ($P < 0.05$) liposuction compared to preoperative values. rHb was significantly higher following superficial liposuction compared to post-tumescent values ($P < 0.05$). Flow dropped significantly following superficial liposuction compared to preoperative values ($P < 0.05$). Velocity ($P < 0.05$) was significantly lower after superficial ($P < 0.05$) and deep liposuction ($P < 0.05$) compared to preoperative values. None of the parameters showed a significant difference following either of the liposuction procedures compared to values recorded after isolation of the perforator (Fig. 3).

Zone II

ANOVA showed significant differences at different time points for rHb ($P = 0.008$), blood flow ($P = 0.001$), and velocity ($P = 0.001$). The difference in capillary venous oxygen saturation was not significant among different time points ($P = 0.38$). rHb was significantly higher after superficial liposuction compared to post-tumescent values ($P < 0.01$) and preoperative values ($P < 0.05$). Flow was significantly lower after superficial liposuction compared to preoperative values ($P < 0.01$). Velocity significantly dropped after deep liposuction compared to preoperative ($P < 0.01$) and post-tumescent values ($P < 0.01$). Velocity also decreased significantly after superficial liposuction compared to preoperative values ($P < 0.01$) and post-tumescent values ($P < 0.01$) (Fig. 4).

Zone III

Capillary venous oxygen saturation ($P = 0.28$) and rHb ($P = 0.32$) were not significantly different at different time points. Flow ($P < 0.001$) and velocity ($P = 0.004$) were significantly different at different time points. Flow was significantly lower after deep liposuction compared to preoperative ($P < 0.05$) and post-tumescent ($P < 0.05$) values. Flow also significantly dropped after superficial liposuction compared to preoperative values ($P < 0.01$) and post-tumescent values ($P < 0.01$), separately. Velocity dropped significantly after deep and superficial liposuction compared to preoperative values, separately ($P < 0.05$) (Fig. 5).

Table 1. Capillary venous oxygen saturation, flow, velocity, and relative hemoglobin values for each zone

Time intervals	Zone I	Zone II	Zone III	Zone IV
Capillary venous oxygen saturation				
Bas	28.8 ± 12.8	25.5 ± 14.5	23.4 ± 13.6	22.3 ± 16.0
P-T	26.3 ± 14.1	23.0 ± 16.3	21.4 ± 15.7	24.1 ± 14.9
PI	20.4 ± 13.4	19.8 ± 15.2	18.8 ± 16.6	16.1 ± 17.9
DLL	19.6 ± 11.7	18.7 ± 14.8	16.4 ± 12.9	15.2 ± 14.5
SLL	22.0 ± 14.6	18.3 ± 15.4	16.5 ± 14.4	15.7 ± 13.4
Relative amount of hemoglobin				
Bas	44.4 ± 9.6	45.6 ± 10.8	45.8 ± 9.2	47.2 ± 8.2
P-T	41.7 ± 8.1	42.9 ± 7.7	46.9 ± 7.9	47.6 ± 10.8
PI	48.7 ± 10.9	51.6 ± 8.2	53.0 ± 14.8	57.1 ± 12.3
DLL	48.1 ± 6.7	52.4 ± 6.0	49.4 ± 11.4	55.9 ± 9.4
SLL	52.8 ± 11.3	56.5 ± 10.5	53.0 ± 12.9	57.4 ± 13.4
Relative blood flow				
Bas	19.1 ± 9.9	21.8 ± 10.4	19.9 ± 11.3	22.4 ± 9.9
P-T	19.3 ± 13.9	19.4 ± 10.2	18.1 ± 14.2	20.4 ± 12.7
PI	16.8 ± 16.4	11.7 ± 9.0	13.4 ± 15.0	7.1 ± 3.4
DLL	15.2 ± 11.5	11.8 ± 9.7	10.9 ± 11.5	5.9 ± 3.0
SLL	12.7 ± 7.7	9.9 ± 6.6	9.9 ± 10.1	5.4 ± 2.9
Blood flow velocity				
Bas	11.1 ± 1.3	11.2 ± 1.3	10.9 ± 1.8	11.9 ± 1.1
P-T	10.2 ± 1.8	10.8 ± 2.0	10.2 ± 1.5	12.3 ± 2.8
PI	10.0 ± 1.4	9.0 ± 1.7	8.8 ± 1.7	7.1 ± 2.3
DLL	9.4 ± 1.7	8.1 ± 2.0	8.8 ± 2.5	7.1 ± 2.4
SLL	9.3 ± 1.7	8.3 ± 1.9	9.0 ± 2.0	6.9 ± 2.7

Values are presented as mean \pm standard deviation. Note that the values are arbitrary.

Bas, basal value, before injection of tumescent solution; P-T, post-tumescent, after injection of tumescent solution; PI, post-isolation of perforator, after isolation of perforator; DLL, after deep layer liposuction; SLL, after superficial layer liposuction.

Fig. 3. Graphical representation of Zone I measurements

Significant differences are marked with an asterisk. Bas, basal value, before injection of tumescent solution; P-T, post-tumescent, after injection of tumescent solution; PI, post-isolation of perforator, after isolation of perforator; DLL, after deep layer liposuction; SLL, after superficial layer liposuction. *P<0.05.

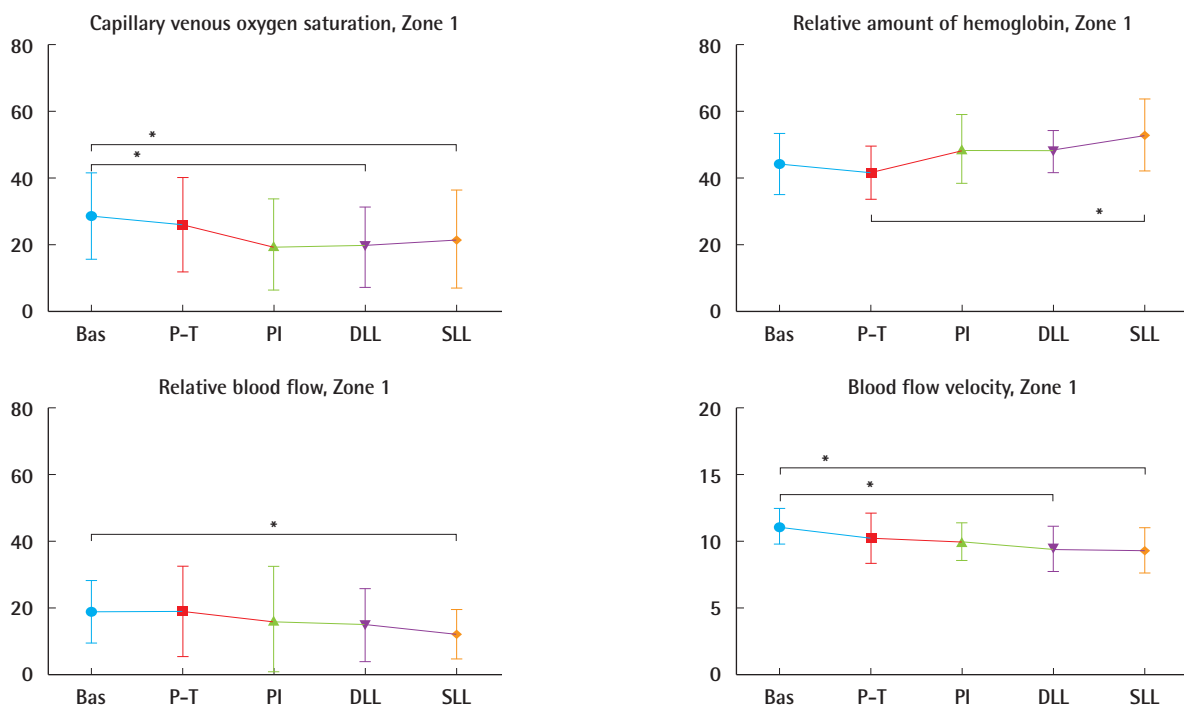


Fig. 4. Graphical representation of Zone II measurements

Significant differences are marked with an asterisk. Bas, basal value, before injection of tumescent solution; P-T, post-tumescent, after injection of tumescent solution; PI, post-isolation of perforator, after isolation of perforator; DLL, after deep layer liposuction; SLL, after superficial layer liposuction. *P<0.05.

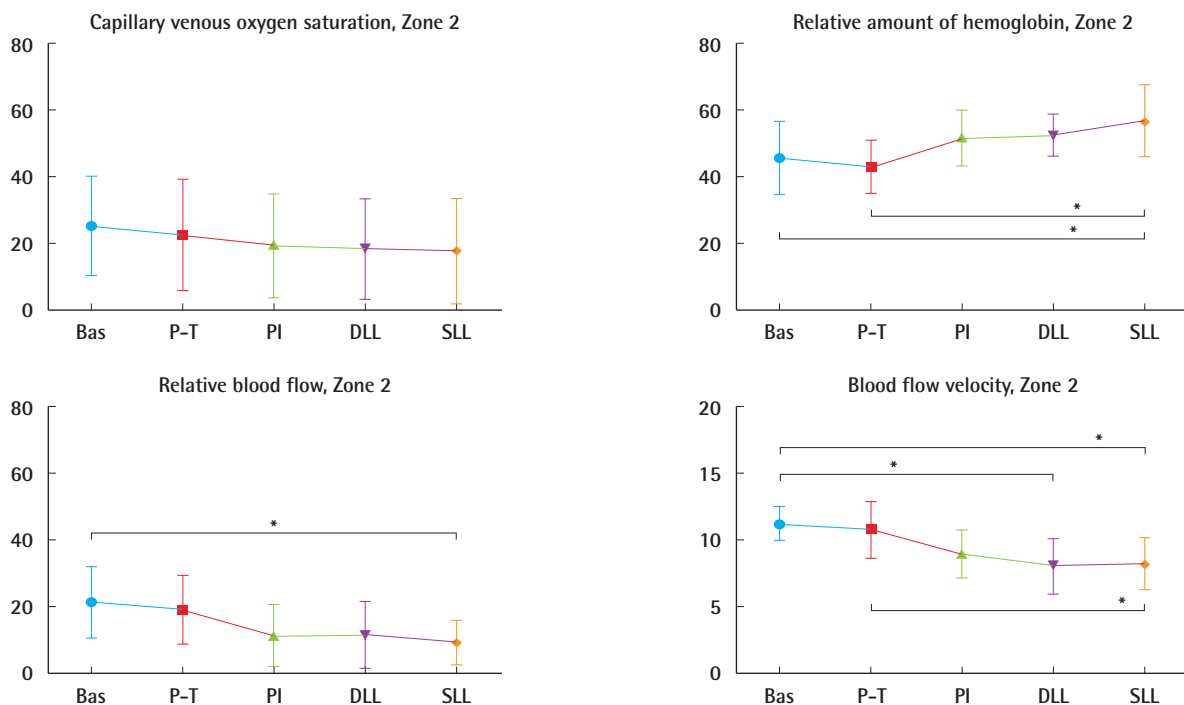


Fig. 5. Graphical representation of Zone III measurements

Significant differences are marked with an asterisk. Bas, basal value, before injection of tumescent solution; P-T, post-tumescent, after injection of tumescent solution; PI, post-isolation of perforator, after isolation of perforator; DLL, after deep layer liposuction; SLL, after superficial layer liposuction. *P < 0.05.

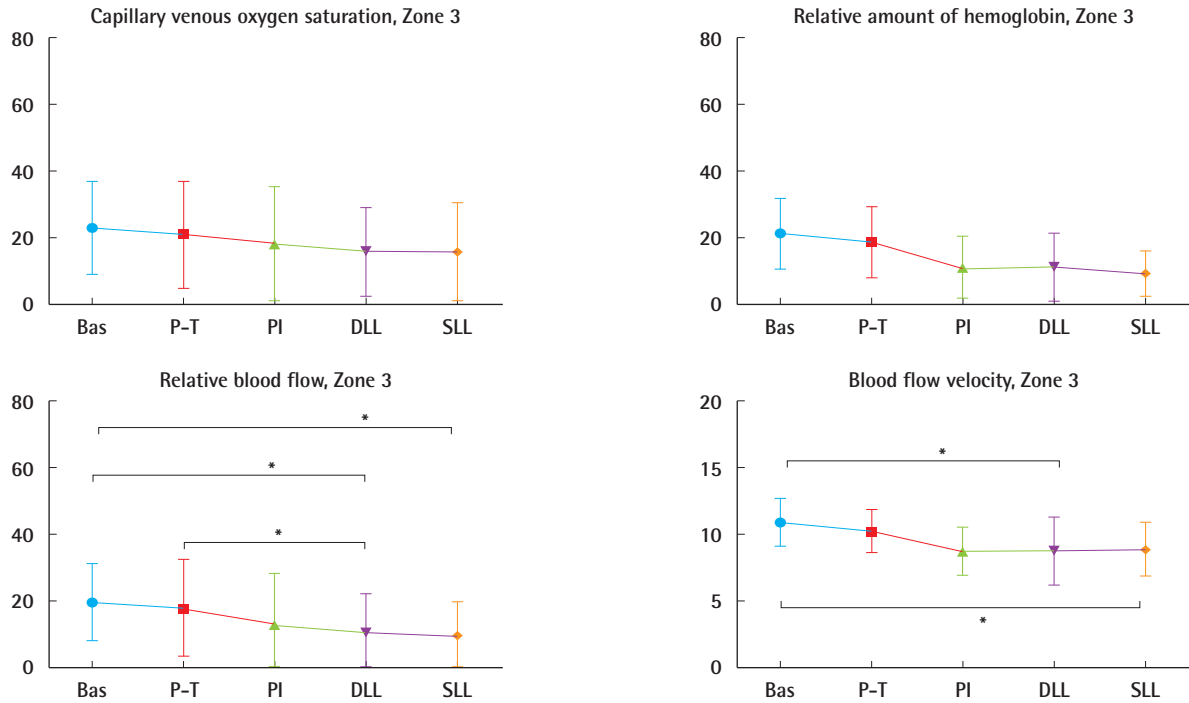
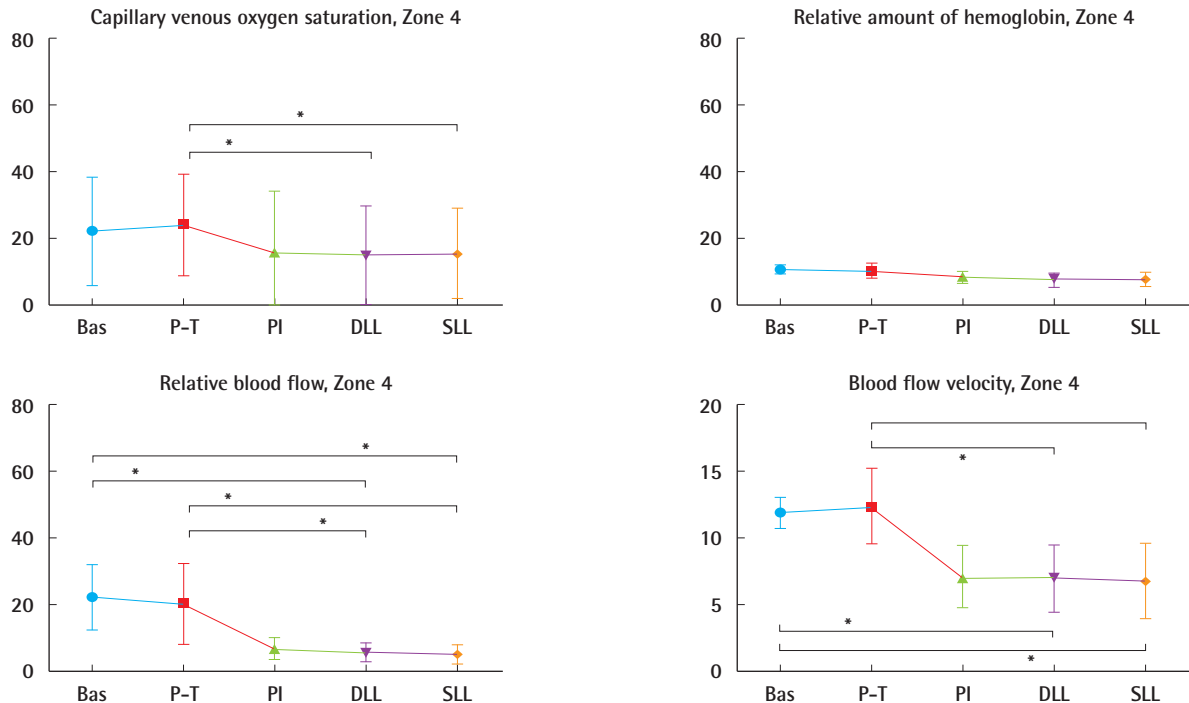


Fig. 6. Graphical representation of Zone IV measurements

Significant differences are marked with an asterisk. Bas, basal value, before injection of tumescent solution; P-T, post-tumescent, after injection of tumescent solution; PI, post-isolation of perforator, after isolation of perforator; DLL, after deep layer liposuction; SLL, after superficial layer liposuction. *P < 0.05.



Zone IV

Capillary venous oxygen saturation ($P < 0.001$), flow ($P < 0.001$), and velocity ($P < 0.001$) were significantly different at different time points. The rHb was not significantly different at different time points ($P = 0.057$). Capillary venous oxygen saturation was significantly lower after deep ($P < 0.01$) and superficial ($P < 0.05$) liposuction compared to post-tumescent values. Flow was significantly lower after deep liposuction compared to preoperative ($P < 0.01$) and post-tumescent ($P < 0.05$) values. Flow also significantly dropped after superficial liposuction compared to preoperative values ($P < 0.001$) and post-tumescent values ($P < 0.01$), separately (Fig. 6). Velocity was significantly lower after deep liposuction compared to preoperative ($P < 0.001$) and post-tumescent values ($P < 0.001$). Velocity also significantly dropped after superficial liposuction compared to preoperative ($P < 0.001$) and post-tumescent values ($P < 0.001$).

Regarding the 4 parameters, measurements taken after isolation of the flap on a single perforator showed no significant difference in any of the abdominal zones, compared to values following deep or superficial liposuction.

DISCUSSION

In the present study, the perforator-based abdominal flap was chosen as a model for investigating the effect of liposuction on perforator flaps. The ease of elevating the flap in an abdominoplasty patient, without causing significant morbidity, made it an ideal option for clinical research. The aim of this study was to demonstrate the effect of liposuction on the oxygenation of the perforator-based abdominal flap. There are controversial results in the literature regarding the effect of liposuction on the perforators of the abdominal wall. In an experimental study, it has been demonstrated that there is an increased risk of necrosis in skin flaps raised from an area where previous liposuction was performed [17]. In a clinical study, Inceoglu et al. [7] have shown that half of the perforator vessels marked preoperatively using color Doppler ultrasound could not be detected 2 weeks or 3 months postoperatively in patients undergoing liposuction. Since there was no significant difference regarding the number and location of these perforators on both postoperative Doppler examinations, they concluded that the decrease in the number of perforators was neither progressive nor reversible throughout the follow-up. On the other hand, Salgarello et al. [8], using color Doppler ultrasound, reported that all the perforators present preoperatively were also detectable 6 months after liposuction. The authors have also reported that there was no significant alteration in mean arterial flow or mean diameter of the arteries.

In a cadaver study, histologic examination on the abdominal

perforators after liposuction showed that the perforators remain intact following the procedure [10]. Endoscopic observation during liposuction also demonstrated intact perforators [11]. Emeri et al. [12], using microangiography techniques in fresh cadavers, also reported that liposuction does not damage perforator vessels. In another cadaver study comparing ultrasound-assisted liposuction and conventional liposuction, Blondeel et al. [9] demonstrated that neither technique was less damaging than the other. These studies mostly demonstrate, using different techniques, the number of perforators that remain intact after liposuction of the abdominal wall. Other clinical studies on flap thinning only report survival rates following the procedure [18]. In the present study, the effect of liposuction on the oxygenation of a perforator flap model was quantitatively demonstrated and compared. The measurement method used in this study was validated in previous experimental studies [19]. The device allows quantification of tissue perfusion. The Doppler shift caused by the movement of erythrocytes is analyzed and displayed as blood flow velocity. The laser signal correlates with the number of moving erythrocytes in the tissue. The system uses this quantity together with velocity to calculate blood flow. It also uses white light to detect oxygen saturation (SO_2) and rHb [14]. Using this device, the oxygen supply to the microcirculation of blood-perfused tissues can be determined. The O2C system presents more precise data on local oxygen supply compared with measurement of tissue partial oxygen pressure, which remains constant during changes in capillary blood flow rate or oxygen consumption [20]. Flow was demonstrated to be a better predictor of tissue perfusion while rHb and SO_2 failed to predict tissue necrosis [21]. The rHb may increase after flap isolation due to congestion. Again, capillary venous oxygen saturation represents relative ischemia due to congestion. Therefore, these 2 parameters give more information on the venous status, whereas blood flow velocity and flow represent arterial inflow.

Our knowledge of the perfusion zones of the DIEP flap was introduced by Hartrampf et al. [22], and was later modified by Holm et al. [16] using fluorescent perfusion techniques. In this present study, abdominal zones were divided according to the description of Holm et al. [16]. Knowledge of the perfusion patterns of the lower abdominal tissue flaps allowed a more accurate comparison of perfusion parameters according to zone concept. For each zone, the average of measurements taken from 6 sub-zones were calculated and compared at 5 different points. In zones II, III, and IV, velocity dropped constantly following isolation of the flap on a single perforator. This has also been reported in other studies evaluating DIEP perfusion zones using CLDS [14], and is expected in perforator flaps due to the tem-

porary decline in arterial inflow following flap elevation. In zones I–IV, flow also declined as a result of the vasoconstrictor effect of the tumescent solution. A drop in venous capillary oxygen saturation in zones I–IV and an increase in the rHb in zones I and II represent venous congestion due to isolation of the flap on a single perforator. However, measurements were not significantly different after liposuction procedures compared to measurements taken after isolation of the perforators. Hence, once the flap was elevated, liposuction procedures did not significantly alter the tissue perfusion. Rozen et al. [23] demonstrated that the cutaneous course of DIEPs defines guidelines for flap thinning. The authors described extensive branching of the perforator occurring just superficial to the Scarpa fascia. These branches radiate obliquely within the superficial layer of adipose tissue (the Camper fascia) to reach the subdermal plexus, where the majority of the anastomoses with adjacent perforators occurred. Therefore, the authors suggested the Scarpa fascia as a useful anatomical landmark for safe thinning. Flow values measured after the isolation of the perforator were not significantly different than flow values measured after liposuction. This may be attributed to anastomosis between perforasomes in the subdermal level. Since the exact location of the perforator was known to the operator, this may have caused him to avoid injuring the vessel. Nevertheless, liposuction was performed on the whole flap evenly and the perfusion parameters demonstrate that the vascular network was preserved. Even though this study does not demonstrate whether the single perforator was damaged or not, quantitative analysis of tissue perfusion gives insight into the liposuction effect on the vascular network.

In conclusion, abdominal tissue classically discarded in abdominoplasty procedures was created as a perforator flap model for the purpose of this study. We believe this to be a unique model for clinical research. Alterations in the arterial and venous statuses of the flaps were mostly attributed to the tumescent effect and ligation of the contralateral perforators, since no significant decline was observed after liposuction procedures compared to measurements taken after isolation of the perforator. Since the study was conducted on patients undergoing classic abdominoplasty procedures, the results only reflected data on the immediate period after the liposuction procedure. Further studies should be carried out to obtain data on the long-term effects of liposuction procedures on perforator flaps.

REFERENCES

1. Teimourian B, Rogers WB 3rd. A national survey of complications associated with suction lipectomy: a comparative study. *Plast Reconstr Surg* 1989;84:628-31.
2. Sattler G. Advances in liposuction and fat transfer. *Dermatol Nurs* 2005;17:133-9.
3. Hallock GG. Liposuction for debulking free flaps. *J Reconstr Microsurg* 1986;2:235-9.
4. Hallock GG. Defatting of flaps by means of suction-assisted lipectomy. *Plast Reconstr Surg* 1985;76:948-52.
5. Grazer FM. Suction-assisted lipectomy, suction lipectomy, lipolysis, and lipexeresis. *Plast Reconstr Surg* 1983;72:620-3.
6. Baird W, Nahai F. The use of lipoplasty in contouring and debulking of flaps. *Clin Plast Surg* 1989;16:395-9.
7. Inceoglu S, Ozdemir H, Inceoglu F, et al. Investigation of the effect of liposuction on the perforator vessels using color Doppler ultrasonography. *Eur J Plast Surg* 1998;21:38-42.
8. Salgarello M, Barone-Adesi L, Cina A, et al. The effect of liposuction on inferior epigastric perforator vessels: a prospective study with color Doppler sonography. *Ann Plast Surg* 2005;55:346-51.
9. Blondeel PN, Derks D, Roche N, et al. The effect of ultrasound-assisted liposuction and conventional liposuction on the perforator vessels in the lower abdominal wall. *Br J Plast Surg* 2003;56:266-71.
10. Teimourian B, Adham MN, Gulin S, et al. Suction lipectomy: a review of 200 patients over a six-year period and a study of the technique in cadavers. *Ann Plast Surg* 1983;11:93-8.
11. Teimourian B, Kroll SS. Subcutaneous endoscopy in suction lipectomy. *Plast Reconstr Surg* 1984;74:708-11.
12. Emeri JE, Krupp S, Doerfl J. Is a free or pedicled TRAM flap safe after liposuction? *Plast Reconstr Surg* 1993;92:1198.
13. Beier JP, Horch RE, Arkudas A, et al. Decision-making in DIEP and ms-TRAM flaps: the potential role for a combined laser Doppler spectrophotometry system. *J Plast Reconstr Aesthet Surg* 2013;66:73-9.
14. Rahmanian-Schwarz A, Rothenberger J, Hirt B, et al. A combined anatomical and clinical study for quantitative analysis of the microcirculation in the classic perfusion zones of the deep inferior epigastric artery perforator flap. *Plast Reconstr Surg* 2011;127:505-13.
15. Rahmanian-Schwarz A, Rothenberger J, Amr A, et al. A postoperative analysis of perfusion dynamics in deep inferior epigastric perforator flap breast reconstruction: a noninvasive quantitative measurement of flap oxygen saturation and blood flow. *Ann Plast Surg* 2012;69:535-9.
16. Holm C, Mayr M, Hofter E, et al. Perfusion zones of the DIEP flap revisited: a clinical study. *Plast Reconstr Surg* 2006;117:37-43.
17. Ozcan G, Shenaq S, Baldwin B, et al. The trauma of suction-assisted lipectomy cannula on flap circulation in rats. *Plast*

- Reconstr Surg 1991;88:250-8.
18. Reuben CM, Bastidas N, Sharma S. Power-assisted suction lipectomy of fasciocutaneous flaps in the extremities. *Ann Plast Surg* 2010;65:60-5.
 19. Walter B, Bauer R, Krug A, et al. Simultaneous measurement of local cortical blood flow and tissue oxygen saturation by Near infra-red Laser Doppler flowmetry and remission spectroscopy in the pig brain. *Acta Neurochir Suppl* 2002;81:197-9.
 20. Wolff KD, Uekermann B, Matthes G, et al. Intracapillary haemoglobin oxygenation and interstitial pO₂ in venous flaps: an experimental study in rats. *Microsurgery* 1998;18:324-30.
 21. Kneser U, Beier JP, Schmitz M, et al. Zonal perfusion patterns in pedicled free-style perforator flaps. *J Plast Reconstr Aesthet Surg* 2014;67:e9-17.
 22. Hartrampf CR, Schefflan M, Black PW. Breast reconstruction with a transverse abdominal island flap. *Plast Reconstr Surg* 1982;69:216-25.
 23. Rozen WM, Murray AC, Ashton MW, et al. The cutaneous course of deep inferior epigastric perforators: implications for flap thinning. *J Plast Reconstr Aesthet Surg* 2009;62:986-90.