

## Prosthodontic Rehabilitation of Patients with Bell's Palsy: Our Experience

Anand Rajapur<sup>1</sup>, Nirban Mitra<sup>2</sup>, V Jeevan Prakash<sup>3</sup>, Sajad Ahmad Rah<sup>2</sup>, Sagar Thumar<sup>2</sup>

### Contributors:

<sup>1</sup>Professor, Department of Prosthodontics, Vyas Dental College & Hospital, Jodhpur, Rajasthan, India; <sup>2</sup>Post-graduate Student, Department of Prosthodontics, Vyas Dental College & Hospital, Jodhpur, Rajasthan, India; <sup>3</sup>Principal, Professor and Head, Department of Oral & Maxillofacial Surgery, Vyas Dental College & Hospital, Jodhpur, Rajasthan, India.

### Correspondence:

Dr. Rajapur A. Department of Prosthodontics, Vyas Dental College & Hospital, Near KudiHod, Pali Road, Jodhpur - 342 005, Rajasthan, India. Tel.: +0291-2720002, 09413900376. Email: dranandrajapur@gmail.com

### How to cite the article:

Rajapur A, Mitra N, Prakash VJ, Rah SA, Thumar S. Prosthodontic rehabilitation of patients with Bell's palsy – Our experience. J Int Oral Health 2015;7(Suppl 2):77-81.

### Abstract:

Bell's palsy is an idiopathic unilateral lower motor neuron paresis or paralysis of the facial nerve of sudden onset. It involves loss of muscular control on the affected side of the face. This paper reports the prosthodontic management of patients with Bell's palsy and also describes a technique to stabilize the jaw movements in complete denture patients using interim dentures. A 65-year-old male edentulous patient and a 55-year-old female edentulous patient reported to the department of prosthodontics to get their missing teeth replaced. They both gave history of facial paralysis and were diagnosed for Bell's palsy. Interim training dentures with flat occlusal tables were fabricated first to correct and stabilize their mandibular movements. During initial 4 weeks, there was poor functioning of the interim dentures. Gradually by 8<sup>th</sup> week the patients started stabilizing the interim dentures and were functional. After observing the improvement when the patients had no pain and could stabilize and use the treatment dentures successfully, definitive complete dentures were fabricated. This case report presents a systematic approach to successively rehabilitate edentulous patients with Bell's palsy.

**Key Words:** Bell's palsy, definitive complete denture, flat occlusal table, interim dentures

### Introduction

Bell's palsy is a form of facial paralysis resulting from a dysfunction of the facial nerve causing an inability to control facial muscles on the affected side. The name was ascribed to Scottish surgeon Sir Charles Bell, who in 1821 demonstrated the separation of the motor and sensory innervation of the face.<sup>1</sup> Its cause is mostly idiopathic, but exposure to cold and several other contributory factors have been named such as rheumatic hypothesis, ischemic hypothesis, immunological hypothesis, viral hypothesis. The combination of facial paralysis

and herpes infection is called Ramsay Hunt syndrome.<sup>2</sup> The incidence being 15-40 cases per 100,000 population with female predilection affecting middle age group having equal chances of involvement of right and left nerves.

Patients with Bell's palsy experience sudden weakness or paralysis on affected side of the face with abrupt loss of muscular control. They also face difficulty in wrinkling the forehead, closing the eye, whistling, raising the eyebrow on the affected side. The corner of the mouth droops causing drooling of saliva. Whenever patient attempts to close the eyelid, the eyeball rolls upward so that the pupil is covered and only the white sclera is visible (Bell's sign).<sup>2,3</sup> There is obliteration of the nasolabial fold. Since the buccinator muscle weakens, food is retained in maxillary and mandibular buccal and labial vestibules. Involvement of chorda tympani nerve leads to loss of taste in the anterior two-third of the tongue and reduced salivation. The expression of the face changes drastically resulting in a mask-like appearance to the facial features.

The medical management of Bell's palsy includes massive doses of steroid administered as a bolus dose, tapered off over the next few weeks followed by physiotherapy (galvanism, massage and facial exercises). Surgical Intervention may necessitate nerve decompression (internal and external), nerve grafting, nerve anastomosis-reanimation (cross facial nerve grafts, nerve transfers and free muscle transplantation).<sup>4,5</sup>

The prosthodontic management of these patients requires a systematic approach as the clinical features of Bell's palsy may interfere with most of the steps such as impression making, jaw relation, denture retention, and stability.<sup>6</sup>

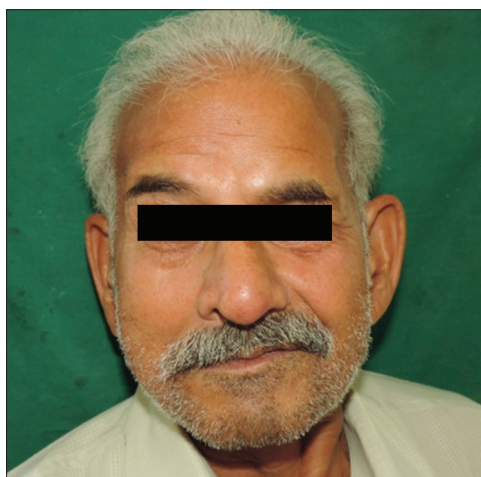
Our experience describes the prosthodontic management of two edentulous patients with Bell's palsy in which complete dentures were fabricated and successfully stabilized over a period of 8 weeks. The problems encountered during prosthodontic rehabilitation included difficulty to obtain definitive jaw positions during recording of jaw relation as the patients had unpredictable and erratic mandibular movements.

### Case Reports

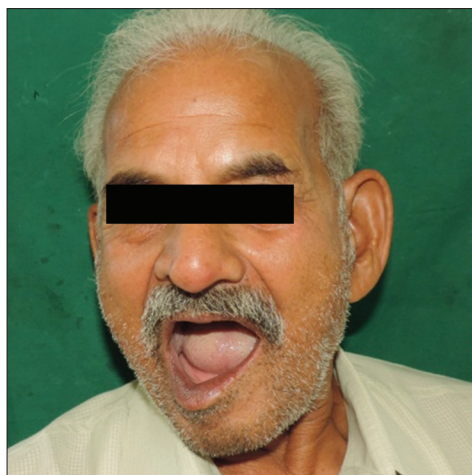
#### Case 1

A 65-year-old edentulous male patient reported with a chief complaint of missing teeth which he wanted to get replaced for the purpose of mastication and aesthetics. The medical history of the patient revealed the occurrence of facial paralysis

6 months prior on the left side of the face and was diagnosed to be suffering from Bell's palsy. He was undergoing treatment for the same. On extraoral examination asymmetry of the face, hearing loss, deviation of the mouth, drooling of saliva and positive Bell's sign were noticed (Figure 1). A conspicuous mandibular shift toward the right side (Figure 2) was observed along with significant difficulty in pronunciation of bilabial (p,b), labiodental and fricatives (f,v), and had a slurred speech. He couldn't perform tapping movement of mandible when instructed. The patient presented with reduced neuromuscular control on jaw closure and phonation as classified by House and Brackmann (1985) as Grade IV – Moderately severe dysfunction. This category includes obvious weakness and/or disfiguring asymmetry and normal symmetry and tone at rest. It also includes absence of motion at the forehead and incomplete closure of eyelid along with a symmetrical motion of jaws and closure with maximum effort.<sup>7</sup> Intraoral examination showed well-rounded maxillary edentulous ridge covered with firm mucosa. The palatal vault was shallow, U-shaped with House's Class-I hard and soft palate relation and Class-I posterior palatal seal area. The mandibular edentulous ridge was well



**Figure 1:** Pre-treatment view: Asymmetry of the face.



**Figure 2:** Pre-treatment view: Shift of mandibular jaw toward right side while opening.

rounded posteriorly and had resorbed, knife-edge ridge anteriorly with well keratinized healthy oral mucosa. Lateral throat form was Neil's Class-I.<sup>8</sup>

### Case 2

A 55-year-old edentulous female patient reported with a chief complaint of missing teeth which she wanted to get replaced for the purpose of mastication. The medical history of the patient revealed the occurrence of facial paralysis after surgical removal of a parotid tumor on the right side. She was undergoing radiotherapy for which all the teeth had been removed. On extraoral examination asymmetry of the face, deviation of the mouth, drooling of saliva and positive Bell's sign were noticed. A conspicuous mandibular shift toward the left side was observed along with slurred speech. She couldn't perform tapping movement of mandible when instructed. The patient presented with reduced neuromuscular control on jaw closure and phonation as classified by House and Brackmann as Grade V – Severe dysfunction.<sup>7</sup> Intraoral examination showed well-rounded maxillary edentulous ridge covered with firm mucosa. The palatal vault was U-shaped with House's Class-I hard and soft palate relation and Class-I posterior palatal seal area. The mandibular edentulous ridge was well rounded posteriorly and anteriorly with well keratinized healthy oral mucosa. Lateral throat form was Neil's Class-I.<sup>8</sup>

Preliminary impressions were made using impression compound (DPI Pinnacle impression compound, DPI, Mumbai). Custom impression trays were fabricated on the preliminary casts obtained using auto-polymerizing polymethylmethacrylate resin (DPI-RR, DPI, Mumbai). Spacers were adapted over both the casts using Rudd and Morrow design.<sup>9</sup> Border molding was done using low fusing green stick impression compound (DPI Pinnacle tracing sticks, DPI, Mumbai) and final wash impression was made with zinc-oxide eugenol paste (DPI Impression paste, DPI, Mumbai). The patients had difficulty in tongue movements which was then done manually by the operator.

The orientation jaw relation was recorded using face bow (Figure 3) and the maxillary casts were secured on the semi-adjustable articulator (Hanau™ Wide-View Arcon Articulator, Whipmix Corporation). The most difficult step in jaw relation as expected was to determine the occlusal vertical dimension due to non-repeatability of the path of closure and bite position on the bite plane. The step was accomplished by supporting the mandible and establishing the vertical and horizontal jaw relations. Artificial teeth (Premadent, Delhi) were arranged following the lingualized theory of occlusion.<sup>10,11</sup> After completing the anterior and posterior try-in based on the patient's esthetics, phonetics and function, the complete dentures were processed. Laboratory remounting was done and occlusal interferences were eliminated. The posterior teeth on both the sides of mandibular denture were removed and flat occlusal tables were made using self-cure clear acrylic resin

(DPI-RR Cold Cure Clear, DPI, Mumbai). Maxillary palatal cusp markings were obtained on the mandibular occlusal table before complete curing of the resin, ensuring even contacts of all the palatal cusps (Figures 4 and 5). The surface of the clear acrylic resin occlusal table is made as flat as possible.<sup>12,13</sup>

The interim dentures were inserted and post insertion instructions were given.<sup>14</sup> They were recalled the following day to check for the sore spots and were then recalled every week for the occlusal adjustments and to observe the tapping movements of maxillary teeth on the occlusal table. Occlusal adjustments, i.e., removal of any premature contacts were done in every subsequent appointment.

We observed their tapping frequency 4-6 times at every visit, but just to keep the action purely voluntary we did not regulate the parameters like mouth opening, intensity or the frequency. For almost a period of 2 weeks, the patients complained of unstable denture and oral ulcers. Constant reassurance to the patients regarding their ability to perform better mastication in few more weeks was made. In the meantime they could only

perform tapping continuously for 2-14 times. After 5 weeks, the patients had no complaints of denture instability and oral ulcers. They had also remarkably increased their tapping frequency to maximum of 28 times. After 8 weeks, the patients were free of complaints of pain, ulcer or difficulty in chewing rather and were able to perform tapping movement up to 40 times as and when instructed (Table 1). We could also see more clearly the indentations made by maxillary palatal cusps over the flat occlusal table. At this stage, we registered the bite with silicone bite registration material (Imprint™ Bite, 3M ESPE, Germany). The interim dentures were remounted on the semi-adjustable articulator and the clear acrylic occlusal table was reduced. Mandibular posterior artificial teeth were arranged and the definitive denture was processed and inserted (Figure 6). The regular alveolar mucosal massage was advised to maintain the supporting tissues in a state of good health.<sup>15</sup> The patients were extremely satisfied with their denture aesthetics and were able to chew satisfactorily.

**Discussion**

The poor neuromuscular control is considered to be the main reason for the poor voluntary movements of the mandible. Edentulous patients are unable to perform satisfactory mandibular functional movements as they receive very limited

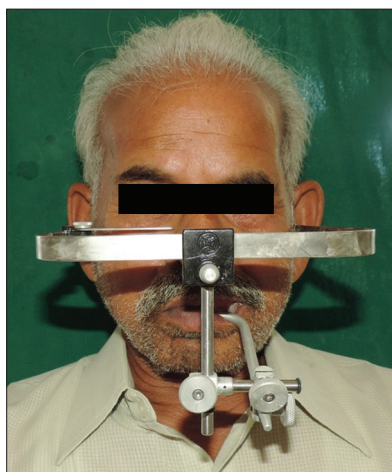

Figure 3: Facebow transfer.

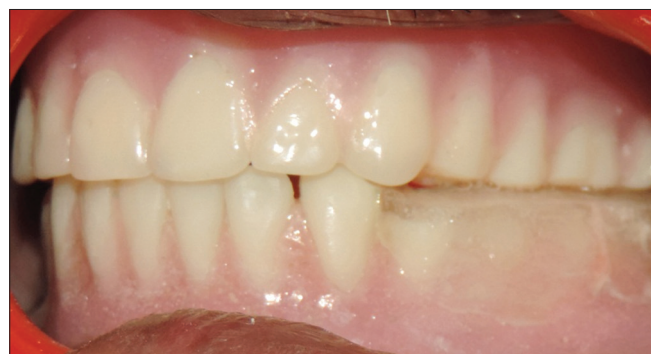

Figure 5: Maxillary palatal cusps contacting the occlusal table.

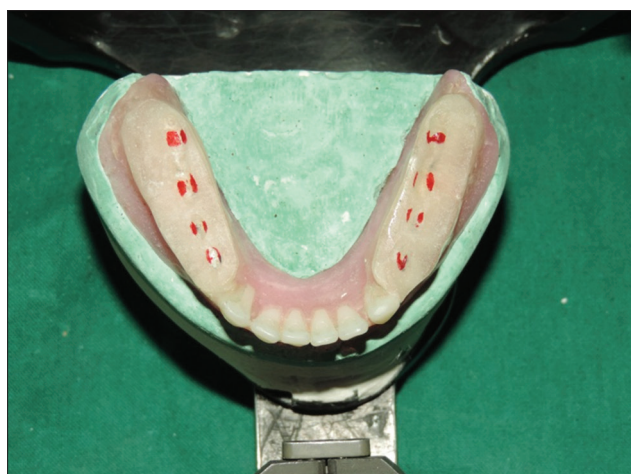

Figure 4: Indentation marks on flat occlusal table of mandibular denture.

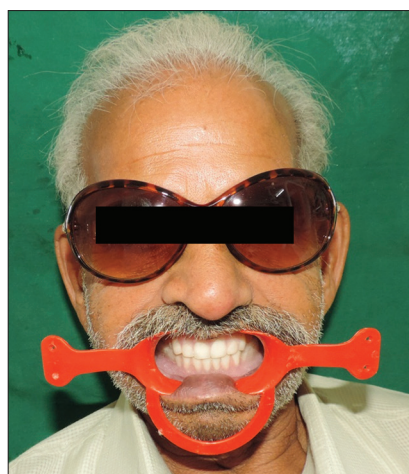

Figure 6: Post-treatment view: Insertion of definitive complete dentures.

Table 1: The progressive increase in maximum and a minimum number of tapping movements performed by the patients at the weekly recall visits.

Cases	1 <sup>st</sup> week (n=5)	2 <sup>nd</sup> week (n=4)	3 <sup>rd</sup> week (n=6)	4 <sup>th</sup> week (n=5)	5 <sup>th</sup> week (n=4)	6 <sup>th</sup> week (n=5)	7 <sup>th</sup> week (n=6)	8 <sup>th</sup> week (n=3)
Case 1								
Max	4	6	14	20	24	28	33	40
Min	1	3	8	14	17	21	27	34
Case 2								
Max	2	4	10	15	18	22	28	38
Min	1	2	6	12	12	18	22	30

n: Trial numbers

input signals and proprioception from muscle fibers.<sup>2,3</sup> In our experience the patients presented uncoordinated mandibular movements. We modified the conventional method of complete denture fabrication and planned a systematic approach to improving the mandibular movements and then go ahead with complete denture fabrication. We used flat occlusal tables to analyze the occlusion; ideally the flat tables should have been elastic and soft though we used auto-polymerizing self-cure acrylic resin as it is simple and easy to manipulate. Our main aim was to achieve single centric spots of the maxillary palatal cusps on the mandibular occlusal table. After 8 weeks our patients could satisfactorily perform the tapping in exact point where the palatal cusps of maxillary teeth contacted the indentations on the flat tables. Thus, we could conclude that our patients mandibular movements were stable. The tapping movement is influenced by frequency, attitude, intensity and the mouth opening of the patient. Any physical and mental stress given to patient affects the tapping movement hence we did not advocate any restraints and permitted voluntary exercise by the patients.<sup>12,13</sup> We used lingualized theory of occlusion as studies have shown that it has got better masticatory efficiency and prevents lateral movements of dentures.<sup>10,11</sup>

The four main requirements that have to be met before insertion of definitive denture are that the patient should not have any pain, the marks of indentations should clearly be seen, the previous interim denture should be stable in the patient's oral cavity and finally all the mandibular movements performed by the patient should be smooth. When all these criteria's were met by our patients we planned fabricating the final definitive complete denture from the interim dentures by asking the patients to bite on a bite registration material to exactly replicate the indentations in definitive prosthesis.<sup>13</sup>

The patients were satisfied by their ability to chew food and also that their concern of esthetic appeal of the face was also solved. The flat occlusal table used to analyze the occlusion and also to perform the tapping movement was effective for rehabilitation of Bell's palsy patient who had very irregular and erratic mandibular movements.

Based on our experience we recommend a systematic stepwise approach for the fabrication of interim dentures for neuromuscular training ensuring predictable mandibular

movements before the fabrication of final dentures, as the process familiarizes the patients to the concept of mastication using dentures and improves their acceptability with less chances of rejection.

### References

1. Worthington HV, Glenny AM, Mauleffinch LF, Daly F, Clarkson J. Using Cochrane reviews for oral diseases. *Oral Dis* 2010;16(7):592-6.
2. Malik NA. Facial nerve and motor disturbances of the face and jaws. In: Malik NA, (Editor). *Text Book of Oral and Maxillofacial Surgery*, 2<sup>nd</sup> ed. New Delhi: Jaypee Brothers Medical Publishers; 2008. p. 719-21.
3. Slavkin HC The significance of a human smile: Observations on Bell's palsy. *J Am Dent Assoc* 1999;130(2):269-72.
4. Numthavaj P, Thakkinstian A, Dejthevaporn C, Attia J. Corticosteroid and antiviral therapy for Bell's palsy: A network meta-analysis. *BMC Neurol* 2011;11:1.
5. Terzis JK, Konofaos P. Nerve transfers in facial palsy. *Facial Plast Surg* 2008;24(2):177-93.
6. Hussain S, Jayesh R, Nayar S, Aruna U, Abraham AM. Prosthodontic management of a completely edentulous patient with Bell's palsy. *Indian J Multidiscip Dent* 2011;2(1):404-6.
7. House JW, Brackmann DE. Facial nerve grading system. *Otolaryngol Head Neck Surg* 1985;93(2):146-7.
8. Engelmeier RL. Complete-denture esthetics. *Dent Clin North Am* 1996;40(1):71-84.
9. Shetty S, Ratna Nag PV, Shenoy K. The selective pressure maxillary impression: A review of the techniques and presentation of an alternate custom tray design. *JIPS* 2007;7(1):8-11.
10. Becker CM, Swoop CC, Guckes AD. Lingualized occlusion for removable prosthodontics. *J Prosthet Dent* 1977;38(6):601-8.
11. Heydecke G, Akkad AS, Wxolkewitz M, Vogeler M, Turp JC, Strub JR. Patient ratings of chewing ability from a randomised crossover trial: Lingualised vs. first premolar/canine-guided occlusion for complete dentures. *Gerodontology* 2007;24:77-86.
12. Inada M, Yamazaki T, Shinozuka O, Sekiguchi G, Tamamori Y, Ohyama T. Complete denture treatments for a cerebral palsy patient by using a treatment denture. A case report. *J Med Dent Sci* 2002;49(2):171-7.
13. Abe J. Clinical mandibular position of edentulous

- patient - The utility and clinical methods of treatment denture. *Nippon Dent Rev* 2001;61:109-16.
14. Felton D, Cooper L, Duqum I, Minsley G, Guckes A, Haug S, *et al*. Evidence-based guidelines for the care and maintenance of complete dentures: A publication of the American College of Prosthodontists. *J Prosthodont* 2011;20 Suppl 1:S1-S12.
15. Pandey S, Datta K. Prosthodontic management of a completely edentulous patient with unilateral facial paralysis. *J Indian Prosthodontic Soc* 2007;7:211-2.