

OPEN

Glaucoma After Corneal Trauma or Surgery—A Rapid, Inflammatory, IOP-Independent Pathway

Claes H. Dohlman, MD, PhD, Chengxin Zhou, PhD, Fengyang Lei, MD, PhD, Fabiano Cade, MD, PhD, Caio V. Regatieri, MD, PhD, Alja Črnež, MD, Jan G. Dohlman, MD, Lucy Q. Shen, MD, and Eleftherios I. Paschalis, PhD

Purpose: To review clinical aspects and cellular and molecular steps in the development of long-term glaucoma after corneal surgery or acute trauma—especially the pivotal role of tumor necrosis factor alpha (TNF- α), the rapidity of the secondary damage to the retinal ganglion cells, and the clinical promise of early antiinflammatory intervention.

Methods: A series of laboratory studies on post-injury and post-surgery glaucoma have been compared to clinical outcome studies on the subject, focusing particularly on the vulnerability of the retinal ganglion cells. Alkali burn to the cornea of mice and rabbits served as the main experimental model. TNF- α titer, ganglion cell apoptosis, and depletion of optic nerve axons have been examined. Anti-TNF- α antibodies or corticosteroids have been used to protect the retinal ganglion cells. Intraocular pressure (IOP) postburn was recorded by manometric methods.

Results: In animals with alkali burn to the cornea, damage to the retina can occur within 24 to 72 hours. This is not because of a direct pH change posteriorly—the alkali is effectively buffered at the iris–lens level. Rather, TNF- α (and other inflammatory cytokines), generated anteriorly, rapidly diffuses posteriorly to cause apoptosis of the ganglion cells. During this time, the IOP remains much lower than the reported values required to cause ganglion cell damage. The TNF- α antibody infliximab or corticosteroids, if administered promptly, are markedly protective of the ganglion cells.

Conclusions: A rapidly initiated, inflammatory (TNF- α mediated), IOP-independent pathway to glaucoma, resulting from acute anterior segment trauma or surgery, has been identified in laboratory studies. Prompt prophylactic treatment with antiinflammatory agents has been shown to be markedly neuroprotective of retinal ganglion cells, presumably capable of reducing the risk of late glaucoma.

Key Words: corneal trauma, surgery, inflammation, glaucoma

(*Cornea* 2019;38:1589–1594)

Glaucoma is a frequent and often severe long-term complication after corneal surgery, infection, or trauma—well documented in an extensive literature. Almost invariably, postevent elevated intraocular pressure (IOP) has been considered the cause. However, in many instances, the IOP is poorly documented in the articles or is registered as quite modest in magnitude. In a number of cases, IOP has been normal or low, still resulting in progressive visual field loss and blindness. Beyond lowering the IOP in any type of glaucoma, there is clearly a need for additional neuroprotection.¹

We have been confronted with the complication of glaucoma because of our interest in artificial corneas.^{2–4} After marked improvements in postoperative management and also in design during the past 2 decades, such devices can give great vision in the short and intermediate terms, if the rest of the eye allows, but severe glaucoma can still in the long run be the most significant complication^{5–15} (Fig. 1). In addition, most eyes undergoing keratoprosthesis (KPro) surgery do already have glaucoma—undoubtedly reflecting the inflammatory or surgical history of these eyes. This fact has been illustrated in a study on 106 consecutive Boston KPro patients with various severe corneal etiologies¹⁰ (Fig. 2). Cup-to-disc ratios were recorded, and the analysis showed that about two-thirds of these patients had glaucoma already preoperatively, and many progressed after the KPro surgery. In addition, glaucoma de novo was not uncommon. Less than 10% of the eyes remained free of glaucoma after 4 years. Based on the original etiology of corneal opacification, patients with chemical burn had the worst glaucoma outcome. However, lowering the IOP by using a valve drainage device usually proved effective in slowing the process.¹⁰

These clinical findings inspired a series of laboratory studies on mice and rabbits,^{16–23} where alkali burn of the

Received for publication April 12, 2019; revision received June 25, 2019; accepted June 25, 2019. Published online ahead of print August 23, 2019.

From the Cornea Service, Glaucoma Service and Boston Keratoprosthesis Laboratory, Massachusetts Eye and Ear and Schepens Eye Research Institute, Harvard Medical School, Boston, MA.

Supported by the Boston Keratoprosthesis Fund, Massachusetts Eye and Ear, Boston, MA.

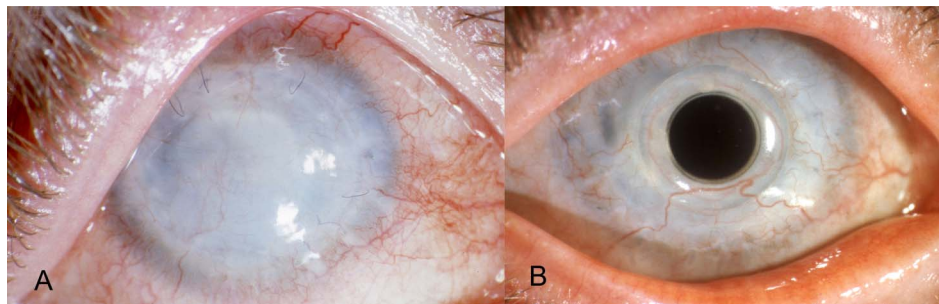
C. H. Dohlman, C. Zhou, F. Lei, F. Cade, C. V. Regatieri, A. Črnež, L. Q. Shen, and E. I. Paschalis have been full-time employed by Massachusetts Eye and Ear, the manufacturer of the Boston keratoprosthesis. The remaining author has no conflicts of interest to disclose.

For this review, no new human or animal studies were performed requiring further ethical approval.

Correspondence: Claes H. Dohlman, MD, PhD, Massachusetts Eye and Ear, 243 Charles St, Boston, MA 02114 (e-mail: claes_dohlman@meei.harvard.edu).

Copyright © 2019 The Author(s). Published by Wolters Kluwer Health, Inc. This is an open-access article distributed under the terms of the Creative Commons Attribution-Non Commercial-No Derivatives License 4.0 (CCBY-NC-ND), where it is permissible to download and share the work provided it is properly cited. The work cannot be changed in any way or used commercially without permission from the journal.

FIGURE 1. An example of keratoprosthesis as a rescue procedure after multiple keratoplasty failures. A, Status after 4 failed grafts for keratoconus, the last one was complicated by fungal keratitis/endophthalmitis and glaucoma. B, Keratoprosthesis, with a follow-up of 17 years. Vision is still 20/20—but with advanced glaucoma.



cornea was used as a model. Not only did the expected cornea damage occur but also rapid subclinical injury to the retina^{16–23}(Fig. 3). With TUNEL stain, substantial apoptosis of the ganglion cells (the hallmark of glaucoma) was demonstrated within 24 to 72 hours. In addition, the depletion of the number of optic nerve axons was recorded after 3 months. These studies helped to understand the importance of inflammation, and its rapid onset, in this glaucomatous neurodegeneration.

Thus, insult to the cornea can result in a very rapid and widespread damage to the retina (Figs. 3 and 4). In chemical burns, the retina injury does not result from a direct pH affect—alkali is effectively buffered at the iris–lens level, as measured with pH probes.^{16,19} Rather, the inflammatory cytokine tumor necrosis factor alpha (TNF- α) is generated in the anterior segment and rapidly (within hours) diffuses posteriorly to cause the ganglion cell apoptosis^{16–21}—presumably capable of resulting in later glaucoma. TNF- α was shown to cause permanent changes in the immune function of the retina, termed “permanent neuroglia remodeling,” which continued to cause neuronal degeneration even long after the noxious stimuli were removed and the TNF- α production in the anterior segment had subsided. This immunological shift

was demonstrated to occur not only in burns but also after ocular hypertension and cornea surgical trauma, indicating the role of inflammation and TNF- α in long-term retinal health.^{22,23}

How do we know that TNF- α is a mediator in the process of ganglion cell apoptosis? We showed that infliximab (antibody to TNF- α), infused over 60 minutes starting 15 minutes after the burn, had a strong protective effect against the apoptosis^{16–19} (Fig. 4) and ameliorated the process of neuroglia remodeling.²³ These findings may open new prophylactic treatment possibilities.²⁶

Thus (in animals), the TNF- α can promptly destroy a substantial portion of the retinal ganglion cells. Is that enough to cause functional loss in patients? It likely is, because it is already well-established that in humans and primates, a 20% to 40% ganglion cell loss results in visual field defects.^{24,25}

These results from the laboratory, combined with clinical experience, prompted a reevaluation of the treatment of our patients with chemical burns.²⁶ It is well known that penetrating keratoplasty (PK) after severe burns have a virtually hopeless visual prognosis,²⁷ whereas KPros usually do well surgically.^{7,28} Late glaucoma is the problem. Therefore, because the above-cited experience from animals

FIGURE 2. Glaucoma prevalence in eyes with keratoprosthesis, preoperative and postoperative status. A cohort of 106 consecutive patient eyes with severe corneal damage which had keratoprosthesis implanted was analyzed for cup-to-disc (C/D) ratio of the optic nerve head. Seventy eyes had a preoperative diagnosis of glaucoma at the time of surgery (green line), and as a group, they worsened despite treatment. Twenty-seven eyes, with normal optic nerve appearance immediately after surgery, developed cupping with time (blue line). Only in 9 eyes did the optic nerve remain totally normal—with 4 years of follow-up (red line). However, a valved drainage device proved effective in retarding glaucoma. Reprinted with permission from Črnež, Pašchalis, Salvador-Culla, Tauber, et al., *Cornea* 2014¹⁰.

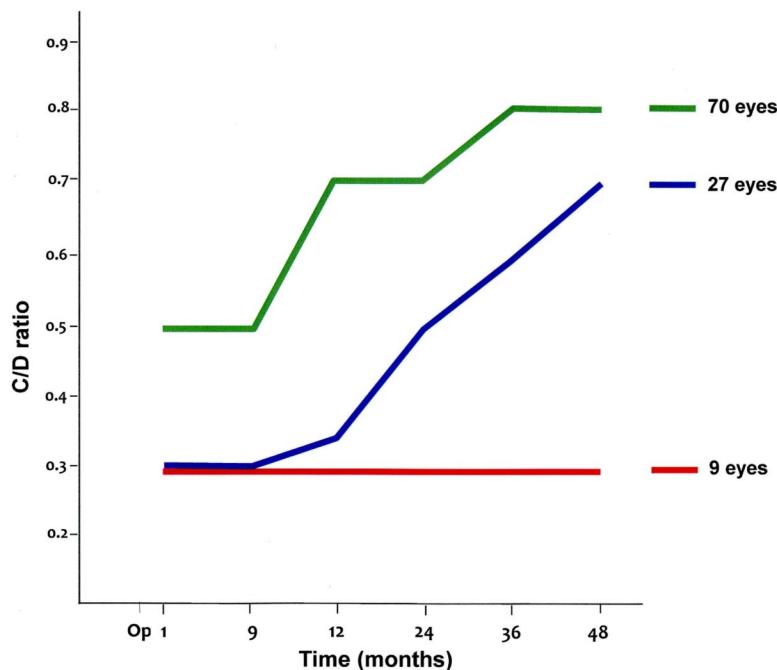
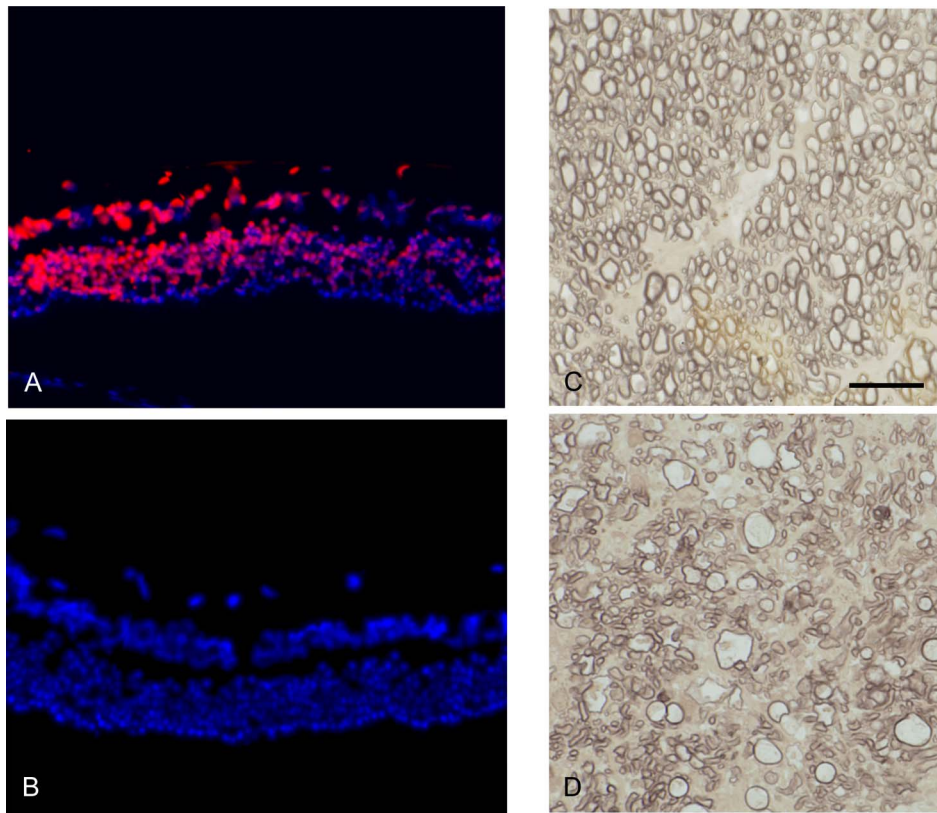


FIGURE 3. Injury to the cornea can rapidly result in damage to the retina (sometimes patchy), including the ganglion cells. After alkali burn to the cornea of mice or rabbits, the retinas were subjected to TUNEL stain for cellular apoptosis. The left panel shows the retinal stain in rabbits 72 hours after exposure, without (A) and with (B) infliximab administration promptly postburn—while the IOP remained essentially normal. The right panel shows a normal optic nerve (C) compared with a nerve 3 months after a corneal burn (D), indicating permanent loss of the axons. Original earlier experiments in mice had given similar results. Reprinted from Zhou, Robert, Kapoulea, et al., *Invest Ophthalmol Vis Sci* 2017.²¹ © The Author(s). This work is licensed under a Creative Commons Attribution-NonCommercial-NoDerivatives 4.0 International License, under which the material may be copied and redistributed in any medium or format.



points to a very rapid (hours or days) destruction of ganglion cells after a burn, it seems logical to start strong anti-inflammatory prophylaxis in patients promptly after the accident.^{26,30} Both corticosteroids and antibodies to TNF- α show rapid and effective neuroprotection of ganglion cells in animals,¹⁹ but biologics are well documented to be considerably safer in long-term treatment (eg, in rheumatology) and are used successfully in uveitis.²⁹ A modified treatment paradigm for patients with chemical burn might start promptly in the emergency department (in addition to standard treatment such as lavage, etc.) with the local administration of triamcinolone (Kenalog), injected sub-Tenon or subconjunctivally. The initial choice of a corticosteroid allows a tuberculosis test to be performed, and the results returned before considering biologics—which presently can take 24 hours. When tuberculosis has been proven absent in the patient, a biologic such as adalimumab (Humira) subcutaneously, or infliximab (Remicade) intravenously, might be a logical drug for long-term continuation.³⁰ Doses, routes of administration, duration of treatment, and the effect of recently introduced new cytokine inhibitors are presently under investigation.

In the burn patients, prophylaxis against later IOP-associated glaucoma from outflow obstruction—often starting in the healing and scarring phase—should be considered as well. Thus, prompt institution of a carbonic anhydrase inhibitor (drops can be unreliable, irritating, after burn) is recommended to bring the IOP to the lowest safe level and maintain it there for months. Finally, after 3 to 6 months,

when the intraocular inflammation has subsided, a KPro is usually indicated.³⁰

If a major ocular trauma such as a chemical burn to the cornea can have immediate dire consequences for the retinal ganglion cells—with expected glaucomatous optic neuropathy as a consequence—is there a need of prophylactic treatment even after standard corneal surgery such as PK, where glaucoma is also very common postoperatively?^{31–34} Close to 200,000 PKs are presently being performed annually worldwide, and a reduction of the incidence of postoperative glaucoma could result in a major improvement of ocular public health. To investigate this question further in the laboratory, mice were implanted with miniature corneal grafts or with miniature KPros into their previously untouched, normal corneas.¹⁸ As was suspected, also such a penetrating surgery triggers rapid upregulation of TNF- α in the retina, as well as ganglion cell apoptosis, although of less magnitude than in the alkali burn model used earlier (Fig. 5). Even a short penetrating injury in a mouse cornea can release potentially injurious levels of inflammatory cytokines.³⁵ The fact that glaucoma is such a long-term problem postoperatively after PK and after KPro, in patients, speaks for likely future routine local administration of a powerful antiinflammatory drug (steroid or biologic) at the end of any surgical procedure—similar to what is recommended after chemical burns. The route of local administration can be subconjunctival, sub-Tenon or, less likely, intravitreal. Postoperative antiinflammatory drops to the surface of the eye, or released from a subconjunctival

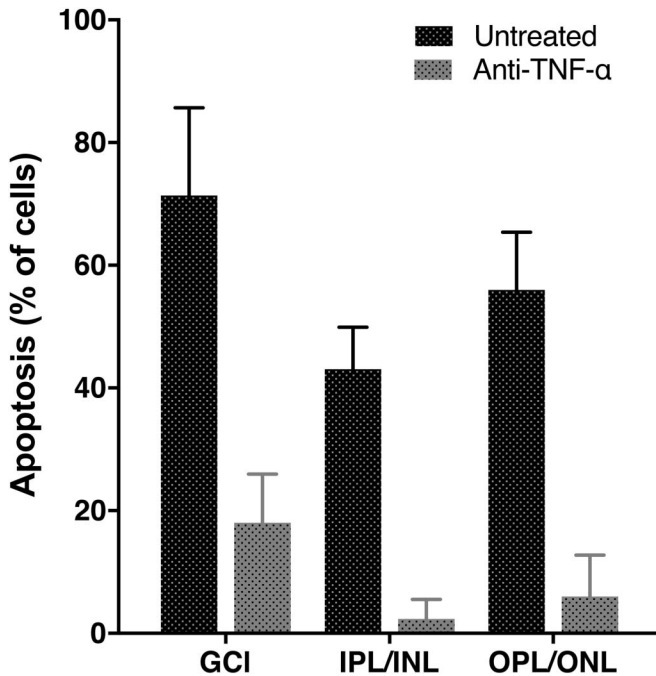


FIGURE 4. Further experiments on mice with alkali-burned corneas showed that other retinal layers can be affected by apoptosis and that infliximab can have a profound protective effect on them as well. This graph illustrates the situation 24 hours postburn, indicating the percentage of apoptosis. Black bar: untreated mice. Gray bar: treated with the anti-TNF- α antibody infliximab. GCL, ganglion cell layer; IPL, inner plexiform layer; INL, inner nuclear layer; OPL, outer plexiform layer; ONL, outer nuclear layer. © Wolters Kluwer Health 2017. Reproduced with permission from Wolters Kluwer Health from Paschalis, Zhou, Lei, et al., *Am J Pathol* 2017¹⁰.

drug-eluting device,²⁰ or from a contact lens (Ciolino, unpublished), may have some effect also at the retinal level, but the necessary dosing is not yet known, nor the tradeoffs regarding complications from the steroids.

Because inflammation-induced ganglion cell apoptosis is triggered very rapidly after corneal surgery or trauma, most likely within hours, and seems to result in glaucoma manifestation often long afterward, how long should anti-inflammatory prophylaxis be continued? A recent study on KPro patients revealed that systemic TNF- α /TNF-receptor 2 levels in blood can remain elevated for years after the surgery.³⁶ The full relevance of this finding is not yet known, but it suggests ongoing chronic low-grade inflammation in eyes with a KPro. One might be able to use TNF- α in blood as an inflammatory marker and indication for treatment. Possibly, a locally or systemically administered biologic will be proven necessary for a long time after the surgery or after any major traumatic event to the eye. Unfortunately, the high cost of these biologics is presently a barrier to extensive human application. Less expensive immunomodulators such as methotrexate or azathioprine are yet to be tested.

From a more global perspective of the pathophysiology of glaucoma, can we exclude the IOP as a link to the

ganglion cell damage during the first few days after the traumatic event? In our animal experiments, the IOP remained normal before burn and 24 hours later (Fig. 6), but what about the possibility of a severe peak between the 2 time points? Some additional experiments were therefore performed in mice and rabbits (unpublished, but with approved protocols). An IOP spike was indeed recorded in rabbits with a fleeting maximum of 45 mm Hg, and remained above 30 mm Hg for a total of only 45 minutes. Afterward, the IOP fell to normal values. In mice, the pressures were normal after 1 and 4 hours. This pattern should be compared with what is known in the literature about the levels of IOP required to cause ganglion cell damage. Thus, in one study, a continuous pressure of 45 mm Hg for at least 7 hours daily, for several days, was necessary to initiate ganglion cell attrition.³⁷ Therefore, it seems extremely unlikely that the IOP during the first few postevent days in our animals—when retinal apoptosis occurs—will have played any pathophysiological role.

The clinical literature correlated with the laboratory studies cited in this brief review seems to indicate the existence of a rapid, inflammatory, IOP-independent pathway to glaucoma—susceptible to effective inhibition by antibodies (Fig. 7). TNF- α has already been shown experimentally to be a mediator between high IOP and ganglion cell apoptosis.^{38,39} However, in our animal experiments, ganglion cell attrition was clearly triggered by the postburn inflammation, not by the IOP—the latter remaining in a harmless range within 1 to 3 days after the exposure (depending on the animal) when severe damage to the ganglion cells had already occurred¹⁹ (Fig. 6). In addition,

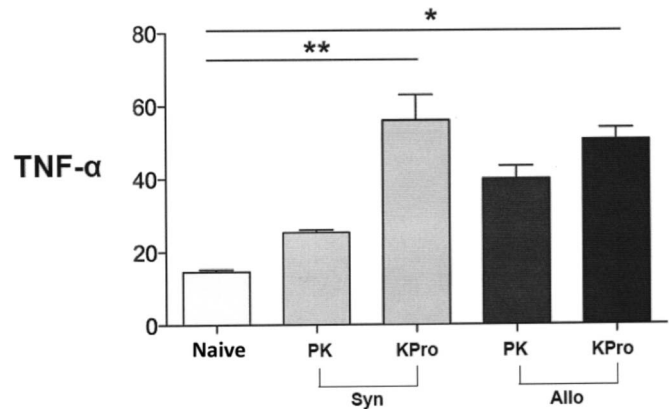


FIGURE 5. TNF- α in the retina of mice 8 weeks after PK or miniature Boston keratoprosthesis (KPro), using allogeneic (Allo) or syngeneic (Syn) carrier corneal grafts implanted into normal corneas. The IOP, measured by direct manometry, was normal at the time of euthanasia. TNF- α is expressed as copies per 10⁶ copies of glyceraldehyde 3-phosphate dehydrogenase. A significant increase was seen in the Syn KPro and Allo KPro groups. * $P = 0.05$; ** $P < 0.05$. Reproduced from Črnež, Omoto, Dohlman, et al. *Invest Ophthalmol Vis Sci*. 2016¹⁸. © The Author(s). This work is licensed under a Creative Commons Attribution-NonCommercial-NoDerivatives 4.0 International License, under which the material may be copied and redistributed in any medium or format.

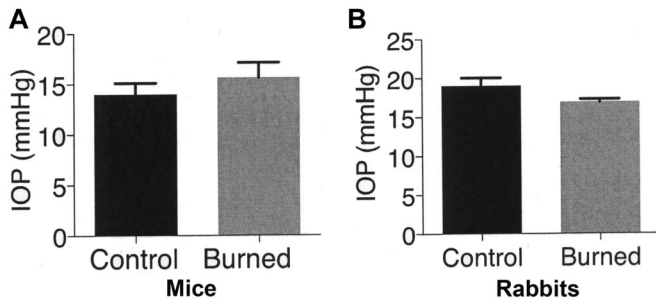


FIGURE 6. Intraocular pressure measured manometrically, before and 24 hours after alkali burn in mice (n = 17) and rabbits (n = 3). No significant changes were recorded. To exclude possible pressure spikes between the 2 end points in time, recent additional experiments with frequent recordings showed a brief peak immediately after burn, too insignificant to be expected to cause glaucomatous damage. © Wolters Kluwer Health 2017. Reprinted with permission from Wolters Kluwer Health from Paschalis, Zhou, Lei, et al., *Am J Pathol* 2017¹⁹.

autoimmune inflammation has lately been shown to affect the optic nerve and result in neuropathy.⁴⁰ Thus, arguments for an IOP-independent pathway to glaucoma can be formulated as follows:

1. In patients, it is well known and documented that corneal surgery or trauma is often later complicated by glaucoma.
2. In animals, an alkali burn to the cornea triggers rapid (within hours) upregulation of TNF- α in the anterior segment.
3. Within 24 to 72 hours, in mice or rabbits, the TNF- α level becomes elevated in the retina as well and the

ganglion cells can show substantial apoptosis. A high percentage of the cells can become affected in our models.

4. During that time (up to 72 hours), IOP remains normal or fleetingly elevated and is expected to be harmless.
5. Antibodies to TNF- α , administered shortly after an alkali burn, are strongly neuroprotective, corroborating that TNF- α can be a prominent mediator in the destruction of the ganglion cells.
6. Finally, these results should be interpreted against the background that already a modest attrition of approximately 30% of ganglion cells results in visual field loss—well documented in humans (Fig. 7).

Thus, an acute traumatic event to the eye (corneal surgery, accidental trauma, etc.) seems to be able to, through an inflammatory pathway, very rapidly cause irreversible damage to retinal ganglion cells and most likely later result in glaucoma, while the IOP is still essentially normal. Later, when the injured eye begins to heal with inflammation, scarring, and trabecular meshwork damage, with frequent chronic IOP elevation as a result, the molecular mechanisms involved in the glaucomatous damage may be different and more difficult to control. Likewise, whether our models will be able to elucidate the mechanism of chronic normal-tension glaucoma is uncertain. In practical terms, however, these new insights point to needed changes in the management after corneal surgery or trauma. Substantially more antiinflammatory medication is warranted, immediately as well as sustained, as prophylaxis against long-term glaucoma. The balance between biologics, other immunomodulators, and corticosteroids for such treatment will have to be defined and calibrated further.

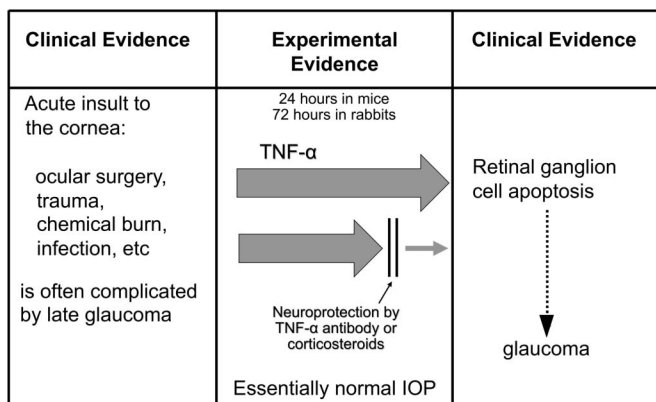


FIGURE 7. Clinical and experimental evidence supporting the concept of a rapid, inflammatory, IOP-independent pathway to glaucoma after an acute trauma or ocular surgery. TNF- α is rapidly upregulated in the anterior segment and, within hours, diffuses posteriorly to the retina where it causes ganglion cell apoptosis—which is known to result in glaucomatous optic neuropathy. Treatment with TNF- α antibody, or corticosteroids, can block this process and be strongly neuroprotective. The IOP remains essentially normal during the time it takes for severe damage to the ganglion cells to occur.

REFERENCES

1. Almasieh M, Levin LA. Neuroprotection in glaucoma: animal models and clinical trials. *Annu Rev Vis Sci.* 2017;3:91–120.
2. Dohlman CH, Schneider H, Doane MG. Prosthokeratoplasty. *Am J Ophthalmol.* 1974;77:694–700.
3. Dohlman JG, Foster CS, Dohlman CH. Boston keratoprosthesis in Stevens-Johnson syndrome: a case of using infliximab to prevent tissue necrosis. *Dig J Ophthalmol.* 2009;15:1–5.
4. Dohlman CH, Cruzat A, White M. The Boston Keratoprosthesis 2014—a step in the evolution of artificial corneas. *Spektr Augenheilkd.* 2014;28:226–233.
5. Netland PA, Terada H, Dohlman CH. Glaucoma associated with keratoprosthesis. *Ophthalmology.* 1998;105:751–757.
6. Harissi-Dagher M, Dohlman CH. The Boston keratoprosthesis in severe ocular trauma. *Can J Ophthalmol.* 2008;43:165–169.
7. Cade F, Grosskreutz CL, Tauber A, et al. The role of glaucoma after Boston keratoprosthesis in severe chemical burns. *Cornea.* 2011;80:1322–1327.
8. Kanyar R, Weizer JS, de Paula FH, et al. Glaucoma associated with Boston type I keratoprosthesis. *Cornea.* 2012;31:134–139.
9. Talajic JC, Agoumi Y, Gagné S, et al. Prevalence, progression, and impact of glaucoma on vision after Boston Type I keratoprosthesis surgery. *Am J Ophthalmol.* 2012;153:267–274.
10. Crnej A, Paschalis EI, Salvador-Culla B, et al. Glaucoma Progression and timing of glaucoma surgery in patients with Boston Keratoprosthesis. *Cornea.* 2014;33:349–354.
11. Lee WB, Shtein RM, Kaufman SC, et al. Boston keratoprosthesis: outcomes and complications: a report by the American Academy of Ophthalmology. *Ophthalmology.* 2015;122:1504–1511.

12. Poon LY, Chodosh J, Vavvas DG, et al. Endoscopic cyclophotocoagulation for the treatment of glaucoma in Boston keratoprosthesis type II patient. *J Glaucoma*. 2017;26:e146–e149.
13. Ali MH, Dikopf MS, Finder AG, et al. Assessment of glaucomatous damage after Boston keratoprosthesis implantation based on digital perimetric quantification of visual fields and optic nerve heading. *Cornea*. 2018;37:602–608.
14. Kamar RS, Tan DT, Por YM, et al. Glaucoma management in patients with osteo-odonto-keratoprosthesis (OOKP). The Singapore OOKP study. *J Glaucoma*. 2009;18:354–360.
15. Iyer G, Srinivasan B, Agarwal B, et al. Glaucoma in modified osteo-odonto-keratoprosthesis eyes: role of additional stage 1A and Ahmed glaucoma drainage device—techniques. *Am J Ophthalmol*. 2015;159:482–489.
16. Cade F, Paschalis EI, Regatieri CV, et al. Alkali burn to the eye: protection using TNF- α inhibition. *Cornea*. 2014;33:382–389.
17. Crnej A, Omoto M, Dohlman TH, et al. Corneal inflammation after miniature keratoprosthesis implantation. *Invest Ophthalmol Vis Sci*. 2014;56:185–189.
18. Crnej A, Omoto M, Dohlman TH, et al. Effect of penetrating keratoplasty and keratoprosthesis implantation on the posterior segment of the eye. An animal study. *Invest Ophthalmol Vis Sci*. 2016;57:1643–1648.
19. Paschalis EI, Zhou C, Lei F, et al. Mechanisms of retinal damage following ocular alkali burns. *Am J Pathol*. 2017;187:1327–1342.
20. Robert MC, Zhou C, Frenette M, et al. A drug delivery system for administration of anti-TNF- α antibody. *Trans Vis Sci Tech*. 2016;5:1–11.
21. Zhou C, Robert MC, Kapoulea V, et al. Sustained subconjunctival delivery of infliximab protects the cornea and retina following alkali burn to the eye. *Invest Ophthalmol Vis Sci*. 2017;58:96–105.
22. Paschalis EI, Lei F, Zhou C, et al. Permanent neuroglial remodeling of the retina following infiltration of CSF1R-inhibition resistant peripheral monocytes. *Proc Nat Acad Sci*. 2018;115:E11359–E11368.
23. Paschalis EI, Lei F, Zhou C, et al. Neuroglial remodeling after various ocular injuries is regulated by microglia. *J Immunol*. 2019;202:539–549.
24. Quigley HA, Dunkelberger GR, Green WR. Retinal ganglion cell atrophy correlated with automated perimetry in human eyes with glaucoma. *Am J Ophthalmol*. 1989;107:453–464.
25. Harwerth RS, Carter-Dawson L, Smith EL III, et al. Neural losses correlated with visual losses in clinical perimetry. *Invest Ophthalmol Vis Sci*. 2004;45:3152–3160.
26. Dohlman CH, Cade F, Regatieri CV, et al. Chemical burns of the eye. The role of retinal injury and new therapeutic possibilities. *Cornea*. 2018;37:248–251.
27. Abel R Jr, Binder PS, Polack FM, et al. The results of penetrating keratoplasty after chemical burn. *Trans Am Acad Ophthalmol Otolaryngol*. 1975;79:584–595.
28. Ciolino JB, Belin MW, Todani A, et al. Boston keratoprosthesis type I study group: multicenter study results. *Ophthalmology*. 2013;120:1195–1200.
29. Levy-Clarke G, Jabs DA, Read RW, et al. Expert panel recommendations for the use of anti-tumor necrosis factor biologic agents in patients with ocular inflammatory disorders. *Ophthalmology*. 2014;121:785–796.
30. Dohlman CH, Robert MC, Paschalis EI. Treatment of chemical burn to the eye. A changing picture. In: Colby K, Dana MR, eds. *Foundations of Corneal Disease*. Denver, CO: Springer, 2019.
31. Al-Mohaimed M, Al Shahwan S, Al-Torbak A, et al. Escalation of glaucoma therapy after penetrating keratoplasty. *Ophthalmology*. 2007;114:2281–2286.
32. Al-Mahmood AM, Al-Swailem SA, Edward DP. Glaucoma and corneal transplant procedures. *J Ophthalmol*. 2012;57:6394.
33. Haddadin RI, Chodosh J. Corneal transplantation and glaucoma. *Semin Ophthalmol*. 2014;29:380–396.
34. Kormmann HL, Gedde SJ. Glaucoma management after corneal transplant surgeries. *Curr Opin Ophthalmol*. 2016;27:132–139.
35. Lei F, Dohlman CH, Chodosh J, et al. Corneal injury causes retinal inflammation. *Invest Ophthalmol Vis Sci*. 2018;59:2529.
36. Paschalis EI, Taniguchi EV, Chodosh J, et al. Blood levels of tumor necrosis factor alpha and its Type 2 receptor are elevated in patients with Boston Type I Keratoprosthesis. *Curr Eye Res*. 2019;42:1–8.
37. Sun H, Wang Y, Pang IH, et al. Protective effect of a JNK inhibitor against retinal ganglion cell loss induced by acute moderate ocular hypertension. *Mol Vis*. 2011;17:867–875.
38. Nakazawa T, Nakazawa C, Matsubara A, et al. Tumor necrosis factor- α mediates oligodendrocyte death and delayed retinal ganglion cell loss in a mouse model of glaucoma. *J Neurosci*. 2006;26:12633–12641.
39. Roh M, Zhang Y, Murakami Y, et al. Etanercept, a widely used inhibitor of tumor necrosis factor- α (TNF- α), prevents retinal ganglion cell loss in a rat model of glaucoma. *PLoS One*. 2012;7:e40065.
40. Chen H, Cho KS, Vu THK, et al. Commensal microflora-induced T-cell responses mediate progressive neurodegeneration in glaucoma. *Nat Commun*. 2018;9:3209.