

# Efficacy of bronchoscopic thermal vapor ablation in patients with heterogeneous emphysema and lobar quantification by three-dimensional ventilation/perfusion single-photon emission computed tomography/computed tomography: a prospective pilot study from China

Wenjun Zhu<sup>1</sup>, Yuchen Zhang<sup>2</sup>, Felix J.F. Herth<sup>3</sup>, Dan Liu<sup>1</sup>, Hui Zhu<sup>1</sup>, Jingyu Shi<sup>1</sup>, Chujie Zhang<sup>1,2</sup>, Gongshun Tang<sup>4</sup>, Fengming Luo<sup>1,2</sup>

<sup>1</sup>Department of Respiratory and Critical Care Medicine, West China Hospital, Sichuan University, Chengdu, Sichuan 610041, China;

<sup>2</sup>Laboratory of Pulmonary Immunology and Inflammation, Frontiers Science Center for Disease-Related Molecular Network, West China Hospital, Sichuan University, Chengdu, Sichuan 610041, China;

<sup>3</sup>Department of Pneumology and Critical Care Medicine, Thoraxklinik University of Heidelberg, Heidelberg, Germany;

<sup>4</sup>Department of Nuclear Medicine, West China Hospital, Sichuan University, Chengdu, Sichuan 610041, China.

Chronic obstructive pulmonary disease (COPD) is characterized by emphysema and airflow limitation and is one of the leading causes of morbidity and mortality worldwide. Endoscopic lung volume reduction (ELVR) is a minimally invasive technique for patients with severe hyperinflation and advanced emphysema. To date, the most investigated form of ELVR is valve implantation, which is to place valves in all the segments of an emphysematous lobe. However, valve replacements do not achieve adequate lung volume reduction in the presence of interlobar collateral ventilation (CV).<sup>[1]</sup> In addition, with the heterogeneity existing within the treatment lobe, complete lobar treatment from implants may result in excessive reduction of the less diseased segments. Thus, a more targeted approach of the most severe emphysematous parts of the lobe is warranted.

Bronchoscopic thermal vapor ablation (BTVA) is an ELVR technique, which reduces the volume of emphysematous segments by inducing a local inflammatory response to water vapor. This is beneficial for patients with severe upper lobe-predominant heterogeneous emphysema, irrespective of interlobar CV.<sup>[2]</sup> The efficacy of BTVA has been evaluated mostly in western countries and has been demonstrated as a clinically significant tool for improving pulmonary function and exercise capacities.<sup>[3]</sup> However,

the efficacy of this novel treatment strategy in Asian population remains undetermined.

Ventilation/perfusion single-photon emission computed tomography/computed tomography (V/Q SPECT/CT) can quantitatively estimate regional pulmonary function. Three-dimensional (3D) V/Q SPECT/CT offers a simultaneous and reproducible method of lobar quantification of lung volume and ventilation and contributes to the eligibility assessment for ELVR, identification of target lobes, and estimation of regional effects after interventions.<sup>[4]</sup> However, the ventilation, perfusion, and V/Q changes of the targeted and nontargeted zones post-BTVA in a clinical setting has not yet been investigated.

We, therefore, conducted this prospective pilot study to determine the efficacy of BTVA on COPD patients with upper lobe-predominant emphysema in China and evaluate the feasibility of lobar quantification using 3D V/Q SPECT/CT.

This is a single-center, prospective, non-randomized, concurrent controlled, pilot study approved by the Institutional Review Board of West China Hospital, Sichuan University (Ethical approval No. 2019533). Written informed consent was provided prior to partici-

Wenjun Zhu and Yuchen Zhang contributed equally to this work.

**Correspondence to:** Gongshun Tang, Department of Nuclear Medicine, West China Hospital, Sichuan University, Chengdu, Sichuan 610041, China  
E-Mail: tgs010@163.com;  
Fengming Luo, Department of Pulmonary and Critical Care Medicine, West China Hospital, Sichuan University, Chengdu, Sichuan 610041, China  
E-Mail: fengmingluo@outlook.com

Copyright © 2022 The Chinese Medical Association, produced by Wolters Kluwer, Inc. under the CC-BY-NC-ND license. This is an open access article distributed under the terms of the Creative Commons Attribution-Non Commercial-No Derivatives License 4.0 (CCBY-NC-ND), where it is permissible to download and share the work provided it is properly cited. The work cannot be changed in any way or used commercially without permission from the journal.

Chinese Medical Journal 2022;135(17)

Received: 29-12-2021; Online: 21-02-2022 Edited by: Peifang Wei

Access this article online	
Quick Response Code: 	Website: www.cmj.org
	DOI: 10.1097/CM9.0000000000002013

pation. Patients aged 45 to 75 years with upper lobe-predominant heterogeneous emphysema were enrolled. Participants with any condition that would interfere with follow-up (FU) assessments or would adversely affect the study outcomes were excluded [Supplementary Table 1, <http://links.lww.com/CM9/A950>].

Enrolled patients were allocated into either the BTVA group or conservative medication treatment (the control group) in a 1:1 ratio. The allocation is voluntary and non-randomized. Patients in the control group received standard medical management based on the Global Guidelines for Chronic Obstructive Pulmonary Disease,<sup>[5]</sup> including bronchodilators, inhaled corticosteroids, and pulmonary rehabilitation. Patients in the BTVA group received vapor ablation treatment in addition to standard medical management over a course of two-staged procedure. The second treatment session was scheduled 13 weeks after the first treatment session. The detailed BTVA procedure and 3D V/Q SPECT/CT protocol (see Supplementary Figure 1, <http://links.lww.com/CM9/A950>) were in the Supplementary Materials, <http://links.lww.com/CM9/A950>.

FU visits were scheduled at 3, 6, and 12 months post-intervention. Spirometry, 6-min walk distance (6MWD), modified Medical Research Council dyspnea scale (mMRC), and COPD assessment test (CAT) were examined during each FU. The 3-month FU data were collected before the second treatment session. 3D V/Q SPECT/CT scan was performed at 1-week pre-BTVA and 6 months post-BTVA to assess the changes in lung ventilation and perfusion; this was not conducted in the control group because of ethical concerns regarding radiation exposure.

The primary efficacy endpoints were improvements in pulmonary function (spirometry) and clinical function (6MWD, CAT, and mMRC) of the two trial groups at 3, 6, and 12 months post-intervention. The secondary efficacy endpoints were changes in lung ventilation and perfusion between 1-week pre-BTVA and 6 months post-

BTVA. Detailed statistical analysis was in the Supplementary Materials, <http://links.lww.com/CM9/A950>.

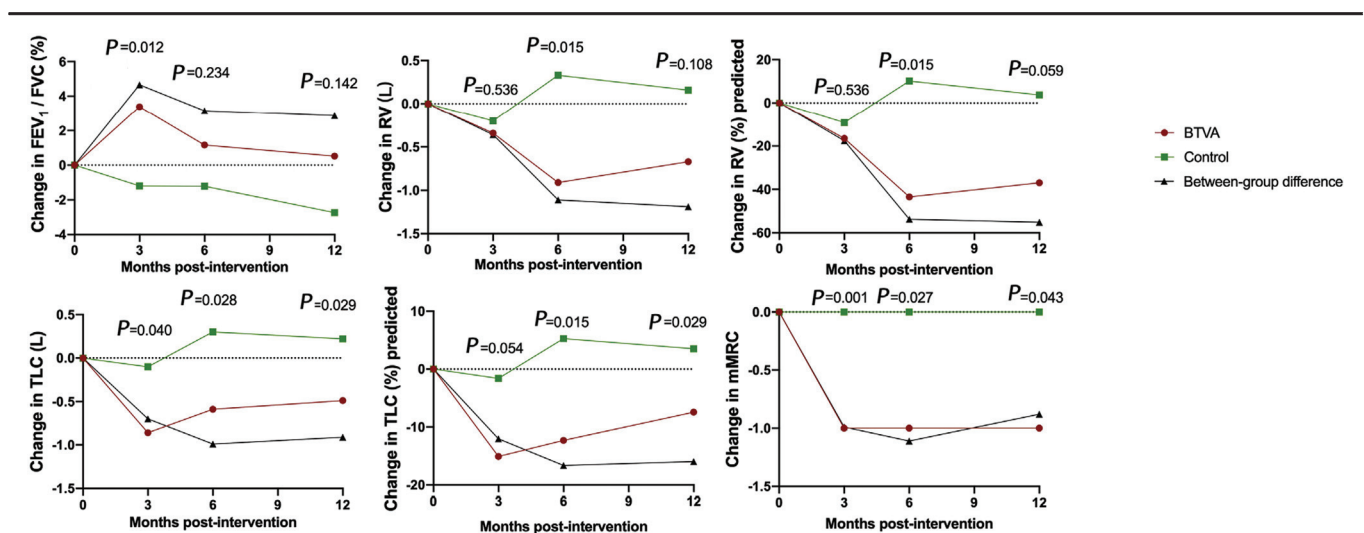
Between January 1, 2018 and December 31, 2019, 45 participants were screened and 18 participants were enrolled in this study with a mean age of  $60.28 \pm 7.81$  years. All participants were male and had a history of heavy smoking, but had abstained from smoking for >6 months [Supplementary Table 2, <http://links.lww.com/CM9/A950>]. Enrolled patients volunteered to be assigned to either the BTVA ( $n = 9$ ) or control group ( $n = 9$ ) [Supplementary Table 3, <http://links.lww.com/CM9/A950>].

Of the nine patients who received BTVA treatment, two did not receive the second treatment session because of serious adverse events. Two patients missed their 3-month spirometry, one patient missed his 6-month FU, and three patients missed their 12-month FU. Of the nine patients who received medication, one missed his 6-month spirometry FU and another missed his 12-month spirometry FU [Supplementary Figure 2, <http://links.lww.com/CM9/A950>].

Of the nine patients in the BTVA group, five underwent lobar quantification by 3D V/Q SPECT/CT both 1 week before and 6 months after the first treatment session. Of the five patients who underwent lobar quantification, one did not undergo second treatment session because of extensive improvement at 3 months.

Changes in spirometry, 6MWD, mMRC, and CAT scores of patients in each trial group were recorded at 3, 6, and 12 months following the first treatment session (or the allocation date for the control group). Figure 1 and Supplementary Table 4, <http://links.lww.com/CM9/A950> show the spirometry results and clinical function improvements between the trial groups.

Improvement in forced expiratory volume in 1 s ( $FEV_1$ )/forced vital capacity at 3 months in the BTVA group was significantly higher than that in the control group



**Figure 1:** Improvements in pulmonary and clinical functions over 12 months after BTVA compared with control group with mean between-group difference. The dots of each trial group were presented as median. Mean between-group difference was calculated as the mean value of BTVA group minus control group. BTVA: Bronchoscopic thermal vapor ablation;  $FEV_1$ : Forced expiratory volume in 1 s; FVC: Forced vital capacity; mMRC: Modified Medical Research Council dyspnea scale; RV: Residual volume; TLC: Total lung capacity.

(3.39 [0.54–4.53]% *vs.* -1.20 [-6.08 to 1.71]%,  $U = 8.000$ ,  $P = 0.012$ ), but was not statistically significant at 6 and 12 months. Improvement in FEV<sub>1</sub>% predicted at 12 months was significantly higher in the BTVA group than in the control group (3.75 [0.78–6.55]% *vs.* -0.25 [-3.55 to 1.83]%,  $U = 7.500$ ,  $P = 0.029$ ), but was not significantly different at 3 and 6 months. Improvement in residual volume (RV) (-0.91 [-1.60 to -0.61] L *vs.* 0.33 [-0.75 to 0.63] L,  $U = 9.000$ ,  $P = 0.015$ ) and RV% predicted (-43.50 [-81.34 to -30.23]% *vs.* 10.15 [-31.30 to 25.15]%,  $U = 9.000$ ,  $P = 0.015$ ) showed significant difference at 6 months when comparing the BTVA and control groups, but not at 3 and 12 months. Improvements in total lung capacity (TLC) and TLC% predicted were significantly higher at 6 and 12 months in the BTVA group than in the control group. Improvement in mMRC was significantly higher in the BTVA group than in the control group through the whole FU period. However, improvements in 6MWD and CAT scores were not statistically different between the trial groups.

Ventilation, perfusion, and V/Q changes on the targeted and non-targeted lobes on the ipsilateral side were calculated using 3D V/Q SPECT/CT [Supplementary Table 5, <http://links.lww.com/CM9/A950>]. The perfusion of the targeted lobe decreased significantly 6 months after BTVA treatment (mean,  $-3.80 \pm 1.64$ %,  $t = 5.171$ ,  $P = 0.007$ ). Although there was a decreasing tendency in ventilation, it was not statistically significant (mean  $\pm$  standard deviation,  $-3.20 \pm 4.32$ %,  $t = 1.655$ ,  $P = 0.173$ ). The ventilation and perfusion of the non-targeted lobe on the ipsilateral side were significantly increased 6 months following BTVA treatment. The mean increase in ventilation was ( $6.20 \pm 4.71$ %) ( $t = -2.942$ ,  $P = 0.042$ ) and the mean increase in perfusion was ( $3.20 \pm 1.10$ %) ( $t = -6.532$ ,  $P = 0.003$ ). No significant change in V/Q between the baseline and 6-month post-intervention was noted both on the targeted and non-targeted lobe on the ipsilateral side.

This is a study investigating the efficacy of BTVA in COPD patients with heterogeneous emphysema and lobar quantification using 3D V/Q SPECT/CT in China. This study confirmed that lung volume reduction with thermal vapor ablation leads to significant improvements both in pulmonary and clinical functions compared with standard care. In addition, we determined the feasibility of 3D V/Q SPECT/CT being used in the lobar quantification of patients who underwent BTVA and confirmed the ventilation and perfusion shifts between the targeted and non-targeted lobes on the ipsilateral lung.

The results at 3 months suggest that the treatment of one segment alone can positively affect the pulmonary and clinical functions. The significant results at 6 and 12 months suggest that staged ongoing treatment results in additional improvements over time. Since emphysema is an inexorable progressive disease and heterogeneity often exists within the treatment lobe, indicating that the lobe has segments that are almost healthy, a targeted strategy that preserves lung tissue is highly desirable. This staged ongoing treatment strategy allows a personalized approach to the treatment of the most diseased segments at

the initial stage, assessment of personal response, and consideration of next-stage treatment.

In this study, a salient reduction in the perfusion of the targeted lobe and a relative increase in the ventilation and perfusion of non-targeted lobes on the ipsilateral side after BTVA were estimated, which is considered a redistribution of ventilation and perfusion of the lung, leading to the promotion of the gas exchange of non-targeted lobes on the ipsilateral side. 3D V/Q SPECT/CT is used to evaluate the regional effects of BTVA in COPD patients with heterogeneous emphysema. Compared to the planar lung scintigraphy, a non-anatomical craniocaudal segmentation approach which is a poor reflection of true lobar anatomy and may miss the general effects, the 3D V/Q SPECT/CT analysis provides anatomically based quantification of local respiratory mechanics that can simultaneously estimate volume, ventilation, and perfusion in a more anatomically accurate and reproducible manner.<sup>[4]</sup> Our study suggests that 3D V/Q SPECT/CT plays a pivotal role in assessing the regional effects in COPD patients after BTVA.

In conclusion, BTVA in a targeted manner leads to pulmonary and clinical function improvements. 3D V/Q SPECT/CT is feasible for lobar quantification in assessing the ventilation and perfusion shifts of BTVA treatment.

### Funding

This work was supported by grants from the National Natural Science Foundation of China (NSFC No. 81770072); the “1.3.5 project for disciplines of excellence, West China Hospital, Sichuan University (No. ZYJC18021)””; Chengdu Science and Technology Bureau (No. 2018SZ0240).

### Conflicts of interest

None.

### References

1. Davey C, Zoumot Z, Jordan S, McNulty WH, Carr DH, Hind MD, *et al.* Bronchoscopic lung volume reduction with endobronchial valves for patients with heterogeneous emphysema and intact interlobar fissures (The BeLieVeR-HiFi Study): a randomised controlled trial. *Lancet* 2015;386:1066–1073. doi: 10.1016/s0140-6736(15)60001-0.
2. Shah PL, Herth FJ, van Geffen WH, Deslee G, Slebos DJ. Lung volume reduction for emphysema. *Lancet Respir Med* 2017;5:147–156. doi: 10.1016/s2213-2600(16)30221-1.
3. Herth FJF, Valipour A, Shah PL, Eberhardt R, Grah C, Egan J, *et al.* Segmental volume reduction using thermal vapour ablation in patients with severe emphysema: 6-month results of the multicentre, parallel-group, open-label, randomised controlled STEP-UP trial. *Lancet Respir Med* 2016;4:185–193. doi: 10.1016/s2213-2600(16)00045-x.
4. Kristiansen JF, Perch M, Iversen M, Krakauer M, Mortensen J. Lobar quantification by ventilation/perfusion SPECT/CT in patients with severe emphysema undergoing lung volume reduction with endobronchial valves. *Respiration* 2019;98:230–238. doi: 10.1159/000500407.
5. Mirza S, Clay RD, Koslow MA, Scanlon PD. COPD guidelines: a review of the 2018 GOLD report. *Mayo Clin Proc* 2018;93:1488–1502. doi: 10.1016/j.mayocp.2018.05.026.

**How to cite this article:** Zhu W, Zhang Y, Herth FJ, Liu D, Zhu H, Shi J, Zhang C, Tang G, Luo F. Efficacy of bronchoscopic thermal vapor ablation in patients with heterogeneous emphysema and lobar quantification by three-dimensional ventilation/perfusion single-photon emission computed tomography/computed tomography: a prospective pilot study from China. *Chin Med J* 2022;135:2098–2100. doi: 10.1097/CM9.0000000000002013