

Systemic Mycobacteriosis in an Aborted Thoroughbred Fetus in Japan

Yuto SANO¹⁾, Kazuya MATSUDA^{1)*}, Keisuke OSAKI¹⁾, Taku MIYASHO²⁾, Tomonori TSUDA³⁾ and Hiroyuki TANIYAMA¹⁾

¹⁾Department of Veterinary Pathology, School of Veterinary Medicine, Rakuno Gakuen University, Ebetsu, Hokkaido 069-8501, Japan

²⁾Department of Animal Science, School of Veterinary Medicine, Rakuno Gakuen University, Ebetsu, Hokkaido 069-8501, Japan

³⁾Northern Farm, Abira, Hokkaido 059-1432, Japan

(Received 28 May 2014/Accepted 1 August 2014/Published online in J-STAGE 21 August 2014)

ABSTRACT. A male Thoroughbred fetus was aborted on day 251 of pregnancy. Gross and histological examinations detected systemic granulomatous lesions in many superficial and visceral lymph nodes and organs including the liver, tonsils, lungs, thymus, spleen, right thyroid gland and gastrointestinal tract, and suppurative placentitis, pyogranulomatous amnionitis and intralesional acid-fast bacilli were also detected. An examination of the DNA base sequence of the β subunit of RNA polymerase demonstrated that *Mycobacterium avium* strain 104 had infected several organs. To the best of our knowledge, this is the first report of equine fetal mycobacterial infection in Japan.

KEY WORDS: abortion, horse, Japan, mycobacterium avium

doi: 10.1292/jvms.14-0276; *J. Vet. Med. Sci.* 76(12): 1617–1621, 2014

Mycobacteria are aerobic, non-motile, non-spore-forming, rod-shaped bacteria that are capable of causing granulomatous inflammation in a wide range of animals [8]. Bacteria belonging to the *Mycobacterium tuberculosis* complex (MTC) are called typical mycobacteria and cause tuberculosis. Conversely, diseases caused by bacteria that are not the members of the MTC; i.e., atypical mycobacteria, are referred to as mycobacterioses or atypical mycobacterioses [6, 8]. In horses, *Mycobacterium (M.) tuberculosis* and *M. bovis* produce tuberculosis, and atypical mycobacteria including those belonging to the *M. avium* complex (MAC) have been reported to cause mycobacteriosis [16]. However, mycobacterial infections rarely occur in horses, even in places where the disease exhibits a high incidence among other animal species; therefore, horses are considered to be naturally highly resistant to mycobacterial infection [16]. In equine cases of mycobacterial infection, lesions usually form in the intestinal tract and the associated lymph nodes, and hematogenous or lymphatic spread can occur to the liver, spleen, lungs and other lymph nodes [12, 14]. Miliary lesions are predominantly seen in the lungs of advanced cases [12]. The clinical signs of equine mycobacterial infection depend on the extent to which the animal's organs have been affected. The most frequent complaints are chronic weight loss, weakness and lethargy. In addition, horses can also present with pyrexia, coughing and respiratory distress due to the development of pulmonary lesions [16].

Equine abortions associated with fetal mycobacterial in-

fection are uncommon. In the English literature, only 4 cases have been reported; i.e., 2 cases of *M. avium* complex infection in North America [3, 5], a case of *M. terrae* infection in Australia [17] and a case of infection by a novel type of mycobacteria in North America [9]. In Japan, there has only been one reported case of equine mycobacteriosis, in which granulomatous pneumonia developed in an adult horse [2]. In this paper, we describe the first case of equine abortion with mycobacterial infection of the fetus and placenta in Japan.

A 9-year-old Thoroughbred mare aborted a male fetus on day 251 of gestation. This was the mare's 5th pregnancy and her first abortion. The mare was imported from the United States about 15 months before the abortion and was pregnant at the time. She had already delivered a healthy filly in Japan. A routine hormone test performed on day 213 of gestation revealed a high serum progesterone level, and further increases were seen on days 226 and 235. A decreased serum estrogen level was also detected on day 235 of gestation. Based on these results, placentitis was suspected, and antibiotic therapy was started. On day 241 of gestation, abdominal swelling was noticed. In an ultrasonographic examination, it was difficult to measure the combined thickness of the uterus and placenta, and this was attributed to a high intrauterine pressure caused by an increased amount of amniotic fluid [13]. The mare began to show signs of labor from day 246 of gestation, and the administration of a uterine relaxant was started. The mare aborted a male fetus 5 days later. Samples from the chorionic surface of the placenta that were obtained at the abortion were submitted for bacteriological examination in a commercial laboratory. The specimens were aerobically cultured for 18 to 24 hr at 35°C on blood, chocolate or MacConkey agar medium, and *Enterobacter agglomerans* was isolated. The aborted fetus and fetal membranes were submitted for gross and histological examinations.

The aborted fetus exhibited a crown-rump length of 47 cm and weighed 10 kg. The fetus presented with growth

*CORRESPONDENCE TO: MATSUDA, K., Department of Veterinary Pathology, School of Veterinary Medicine, Rakuno Gakuen University, 582 Bunkyo-dai-Midorimachi, Ebetsu, Hokkaido 069-8501, Japan. e-mail: kmatsuda@rakuno.ac.jp

©2014 The Japanese Society of Veterinary Science

This is an open-access article distributed under the terms of the Creative Commons Attribution Non-Commercial No Derivatives (by-nc-nd) License <http://creativecommons.org/licenses/by-nc-nd/3.0/>.

insufficiency and was emaciated, and a white viscous substance adhered to its external surface. Enlarged superficial and visceral lymph nodes were seen throughout its body, including the axillary, inguinal, mediastinal, bronchial, intercostal, hepatic, splenic, gastric, mesenteric and colonic lymph nodes. The cranial mesenteric lymph nodes were most severely affected and measured approximately $9 \times 4 \times 4$ cm (Fig. 1). Cut sections revealed the multinodular proliferation of homogenous light-tan tissue with occasional central yellowish-white foci (Fig. 2). The liver was diffusely yellowish in color and slightly swollen. About half of the caudate lobe of the liver had been replaced with an aggregate of small yellowish-white nodules, which measured up to 3 mm in diameter. The tonsils were enlarged and exhibited an irregularly roughened surface. White nodules, which measured up to 5 mm in diameter, were scattered throughout the lungs, thymus, spleen and right thyroid gland. The intestinal mucosa was diffusely roughened from the jejunum to the colon, and many minute white nodules were evident in the wall on cut sections. The lungs displayed diffuse atelectasis.

In the placenta, the cervical star exhibited a birth tear. In addition, the placenta had thickened slightly due to edema, and the chorionic surface was diffusely congestive and covered with a sanguineous exudate containing necrotic debris. The allantoamnion was diffusely edematous, and numerous raised yellow plaques, which measured up to 1 cm in diameter and in some cases had fused together, were distributed across the surface of the amnion (Fig. 3). The collected tissues were fixed in 10% neutral-buffered formalin, embedded in paraffin, cut into 4 μ m-thick sections and stained with hematoxylin and eosin. Selected sections were subjected to Gram and Ziehl-Neelsen staining.

Histologically, most of the normal lymph node tissue had been replaced by diffuse granulomatous lesions composed of many epithelioid macrophages, scattered neutrophils and multinucleated giant cells intermingled with proliferative fibrous tissue (Fig. 4). The multifocal accumulation of neutrophils, which had become necrotic, and a coagulum of nuclear and cytoplasmic debris were also observed (Fig. 4). The lesions displayed a sarcomatous appearance as described previously in equine mycobacterial infections (Fig. 5), whereas tubercles in other animal species are typically nodular granulomas composed of concentrically arranged cells [1]. The cytoplasm of the macrophages and multinucleated giant cells within these lesions exhibited a fine granular appearance. In addition to the lymph nodes that had grossly enlarged, the superficial cervical, medial and lateral retropharyngeal, renal, medial iliac and iliofemoral lymph nodes also exhibited lesions. The grossly observed small nodules in the caudate lobe of the liver were granulomas, which were frequently accompanied by central necrosis. The hepatocytes displayed diffuse fatty changes, and small foci of granulomatous inflammation were found in the portal regions of the remaining lobes. Similar granulomatous lesions had also formed in the tonsils, lungs, thymus, spleen and right thyroid gland, which corresponded to the small white nodules observed during the gross examination. Multifocal or diffuse granulomatous proliferation was seen in the lamina propria

and submucosa from the stomach to the right dorsal colon. The chorionic surface of the allantochorion was diffusely covered with an abundant proteinaceous exudate containing degenerative neutrophils with a scattered or focal distribution and colonies of Gram-positive bacilli. In addition, neutrophils had accumulated multifocally in the villous stroma, and the chorioallantoic stroma was edematous. Squamous metaplasia of the chorionic epithelium was also observed. Severe lesions were present throughout an extensive area from the cervix to the body of the chorion. In the amnion, neutrophils had accumulated to form multiple abscesses and were also found in the regions around blood vessels. Epithelioid macrophages and multinucleated giant cells were scattered around the abscesses and among the infiltrating neutrophils. Ziehl-Neelsen staining detected numerous acid-fast bacilli within the intralesional phagocytes in the liver, tonsils, lungs, spleen, thymus, jejunum, ileum, colons and superficial cervical, axillary, inguinal, mediastinal, gastric and mesenteric lymph nodes in the fetus and amnion (Fig. 5, inset), which were only weakly stained by Gram staining. Acid-fast bacilli were also scattered in the necrotic foci. The Gram-positive bacilli in the chorionic exudate exhibited intense acid-fast reactions. Acid-fast bacilli that had adhered to the fetus' skin were also observed.

Cryopreserved specimens of the thymus, lungs, liver, spleen, cranial mesenteric lymph nodes, allantochorion and allantoamnion that were obtained during necropsy were subjected to polymerase chain reaction (PCR) analysis to identify the acid-fast organisms. DNA was extracted from the samples using a DNA isolation kit (MagNA Pure LC DNA Isolation Kit I, Roche, Basel, Switzerland) and was then analyzed by PCR targeting the gene encoding the β subunit of RNA polymerase (*rpoB*) (primers: MF, 5'CGACCACTTCGGCAACCG3'; MR, 5'TCGATCGGGCACATCCGG3'), as described previously [10]. The resultant PCR product was approximately 350 base pairs in length (Fig. 6), and its nucleotide sequence was analyzed in a commercial laboratory (MacroGen Japan Corp., Tokyo, Japan). A BLAST search detected 100% homology between the PCR product and the *M. avium* strain 104 (*M. avium* 104) published in GenBank (accession numbers NC008595 and CP000479). Blood and fecal specimens from the mare, which were obtained at 8 and 17 months after the abortion, respectively, were also subjected to PCR analysis using the same method. No specific DNA of mycobacterial organisms was detected in these specimens.

Based on these findings, the case was etiologically diagnosed as fetal systemic mycobacteriosis and mycobacterial placentitis due to *M. avium* 104 infection. The fetus had systemic lesions histologically characterized by granulomatous inflammation with intralesional acid-fast bacilli. The fetal membranes exhibited diffuse, severe suppurative chorionitis and pyogranulomatous amnionitis, and intralesional acid-fast bacilli were detected on them.

In Japan, there has only been one case report about equine mycobacterial infection, which involved granulomatous pneumonia in an adult horse. Bacteria belonging to the MAC were isolated from the case [2]. *M. avium* 104, which was

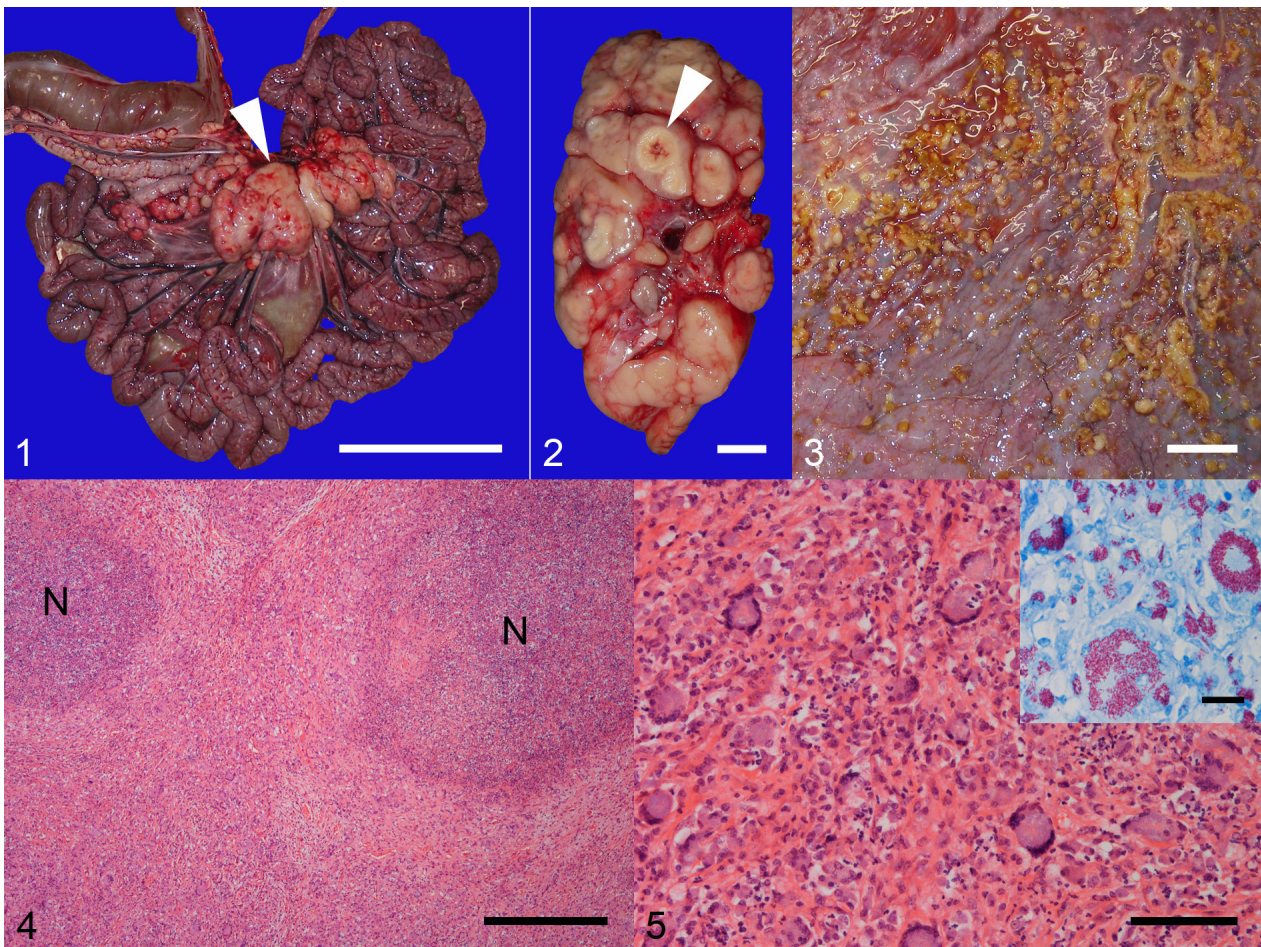


Fig. 1. Gross photograph of the fetus' intestinal tract and the associated lymph nodes. The cranial mesenteric lymph nodes are markedly enlarged (arrowhead). Bar=10 cm.

Fig. 2. Cut surface of a cranial mesenteric lymph node. The lymph node is enlarged and has been replaced with homogenous light-tan tissue and occasional central necrosis (arrowhead). Bar=1 cm.

Fig. 3. Gross photograph of the surface of the amnion. Multifocal to coalescing, raised yellow plaques are distributed across the surface of the amnion. Bar=2 cm.

Fig. 4. The cranial mesenteric lymph node has been replaced by a diffuse granulomatous lesion containing necrotic foci (N). HE. Bar=500 μ m.

Fig. 5. Higher magnification image of the granulomatous lesion in the cranial mesenteric lymph node. The lesion is composed of epithelioid macrophages, multinucleated giant cells and neutrophils admixed with prominent fibrous tissue, which exhibits a sarcomatous appearance. HE. Bar=100 μ m. (Inset) Numerous acid-fast staining bacilli are detected within the cytoplasm of the epithelioid macrophages and multinucleated giant cells. Ziehl-Neelsen. Bar=20 μ m.

detected in our specimens, is also a member of the MAC and was previously demonstrated to be identical to a strain of *M. avium* subsp. *hominissuis* (MAH) based on an examination of the sequence of its *hsp65* gene [18]. MAH infection is often detected in pigs and humans in Japan [7], as well as in other countries [15] and has been described in adult horses, but not in equine fetuses [4, 11, 16]. Although MAC species have been identified as causative agents in two equine cases of fetal mycobacterial infection [3, 5], this is the first report about a case in which MAH infection resulted in fetal mycobacteriosis and abortion. The present case indicates that it is possible for mycobacterial organisms to be transmitted from

infected horses, their environments and/or equine veterinary facilities. The risk assessment is needed against mycobacterial infection in persons working in the horse industry.

Three infectious routes have been suggested to be involved in the pathogenesis of placentitis in horses: ascending infection from the posterior genital tract by way of the cervix, hematogenous infection from the maternal bloodstream and local spread from infectious foci derived from deep-seated endometritis [20]. In the current case, the presence of acid-fast bacilli in the exudate found on the chorionic surface indicated that the bacteria might have entered the uterus via the cervix. Furthermore, bacterial invasion of the chorionic

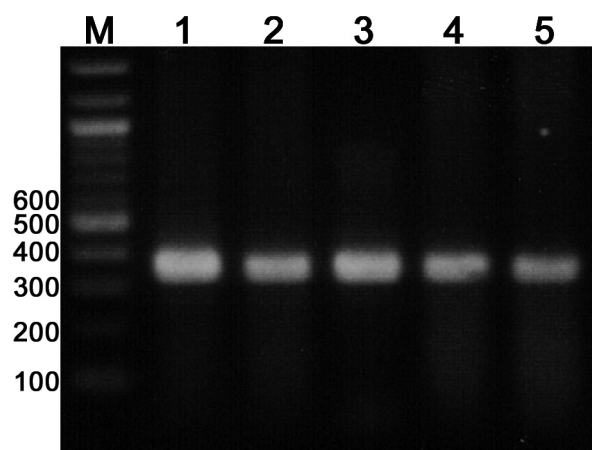


Fig. 6. PCR analysis targeting the *rpoB* gene. M: 100 bp DNA ladder, lanes 1–5: DNA samples obtained from the liver, lungs, cranial mesenteric lymph nodes, amnion and chorion, respectively. All PCR products are approximately 350 base pairs in length.

surface and subsequent hematogenous spread might have caused the fetus' systemic infection. The adherence of acid-fast bacilli to the fetal skin indicated that the bacilli were present in the amniotic fluid, and a peroral infection might subsequently have occurred. Suppurative chorionitis was also observed in the previous cases of fetal equine mycobacteriosis [5, 9]. Superinfection by *Enterobacter agglomerans* or other undetected bacteria might have modified the chorionic lesion and played a role in the subsequent abortion. The fact that mycobacteria were not isolated from the specimen collected in the present case suggests that a specific culture method might be needed for isolating mycobacteria [16].

In the 4 previously reported cases of fetal mycobacterial infection involving aborted horse fetuses, the fetuses were aborted on days 160, 180, 255 (8 1/2 months) and 300 of gestation, respectively [3, 5, 9, 17]. In one of these cases, a Standardbred fetus that was delivered on day 160 of gestation had numerous non-caseating granulomas in its small intestine, splenic lymph nodes, lungs, liver, amnion and allantochorion, which were only detected during microscopic examinations [3]. However, an American Quarter Horse that was aborted on day 180 of gestation did not have any significant granulomatous lesions [9]. In addition, an 8 1/2-month-old Thoroughbred fetus did not exhibit any gross lesions, but histiocytic bronchopneumonia involving intralobular acid-fast bacilli was detected microscopically [17]. Finally, a Standardbred fetus that was aborted on day 300 of gestation had non-caseating granulomas in its liver; suppurative pneumonia, in which intraalveolar multinucleated giant cells were found to have engulfed aspirated materials; and extensive suppurative placentitis [5]. Compared to these cases, the present case, in which the fetus was aborted on day 251 of gestation, involved more severe and extensive lesions, which affected the fetus' lymph nodes and organs. The degree and distribution of mycobacterial lesions are

considered to be influenced by various bacterial parameters, such as the quantity and virulence of the causative bacteria [8]. The immunological status of the host is also considered to play a key role in the development of lesions in human MAC infections [6]. In human cases of pulmonary and disseminated MAC disease, *M. avium* 104 was frequently detected in the lesions of immunocompromised hosts [19]. In this case, although the virulence of the isolated mycobacterium was not determined, the destruction of lymphoid tissue might have adversely affected the immunological status of the fetus, leading to a vicious circle of disease expansion.

REFERENCES

- Alfonso, L. 2011. Respiratory system, mediastinum, and pleurae. pp. 458–538. *In: Pathologic Basis of Veterinary Diseases*, 5th ed. (Zachary, J. F. and McGavin, M. D. eds.), Elsevier, St. Louis.
- Anzai, T., Kamada, M., Kanemaru, T. and Oikawa, M. 1989. Isolation of *Mycobacterium avium* complex from a Thoroughbred racehorse with fatal pneumonia. *Bull. Equine Res. Inst.* **26**: 73–77.
- Cline, J. M., Schlafer, D. W., Callihan, D. R., Vanderwall, D. and Drazek, F. J. 1991. Abortion and granulomatous colitis due to *Mycobacterium avium* complex infection in a horse. *Vet. Pathol.* **28**: 89–91. [[CrossRef](#)] [[Medline](#)]
- Dagleish, M. P., Stevenson, K., Foster, G., McLuckie, J., Sellar, M., Harley, J., Evans, J. and Brownlow, A. 2012. *Mycobacterium avium* subsp. *hominissuis* infection in a captive-bred kiang (*Equus kiang*). *J. Comp. Pathol.* **146**: 372–377. [[CrossRef](#)] [[Medline](#)]
- Hélie, P. and Higgins, R. 1996. *Mycobacterium avium* complex abortion in a mare. *J. Vet. Diagn. Invest.* **8**: 257–258. [[CrossRef](#)] [[Medline](#)]
- Inderlied, C. B., Kemper, C. A. and Bermudez, L. E. M. 1993. The *Mycobacterium avium* complex. *Clin. Microbiol. Rev.* **6**: 266–310. [[Medline](#)]
- Iwamoto, T., Nakajima, C., Nishiuchi, Y., Kato, T., Yoshida, S., Nakanishi, N., Tamaru, A., Tamura, Y., Suzuki, Y. and Nasu, M. 2012. Genetic diversity of *Mycobacterium avium* subsp. *hominissuis* strains isolated from humans, pigs, and human living environment. *Infect. Genet. Evol.* **12**: 846–852. [[CrossRef](#)] [[Medline](#)]
- Jeff, L. C. and Kurt, J. W. 2007. Respiratory system. pp. 523–653. *In: Jubb, Kennedy, and Palmer's Pathology of Domestic Animals*, vol. 2. 5th ed. (Maxie, M. G. ed.), Saunders, Elsevier, Philadelphia.
- Johnson, A. K., Roberts, J. F., Hagan, A., Wilborn, R. R., Dujovne, G., Sells, S. F. and Donahue, J. M. 2012. Infection of an equine placenta with a novel mycobacterial species leading to abortion. *J. Vet. Diagn. Invest.* **24**: 785–790. [[CrossRef](#)] [[Medline](#)]
- Kim, B. J., Lee, S. H., Lyu, M. A., Kim, S. J., Bai, G. H., Kim, S. J., Chae, G. T., Kim, E. C., Cha, C. Y. and Kook, Y. H. 1999. Identification of mycobacterial species by comparative sequence analysis of the RNA polymerase gene (*rpoB*). *J. Clin. Microbiol.* **37**: 1714–1720. [[Medline](#)]
- Kriz, P., Jahn, P., Bezdekova, B., Blahutkova, M., Mrlik, V., Slana, I. and Pavlik, I. 2010. *Mycobacterium avium* subsp. *hominissuis* infection in horses. *Emerg. Infect. Dis.* **16**: 1328–1329. [[CrossRef](#)] [[Medline](#)]
- Luke, D. 1958. Tuberculosis in the horse, pig, sheep and goat. *Vet. Rec.* **70**: 529–536.
- Macpherson, M. L. 2006. Diagnosis and treatment of equine

- placentitis. *Vet. Clin. North Am. Equine Pract.* **22**: 763–776. [[CrossRef](#)] [[Medline](#)]
14. Mair, T. S., Taylor, F. G. R., Gibbs, C. and Lucke, V. M. 1986. Generalized avian tuberculosis in a horse. *Equine Vet. J.* **18**: 226–230. [[CrossRef](#)] [[Medline](#)]
 15. Mijs, W., de Haas, P., Rossau, R., Van der Laan, T., Rigouts, L., Portaels, F. and van Soelingen, D. 2002. Molecular evidence to support a proposal to reserve the designation *Mycobacterium avium* subsp. *avium* for bird-type isolates and '*M. avium* subsp. *hominissuis*' for the human/porcine type of *M. avium*. *Int. J. Syst. Evol. Microbiol.* **52**: 1505–1518. [[CrossRef](#)] [[Medline](#)]
 16. Pavlik, I., Jahn, P., Dvorska, L., Bartos, M., Novotny, L. and Halouzka, R. 2004. Mycobacterial infections in horses: a review of the literature. *Vet. Med.-Czech* **49**: 427–440.
 17. Tasler, G. R. W. and Hartley, W. J. 1981. Foal abortion associated with *Mycobacterium terrae* infection. *Vet. Pathol.* **18**: 122–125. [[Medline](#)]
 18. Turenne, C. Y., Semret, M., Cousins, D. V., Collins, D. M. and Behr, M. A. 2006. Sequencing of *hsp65* distinguishes among subsets of the *Mycobacterium avium* complex. *J. Clin. Microbiol.* **44**: 433–440. [[CrossRef](#)] [[Medline](#)]
 19. Uchiya, K., Takahashi, H., Yagi, T., Moriyama, M., Inagaki, T., Ichikawa, K., Nakagawa, T., Nikai, T. and Ogawa, K. 2013. Comparative genome analysis of *Mycobacterium avium* revealed genetic diversity in strains that cause pulmonary and disseminated disease. *PLoS ONE* **8**: e71831. [[CrossRef](#)] [[Medline](#)]
 20. Whitwell, K. E. 1980. Investigations into fetal and neonatal losses in the horse. *Vet. Clin. North Am. Large Anim. Pract.* **2**: 313–331. [[Medline](#)]