

Case Report

Postoperative testicular abscess with bacteremia due to *Actinomyces neuii*



Juan Carlos Rico Crescencio ^{*}, Robin Koshy

Division of Infectious Diseases, North Shore-LIJ Health System, Manhasset, NY 11030, USA

ARTICLE INFO

Article history:

Received 11 April 2014

Received in revised form 16 May 2014

Accepted 21 May 2014

Keywords:

Actinomyces neuii

Testicular abscess

Bacteremia

ABSTRACT

Bacteremia due to *Actinomyces neuii* has been reported in the literature 14 times. *A. neuii* is an endogenous organism that has been cultured in clinical specimens of the genitourinary tract; we are reporting a unique case of *A. neuii* postoperative testicular abscess with bacteremia which was successfully treated with surgery and a short course of parenteral antimicrobials.

© 2014 The Authors. Published by Elsevier Ltd. This is an open access article under the CC BY-NC-ND license (<http://creativecommons.org/licenses/by-nc-nd/3.0/>).

Introduction

Actinomyces neuii are irregularly shaped gram-positive rods that grow well under aerobic conditions as other species in the genus, but do not display the typical branching filaments and do not cause the typical lesions of actinomycosis with purulent discharge of sulfur granules observed in most other actinomyces species. *A. neuii* represents 17% of all clinical Actinomyces isolates [1].

Case report

A 26 year-old-male was admitted to the hospital last year with the chief complaint of fevers up to 104 °F, associated with chills, nausea, vomiting, right testicular pain and swelling. He denied any dysuria, hematuria, urinary urgency, hesitancy or penile discharge. Four weeks before admission, the patient had an ultrasound of the scrotum, for a lump detected on the right testicle during a routine exam, which showed a 2.8 cm × 2.7 cm × 2.5 cm mass with onion skinning and increased stiffness in the right testicle consistent with epidermoid cyst. He subsequently underwent a right partial orchiectomy that confirmed the diagnosis. Two weeks after the surgery, an intratesticular hematoma was noted at his urology clinic visit, and he received ciprofloxacin PO as prophylaxis for one week.

This patient had history of imperforated anus repair and bladder neck fistula repair few months after birth, and lysis of adhesions 2 years ago. He is an engineer, lives with his wife and has no toxic habits or family history of malignancies.

Upon examination, the patient appeared ill, febrile (T 103.1 °F), tachycardic (HR 126 bpm), normotensive (BP 111/71 mmHg) and tachypneic (RR 22 breaths per minute) saturating 100% on room air. His physical exam revealed the presence of right testicular enlargement with skin induration and tenderness on palpation. Laboratory results were remarkable for leukocytosis (WBC 18.1), mild acute kidney injury and hypokalemia. Blood cultures grew gram positive rods in aerobic bottles, at 58 and 70 h of incubation respectively. A testicular ultrasound showed 5.1 cm × 3.7 cm × 4 cm collection suggestive of infected hematoma or abscess (Fig. 1). The patient received vancomycin, gentamicin and clindamycin IV in the ED, and underwent a radical right orchiectomy. The pathology report showed a testicular abscess, and G&S showed moderate gram positive rods along with few gram positive cocci in tetrads and cultures. Cultures from the blood and the abscess grew *A. neuii*.

This is a representative sagittal view of the right testicle showing a collection within the testicle measuring approximately 5.1 cm × 3.7 cm × 4 cm with thickened wall and internal debris.

Piperacillin/tazobactam and vancomycin IV were started after the surgery pending culture results. Subsequent blood cultures were negative, and the patient was discharged, 5 days later, on ertapenem and vancomycin IV for a total of 14 days from the time of the negative blood cultures. The patient presented for follow-up visits demonstrating rapid wound healing and no acute symptoms.

^{*} Corresponding author at: Division of Infectious Disease, North Shore-LIJ Health System, 400 Community Drive, Manhasset, NY 11030, USA. Tel.: +1 516 562 4280; fax: +1 516 562 2626.

E-mail address: jricocre12@nshs.edu (J.C.R. Crescencio).

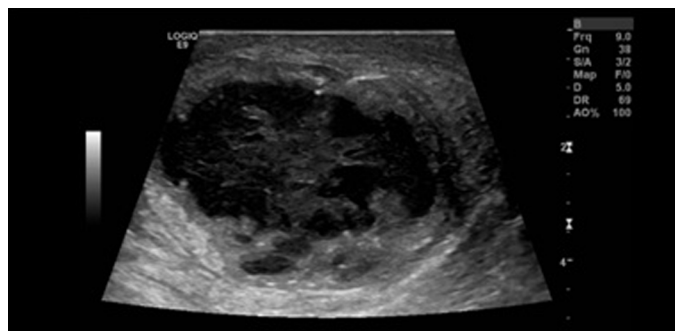


Fig. 1. Scrotal ultrasound.

Discussion

In 1993 Funke et al., based on 16S rRNA sequence analysis, DNA–DNA hybridization studies, as well as cellular and metabolic acid profiles, assigned the formerly known as “CDC Group 1 Coryneform bacteria” and “CDC 1-like Coryneform bacteria” to the genus *Actinomyces* as *A. neuii* subsp. *neuii* and *A. neuii* subsp. *anitratu*s respectively [1].

A. neuii are gram positive bacteria, non-motile, non-spore forming, catalase positive, facultative anaerobic, predominantly diphtheroidal but coccobacilli may occur. Colonies are circular, smooth, opaque and white, measuring 0.5–1.5 mm in diameter after 48 h of incubation in 5% CO₂ on sheep blood agar. At the morphological level, *A. neuii* subsp. *neuii* differs from the subsp. *anitratu*s in the ability to cause α -hemolysis where the later is unable to perform it. Another major difference between both subspecies is found at the molecular level where *A. neuii* subsp. *anitratu*s lacks the ability to reduce nitrate.

Actinomyces spp. are known colonizers of the human body, but only one study has shown *A. neuii* in the oral flora of healthy individuals [2]. Human to human transmission has been observed in a case of maternal chorioamnionitis in which *A. neuii* caused sepsis in a preterm neonate.

Traditionally, *A. neuii* has been isolated in abscesses and infected atheromas, followed by infected skin lesions [1]. There have been case reports in the literature of *A. neuii* causing: endocarditis, endophthalmitis, genitourinary infections, chorioamnionitis, chronic osteomyelitis, septic arthritis, mammary prosthesis infection,

prosthetic joint infections, ventricular-peritoneal shunt infections, and penile prosthesis reservoir infections.

A. neuii is susceptible to penicillins, cephalosporins, clindamycin, macrolides, tetracyclines, carbapenems and vancomycin. Diminished susceptibility has been observed to aminoglycosides and fluoroquinolones.

A total of 14 cases with documented *A. neuii* bacteremia, as a single agent have been reported, but only in 6 cases therapeutic management are mentioned. In 2 cases of endocarditis, both patients received antibiotic therapy for a total of a year (combining IV and PO antimicrobials) [3,4]. In a case of chorioamnionitis, a preterm newborn received 2 weeks of ampicillin IV followed by 4 weeks of penicillin G PO [5]. A case of perinephric abscess received almost 6 weeks of IV and PO antimicrobials [6]. A fateful case of *A. neuii* bacteremia secondary to septic arthritis vs. urinary tract infection was on 29 days of IV antimicrobials when the patient passed away with acute respiratory failure due to pulmonary embolism [1]. One case of cystitis was reported in a revision of *Actinomyces* spp. infections in Denmark that was treated with a short-course of antimicrobials (cefuroxime and meropenem for 9 days) [6].

In our case, as the source of the infection was radically controlled by surgery, and having in mind that *A. neuii* does not cause the characteristic chronic lesions with dense fibrosis, draining fistulae and sulfur granules as other *Actinomyces* spp. do, we decided to keep the antimicrobial management for 2 weeks.

Conflict of interest

The authors declare no competing financial interests.

References

- [1] Funke G, von Graevenitz A. Infections due to *Actinomyces neuii* (former “CDC coryneform group 1” bacteria). *Infection* 1995;23:73–5.
- [2] Persson GR, Hitti J, Paul K, Hirschi R, Weibel M, Rothen M, et al. *Tannerella forsythia* and *Pseudomonas aeruginosa* in subgingival bacterial samples from parous women. *J Periodontol* 2008;79:508–16.
- [3] Grundmann S, Huebner J, Stuplich J, Koch A, Wu K, Geibel-Zehender A, et al. Prosthetic valve endocarditis due to *Actinomyces neuii* successfully treated with antibiotic therapy. *J Clin Microbiol* 2010;48:1008–11.
- [4] Cohen E, Bishara J, Medalion B, Sagie A, Garty M. Infective endocarditis due to *Actinomyces neuii*. *Scand J Infect Dis* 2007;17:445–7.
- [5] Mann C, Dertinger S, Hartmann G, Schurz R, Simma B. *Actinomyces neuii* and neonatal sepsis. *Infection* 2002;30:178–80.
- [6] Hansen JM, Fjeldsoe-Nielsen H, Sulim S, Kemp M, Christensen JJ. *Actinomyces* species: a Danish survey on human infections and microbiological characteristics. *Open Microbiol J* 2009;3:113–20.