



## Case report

## Office-based intravitreal injection of expansile gas for management of macular hole in previously vitrectomized eyes



Michael A. Apolinario<sup>a,b</sup>, Shaun I.R. Lampen<sup>a</sup>, Tien P. Wong<sup>a,c</sup>, Christopher R. Henry<sup>a,c</sup>, Charles C. Wykoff<sup>a,c,\*</sup>

<sup>a</sup> Retina Consultants of Houston, Houston, TX, USA

<sup>b</sup> Texas A&M Health Science Center College of Medicine, College Station, TX, USA

<sup>c</sup> Blanton Eye Institute, Houston Methodist Hospital & Weill Cornell Medical College, Houston, TX, USA

## ARTICLE INFO

## Keywords:

Macular hole  
Pars plana vitrectomy  
Intravitreal gas injection

## ABSTRACT

**Purpose:** To report the successful closure of full-thickness macular hole (MH), using an office-based intravitreal gas injection, in two eyes having undergone prior pars plana vitrectomy (PPV).

**Observations:** Patient 1 presented with acute loss of visual acuity to 20/300 in the left eye 5 months following PPV for fovea-off rhegmatogenous retinal detachment; MH was confirmed by examination and optical coherence tomography (OCT). 0.6 cc of 100% C3F8 gas was injected, with subsequent MH closure following one week of face-down positioning. Patient 2 presented with right eye visual acuity of 20/60 one month following PPV for optic nerve pit-associated maculopathy; MH was confirmed by examination and OCT. 0.85 cc of 100% C3F8 gas was injected in the office, with subsequent MH closure following one week of face-down positioning.

**Conclusions and importance:** MH management in previously vitrectomized eyes has traditionally been repeat PPV with internal limiting membrane peeling, fluid-air exchange, and expansile gas exchange. Intravitreal gas injection, in an office-based setting, is a viable clinical approach to close MH in some previously vitrectomized eyes.

## 1. Introduction

Macular hole (MH) is a well-recognized clinical entity whose formation is primarily attributed to vitreomacular traction, as originally described by J. Donald Gass in the pre-optical coherence tomography (OCT) era.<sup>1</sup> Pioneered in the 1990s, a standard management approach includes pars plana vitrectomy (PPV), with or without peeling of the internal limiting membrane (ILM).<sup>2</sup> However, MH can also occur in the absence of vitreous traction<sup>2</sup> as evidenced by the development of MH in eyes having previously undergone PPV.<sup>3,4,3,4</sup> The current standard approach to managing MH following PPV is to repeat PPV with concurrent ILM peeling. In the current report, two cases of MH in previously vitrectomized eyes were successfully closed following an office-based intravitreal injection of expansile gas.

## 2. Findings

## 2.1. Case 1

A 60-year-old male with type 2 diabetes mellitus receiving

intravitreal anti-vascular endothelial growth factor (VEGF) injections for diabetic macular edema (DME) in the left eye developed acute onset photopsias and floaters six days following an intravitreal aflibercept injection. The patient was diagnosed with a fovea-involving rhegmatogenous retinal detachment (RRD) (Fig. 1A). Best prior visual acuity (VA) while receiving anti-VEGF injections was 20/25; VA at RRD diagnosis was 20/400. The patient underwent RRD repair with PPV and encircling scleral buckle placement one day following RRD diagnosis without concurrent ILM peeling. Due to persistent DME post-operatively, the patient resumed anti-VEGF intravitreal injections four months following RRD repair. One month after the first intravitreal anti-VEGF injection following RRD repair, corresponding to 5 months following RRD repair, the patient presented with acute onset scotoma centrally with VA of 20/300. Ophthalmoscopic examination and OCT imaging identified the presence of a full thickness MH (Fig. 1B). Office-based MH closure was attempted with injection of 0.6 cc of 100% C3F8 gas with concurrent anterior chamber paracentesis for normalization of intraocular pressure (IOP). Bubble expansion resulted in greater than 40% gas fill in the vitreous cavity. The patient was instructed to maintain face down positioning for one week. Evaluation 7 days

\* Corresponding author. 6560 Fannin Street, Suite 750, Houston, TX, 77030, USA.

E-mail address: [ccwmd@houstonretina.com](mailto:ccwmd@houstonretina.com) (C.C. Wykoff).

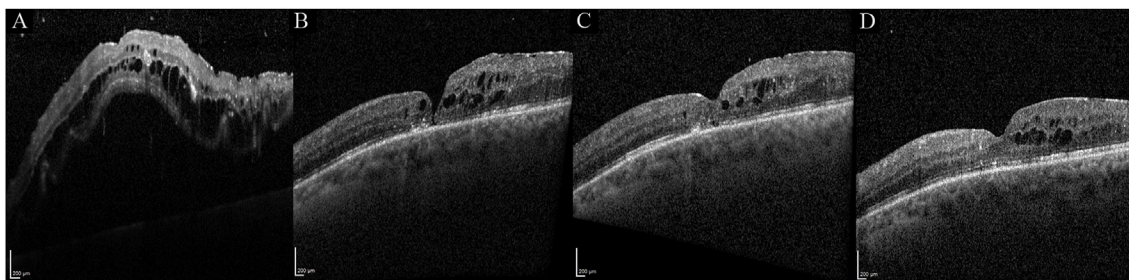
<https://doi.org/10.1016/j.ajoc.2019.100492>

Received 22 May 2018; Received in revised form 7 November 2018; Accepted 6 June 2019

Available online 05 July 2019

2451-9936/© 2019 The Authors. Published by Elsevier Inc. This is an open access article under the CC BY-NC-ND license

(<http://creativecommons.org/licenses/by-nc-nd/4.0/>).



**Fig. 1.** Optical coherence tomography line-scans of Patient 1 at time of rhegmatogenous retinal detachment (RRD) diagnosis (A), at time of full thickness macular hole (MH) diagnosis measuring 53  $\mu\text{m}$  in widest width five months following RRD repair (B), seven days post-0.6 cc 100% C3F8 gas intravitreal injection demonstrating MH closure (C), and six months post-successful MH closure (D).

following intravitreal gas injection demonstrated MH closure (Fig. 1C). Three weeks later he resumed anti-VEGF treatments, with subsequent gradual VA improving to 20/40 by 6 months post-MH closure (Fig. 1D).

## 2.2. Case 2

An otherwise healthy 19-year-old male presented with VA of 20/100 and distorted vision in his right eye. Examination revealed a prominent optic nerve pit with associated maculopathy involving intraretinal and subretinal fluid extending through the fovea (Fig. 2A). PPV was performed with concurrent ILM peeling, fluid-air exchange, and expansile gas exchange. One month following PPV with ILM peeling, VA had improved to 20/60, however, a new full thickness MH was identified on examination and OCT (Fig. 2B). Office-based MH closure was attempted with injection of 0.85 cc of 100% C3F8 gas with concurrent anterior chamber paracentesis for normalization of the IOP. Bubble expansion resulted in a greater than 80% gas fill in the vitreous cavity. The patient was instructed to maintain face down positioning for one week. OCT 8 weeks following intravitreal gas injection demonstrated MH closure with improvement of VA to 20/40 (Fig. 2C). Follow-up visit two years later demonstrated VA improvement to 20/30 (Fig. 2D).

## 3. Discussion

Successful closure of MH with clinic-based intravitreal gas injection has been described for MH in non-vitreotomized eyes, especially in the setting of vitreomacular traction.<sup>8,9,9</sup> MH following PPV is an uncommon clinical entity and data related to its management are limited. Successful closure of MH in previously vitrectomized eyes has been reported with repeat PPV, simultaneous ILM peeling, fluid-air exchange, and expansile gas exchange.<sup>2,5–7</sup> Compared to repeat PPV, office-based intravitreal gas injection has the advantage of being a readily performed procedure, possibly with lower risk of peri-operative complications.<sup>9,10</sup> In the current manuscript, two cases of MH developing following PPV were successfully closed with clinic-based 100%

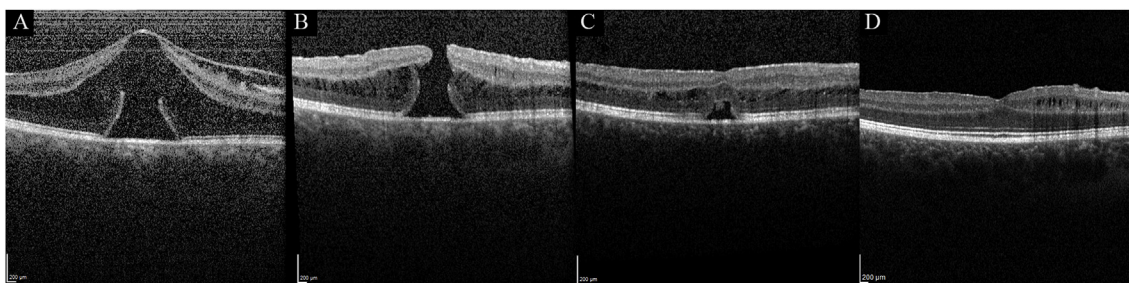
C3F8 intravitreal gas injection with prescribed face down positioning for one week.

There are at least two notable differences between the current cases. First, one case underwent ILM peeling during the initial PPV and one did not. A previous analysis of 423 eyes having undergone PPV with ILM peeling reported that 2 eyes subsequently developed centrally located MH postoperatively; the authors postulated that ILM peeling may have resulted in Müller cell trauma, glial structural damage, and subsequent development of full-thickness MH.<sup>11</sup> Second, the MH widest widths of the two current cases were remarkably different, at 53 and 763  $\mu\text{m}$ . While MH closure can be achieved with or without ILM removal,<sup>11,12</sup> it is still unclear precisely which patients may benefit from ILM removal. Similarly, the current series does not define which patients may, and which may not, achieve MH closure without returning to the operating room. Larger series are needed to better understand which patients may benefit from the less invasive procedure described in the current series and still achieve similar MH closure rates as could be achieved by returning to the operating room.

Pneumatic retinopexy for RRD repair typically involves injection of less than 0.6 cc of C3F8. Because C3F8 is expected to expand approximately 4-fold over 48–72 hours, injection of 1 cc C3F8 has been reported to cause severe IOP elevation.<sup>13</sup> However, these reports focus on the experiences of eyes with formed vitreous where there may be limited volume for gas to expand. In comparison, within an eye that has undergone PPV, the aqueous filling the vitreous cavity can theoretically readily egress from the eye through the anterior chamber angle while the patient is in a prone position and the apex of the gas is at the macula.

## 4. Conclusion

The current two cases illustrate the successful management of MH, which formed following PPV, with intravitreal injection of 100% C3F8 gas with one week of face down positioning. Office-based intravitreal gas injection may be a viable clinical approach to consider that may have advantages over repeat PPV.



**Fig. 2.** Optical coherence tomography line-scans of Patient 2 at time of presentation with optic pit-associated maculopathy (A), at time of full thickness macular hole (MH) diagnosis measuring 763  $\mu\text{m}$  in widest width one month following pars plana vitrectomy and internal limiting membrane peeling (B), one week post-0.85 cc 100% C3F8 gas intravitreal injection demonstrating MH closure (C), and two years post-successful MH closure (D).

## Patient consents

Consent to publish the case series was not obtained due to an existing institutional review board approval for retrospective analyses. This report does not contain any personal information that could lead to the identification of the patient.

## Institutional review board

Institutional review board approval (Houston Methodist Hospital) was obtained.

## Acknowledgements and disclosures

The data discussed in the current manuscript has not been presented at any meetings or conferences.

## Financial support

No funding or grant support.

## Authorship

All authors attest that they meet the current ICMJE criteria for authorship. Acknowledgements  
None.

## Conflicts of interest

All authors have no financial disclosures: MAA, SURL, TPW, CRH, CCW.

## Appendix A. Supplementary data

Supplementary data to this article can be found online at <https://doi.org/10.1016/j.ajoc.2019.100492>.

## References

- Gass JDM. Reappraisal of biomicroscopic classification of stages of development of a macular hole. *Am J Ophthalmol.* 1995;119(6):752–759. [https://doi.org/10.1016/s0002-9394\(14\)72781-3](https://doi.org/10.1016/s0002-9394(14)72781-3).
- Fabian ID, Moisseiev E, Moisseiev J, Moroz I, Barak A, Alhalel A. Macular hole after vitrectomy for primary rhegmatogenous retinal detachment. *Retina.* 2012;32(3):511–519. <https://doi.org/10.1097/iae.0b013e31821f5d81>.
- Khurana RN, Wykoff CC, Bansal AS, et al. The association of epiretinal membrane with macular hole formation after rhegmatogenous retinal detachment repair. *Retina.* 2017;37(6):1073–1078. <https://doi.org/10.1097/iae.0000000000001307>.
- Schlenker MB, Lam W-C, Devenyi RG, Kertes PJ. Understanding macular holes that develop after repair of retinal detachment. *Can J Ophthalmol.* 2012;47(5):435–441. <https://doi.org/10.1016/j.jcjo.2012.05.001>.
- Benzerroug M, Genevois O, Siahmed K, Nasser Z, Muraine M, Brasseur G. Results of surgery on macular holes that develop after rhegmatogenous retinal detachment. *Br J Ophthalmol.* 2008;92(2):217–219. <https://doi.org/10.1136/bjo.2007.122796>.
- Kumagai K, Ogino N, Furukawa M, Larson E, Uemura A. Surgical outcomes for patients who develop macular holes after pars plana vitrectomy. *Am J of Ophthalmol.* 2008;145(6):1077–1080. <https://doi.org/10.1016/j.ajo.2008.01.030>.
- Moshfeghi AA, Salam GA, Deramo VA, et al. Management of macular holes that develop after retinal detachment repair. *Am J Ophthalmol.* 2003;136(5):895–899. [https://doi.org/10.1016/s0002-9394\(03\)00572-5](https://doi.org/10.1016/s0002-9394(03)00572-5).
- Gupta B, Mchugh D. Pneumatic retinopexy for the management of impending macular hole: an optical coherence tomography study. *Int Ophthalmol.* 2010;31(1):23–24. <https://doi.org/10.1007/s10792-010-9364-1>.
- Chen F-T, Yeh P-T, Lin C-P, Chen M-S, Yang C-H, Yang C-M. Intravitreal gas injection for macular hole with localized retinal detachment in highly myopic patients. *Acta Ophthalmol.* 2011;89(2):172–178. <https://doi.org/10.1111/j.1755-3768.2009.01649.x>.
- Chen T-C, Yang C-H, Yang C-M. Intravitreal expansile gas in the treatment of early macular hole: reappraisal. *Ophthalmologica.* 2012;228(3):159–166. <https://doi.org/10.1159/000337840>.
- Rush RB, Simunovic MP, Aragon AV, Ysasaga JE. Postoperative macular hole formation after vitrectomy with internal limiting membrane peeling for the treatment of epiretinal membrane. *Retina.* 2014;34(5):890–896. <https://doi.org/10.1097/iae.000000000000034>.
- Michalewska Z, Michalewski J, Adelman RA, Nawrocki J. Inverted internal limiting membrane flap technique for large macular holes. *Ophthalmology.* 2010;117(10):2018–2025. <https://doi.org/10.1016/j.ophtha.2010.02.011>.
- Gedde SJ. Management of glaucoma after retinal detachment surgery. *Current Op in Ophthalmol.* 2002;13(2):103–109. <https://doi.org/10.1097/00055735-200204000-00009>.