

Therapeutic effect of enterprise stent-assisted embolization for very small ruptured intracranial aneurysms

Feiyun Qin, MD, Zhenbao Li, MD*, Xinggen Fang, PhD, Xintong Zhao, PhD, Jiaqiang Liu, MD, Degang Wu, MD, Niansheng Lai, MD

Abstract

Enterprise stent has been widespread used in wide-necked intracranial aneurysms and good efficacy has been achieved, but there are few reports on its applications in very small ruptured intracranial aneurysms in literatures. This study aimed to evaluate the safety and efficacy of Enterprise stent-assisted coiling embolization of very small ruptured intracranial aneurysms.

We retrospectively reviewed the clinical and imaging data from 37 patients with very small ruptured intracranial aneurysms who had SAC using Enterprise stents performed from February 2012 to July 2016 in our department. Data collected and analyzed included patient demographics, morphologic features of the aneurysm, treatment results, and follow-up results. Clinical outcomes were evaluated by the Glasgow Outcome Scale (GOS).

Enterprise stents were successfully implanted in all 37 patients with very small ruptured intracranial aneurysms. Of the 37 individuals, 28 patients exhibited complete occlusion at Raymond grade I, 5 patients exhibited occlusion at Raymond grade II, and 4 patients at Raymond grade III. Procedure-related complications occurred in 3 of 37 patients (8.1%), including 1 case of intraprocedure aneurysm rupture who died from cerebral herniation caused by severe postoperative cerebral ischemia during the hospital stay, and the other 2 complications were acute in-stent thrombosis, and occlusion of parent artery caused by falling-off internal carotid artery plaque, respectively. A total of 36 patients underwent postoperative clinical follow-up visits for 6 to 24 months of which 31 patients recovered (GOS \geq 4). One patient had hemiplegic paralysis, and no rehemorrhage was found. A total of 25 patients underwent follow-up digital subtraction angiography (DSA) at 3–21 months postintervention, in whom there were 22 cases with complete occlusion, 2 cases with recurrence of aneurysm neck, and 1 case with in-stent restenosis, but there was no patient with neurologic deficits.

The Enterprise stent-assisted coiling embolization can be a safe and effective technique for treatment of very small ruptured intracranial aneurysms.

Abbreviations: DSA = digital subtraction angiography, GOS = Glasgow Outcome Scale, IPR = intraprocedure rupture, ISAT = International subarachnoid aneurysm trial.

Keywords: embolization, endovascular treatment, Enterprise stent, ruptured, very small intracranial aneurysms

1. Introduction

At present, there is still no clear definition of very small aneurysms. Generally, the intracranial aneurysm with a maximum diameter no more than 3 mm is called very small aneurysms.^[1] With the development of imaging technology, especially the widespread use of 3-dimensional (3D) cerebral angiography, tiny aneurysms with the maximum diameter \leq 3 mm have no longer been rare clinically.^[2] Because these aneurysms has small lumen and thin wall, and most aneurysms are wide-necked, both surgical clipping and endovascular

treatment are very difficult. International subarachnoid aneurysm trial (ISAT)^[3] has established the position of endovascular treatment in ruptured intracranial aneurysms, but this study has not included the very small intracranial aneurysms. There are still challenges for the treatment of these aneurysms.

In addition, the stent-assisted embolization technique has been widely used for endovascular treatment of wide-necked intracranial aneurysms. The stent can prevent spring coil into the parent artery, increase the embolization rate of aneurysm, and reduce postoperative aneurysm recanalization effectively.^[4] Several studies have reported the application of Enterprise stents to endovascular treatment of wide-necked intracranial aneurysm, and confirmed its safety and therapeutic efficacy.^[5–7] However, its application in endovascular treatment of ruptured very small aneurysms has not yet been reported. This study retrospectively analyzed the clinical and imaging data of 37 patients using Enterprise stent-assisted coiling embolization of ruptured very small intracranial aneurysms, aiming to evaluate the safety and efficacy of Enterprise stent in endovascular treatment of ruptured very small intracranial aneurysms.

2. Materials and methods

2.1. Study objects

This study has been approved by the Ethics Committee of Yijishan Hospital. Informed consent has been signed by each

Editor: Bappaditya Ray.

The authors have no funding and conflicts of interest to disclose.

Department of Neurosurgery, Yijishan Hospital, Wannan Medical College, Wuhu, China.

* Correspondence: Zhenbao Li, Department of Neurosurgery, Yijishan Hospital, Wannan Medical College, Wuhu, China (e-mail: lizhenbaowuhu@163.com).

Copyright © 2017 the Author(s). Published by Wolters Kluwer Health, Inc. This is an open access article distributed under the Creative Commons Attribution-NoDerivatives License 4.0, which allows for redistribution, commercial and non-commercial, as long as it is passed along unchanged and in whole, with credit to the author.

Medicine (2017) 96:34(e7832)

Received: 23 January 2017 / Received in final form: 29 July 2017 / Accepted: 1 August 2017

<http://dx.doi.org/10.1097/MD.0000000000007832>

patient. A total of 37 patients with ruptured very small intracranial aneurysms who had SAC using Enterprise stent-assisted coiling embolization from February 2012 to July 2016 in our department were included. All patients had clinical manifestations of spontaneous subarachnoid hemorrhage, which were confirmed by cranial CT. They were confirmed to have microintracranial wide-necked aneurysms (maximum diameter ≤ 3 mm) by DSA, including 14 cases of anterior communicating aneurysm, 12 cases of posterior communicating aneurysm, 4 cases of middle cerebral aneurysm, 4 cases of ophthalmic aneurysm, 2 cases of A1 segment aneurysm of anterior cerebral artery, and 1 case of bifurcation aneurysm of internal carotid artery. The average diameter of aneurysm was 2.1 ± 0.5 mm (diameter range was 1.6–3.0 mm). These 37 patients included 15 males and 22 females, aged from 26 to 77 years old (averagely 52 ± 7.8 years old). Hunt–Hess grading showed 15 cases of grade H-H 1, 8 cases of grade 2, 8 cases of grade 3, and 6 cases of grade 4.

Inclusion criteria included: (1) A patient was confirmed by cranial CT to have manifestations of subarachnoid hemorrhage, and the hemorrhage site was corresponding to the position of aneurysm; (2) a patient was confirmed by DSA to have very small intracranial aneurysms (maximum diameter ≤ 3 mm, Hunt–Hess grade I–IV); (3) a patient received Enterprise stent-assisted coiling embolization. Exclusion criteria included: (1) the patient had no history of subarachnoid hemorrhage; (2) the hemorrhage site was not consistent with the position of aneurysm; (3) the patient received non-Enterprise stent assisted embolization, such as surgical clipping, simple coil embolization, and so on.

2.2. Treatment methods

All procedures were performed with the patients under general anesthesia and were systemically heparinized during surgery. A 6-F arterial sheath (Terumo Holding Co. Ltd., Tokyo, Japan) was inserted following a puncture to the femoral using the Seldinger technique. Routine DSA with 3D was performed for each patient to evaluate the aneurysm size and the proximal and distal diameters of the parent arteries, in order to clearly determine the anatomical association between the aneurysm and the parent artery and the branches. Based on the DSA results, the appropriate surgical approach, operating angle, coil, and stent were selected for each patient. A 6F ENVOY guiding catheter (Cordis Neurovascular, Inc., Miami Lakes, FL) was inserted into the internal carotid artery at the level of the second cervical vertebra. A Select Plus microcatheter was conducted through a microwire and positioned in the parent artery past the aneurysm neck. The Enterprise stent was advanced through the Select Plus microcatheter and placed at the cephalic end of the microcatheter; however, the stent was not released. An Echelon 10 microcatheter (eV3 Endovascular, Inc.) with a very small shaped tip was inserted into the aneurysmal sac or neck. Aneurysmal coiling was performed using an Axiom 3D coil (eV3 Endovascular, Inc.) of appropriate diameter and length. After 1 or 2 coil loops were released to fill the aneurysmal cavity, the stent was slowly released, and the release was stopped after the microcatheter was fixed and the coil did not pulsate. The aneurysmal cavity was continuously filled with the coil until 1–2 cm of the coil remained inside the parent artery. The microcatheter was removed after the guidewire-achieved stability. After the position of the coil was stabilized, the stent was completely released and the coil was isolated.

All patients received 300 mg aspirin and 300 mg Plavix (Sanofi Winthrop, Paris, France) orally or intragastrically prior

to the intervention. Following the intervention, patients were treated with 100 mg of Aspirin and 75 mg Plavix per day. Plavix administration was terminated after 6 weeks, whereas aspirin was given for longtime. A lumbar puncture was performed daily, starting on the first day after the intervention, until no blood was observed in the cerebrospinal fluid. For patients with acute hydrocephalus, routine ventricular drainage was performed.

2.3. Postoperative evaluation and follow-up methods

The degree of occlusion was evaluated immediately post-intervention. Occlusion degree was graded according to the modified Raymond scale^[8] as follows: Grade I, complete occlusion (no contrast agents observed in the aneurysm); grade II, neck remnant (contrast agents observed in the aneurysmal neck); grade III, partial occlusion (contrast agents observed in the aneurysmal cavity). All patients underwent clinical follow-up via telephone and hospital visits at 1, 6, 12, and 24 months following the intervention. Patients underwent a follow-up DSA at 3, 9, and 21 months after the intervention. Clinical outcome was evaluated according to the Glasgow Outcome Scale (GOS): 1 score (death), 2 scores (no response, being unable to respond to external environment), 3 scores (being able to move as ordered, but being unable to live independently), 4 scores (being able to live independently, but unable to return to work or go to school), 5 scores (being able to return to work or go to school). The patient with $GOS \geq 4$ was defined to have a good clinical outcome, and that with $GOS \leq 3$ was defined to have a poor clinical outcome.

3. Results

3.1. Surgical outcome

All patients underwent 3D-DSA immediately following the surgery (Figs. 1 and 2), and the degree of occlusion was evaluated according to the Raymond scale. A total of 37 patients with ruptured very small intracranial aneurysms all successfully received Enterprise stent-assisted coiling embolization. At the end of the embolization, immediate postoperative DSA showed that complete occlusion was achieved in 28 cases (75.6%), subtotal occlusion (neck remnant) was achieved in 5 cases (13.6%), and partial occlusion (contrast agent mildly filled the body of aneurysm) in 4 cases (10.8%).

3.2. Complications

Procedure-related complications appeared in a total of 3 patients (8.1%). One patient experienced intra-procedure rupture of aneurysm, who was given immediate protamine, blood pressure control, and rapid coil filling, and then the hemorrhage was stopped. However, at the second day after surgery, this patient died from cerebral herniation caused by severe postoperative cerebral ischemia, and the mortality rate was 2.7%. The second case had acute in-stent thrombosis, which disappeared after giving tirofiban for rapid thrombolysis. This patient did not show any neurologic deficits after the procedure, and the 2-year clinical follow-up was uneventful. The third patient had occlusion of distal middle cerebral artery caused by falling-off internal carotid artery plaque, which was not obviously improved after giving tirofiban for thrombolysis who had hemiplegia on one side of the limb, and the morbidity was 2.7%, too.

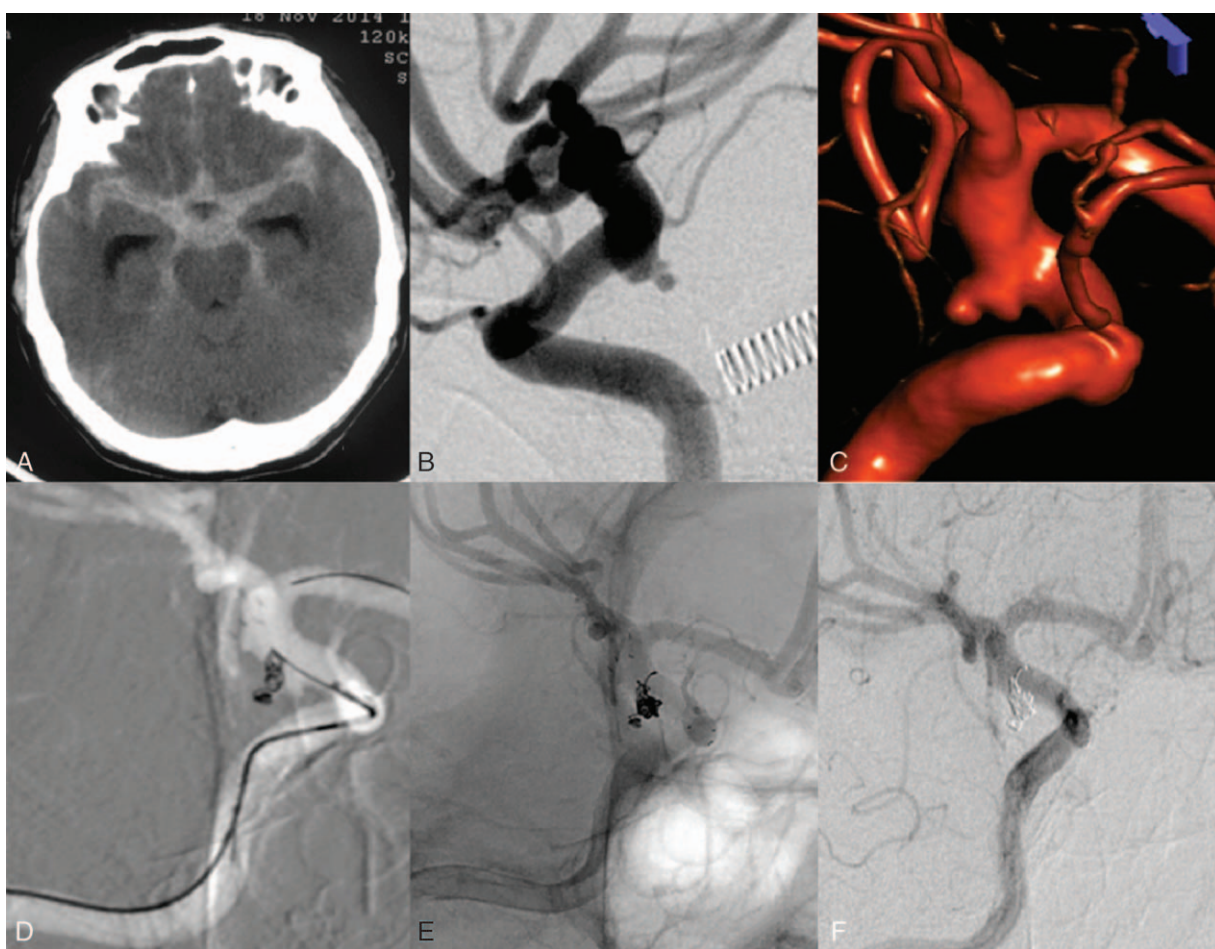


Figure 1. Images before and after Enterprise stent-assisted coiling embolization in a 65-year-old male that presented with a sudden headache and was hospitalized due to the onset of spontaneous subarachnoid hemorrhage. (A) Cranial CT on admission indicated: subarachnoid hemorrhage. (B and C) DSA images show a very small aneurysm in the right posterior communicating artery with a vesicle on the top. (D) The procedure of the enterprise stent assisted-coil embolization with the stent semi-released technique. An Enterprise-stent (4.5 × 22 mm) was placed in the parent artery past the aneurysm neck, and the coils (1 Complex coil and 3 hypersoft coils) were under the stent in the parent artery. (E) Postoperative immediate DSA images show that the degree of the occlusion was Raymond grade I. (F) 3 months after the intervention, the DSA follow-up indicated dense coil packing in the aneurysm (Raymond grade I), and the parent was patent without any stenosis. CT = computed tomography, DSA = digital subtraction angiography.

3.3. Follow-up outcome

After surgery, 36 patients underwent clinical follow-up for 6 to 24 months (mean: 10 ± 5.6). Among them, 22, 9, 3, and 2 patients had GOS score of 5, 4, 3, and 2, respectively. One patient had unilateral hemiplegia, and there was no rehemorrhage patient. Twenty-five patients received a DSA follow-up for 3 to 21 months after the intervention, of which 22 patients (88.0%) achieved complete occlusion at Raymond grade I and 3 patients at grade II. After surgery, there were 2 cases with aneurysmal neck recanalization, which was not given retreatment because of the slight degree of recanalization. One patient suffered from in-stent stenosis, without obvious clinical symptoms (Table 1).

4. Discussion

At present, there are many types of stents used in endovascular treatment of wide-necked intracranial aneurysms, including Neuroform, Leo (Light-emitting diode), Solitaire, Enterprise stents, and so on. Many stent deployment techniques have been developed for intracranial aneurysms, including the microcatheter through stent mesh, jailing, semi-releasing, stent after coiling, stent implantation for salvage, Y-stenting and single- or

multiple-stenting techniques, etc. Enterprise stent is a laser-cut self-expandable nitinol stent with a fixed closed-cell low-profile design, which was developed by Cordis Company in 2007. This stent has a higher flexibility without the need for positioning a microguidewire far distal in the cerebral vessels, which can pass through the tortuous intracranial circulation easily. It adopts a closed-cell design, with good radial support force, and this stent is characterized by partial retrievability, that is, it is retrievable and re-implantable if its total release length is not more than 70%.

With the application of high-resolution imaging equipment, especially clinical popularization of 3D cerebral angiography technique, the diagnosis rate and detection rate of very small intracranial aneurysms (maximal diameter ≤ 3 mm) become higher. Gupta et al^[9] reported that the tiny aneurysms accounted for 7% of all ruptured aneurysms. There is still controversy on whether unruptured very small aneurysms need treatment, but at present it is universally recognized that it is necessary to provide treatment for ruptured very small aneurysms. However, because these aneurysms have a thin wall and parent arteries typically exhibit a thick wall with calcification, during the clipping of very small aneurysms, the aneurysmal neck may easily break.^[1] Most patients may be less willing to accept the microsurgical clipping

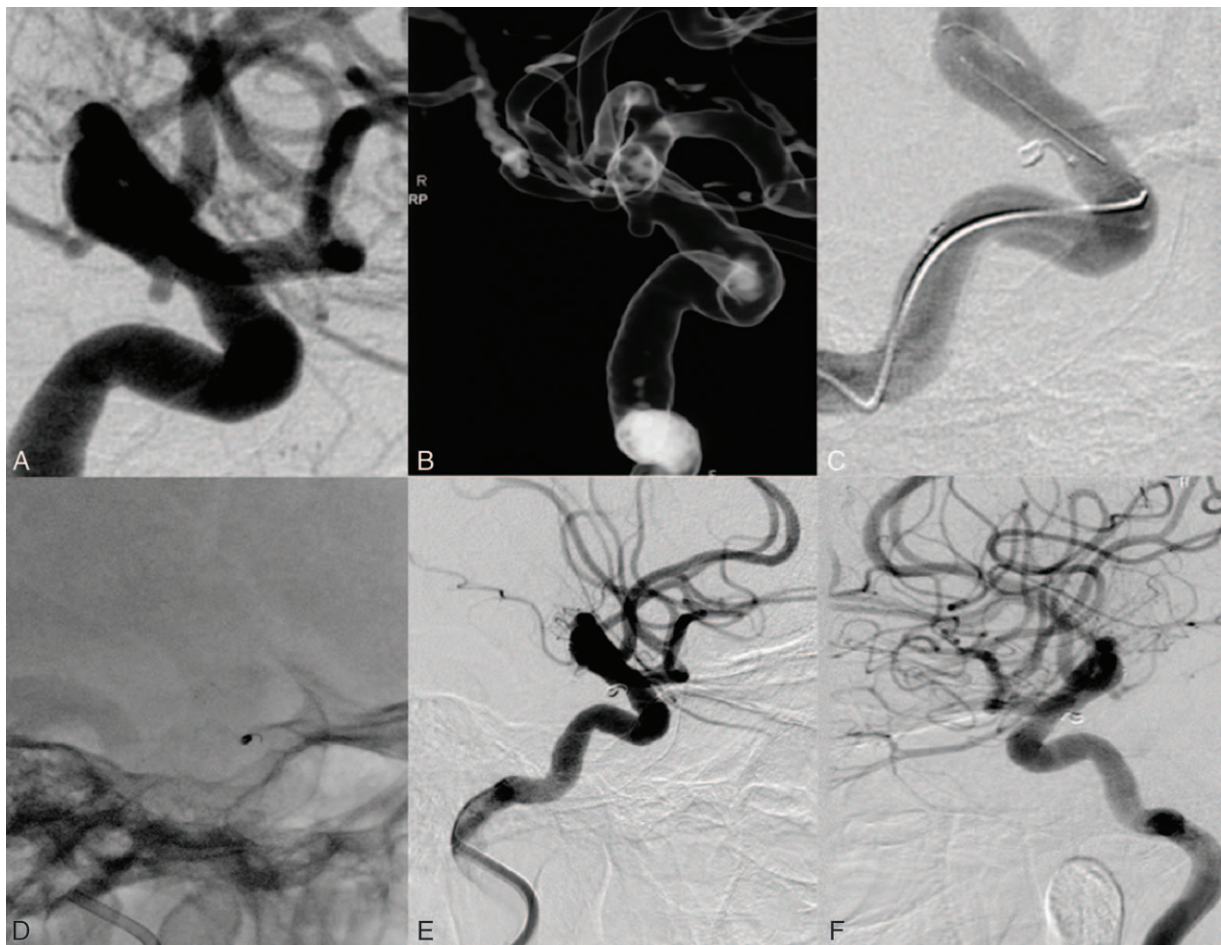


Figure 2. Images before and after Enterprise stent-assisted coiling embolization in a 63-year-old female that presented with a sudden headache and vomiting, and was hospitalized due to the onset of spontaneous subarachnoid hemorrhage. (A and B) DSA images show a very small aneurysm in the left ophthalmic artery segments of the internal carotid artery. (C) The procedure of the enterprise stent-assisted coil embolization with the stent semi-released technique. An enterprise-stent (4.5×22 mm) was placed in the parent artery past the aneurysm neck, and the coils (1 AXIUM 3D coil, $1.5 \text{ mm}/2 \text{ cm}$) were under the stent in the parent artery. (D) Fluoroscopic image presented clear marks on the spring coil and stent. (E) Postoperative immediate DSA images show that the degree of the occlusion was Raymond grade I. (F) 6 months after the intervention, the DSA follow-up indicated dense coil packing in the aneurysm (Raymond grade I), and the parent was patent without any stenosis. DSA = digital subtraction angiography.

treatment because of severe trauma. In our center, due to the mature technology and small trauma, most of the patients chose the endovascular treatment. Of course, some patients were still using surgical clip treatment, according to their individual situation.

Intra-procedure rupture (IPR) is the most severe complication in endovascular treatment of very small aneurysms, with high mortality and morbidity rates. The IPR rate of very small aneurysms was more than 2 times (7.7%) and 5 times (11.7%) higher respectively than that of larger aneurysm (Van Rooij et al^[10] and Nguyen et al^[11]). At the same time, compared with unruptured aneurysms, the intra-procedure re-rupture rate of ruptured aneurysms is higher.^[12] Ji et al^[13] used stent-assisted embolization for 56 cases of ruptured very small intracranial aneurysms, and the IPR rate was 7.1%. A multi-center study conducted by Mocco et al^[14] indicated that Enterprise stent for the treatment of ruptured intracranial aneurysms showed a higher mortality rate (12.5%, 2/16), so they believed caution should be taken in the treatment of ruptured intracranial aneurysms with Enterprise stent. In this study, only 1 patient (3.3%) had intra-procedure rupture, and the hemorrhage stopped by giving protamine to neutralize heparin, controlling

blood pressure, and rapid embolization with the coils. However, on the 2nd day after the intervention, the patient died from cerebral herniation caused by severe brain swelling. Compared with the above studies, the IPR rate and mortality rates in this study was low, which, as we believed, were correlated to the following technical factors.

Good microcatheter shaping is the premise for a successful embolization. Good microcatheter shaping can reduce the manipulation of the head of microguide wire and reduce the risk of aneurysm puncture by the microguide wire. It is also very important to select proper spring coils according to the size and shape of aneurysm. Generally, a 3D coil is the first choice, with the diameter equal to or slightly less than the diameter of the aneurysm. This size facilitates the coil to form a basket, and the coils may not roll in the sac of aneurysm at the same time. When the stent was released, the pressure against the aneurysm wall might be small and reduce the risk of IPR. If the coil is not suitable during the surgery, it shall be absolutely given up and changed to a proper one. On the premise of safety embolization, we do not pursue complete occlusion too much. Kim and Ko^[15] believed that when the stent-assisted coil embolization technique is used for the treatment of very small intracranial aneurysms, even if the

Table 1**Enterprise stent-assisted embolization for 37 cases of ruptured very small intracranial aneurysms.**

Patient no	Gender/age	Hunt-Hess grading	Position of aneurysms	Size mm	Aneurysmal neck mm	Intraoperative complications	Immediate radiography (mRS)	Radiology at follow-ups	Clinical outcome (GOS)
1	F/45	2	Anterior cerebral	1.6 × 2	2	NO	1	1	5
2	F/54	3	Posterior communicating	2.3 × 2.8	2.8	NO	1	NO	5
3	F/49	1	Posterior communicating	2.2 × 2.4	2.1	NO	1	1	5
4	M/73	4	Anterior communicating	1.4 × 1.5	2	NO	1	1	4
5	M/71	2	Anterior communicating	1.5 × 1.6	2	NO	1	1	4
6	F/69	2	Posterior communicating	2.2 × 3	3	NO	3	1	5
7	F/64	4	Middle cerebral	2.8 × 3.0	3	NO	1	NO	3
8	M/26	4	Anterior communicating	2.2 × 1.3	2.3	Intra procedure rupture	1	NO	1
9	F/69	1	Anterior communicating	2.2 × 2.0	2.5	NO	1	1	5
10	F/59	3	Posterior communicating	2.1 × 1.8	1.8	NO	1	1	5
11	F/69	1	Anterior communicating	3 × 3	3	NO	1	NO	4
12	M/50	1	Posterior communicating	2.2 × 2	2.5	NO	1	NO	5
13	F/58	3	Internal carotid	2 × 2	1.3	NO	1	1	5
14	M/63	4	Posterior communicating	1.7 × 1.6	2	NO	1	NO	4
15	M/60	2	Ophthalmic artery	2.1 × 2	2	NO	1	1	5
16	M/68	3	Anterior communicating	1.6 × 1.6	1.0	NO	1	NO	2
17	F/49	3	Anterior communicating	2.5 × 2.8	2.8	NO	1	NO	5
18	F/52	2	Ophthalmic artery	1.7 × 2.1	2	NO	1	NO	5
19	F/60	3	Anterior communicating	1.9 × 1.5	1.6	NO	1	1	4
20	F/45	1	Middle cerebral	3 × 2.7	2.9	NO	1	1	5
21	F/77	2	Middle cerebral	2.7 × 2.1	2.4	Occlusion of parent artery	1	1	3
22	M/46	3	Anterior communicating	1.8 × 1.9	2.1	NO	3	NO	5
23	F/68	2	Ophthalmic artery	2.1 × 1.3	1.8	NO	3	1	5
24	F/69	1	Posterior communicating	2.9 × 1.9	2	NO	1	Recanalization of the aneurysmal neck	4
25	M/64	1	Anterior communicating	2.6 × 2.8	2.2	NO	2	No change	5
26	M/51	3	Anterior communicating	2 × 2.6	1.8	NO	1	Relapse of the aneurysmal neck	5
27	F/41	1	Posterior communicating	1.4 × 2.7	2	NO	1	In stent stenosis	3
28	F/44	4	Posterior communicating	3.0 × 2.5	3	NO	1	NO	4
29	M/47	1	Anterior communicating	1.8 × 2.7	2.5	NO	1	NO	5
30	M/61	1	Posterior communicating	1.5 × 2.1	3	In stent thrombosis	1	1	2
31	F/46	2	Anterior cerebral	2.3 × 1.2	2	NO	3	1	5
32	M/65	1	Posterior communicating	2 × 2	2.5	NO	1	1	5
33	F/61	1	Ophthalmic artery	2.1 × 1.9	1.6	NO	1	1	5
34	F/67	2	Anterior communicating	2.4 × 2.6	1.8	NO	2	1	5
35	M/53	3	Posterior communicating	2.2 × 1.9	2.1	NO	2	1	4
36	F/67	4	Middle cerebral	1.7 × 1.6	1.5	NO	1	1	5
37	M/58	1	Anterior communicating	2.1 × 1.4	1.3	NO	1	1	4

GOS=Glasgow Outcome Scale.

aneurysm is not completely embolized or only the aneurysmal neck is covered by the stent due to limited aneurysm cavity, the healing of the aneurysmal neck can still be promoted. A single-centered study by Peng et al^[16] proved that the use of Enterprise stent-assisted embolization for very small aneurysms was able to achieve a very high progressive and complete occlusion rates. In most patients, incomplete or partial occlusion developed into complete occlusion at follow-ups.^[16] The technical and physiological properties of the Enterprise stent itself might lead to the high rate of progressive occlusion.^[16] The Enterprise stent, with the mechanical, hemodynamic, and biological benefits, may also promote progressive thrombosis and offer scaffolding for the parent arterial intimal layer reconstruction at the aneurysm neck. In this study, postoperative immediate DSA images of 4 cases with very small aneurysms showed partial occlusion, which all evolved to complete occlusion in the DSA follow-up. Therefore, the use of Enterprise stent-assisted coil embolization for very small aneurysms is able to achieve a good clinical outcome even in the case of initial partial occlusion, and pursuing complete occlusion too much may increase the risk of aneurysm rupture.

At present, there is still controversy on whether to use stent for the ruptured aneurysms in the acute stage (≤ 3 d), because the patient with acute subarachnoid hemorrhage is in a high coagulation state, and the use of stent-assisted embolization may increase the occurrence rate of thrombotic event. According to some studies, the occurrence rate of thrombosis in the coiling embolization aneurysm procedure was 1% to 17%, which is mainly related to the heterogeneity of coil and stent, long duration of implantation process, intima-injury of the vessel in implantation, insufficiency of anticoagulation or anti-platelet aggregation or activation of coagulation system, and so on. Yang et al^[17] used stent-assisted embolization for ruptured intracranial aneurysm, and the incidence of intra-procedure thrombosis was 8.1%. According to a systematic evaluation by Rhu et al,^[18] the incidence of thrombus in the stent-assisted embolization for ruptured intracranial aneurysm was 11.2%. According to a meta analysis of 1105 cases of endovascular treatment of very small aneurysms by Yamaki et al,^[19] the incidence of thrombosis in stent-assisted embolization for ruptured tiny aneurysms was 13%. Compared with the above studies, only 1 patient (2.7%) in this study had intra-procedure thrombosis, which relieved after giving Tirofiban for rapid

thrombolysis, so the occurrence rate of thrombus event was low. We believed this might be related to the following reasons.

The Enterprise stent is a laser-cut stent, with smooth surface and good flexibility, and it causes less injury to vascular intima. Chen et al.^[20] used Enterprise stent and Solitaire stent-assisted embolization for 77 cases of wide-necked intracranial aneurysm, and they found that the incidence of acute thrombosis in the use of Solitaire stent was higher (26.6% vs 1.8%, $P < .05$). Chung et al.^[21] reported a study that using Enterprise and Neuroform stent-assisted embolization of 71 patients with ruptured wide-necked intracranial aneurysms; they found that Neuroform stent-assisted embolization showed a higher incidence of thrombosis, up to 22.7% significantly higher than that of Enterprise stent group (8.2%).^[22] In this study, because Enterprise stent has partial retrievability and can be retrieved and repositioned when the deploying rate is no more than 70%, so we used the stent semi-releasing or post-releasing technique to embolism the aneurysms. Compared with the microcatheter through the stent mesh technique, the semi-releasing or post-releasing techniques reduces the navigation time, resulting in quicker packing and lower the incidence of thromboembolic events.^[21] The coil used for endovascular treatment of very small aneurysm usually has small diameter (sometimes even merely 1 mm), but Enterprise stent has relative large stent mesh; therefore, the coil may protrude into the parent artery from stent mesh and caused the thrombosis event. Therefore, we usually left a small section of the coil in the parent artery, which is compressed onto the parent artery wall by the stent, to prevent the coil protrude into the parent artery and subsequent cerebral ischemia. By using this technique, there was no case which experienced the coil protruding into the parent artery in this study.

In conclusion, the Enterprise stent-assisted coiling embolization can be a safe and effective technique for treatment of very small ruptured intracranial aneurysms. However, there are several limitations in this study. First, this study is a retrospective study, and random grouping was not carried out and there was no control group. Second, as the sample size was small and the follow-up period was not long, larger sample size and longer follow-up period were needed to acquire the long-term efficacy of the Enterprise stent-assisted embolization for very small ruptured intracranial aneurysms.

References

- [1] Zhang HQ. Is it necessary to treat the mini unruptured intracranial aneurysms? *Chin J Cerebrovasc Dis* 2013;10:1–3.
- [2] van Rooij WJ, Sprengers ME, de Gast AN, et al. 3D rotational angiography: the new gold standard in the detection of additional intracranial aneurysms. *AJNR Am J Neuroradiol* 2008;29:976–9.
- [3] Molyneux A, Kerr R, Stratton I, et al. International Subarachnoid Aneurysm Trial (ISAT) of neurosurgical clipping versus endovascular coiling in 2143 patients with ruptured intracranial aneurysms: a randomised trial. *Lancet* 2002;360:1267–74.
- [4] Phan K, Huo YR, Jia F, et al. Meta-analysis of stent-assisted coiling versus coiling-only for the treatment of intracranial aneurysms. *J Clin Neurosci* 2016;31:15–22.
- [5] Hwang SK, Hwang G, Bang JS, et al. Endovascular Enterprise stent-assisted coil embolization for wide-necked unruptured intracranial aneurysms. *J Clin Neurosci* 2013;20:1276–9.
- [6] Jia J, Lv X, Liu A, et al. Enterprise stent-assisted coiling of wide-necked intracranial aneurysms: clinical and angiographic follow-up. *Interv Neuroradiol* 2012;18:426–31.
- [7] Lv X, Li Y, Xinjian Y, et al. Results of endovascular treatment for intracranial wide-necked saccular and dissecting aneurysms using the Enterprise stent: a single center experience. *Eur J Radiol* 2012;81:1179–83.
- [8] Raymond J, Guilbert F, Weill A, et al. Long-term angiographic recurrences after selective endovascular treatment of aneurysms with detachable coils. *Stroke* 2003;34:1398–403.
- [9] Gupta V, Chugh M, Jha AN, et al. Coil embolization of very small (2 mm or smaller) berry aneurysms: feasibility and technical issues. *AJNR Am J Neuroradiol* 2009;30:308–14.
- [10] van Rooij WJ, Keeren GJ, Peluso JP, et al. Clinical and angiographic results of coiling of 196 very small (< or = 3 mm) intracranial aneurysms. *AJNR Am J Neuroradiol* 2009;30:835–9.
- [11] Nguyen TN, Raymond J, Guilbert F, et al. Association of endovascular therapy of very small ruptured aneurysms with higher rates of procedure-related rupture. *J Neurosurg* 2008;108:1088–92.
- [12] Ng P, Khangure MS, Phatouros CC, et al. Endovascular treatment of intracranial aneurysms with Guglielmi detachable coils: analysis of midterm angiographic and clinical outcomes. *Stroke* 2002;33:210–7.
- [13] Ji W, Kang H, Liu A, et al. Stent-assisted coiling of very small wide-necked intracranial aneurysms: Complications, anatomical results and clinical outcomes. *Neurol Neurochir Pol* 2016;50:410–7.
- [14] Mocco J, Snyder KV, Albuquerque FC, et al. Treatment of intracranial aneurysms with the Enterprise stent: a multicenter registry. *J Neurosurg* 2009;110:35–9.
- [15] Kim YJ, Ko JH. Sole stenting with large cell stents for very small ruptured intracranial aneurysms. *Interv Neuroradiol* 2014;20:45–53.
- [16] Peng T, Qian Z, Liu A, et al. Progressive occlusion of enterprise stent-assisted coiling of ruptured wide-necked intracranial aneurysms and related factors on angiographic follow-up: a single-center experience with 468 patients. *PLoS One* 2014;9:e92407.
- [17] Yang P, Zhao K, Zhou Y, et al. Stent-assisted coil placement for the treatment of 211 acutely ruptured wide-necked intracranial aneurysms: a single-center 11-year experience. *Radiology* 2015;276:545–52.
- [18] Ryu CW, Park S, Koh JS, et al. Complications in stent-assisted endovascular therapy of ruptured intracranial aneurysms and relevance to antiplatelet administration: a systematic review. *AJNR Am J Neuroradiol* 2015;1682–8.
- [19] Yamaki VN, Brinjikji W, Murad MH, et al. Endovascular treatment of very small intracranial aneurysms: meta-analysis. *AJNR Am J Neuroradiol* 2016;37:862–7.
- [20] Chen YA, Hussain M, Zhang JY, et al. Stent-assisted coiling of cerebral aneurysms using the Enterprise and the Solitaire devices. *Neurol Res* 2014;36:461–7.
- [21] Chung J, Lim YC, Suh SH, et al. Stent-assisted coil embolization of ruptured wide-necked aneurysms in the acute period: incidence of and risk factors for periprocedural complications. *J Neurosurg* 2014;121:4–11.
- [22] Liu A, Peng T, Qian Z, et al. Enterprise stent-assisted coiling for wide-necked intracranial aneurysms during ultra-early (48 hours) subarachnoid hemorrhage: a single-center experience in 59 consecutive patients. *J Neuroradiol* 2015;42:298–303.