

# Titanium mesh bone grafting combined with pedicle screw internal fixation for treatment of Kümmell disease with cord compression

## A case report and literature review

Liangwei Mei, MD<sup>a</sup>, Wenhua Sang, MD<sup>b</sup>, Zhenzhong Chen, MD<sup>c</sup>, Chao Lou, MD<sup>c</sup>, Lin Zheng, MD<sup>c</sup>, Kangtao Jin, MD<sup>c</sup>, Wenjun Huang, MD<sup>c</sup>, Dengwei He, MD<sup>c,\*</sup>

### Abstract

**Rationale:** In 1891, Dr. Hermann Kümmell, a German surgeon, described a clinical entity characterized by the development of progressive painful kyphosis following an asymptomatic period of months or years after a minor spinal trauma, leading to a gradual collapse of the vertebra and dynamic instability, ultimately progressing to kyphosis with prolonged back pain and/or paraparesis. To date, the main pathologic eliciting event remains unclear, and no standard treatment or single effective treatment are available for Kümmell disease.

**Patient concerns:** A 74-year-old woman presented with severe back pain and numbness of both legs for approximately 2 months.

**Diagnoses:** According to the clinical symptoms and imaging examinations, the patient was diagnosed with stage III Kümmell disease.

**Interventions:** The patient underwent titanium mesh bone grafting combined with pedicle screw internal fixation.

**Outcomes:** Postoperative kyphosis was corrected, and the vertebra was reconstructed.

**Lessons:** Kümmell disease is not a rare complication of osteoporotic vertebral compression fractures, and treatment of each patient must be individualized. The application of titanium mesh bone grafting combined with pedicle screw internal fixation is an effective treatment option for stage III Kümmell disease.

**Abbreviations:** CT = computed tomography, IVC = intravertebral vacuum cleft, MRI = magnetic resonance imaging, PKP = percutaneous kyphoplasty, PVP = percutaneous vertebroplasty, VCF = vertebral compression fractures.

**Keywords:** bone graft, internal fixation, Kümmell disease, open surgery, percutaneous vertebroplasty

Editor: N/A.

*Ethical review and patient consent:* This study obtained ethics committee approval from The Fifth Affiliated Hospital of Wenzhou Medical University. Written informed consent was gained from the patient for publication of this case report and any accompanying images.

*Funding/support:* This study was financially supported by the Zhejiang Science and Technology Department Public Welfare Technology Application Research Project (Project Number: 2016KYA200) and the General Project of Zhejiang Natural Science Foundation (Project Number: Y17C100002).

The authors have no conflicts of interest to disclose.

<sup>a</sup>Department of Orthopaedic Surgery, The Fourth People's Hospital of Shanxi, Xi'an, Shanxi, <sup>b</sup>School of Basic Medical Sciences, Wenzhou Medical University, Wenzhou, <sup>c</sup>Department of Orthopaedic Surgery, The Fifth Affiliated Hospital of Wenzhou Medical University, Lishui Municipal Central Hospital, Lishui, Zhejiang, China.

\*Correspondence: Dengwei He, Department of Orthopaedic Surgery, The Fifth Affiliated Hospital of Wenzhou Medical University, Lishui Municipal Central Hospital, 289 Kuocang Road, Lishui 323000, Zhejiang, China (e-mail: 1633142088@qq.com).

Copyright © 2018 the Author(s). Published by Wolters Kluwer Health, Inc. This is an open access article distributed under the terms of the Creative Commons Attribution-Non Commercial-No Derivatives License 4.0 (CCBY-NC-ND), where it is permissible to download and share the work provided it is properly cited. The work cannot be changed in any way or used commercially without permission from the journal.

Medicine (2018) 97:36(e12183)

Received: 3 May 2018 / Accepted: 10 August 2018

<http://dx.doi.org/10.1097/MD.00000000000012183>

## 1. Introduction

Kümmell disease is a complication of vertebral compression fractures (VCFs). The disease can occur several months or even years after the initial spinal injury and is distinguished from common osteoporotic compression fractures by its delayed development. In recent years, with advances in radiological technologies, the actual disease incidence has been quite high (between 7% and 37% of VCFs), particularly among the elderly population.<sup>[1]</sup> Because the pathogenesis is unclear, multiple synonymous terms have been used to describe this pathology, including delayed posttraumatic vertebral osteonecrosis, avascular necrosis after VCF, intravertebral pseudarthrosis, intra-vertebral vacuum cleft (IVC), delayed traumatic vertebral collapse, and vertebral compression fracture nonunion.<sup>[2]</sup> For consistency, we will refer to this pathology as Kümmell disease in this article.

Kümmell disease typically manifests as an IVC and failure of the fracture healing process, for which effective conservative treatments are not available.<sup>[2]</sup> Surgical intervention is recommended. Various surgical procedures have been proposed for the management of Kümmell disease. However, the optimal surgical procedures remain controversial. The aim of this article is to report the application of titanium mesh bone grafting combined with pedicle screw internal fixation for treatment of Kümmell

disease with cord compression and discuss the surgical treatment of this clinical entity.

## 2. Case report

A 74-year-old woman with a history of cerebellar atrophy presented with severe back pain and numbness of both legs after an accidental fall 2 months prior. The pain was aggravated by activity. Her lifestyle was limited, and she was generally confined to bed. The patient's general medical examination revealed poor muscle strength, Lasegue's sign (–) on both sides, and osteoporosis with a T-score of 4.6. Both knee and ankle reflexes were present.

At another hospital, the patient underwent magnetic resonance imaging (MRI) of her thoracic and lumbar spine, which revealed a destructive lesion involving vertebral level T12 and kyphosis; the spinal canal was stenotic due to retropulsed bony fragments. On sagittal MRI, the T12 fracture exhibited low signal intensity on T1-weighted images and high intensity on T2-weighted images. Computed tomography (CT) was performed after the patient was hospitalized (Fig. 1). The patient was diagnosed with stage III Kümmell disease.

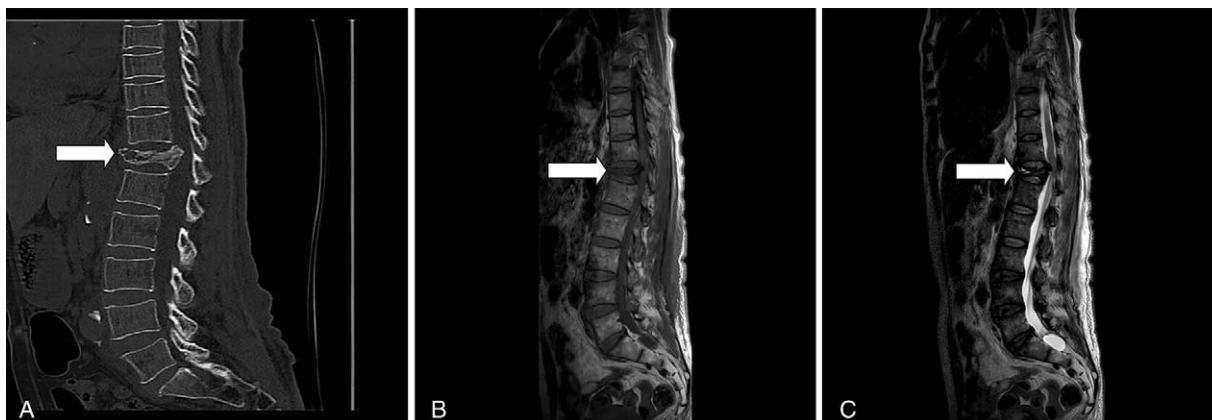The operation was performed in the prone position with general anesthesia. Good posterior exposure of the spine was achieved. Then, fenestrated pedicle screws were inserted in objective vertebrae T10, T11, L1, and L2 under C-arm guidance. A laminectomy was performed for decompression treatment. The pathologic vertebra was resected to reduce the decompression of the spinal cord followed by the placement of titanium mesh filled with autologous or allogeneic bone after the distraction. Pedicle screws were fixed and fused after reconstruction of the spine curve using a bendable titanium rod in accordance with the physiological curvature. The operation lasted 210 minutes, and the estimated total blood loss was 800 mL.

Immediately postoperation, kyphosis was corrected, and the vertebra was reconstructed (Fig. 2). One month after the operation, the patient underwent an evaluation for a comparison of the current state to the preoperative framework. A slight improvement in lower limb strength was noted. In addition, x-ray of the spine excluded mobilization of the stabilization system (Fig. 3).

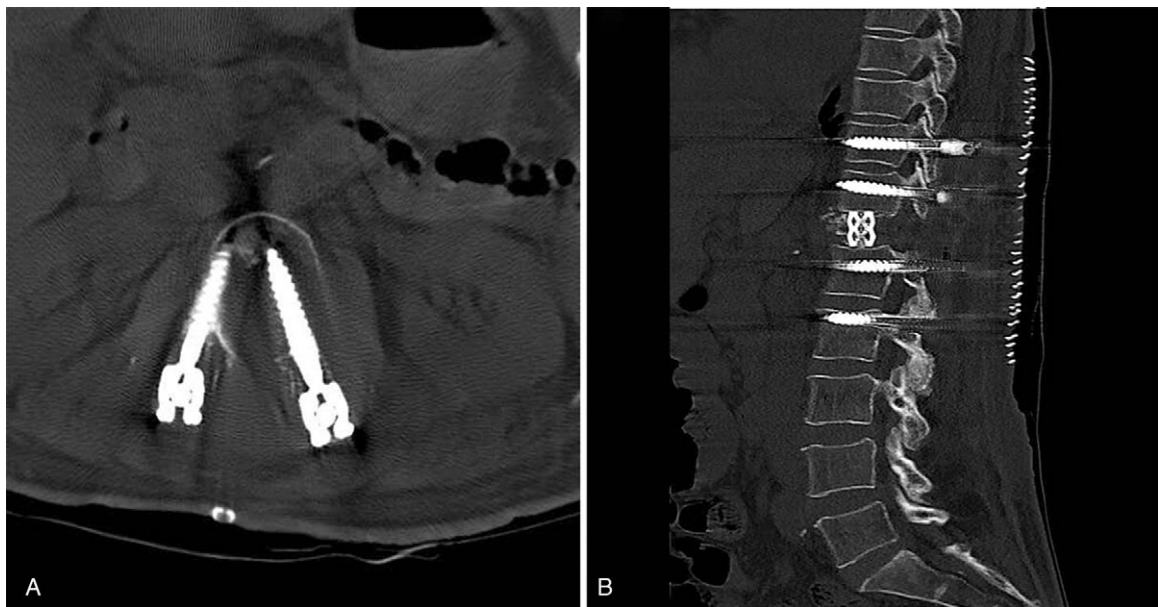
## 3. Discussion

We report a patient who presented with stage III Kümmell disease with cord compression. After titanium mesh bone grafting combined with pedicle screw internal fixation, kyphosis was corrected, and the vertebra was reconstructed. Previously, anterior column support was focused on the role of vertebroplasty or kyphoplasty as a minimally invasive surgery. Some scholars have reported that patients with stage III Kümmell disease achieved satisfactory results using vertebroplasty combined with pedicle screw internal fixation.<sup>[3,4]</sup> However, in our study, we considered several factors when deciding which treatment to use. Vertebroplasty or kyphoplasty were not attempted by the authors. Given that the surrounding vertebral cortex was already compromised in this case (Fig. 1), inserted cement could easily leak out of the vertebral body and potentially enter the spinal canal, which could be very dangerous. We chose titanium mesh to restore anterior column support, provide sufficient bone grafting, and promote vertebral bone healing. With regard to decompression methods, an anterior approach may be easier and safer, as the spinal cord is compressed by the “retropulsed” bone fragments. However, an anterior approach for problems at the thoracolumbar junction in this patient group was considered too aggressive based on factors such as old age and the presence of other medical disorders. In contrast, posterior decompression avoids the need for sectioning the diaphragm or opening either the thoracic cavity or the retroperitoneal space, both of which are inevitable with an anterior thoracolumbar approach for T12 or L1. When methods for stabilization are considered, anterior fixation is not very secure in the osteoporotic spine because the vertebral body consists mostly of cancellous bone, and the cortical bone of the vertebral body is also very thin. In contrast, posterior fixation using the pedicle screw system provides relatively stable fixation even in an osteoporotic spine because the pedicle remains a strong part of the vertebra. Based on these factors, we decided to perform posterior decompression through the pedicles and posterior stabilization using a pedicle screw system.

Titanium mesh bone grafting combined with pedicle screw internal fixation can restore the vertebral height, partially reduce bone fragments, decompress neural elements, correct the angular deformity and stabilize the spinal column. This approach



**Figure 1.** (A) CT scan of a compression fracture of T12 with an incomplete vertebral body wall and protrusion of a bone fragment into the spinal canal before operation. (B and C) On sagittal MRI, the T12 fracture with epidural involvement exhibited low signal intensity on T1-weighted images and high intensity on T2-weighted images. CT=computed tomography, MRI=magnetic resonance imaging.



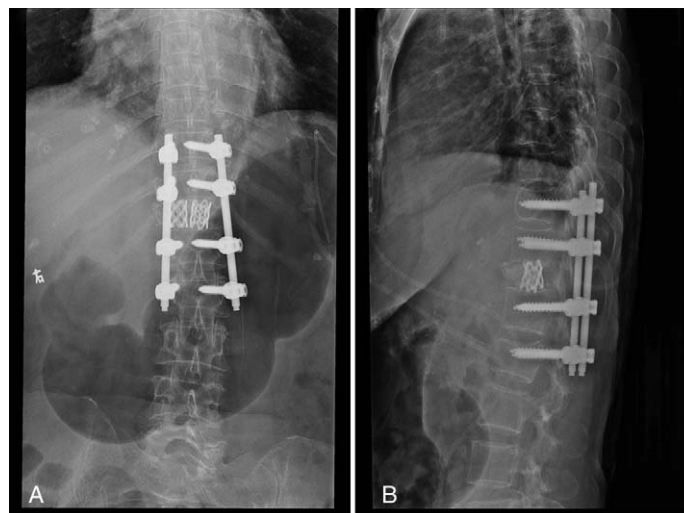
**Figure 2.** (A and B) Immediately postoperation. CT images exhibited successful decompression and reconstruction of the collapsed vertebral body using titanium mesh bone grafting combined with pedicle screw internal fixation. CT=computed tomography.

combines the advantages of the anterior only approach and the posterior only approach and reduces the trauma and complications that may arise with the combined approach. However, this approach is associated with several disadvantages. Although laminectomy aids in decompression, it may also further increase spinal instability. The effect of posterolateral bone grafting fusion is inaccurate. Posterior vertebral body reduction is very difficult for older fractures (older than 2 weeks). Moreover, even if serious vertebral collapse is associated with satisfactory reduction through this approach, the “shell vertebral body” phenomenon can still occur and cause secondary vertebral kyphosis,<sup>[5]</sup> which typically requires correction via the anterior approach and significantly increases the physical and economic burden for patients.

Here, we summarize the surgical treatment of Kümmell disease reported in the literature.

### 3.1. Minimally invasive surgery

Kümmell disease presents as vertebral body collapse with dynamic mobility via the cleft, which could lead to prolonged back pain. Percutaneous vertebroplasty (PVP) and percutaneous kyphoplasty (PKP) have served as the main therapeutic methods for these patients in recent years. Effective pain reduction and satisfactory clinical outcomes can be obtained after microfracture elimination and vertebral stabilization. Park et al<sup>[6]</sup> observed 18 patients with Kümmell disease treated with PVP, and think that PVP is an effective treatment option for pain relief and maintenance of sagittal balance.



**Figure 3.** One month later, postoperative posteroanterior (A) and lateral (B) standing radiographs revealed good sagittal alignment.

However, not all studies shared an optimistic view of PVP. Ha et al<sup>[7]</sup> stressed that patients with Kümmell disease had less reduction of pain and more inconvenience in daily life after PVP than patients who did not undergo PVP. These authors suggested that merely filling the IVC might not be adequate in some patients because the remainder of the vertebral body would remain unsupported, causing further pain. Heo et al<sup>[8]</sup> suggested that exclusively treating Kümmell disease with a bone cement augmentation procedure is associated with recurrent collapse and dislodged or fragmented bone cement. These authors reported that the incidence of recollapse after vertebroplasty was significantly increased in patients with Kümmell disease (28.6%) compared with that in the VCF group (1.2%) and suggested that VCFs with osteonecrosis or pseudarthrosis may be a relative contraindication for vertebroplasty. A previous study hypothesized that the osteolysis rate among patients with Kümmell disease is greater than the rate of bone callus formation.<sup>[9]</sup> Following PVP or PKP, accelerated osteolysis occurs and may displace the bone cement. Hasegawa et al<sup>[10]</sup> histologically examined the IVC and found that the cleft surface was covered with fibrocartilaginous membrane. This condition may cause the pattern of cement filling to differ between Kümmell disease and VCFs. For patients with Kümmell disease, cement acts as space-occupying material, and the locking effect between bone and cement is insufficient. Therefore, the potential exists for dislodgment or fragmentation, which would result in clinical failure.<sup>[11]</sup>

### 3.2. Open surgery

PVP or PKP is not applied for all types of Kümmell disease. Li et al<sup>[12]</sup> divided the disease into 3 stages: stage I—vertebral body height loss <20%, no adjacent disc degeneration; stage II—vertebral body height loss ≥20%, typically with adjacent disc degeneration and dynamic mobile fracture; stage III—posterior cortex fracture with spinal cord compression. PVP or PKP is a relative contraindication for stage III patients. Given the risk of cement leakage into the spinal canal due to the breakage of the posterior cortical wall, most patients must undergo anterior or posterior surgery for spinal decompression and internal bone graft fixation to restore the stability of the spine and neurological functions.

**3.2.1. Anterior approach.** The anterior surgical approach offers reliable decompression of neural tissue under direct vision, facilitates the removal of the retropulsed fragment, does not disturb “intact” posterior elements, and conforms to the biomechanical integrity. Anterior surgery requires a thoracotomy (pleural or extrapleural) and a retroperitoneal approach. The surgery typically involves a longer operation time and may injure the internal organs. Therefore, such a procedure is highly invasive, and elderly patients with serious comorbidities and severe bone fragility may not tolerate the procedure. In addition, anterior fixation alone is less rigid than posterior fixation constructs, and some patients who undergo anterior surgery may require additional posterior reinforcement due to multiple-level vertebral collapse, steroid-induced osteoporosis, or low bone mineral density. Sudo et al<sup>[13]</sup> reported that an anterior only approach resulted in the requirement of additional posterior instrumentation surgery in 28% of patients due to the progression of a kyphotic deformity or postoperative screw loosening. To avoid such unexpected additional surgeries, some surgeons primarily opt for a combination of both anterior and posterior surgery.

**3.2.2. Posterior approach.** The posterior approach for indirect decompression of the spinal cord avoids the impact of the anterior approach on abdominal viscera function, preserves segment motion, and reduces postoperative morbidity. In addition, most spinal surgeons are familiar with the posterior approach.

Some posterior surgical options have been reported to treat patients with Kümmell disease. The first one is cement-augmented pedicle screw fixation. Di et al<sup>[14]</sup> reported a cement-augmented pedicle screw placement in a patient with Kümmell disease. The operation was successful without any complications. The patient stated that symptoms were obviously improved in 1 week after operation. The second one is posterior pedicle screw internal fixation combined with bone graft. This posterior procedure has been applied to patients with spinal cord compression and offers satisfactory relief by indirect decompression. In addition, the intervertebral cleft can heal through the bone graft. Wang et al<sup>[15]</sup> adopted transpedicular vertebral body grafting combined with vertebral pedicle screw fixation to treat patients with Kümmell disease. Compared with the traditional anterior approach, this modified posterior operation offers equivalent effects on pain relief, kyphosis correction, and improvements in neurological function. Liu et al<sup>[16]</sup> performed bone graft and titanium mesh combined with short-segment fixation to treat this disease. The procedure was successful without any complications. Patient reported that symptoms were obviously improved in 1 week after operation. The third one is posterior internal fixation combined with vertebroplasty. Vertebroplasty provides anterior stabilization of the vertebral column, minimizes posterior pedicle screw stress, and relieves posterior dynamic mobility with short segment fixation. This technique improves angular deformity and reconstitution of body height, and the instrumentation failure rate may be reduced compared with that in procedures without vertebroplasty. Zhang et al<sup>[3]</sup> reported 16 patients treated by posterior decompression with short-segment fixation and fusion combined with vertebroplasty for Kümmell disease with neurological deficits. The neurological function of all patients was improved by at least 1 Frankel grade. In addition, obvious loosening of internal fixation and bone cement displacement were not observed. Lee et al<sup>[4]</sup> reported 10 patients with Kümmell disease with cord compression treated by short instrumentation combined with vertebroplasty and posterolateral fusion, and significant correction of kyphosis and anterior vertebral height were obtained. The fourth one is posterior osteotomy. Although the posterior approach is generally performed for indirect decompression of the spinal cord, osteotomy is an exceptional posterior surgery that can be performed with direct visualization of the circumferentially decompressed spinal cord. In addition, if a high angle of kyphosis correction is required, posterior spinal shortening osteotomy is a better choice for patients with serious kyphosis combined with neurological deficits. Jo et al<sup>[17]</sup> observed 13 patients with Kümmell disease treated by modified closing wedge osteotomy (with removal of the injured upper endplate and upper disc). The maximum correction angle was 41°, and the mean correction angle was 29.6°. Sagittal alignment improved with a mean correction rate of 58.3%. The mean surgical time was 275 minutes, and the mean intraoperative blood loss was 1585 mL. In addition, neurological function improved from AIS Grade C to D in 2 patients and from AIS Grade D to E in 2 patients. One patient experienced worsening neurological function due to intraoperative nerve root injury.

**Table 1****Summary of the surgical techniques to treat Kümmell disease.**

	Minimally invasive surgery	Open surgery		
		Anterior approach	Posterior approach	Combined anterior and posterior surgery
Indication	Stage I and II Kümmell disease	Stage III Kümmell disease	Stage III Kümmell disease	Stage III Kümmell disease
Advantages	Minimally invasive and highly effective	Reliable decompression of neural tissue under direct vision and easy for removing the retropulsed fragment.	Indirect decompression, reduce postoperative complications and is familiar to most spinal surgeons.	Strong fixation and sufficient neurological decompression.
Disadvantages	Cement leakage, recollapse, etc.	Longer operation time, highly invasive and fixation is less rigid than the posterior approach.	The ability to reset protruding into the spinal fracture block is limited.	Maximizes invasive and long operation time.

**3.2.3. Combined anterior and posterior surgery.** Although the posterior approach can be used effectively for indirect decompression, its ability to reset protrusions into the spinal fracture block is limited, and anterior surgery can offer spinal canal decompression and anterior support to restore the stability of the anterior column. Given the different characteristics of both surgeries, some scholars have proposed combining anterior and posterior surgery to treat stage III Kümmell disease.<sup>[3]</sup> The anterior–posterior combined procedure provides strong fixation with posterior instrumentation and anterior reconstruction. A biomechanical study revealed the superiority of the rigidity obtained with this combined surgery compared with that obtained with anterior or posterior fixation alone, especially in patients with severe osteoporosis.<sup>[18]</sup> Nakashima et al<sup>[19]</sup> compared the surgical results of anterior and posterior combined surgery (AP) and posterior fixation with vertebroplasty in the treatment of Kümmell disease with neurological deficits. Postoperative complications, such as nonunion and severe local kyphosis progression, were less frequently observed in the AP group. However, the operative time was significantly longer, and intraoperative blood loss was significantly greater. Given the increased invasive nature of the procedure and the long operation time, the use of this combined surgery is clinically limited.

Our study confirmed the efficacy of titanium mesh bone grafting combined with pedicle screw internal fixation for the treatment of stage III Kümmell disease with cord compression. Therefore, for patients diagnosed with Kümmell disease accompanied by severe vertebral collapse, kyphosis, and nerve compression, we suggest that this approach can effectively decompress the nerves, reconstruct the height of the vertebral body and restore the stability of the spine, representing an effective surgical option. However, it is important to consider some key limitations of this study, such as the limited number of patients and the lack of a control group. Additional cases should be accumulated to support this finding. In addition, we only observed the effects in this patient 1 month after the operation, and long-term follow-up is necessary.

#### 4. Conclusion

According to the literature, 4 main surgical approaches are commonly used for the treatment of Kümmell disease: PVP, the anterior approach, the posterior approach, and the anterior–posterior combined approach (Table 1). For stage I and II Kümmell disease, most studies recommend PVP or PKP. For stage III disease, most patients require spinal decompression and bone graft fixation to restore the stability of the spine and neurological

function. The ultimate treatment of this disease must be individualized according to the stage of the disease and the experience and preference of the surgeon. Additionally, titanium mesh bone grafting combined with pedicle screw internal fixation is an alternative method for patients with stage III Kümmell disease.

#### Author contributions

**Data curation:** Liangwei Mei, Wenjun Huang, Dengwei He.

**Formal analysis:** Zhenzhong Chen, Kangtao Jin.

**Methodology:** Wenhua Sang, Chao Lou.

**Software:** Lin Zheng.

**Writing – original draft:** Liangwei Mei.

**Writing – review & editing:** Liangwei Mei.

#### References

- [1] Freedman BA, Heller JG. Kummel disease: a not-so-rare complication of osteoporotic vertebral compression fractures. *J Am Board Fam Med* 2009;22:75–8.
- [2] He D, Yu W, Chen Z, et al. Pathogenesis of the intravertebral vacuum of Kümmell's disease. *Exp Ther Med* 2016;12:879–82.
- [3] Zhang GX, Gao YZ, Zheng J, et al. Posterior decompression and short segmental pedicle screw fixation combined with vertebroplasty for Kümmell's disease with neurological deficits. *Exp Ther Med* 2013;5: 517–22.
- [4] Lee SH, Kim ES, Eoh W. Cement augmented anterior reconstruction with short posterior instrumentation: a less invasive surgical option for Kummell's disease with cord compression. *J Clin Neurosci* 2011;18: 509–14.
- [5] Pappou IP, Papadopoulos EC, Swanson AN, et al. Osteoporotic vertebral fractures and collapse with intravertebral vacuum sign (Kümmell's disease). *Orthopedics* 2008;31:61–6.
- [6] Park JW, Park JH, Jeon HJ, et al. Kümmell's disease treated with percutaneous vertebroplasty: minimum 1 year follow-up. *Korean J Neurotrauma* 2017;13:119–23.
- [7] Ha KY, Lee JS, Kim KW, et al. Percutaneous vertebroplasty for vertebral compression fractures with and without intravertebral clefts. *J Bone Joint Surg Br* 2006;88:629–33.
- [8] Heo DH, Chin DK, Yoon YS, et al. Recollapse of previous vertebral compression fracture after percutaneous vertebroplasty. *Osteoporos Int* 2009;20:473–80.
- [9] Park SJ, Kim HS, Lee SK, et al. Bone cement-augmented percutaneous short segment fixation: an effective treatment for Kummell's disease? *J Korean Neurosurg Soc* 2015;58:54–9.
- [10] Hasegawa K, Homma T, Uchiyama S, et al. Vertebral pseudarthrosis in the osteoporotic spine. *Spine (Phila Pa 1976)* 1998;23:2201–6.
- [11] Erdem MN, Karaca S, Sari S, et al. Application of cement on strategic vertebrae in the treatment of the osteoporotic spine. *Spine J* 2017; 17:328–37.
- [12] Li KC, Wong TU, Kung FC, et al. Staging of Kümmell's disease. *J Muscul Res* 2004;8:43–55.

- [13] Sudo H, Ito M, Kaneda K, et al. Anterior decompression and strut graft versus posterior decompression and pedicle screw fixation with vertebroplasty for osteoporotic thoracolumbar vertebral collapse with neurologic deficits. *Spine J* 2013;13:1726–32.
- [14] Di HX, Liu FY, Yang SD, et al. Short-segment fixation with a cement-augmented pedicle screw for Kummell disease: Case report. *Medicine (Baltimore)* 2017;96:e8617.
- [15] Wang F, Wang DH, Tan BY, et al. Comparative study of modified posterior operation to treat Kummell's disease. *Medicine (Baltimore)* 2015;94:e1595.
- [16] Liu FY, Huo LS, Liu S, et al. Modified posterior vertebral column resection for Kummell disease: case report. *Medicine (Baltimore)* 2017; 96:e5955.
- [17] Jo DJ, Kim YS, Kim SM, et al. Clinical and radiological outcomes of modified posterior closing wedge osteotomy for the treatment of posttraumatic thoracolumbar kyphosis. *J Neurosurg Spine* 2015;23: 510–7.
- [18] Machino M, Yukawa Y, Ito K, et al. Posterior/anterior combined surgery for thoracolumbar burst fractures—posterior instrumentation with pedicle screws and laminar hooks, anterior decompression and strut grafting. *Spinal Cord* 2011;49:573–9.
- [19] Nakashima H, Imagama S, Yukawa Y, et al. Comparative study of 2 surgical procedures for osteoporotic delayed vertebral collapse: anterior and posterior combined surgery versus posterior spinal fusion with vertebroplasty. *Spine (Phila Pa 1976)* 2015;40: E120–6.