

Extensive venous thrombosis of the upper extremity in a diabetic patient with a hyperosmolar hyperglycemic state

Juri Park, M.D., Dong Jin Kim, M.D., Hee Young Kim, M.D., Ji A Seo, M.D.,
Sin Gon Kim, M.D., Sei Hyun Baik, M.D. and Dong Seop Choi, M.D.

Department of Internal Medicine, Korea University College of Medicine, Seoul, Korea

We report a case of extensive venous thrombosis of the upper extremity in a patient with a hyperosmolar hyperglycemic state (HHS). Thrombosis of the upper extremities is generally found in 4% of cases with deep venous thrombosis. Extensive, symptomatic venous thrombosis of the upper extremity, as seen in this patient, is rare except with catheter-related thrombosis. Recent studies have supported the safety and efficacy of catheter-directed thrombolysis in patients with no contraindication to thrombolytic therapy, and have recommended early catheter-directed thrombolysis. Therefore, our patient was treated with early catheter-directed thrombolysis followed by anticoagulation.

Key Words : Hyperglycemic Hyperosmolar Nonketotic Coma, Diabetes Mellitus, Upper Extremity, Venous Thrombosis

INTRODUCTION

Diabetes mellitus is considered to be a hypercoagulable state and is recognized as a risk factor for arterial thromboembolism in coronary, cerebral, mesenteric and peripheral vessels¹⁾. However, venous thromboembolism has rarely been reported as a complication of diabetic ketoacidosis or a hyperosmolar hyperglycemic state (HHS)²⁾. Upper extremity venous thrombosis accounts for only 4% of cases of venous thrombosis; symptomatic cases are uncommon, accounting only for 0.15% of upper extremity venous thromboses, including catheter-related thrombosis³⁻⁵⁾. We report here a case of extensive symptomatic venous thrombosis of the upper extremity, which developed after subclavian vein catheterization, in a patient with Type 2 diabetes and a hyperosmolar hyperglycemic state.

CASE REPORT

A 38-year-old man with diabetes mellitus presented to the

emergency room with a five day history of vomiting, lethargy and drowsiness. 5 days prior to admission he had been drinking heavily. He had a 10 year history of diabetes, treated with an oral hypoglycemic agent.

On admission he was afebrile, severely dehydrated and drowsy. No infectious focus was found on clinical examination, and there were no neurological manifestations. Admission laboratory data were notable for a plasma glucose of 1314 mg/dL (72.2 mmol/L), a serum osmolality of 423 mOsm/kg, a potassium level of 5.1 mEq/L and a creatinine level of 2.1 mg/dL. Arterial blood gas analysis on room air showed a pH of 7.37, PaO₂ of 74.5 mmHg, PaCO₂ of 53.1 mmHg, and HCO₃⁻ level of 30.1 mmol/L. There was 1+ ketonuria. The blood count demonstrated a polycythemia, with a hemoglobin of 20.2 g/dL, a white cell count of 12,400/ μ L and a platelet count of 256,000/ μ L. The coagulation screen, PT and aPTT were normal. His electrocardiogram revealed a sinus tachycardia.

The diagnosis of a hyperosmolar hyperglycemic state with severe dehydration was made. A right subclavian catheter was placed for fluid replacement in the emergency room. The patient

• Received : February 27, 2006

• Accepted : April 17, 2006

• Correspondence to : Sin Gon Kim, M.D., Division of Endocrinology, Department of Internal Medicine, Korea University Anam Hospital, 126-1, Anam-5-dong, Seongbuk-gu, Seoul, 136-705, Korea Tel : 82-2-920-5394, Fax : 82-2-953-9355, E-mail : k50367@korea.ac.kr

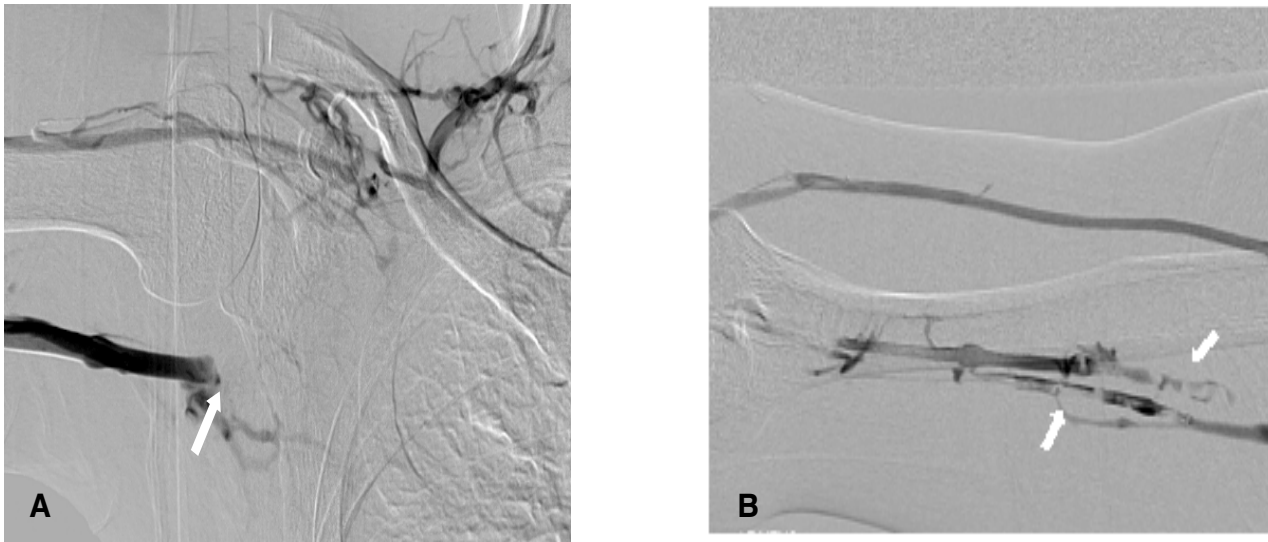


Figure 1. Right upper arm venography shows axillo-subclavian vein thrombosis (A) and thrombosis of the brachial and basilic veins (B).

was treated with intravenous insulin, fluid infusion and empirical antibiotics. By the next day, his condition was much improved and he was mentally alert.

Thirty hrs after central venous catheter placement the patient complained of pain in his right arm; moderate edema and erythema of the arm were noted. The right subclavian catheter was removed and the patient was closely observed. On hospital day three, his right arm edema was aggravated, and he developed neck edema. Thrombocytopenia was observed. A color Doppler ultrasonogram of the extremity demonstrated acute thrombosis from the right internal jugular and subclavian veins to the brachial and basilic vein. An upper extremity venogram confirmed occlusion at these sites (Figure 1). The patient denied any prior history of venous thromboembolism. Coagulation profile studies including plasma prothrombin time, antithrombin III, homocysteine, protein C, protein S, lipoprotein and Factor VIII concentrations were within normal limits.

The patient was treated with intravenous heparin and thrombolysis. Thrombolysis was performed using a bolus injection of urokinase, 300,000 units, with a multisided hole infusion catheter positioned at the right basilic and cephalic veins. The thrombolytic infusion was continued overnight via catheter. The next day, a follow-up venogram showed partial lysis of the clot. On discharge, the swelling and pain in the right arm were much improved; the platelet count improved and the patient was kept on warfarin until follow up. Two months later, the patient had no symptoms and the follow up color Doppler ultrasonogram showed no evidence of a thrombus in the previously damaged vein (Figure 2, 3).

DISCUSSION

Our patient was admitted in a hyperosmolar hyperglycemic state with severe dehydration. Thirty hours after placement of a subclavian venous catheter, he developed symptomatic deep vein thrombosis of the upper extremity, from the right internal jugular vein to the brachial vein. This patient had no prior history of venous thromboembolism and his admission coagulation profile was within normal limits. There was no evidence of cancer.

It is well known that arterial thromboembolic events, such as myocardial infarction, cerebrovascular accidents and peripheral and mesenteric arterial thrombosis, occur more frequently in diabetic patients^{6,7}. In contrast to these arterial thrombotic events, diabetes has not been identified as a risk factor for venous thromboembolism^{2,8}. However, recent studies show that the risk of venous thromboembolism, among diabetic patients, is greater than in the non-diabetic population⁸. Several potential mechanisms might account for an increased tendency for thrombosis with hyperglycemia^{1,9}. All components of the hemostatic system may be altered with diabetes mellitus. Vascular endothelium abnormalities, the activation of platelets and clotting factors, elevated coagulation activation markers, decreased levels of the anticoagulant protein C, and a relatively inhibited fibrinolytic system are all associated with the mechanism of thrombosis in hyperglycemia^{1,11}. Increased circulating platelet aggregates and higher plasma levels of platelet release products demonstrate platelet hyperactivity in diabetes mellitus. Dehydration associated with hyperglycemia may be a contributing factor for enhancing venous stasis as part of Virchow's triad of the pathogenesis of deep vein

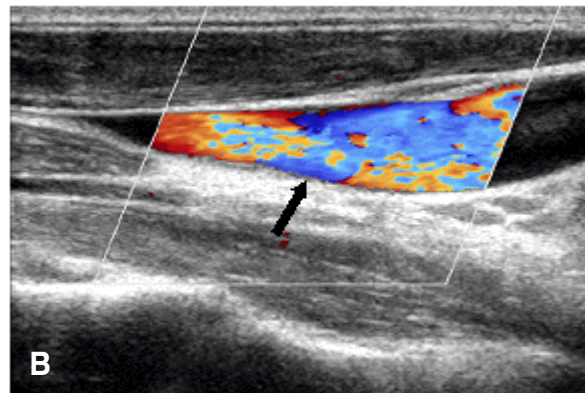
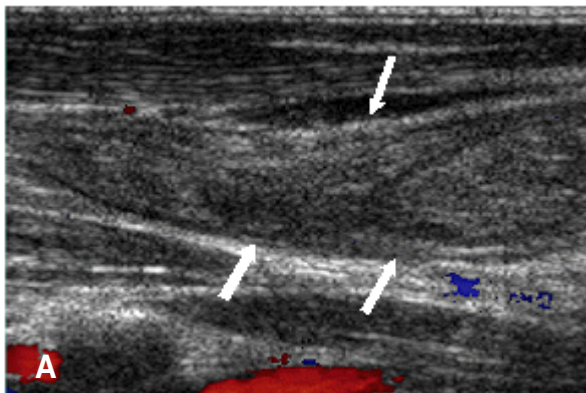


Figure 2. Initial color Doppler ultrasonogram (A) shows obstruction of the right internal jugular vein (white arrow). Two months later color Doppler ultrasonogram (B) demonstrates a completely resolved thrombosis within the right internal jugular vein (black arrow).

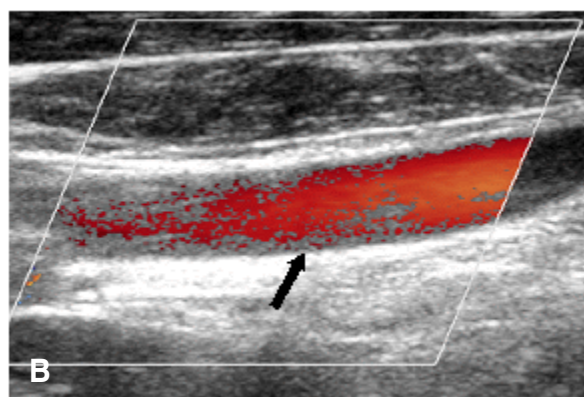
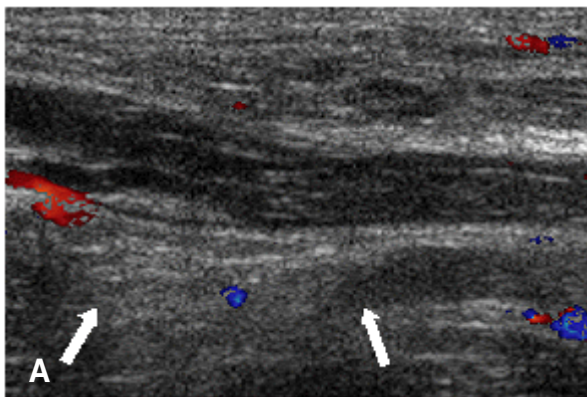


Figure 3. Initial color Doppler ultrasonogram (A) shows obstruction of the right axillary vein (white arrow). Two months later color Doppler ultrasonogram (B) demonstrates a completely resolved thrombosis within the right axillary vein (black arrow).

thrombosis. This constellation of findings supports the clinical observation that diabetes is a hypercoagulable state^{1, 10, 11}.

In contrast to the high prevalence of deep vein thrombosis, upper extremity thrombosis is relatively infrequent. Thrombosis of the upper extremities accounts for only 1% to 4% of all cases of deep vein thrombosis^{4, 5}. Symptomatic and extensive upper extremity venous thrombosis, as in our patient, is rare^{5, 12, 13}.

A well established risk factor for deep venous thrombosis of the upper extremity is placement of a central venous catheter^{13, 14}. Catheter related thrombosis may be caused by several factors. Venous stenosis and stasis is thought to develop from a combination of local venous wall irritation during catheter insertion or during infusion of medicine, as well as a foreign body response. Patients with incorrectly placed catheter tips are more likely to develop deep vein thrombosis^{15, 16}. In our case, a number of veins, from internal jugular and subclavian to brachial and basilic, showed thrombosis. There was swelling, erythema and pain of the upper arm and neck. Symptomatic and

extensive central venous catheter related thrombosis is infrequent, although the incidence of asymptomatic central venous catheter-related thrombosis diagnosed by venographic studies has been reported to be as high as 66%.¹⁷ Deep venous thrombosis is closely associated with age. Secondary upper extremity deep vein thrombosis usually occurs in patients older than 50, with a slightly increased incidence in women. Our patient was young compared to cases previously reported⁵.

The utility of routine anticoagulation in hyperosmolar hyperglycemic patients after placement of a central venous catheter is unclear. There is inadequate clinical evidence for full anticoagulation in these patients, and the practice significantly increases the risk of bleeding¹⁸. With the use of intravenous unfractionated heparin, the risk of major bleeding can be as high as 7%, and the rate of fatal bleeding has been reported to be up to 2%¹⁹. However, the results of catheter-directed thrombolysis for upper extremity deep vein thrombosis are encouraging, with nearly complete thrombus clearance reported

in 72% to 88% of cases. The response appears to depend primarily on the chronicity of the thrombus²⁰. Current experiences support the safety and efficacy of catheter-directed thrombolysis in patients with no contraindication to thrombolytic therapy²¹. Symptomatic extensive thrombosis in our patient was found within 30 hrs after central venous catheter placement, and he was treated promptly with catheter-directed thrombolytic therapy.

This case illustrates that central venous catheterization can result in severe symptomatic upper extremity thrombosis in a young diabetic patient with a hyperosmolar hyperglycemic state. Although the central venous catheter has a potential risk of inducing thrombus formation, it is used frequently in patients with a hyperosmolar hyperglycemic state for fluid replacement. However, the central venous catheter should be removed as soon as possible after the initial treatment. If edema develops in the extremity, after central venous catheter placement, the patient should be carefully evaluated for the possibility of thrombosis, even at a younger age.

REFERENCES

- 1) Carr ME. *Diabetes mellitus: a hypercoagulable state. J Diabetes Complications* 15:44-54, 2001
- 2) Shujaat A, Shapiro JM. *Massive pulmonary embolism in diabetic ketoacidosis and non-ketotic hyperosmolar state: case series and review of the literature. Clin Intensive Care* 15:73-77, 2004
- 3) Mustafa S, Stein PD, Patel KC, Otten TR, Holmes R, Silbergleit A. *Upper extremity deep venous thrombosis. Chest* 123:1953-1956, 2003
- 4) Horattas MC, Wright DJ, Fenton AH, Evans DM, Oddi MA, Kamienski RW, Shields EF. *Changing concept of deep venous thrombosis of the upper extremity: report of a series and review of the literature. Surgery* 104:561-567, 1988
- 5) Prandoni P, Bernardi E. *Upper extremity deep vein thrombosis. Curr Opin Pulm Med* 5:222-226, 1999
- 6) Krentz AJ, Natrass M. *Acute metabolic complications of diabetes: diabetic ketoacidosis, hyperosmolar non-ketotic hyperglycaemia and lactic acidosis. In: Pickup JC, Williams G, eds. Textbook of diabetes. 3rd ed. p. 32.1-32.24. Oxford, Blackwell Science, 2003*
- 7) Hamblin PS, Topliss DJ, Chosich N, Lording DW, Stockigt JR. *Deaths associated with diabetic ketoacidosis and hyperosmolar coma: 1973-1988. Med J Aust* 151:439-444, 1989
- 8) Petrauskiene V, Falk M, Waernbaum I, Norberg M, Eriksson JW. *The risk of venous thromboembolism is markedly elevated in patients with diabetes. Diabetologia* 48:1017-1021, 2005
- 9) Worly JM, Fortenberry JD, Hansen I, Chambliss CR, Stockwell J. *Deep venous thrombosis in children with diabetic ketoacidosis and femoral central venous catheters. Pediatrics* 113:e57-e60, 2004
- 10) Reverter JL, Reverter JC, Tassies D, Rius F, Monteagudo J, Rubies-Prat J, Escolar G, Ordinas A, Sanmarti A. *Thrombomodulin and induced tissue factor expression on monocytes as markers of diabetic microangiopathy: a prospective study on hemostasis and lipoproteins in insulin-dependent diabetes mellitus. Am J Hematol* 56:93-99, 1997
- 11) Yokoyama H, Myrup B, Rossing P, Ostergaard PB. *Increased tissue factor pathway inhibitor activity in IDDM patients with nephropathy. Diabetes Care* 19:441-445, 1996
- 12) Hill SL, Berry RE. *Subclavian vein thrombosis: a continuing challenge. Surgery* 108:1-9, 1990
- 13) Lokich JJ, Becker B. *Subclavian vein thrombosis in patients treated with infusion chemotherapy for advanced malignancy. Cancer* 52:1586-1589, 1983
- 14) Marinella MA, Kathula SK, Markert RJ. *Spectrum of upper-extremity deep venous thrombosis in a community teaching hospital. Heart Lung* 29:113-117, 2000
- 15) Joffe HV, Goldhaber SZ. *Upper extremity deep vein thrombosis. Circulation* 106:1874-1880, 2002
- 16) Cimochoowski GE, Worley E, Rutherford WE, Sartain J, Blondin J, Harter H. *Superiority of the internal jugular over the subclavian access for temporary dialysis. Nephron* 54:154-161, 1990
- 17) Blom JW, Doggen CJ, Osanto S, Rosendaal FR. *Old and new risk factors for upper extremity deep venous thrombosis. J Thromb Haemost* 3:2471-2478, 2005
- 18) Kian K, Eiger G. *Anticoagulant therapy in hyperosmolar non-ketotic diabetic coma. Diabet Med* 20:603, 2003
- 19) Levine MN, Raskob G, Landefeld S, Kearon C. *Hemorrhagic complications of anticoagulant treatment. Chest* 119:108S-121S, 2001
- 20) Grunwald MR, Hofmann LV. *Catheter-directed thrombolysis for the treatment of symptomatic deep vein thrombosis. Circulation* 109:e10, 2004
- 21) Arko FR, Cipriano P, Lee E, Filis KA, Zarins CK, Fogarty TJ. *Treatment of axillosubclavian vein thrombosis: a novel technique for rapid removal of clot using low-dose thrombolysis. J Endovasc Ther* 10:733-738, 2003