




Diagnostic Accuracy of Somatosensory Evoked Potential and Transcranial Motor Evoked Potential in Detection of Neurological Injury in Intradural Extramedullary Spinal Cord Tumor Surgeries: A Short-Term Follow-Up Prospective Interventional Study Experience from Tertiary Care Center of India

Manish Kumar Mishra¹  Nityanand Pandey¹ Hanjabam Barun Sharma² Ravi Shankar Prasad¹
Anurag Sahu¹ Ravi Shekhar Pradhan¹ Vikrant Yadav¹

¹Department of Neurosurgery, Institute of Medical Sciences, Varanasi, Uttar Pradesh, India

²Department of Physiology, Institute of Medical Sciences, Varanasi, Uttar Pradesh, India

Address for correspondence Manish Kumar Mishra, MS, DNB, MRCS (Ed), A-605, French Apartments, Sector 16B, Greater Noida (West), Uttar Pradesh 201308, India
(e-mail: drmanishmishravmmc@gmail.com).

Asian J Neurosurg 2024;19:210–220.

Abstract

Keywords

- ▶ intradural extramedullary spinal cord tumor
- ▶ intraoperative neurophysiological monitoring
- ▶ IONM
- ▶ modified McCormick scale
- ▶ motor evoked potential
- ▶ somatosensory evoked potential

Objective Intraoperative neuromonitoring (IONM) is an acknowledged tool for real-time neuraxis assessment during surgery. Somatosensory evoked potential (SSEP) and transcranial motor evoked potential (MEP) are commonest deployed modalities of IONM. Role of SSEP and MEP in intradural extramedullary spinal cord tumor (IDEMSCT) surgery is not well established. The aim of this study was to evaluate sensitivity, specificity, positive predictive value, negative predictive value, and diagnostic accuracy of SSEP and transcranial MEP, in detection of intraoperative neurological injury in IDEMSCT patients as well as their postoperative limb-specific neurological improvement assessment at fixed intervals till 30 days.

Materials and Methods Symptomatic patients with IDEMSCTs were selected according to the inclusion criteria of study protocol. On modified McCormick (mMC) scale, their sensory-motor deficit was assessed both preoperatively and postoperatively. Surgery was done under SSEP and MEP (transcranial) monitoring using appropriate anesthetic agents. Gross total/subtotal resection of tumor was achieved as per IONM warning alarms. Sensitivity, specificity, positive predictive value, negative predictive value, and diagnostic accuracy of SSEP and MEP were calculated considering postoperative neurological changes as “reference standard.” Patients were followed up at postoperative day (POD) 0, 1, 7, and 30 for convalescence.

Statistical Analysis With appropriate tests of significance, statistical analysis was carried out. Receiver-operating characteristic curve was used to find cutoff point of

article published online
June 5, 2024

DOI <https://doi.org/10.1055/s-0044-1787052>.
ISSN 2248-9614.

© 2024. Asian Congress of Neurological Surgeons. All rights reserved.

This is an open access article published by Thieme under the terms of the Creative Commons Attribution-NonDerivative-NonCommercial-License, permitting copying and reproduction so long as the original work is given appropriate credit. Contents may not be used for commercial purposes, or adapted, remixed, transformed or built upon. (<https://creativecommons.org/licenses/by-nc-nd/4.0/>)

Thieme Medical and Scientific Publishers Pvt. Ltd., A-12, 2nd Floor, Sector 2, Noida-201301 UP, India

mMC for SSEP being recordable in patients with higher neurological deficit along with calculation of sensitivity, specificity, positive predictive value, negative predictive value, and diagnostic accuracy of SSEP and MEP for prediction of intraoperative neurological injury.

Results Study included 32 patients. Baseline mean mMC value was 2.59. Under neuromonitoring, gross total resection of IDEMSCT was achieved in 87.5% patients. SSEP was recordable in subset of patients with mMC value less than or equal to 2 with diagnostic accuracy of 100%. MEP was recordable in all patients and it had 96.88% diagnostic accuracy. Statistically significant neurological improvement was noted at POD-7 and POD-30 follow-up.

Conclusion SSEP and MEP individually carry high diagnostic accuracy in detection of intraoperative neurological injuries in patients undergoing IDEMSCT surgery. MEP continues to monitor the neuraxis, even in those subsets of patients where SSEP fails to record.

Introduction

Spinal cord tumor (SCT) surgery intrinsically involves manipulation of neural structures. Intraoperative neurological injury manifesting as postoperative sensory/motor deterioration is an unnerving event for surgeons. Quench for a device, which can monitor the integrity of neuraxis in real time during spine surgery, was met by intraoperative neurophysiological monitoring (IONM) system in the second half of twentieth century. Over the period it evolved and the latest system incorporates different modalities, namely evoked potentials including somatosensory evoked potential (SSEP), motor evoked potential (MEP), brainstem auditory evoked potential, visual evoked potential, electroencephalography, electromyography (EMG), to monitor specific neural pathway.¹ Its importance, especially in spine surgery, was acknowledged by the American Academy of Neurology and the American Clinical Neurophysiology Society a decade back (2012) and they recommended that: "Intraoperative monitoring using SSEPs and transcranial MEPs be established as an effective means of predicting an increased risk of adverse outcomes, such as paraparesis, paraplegia, and quadriplegia, in spinal surgery."²

Effectiveness of IONM in intramedullary spinal cord tumor (IMSCT) surgery is well established; however, its role in resection of intradural extramedullary spinal cord tumor (IDEMSCT) is still controversial. Though 6 to 7% patients of IDEMSCT postoperatively develop permanent neurological deficits,^{3,4} the opponents expostulate its use by citing factors like extra-axial location of lesion, low canal occupancy, increased surgical duration, and higher cost of surgery/anesthesia.⁵

In this era of evidence, an unambiguous knowledge of precision of IONM is needed while defining its niche in SCT surgery, especially IDEMSCTs. Indexed study focuses on sensitivity, specificity, positive predictive value (PPV), negative predictive value (NPV), and overall diagnostic accuracy of SSEP and transcranial MEP individually in detection of intraoperative neurological injury in patients undergoing IDEMSCT resection for oncological cure.

Materials and Methods

The proposed prospective study was conducted in the Department of Neurosurgery, Institute of Medical Sciences, Banaras Hindu University, Varanasi, Uttar Pradesh, India, in collaboration with Department of Physiology over a period of 24 months (January 2021–December 2022). Study protocol was approved by Institutional Ethics Committee. Patients presenting in outpatient department with IDEMSCT were selected on the basis of clinical history, physical examination, and contrast-enhanced magnetic resonance imaging (MRI) of spine. All patients were informed about the benefits/risks of surgery under IONM and written consent was taken. Limb-specific neurological deficit was measured using modified McCormick (mMC) scale (► **Table 1**).⁶

Inclusion Criteria

- IDEMSCT patients with mMC grade I-IV neurological deficit
- Between 10 and 65 years of age at the time of enrolment

Exclusion Criteria

- IDEMSCT patients with other spinal compressive lesions
- IDEMSCT patients with mMC grade V neurological deficit
- Pregnant patients
- Patients on treatment for seizure/ movement disorders
- History of deep venous thrombosis

For statistical ease, IDEMSCTs of junctional region of spine (namely cervicodorsal/dorsolumbar) were placed in cervical/dorsal/lumbar group, on the basis of major regional occupancy (>50%) in longitudinal axis on MRI. Limb-specific neurological deficit using mMC scale was assessed preoperatively (baseline), on the day of surgery after 4 hours of reversal from general anesthesia (postoperative day [POD] 0), on POD 1, 7, and 30. MRI spine was carried out in all patients on POD-0.

Anesthesia for surgery under IONM: Following preoxygenation for 3 to 5 minutes general anesthesia was induced

Table 1 Integrated table showing clinical, radiological, and surgical profile of patients included in the study

Sl. no.	Age	Sex	Baseline mMC grade	IDEMSCT location	Tumor location with respect to cord	SSEP recordable	SSEP drop (>50%)	MEP drop (>50%)	Tumor resection	New deficit
1	27	F	3	D	Lt	NR	NA	Y	STR	Y
2	26	M	2	D	Lt	R	N	N	GTR	N
3	22	M	2	C	Lt	R	N	N	GTR	N
4	12	F	1	C	Lt	R	N	N	GTR	N
5	18	M	3	L	Co	NR	NA	N	GTR	N
6	45	F	3	D	Lt	NR	NA	N	GTR	N
7	23	F	3	D	Lt	NR	NA	N	GTR	N
8	22	M	3	L	P	NR	NA	N	GTR	N
9	46	F	2	D	P	R	N	N	GTR	N
10	65	F	3	L	Lt	NR	NA	N	GTR	N
11	14	M	3	D	Lt	NR	NA	N	GTR	N
12	39	M	2	C	P	R	N	N	GTR	N
13	28	M	2	D	P	R	N	N	GTR	N
14	47	M	2	D	Lt	R	N	N	GTR	N
15	17	M	4	L	Lt	NR	NA	N	GTR	N
16	59	F	3	D	Lt	NR	NA	N	GTR	N
17	45	F	2	D	A	R	Y	Y	STR	Y
18	16	F	3	L	P	NR	NA	N	GTR	N
19	52	M	3	L	Co	NR	NA	N	GTR	N
20	13	F	1	C	Lt	R	N	N	GTR	N
21	46	F	2	D	P	R	N	N	GTR	N
22	65	M	4	D	Lt	NR	NA	N	GTR	Y
23	40	F	3	C	Lt	NR	NA	N	GTR	N
24	23	F	1	D	Lt	R	N	N	GTR	N
25	28	F	3	D	A	NR	NA	Y	STR	Y
26	54	F	3	D	P	NR	NA	N	GTR	N
27	60	F	3	D	Lt	NR	NA	N	GTR	N
28	45	F	2	C	Lt	R	N	N	GTR	N
29	27	M	2	C	Lt	R	Y	Y	STR	Y
30	60	F	3	D	P	NR	NA	N	GTR	N
31	50	M	4	C	Lt	NR	NA	N	GTR	N
32	45	M	3	L	Co	NR	NA	N	GTR	N

Abbreviations: A, anterior; C, cervical; D, dorsal; F, female; GTR, gross total resection; L, lumbar; Lt, lateral; M, male; N, no; NA, not applicable; MEP, motor evoked potential; mMC, modified McCormick scale; NR, not recordable; P, posterior; R, recordable; SSEP, somatosensory evoked potential; STR, subtotal resection; Y, yes.

with fentanyl (2 µg/kg) and propofol (titrated to loss of consciousness) by neuroanesthesiologist. After adequate mask ventilation, vecuronium (0.1 mg/kg) was administered and patients were intubated with appropriate-sized endotracheal tube. Temperature probe was attached. Body temperature was maintained throughout the procedure between 36 and 37°C. Bite block was placed between the jaws. Ventilation was adjusted to obtain a stable airway pressure with end-tidal carbon dioxide levels between 30 and 40 mm Hg (adjusted after obtaining an arterial blood gas

to correlate with a partial pressure of carbon dioxide between 35 and 45 mm mercury). In all cases, bispectral index (BIS) was used to monitor the depth of anesthesia, with BIS maintained between 40 and 60. Wearing-off effect of vecuronium was confirmed with the ulnar nerve stimulation. Baseline MEPs (transcranial) were recorded. Anesthesia was maintained by intravenous propofol (2%) infusion at 50 to 100 µg/kg/min with fentanyl infusion at 1 to 2 µg/kg/hour. It was occasionally supplemented with inhalational anesthetic agents, that is, air-nitrous oxide in 1:1 ratio and

isoflurane at permissible low minimal alveolar concentration (MAC) 0.4 to 0.5, when plane of anesthesia was not maintained. At this time, neurophysiologist was informed and IONM waveform changes were closely monitored. At the time of skin closure, anesthetic agents were stopped. Inhalational anesthetic drugs were stopped at approximately 10 minutes prior to end of surgery. Reversal of residual neuromuscular blockade was done with intravenous neostigmine 50µg/kg and glycopyrrolate 10µg/kg drugs. If criteria were met, patient was extubated.

Surgery under IONM: A standardized workflow was followed in the study (►Fig. 1). “Medtronic NIM – Eclipse system 68L2128-C” was used as neurophysiological detector. After cleaning of the local sites with chlorhexidine and 70% ethyl alcohol solution, electrodes were fixed on patient. Cork-screw electrodes were applied over scalp at standard sites (F_Z, C_Z, C₃, C₃, C₄, C₄) of international 10 to 20 system (►Fig. 2A). In upper extremities, SSEP stimulating electrodes were placed over median nerve at the wrist (►Fig. 2B), while in the lower extremities, they were placed over posterior tibial nerve (►Fig. 2C). Invasive subdermal needle electrodes were inserted at target muscles of upper and/or lower limbs for recording of trans cranial MEP (►Fig. 2D). All electrodes were secured using adhesive plasters.

Patients were positioned prone on table over bolsters. Distal ends of electrodes were inserted in data acquisition modules that were in continuation with IONM system. Baseline SSEP and MEP waveforms (►Fig. 3A, B) were recorded. Weaned-off effect of muscle relaxant was ensured. Surgery was proceeded. SSEP and/or MEP were recorded at multiple phases of surgery (namely laminectomy, durotomy, tumor decompression, and resection). More than 50% decrease in amplitude of waveform was considered as “warning sign” (►Fig. 3C, D).

At such instances, surgery was withheld temporarily when MEP amplitude decreased by more than 50%. Cord was irrigated with warm saline; mean arterial pressure, MAC of isoflurane, patient’s body temperature (to rule out hypothermia), and BIS were checked. It was resumed on improvement of amplitude. “Unilateral or bilateral disappearance of waveform (especially MEP) as well as lack of restoration of amplitude by more than 50%” were considered red flag. Correctable parameters were rechecked and needful adjustments were done. Subject to normalization of waveform, surgery was further proceeded, else aborted (►Fig. 3E). After tumor resection, watertight duraplasty was performed and checked on-table by “induced Valsalva maneuver”. Anatomical closure of surgical site was done. Excised specimen was sent for histopathological examination. Neurological status of limb was reassessed using mMC scale, after 4 hours of extubation (i.e., POD 0), POD 1, 7, and 30. Clinical change in mMC value was considered “reference standard” and diagnostic accuracy of SSEP and MEP was compared with respect to it.

Statistical Analysis

Data was fed in Microsoft EXCEL spreadsheet and analyzed using Statistical Package for Social Sciences (SPSS) software,

IBM manufacturer, Chicago, United States, version 25.0. Presentation of “Categorical variables” was done in form of number and percentage (%). On the other hand, “quantitative data” were presented as “mean ± SD” (standard deviation) and as “median with 25th and 75th percentiles” (interquartile range). Following statistical tests were applied for results:

1. Association of variables, which were quantitative in nature, was analyzed using analysis of variance. Paired *t*-test was used for comparison across follow-up.
2. Association of variables, which were qualitative in nature, was analyzed using Fisher’s exact test, as at least one cell had an expected value of less than 5.
3. Receiver-operating characteristic (ROC) curve was used to find cutoff point of mMC for SSEP being recordable in patients with higher neurological deficit along with calculation of sensitivity, specificity, PPV, NPV, and diagnostic accuracy of SSEP.
4. Sensitivity, specificity, PPV, and NPV of SSEP and MEP were calculated for predicting intraoperative neurological injury/new motor deficit.

Statistically, *p*-value of less than 0.05 was considered significant.

Results

Between January 2021 and December 2022, 35 patients with IDEMSCT were enrolled and underwent surgery under IONM, at our institution. Three patients were lost to follow-up at 30 days. Finally, the cohort comprised of 32 patients (►Table 1). All patients had varying degree of neurological deficits. Mean age of presentation was 36.84 years. There was female preponderance with female: male ratio: 1.28:1. Preoperative/baseline sensory-motor deficit in limbs was measured on mMC (►Table 2) and mean mMC value was 2.59. Most of these spinal tumors (53.13%) were located in dorsal vertebral region. Within thecal sac, the commonest site (59.38%) was “lateral” to cord. Mean duration of surgery was 222.34 minutes. Duration of surgery was significantly dependent on tumor location within thecal sac. It was minimum (mean: 186.67 minutes) for tumors at conus and maximum (mean: 295 minutes) for tumors ventral to cord. Gross total resection (GTR) was achieved in 28 (87.5%) patients, while it was “subtotal” in four (12.5%) patients due to persistent warning changes in MEP waveform.

SSEP with typical waveform (►Fig. 3A) was recordable in 13 (40.63%) patients. Patients with high neurological deficit had very small amplitude SSEP waves (►Fig. 3F), where tracking 50% amplitude drop was elusive. In our study, majority of patients (19/32, 59.37%) had this very type of small amplitude SSEP recordings. On application of statistical ROC curve, we found that standard SSEP waves were recordable in subset of patients who had mMC score less than or equal to 2 (►Fig. 4). Since authors could not reliably notice “more than 50% drop in amplitude” in such small waves, so further SSEP analysis was carried out in 13 patients who displayed typical waveforms. Among these 13 patients, SSEP

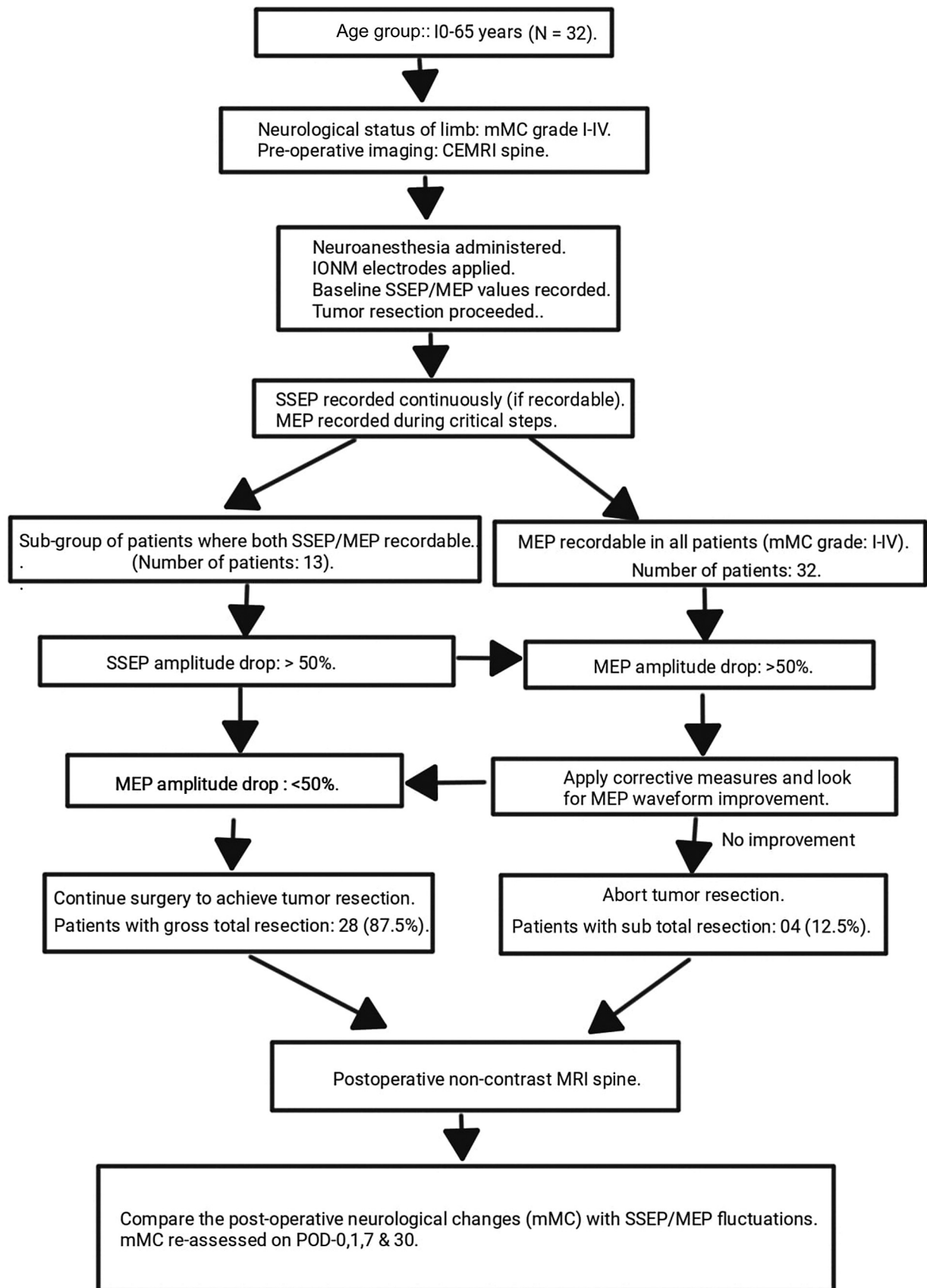


Fig. 1 Outline of the standardized workflow of this study. CEMRI, contrast-enhanced computed tomography; IONM, Intraoperative neuro-monitoring; MEP, motor evoked potential; mMC, modified McCormick scale; SSEP, somatosensory evoked potential.

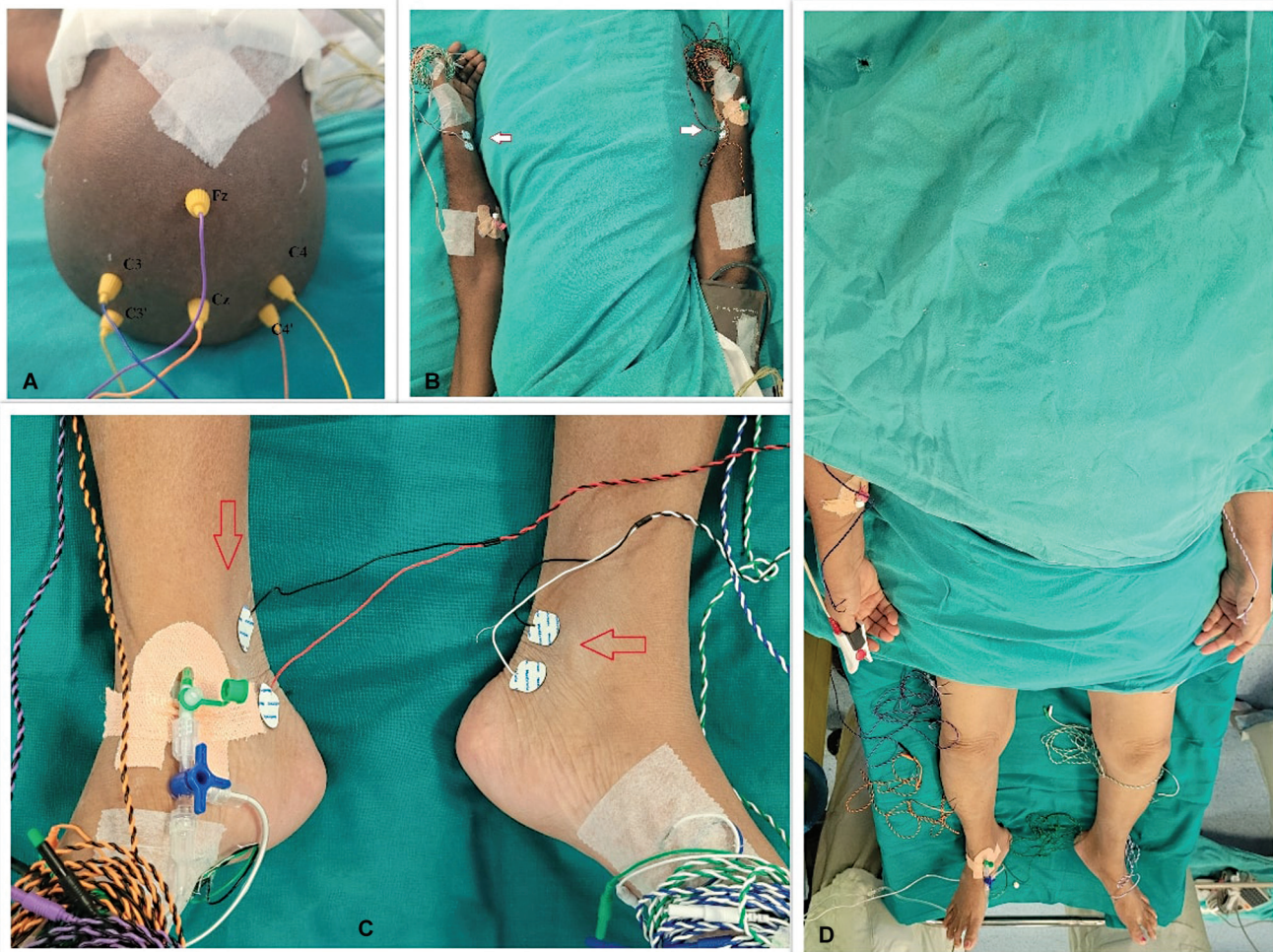

Fig. 2 Preoperative patient with multiple electrodes for spinal cord tumor surgery under intraoperative neuromonitoring (A) Cork-screw electrodes fixed over scalp according to international 10-20 system. (B) Sticky electrodes attached over both fore arms near wrist (arrow marked) for somatosensory evoked potential (SSEP) recording from median nerve of upper limbs. (C) Sticky electrodes attached over both legs near ankle (arrow marked) for SSEP recording from posterior tibial nerve of lower limbs. (D) Invasive subdermal needle electrodes for motor evoked potential recording inserted in target muscles of both lower limbs, namely vastus medialis of thigh, tibialis anterior of leg, flexor hallucis longus of foot during dorsal intradural extramedullary spinal cord tumor surgery with control electrodes inserted in abductor pollicis brevis muscle of hand.

showed intraoperative drops (>50%) in amplitude in two cases that did not recover despite rescue protocol of optimizing blood pressure, core temperature, local irrigation with warm saline, etc. Their “post-operative” MRI spine had no radiological signs of cord parenchyma injury. Both cases had temporary sensory-motor deterioration from baseline, which were found recovered on POD 7 follow-up. Nurick grade further continued to improve. In this subset of study cohort, statistically SSEP had 100% sensitivity, 100% specificity, 100% PPV, and 100% negative predictive value in identification of neurological injury (►Table 3).

MEP was recordable in all 32 patients. Authors noticed an inverse relationship between neurological deficit of limb muscle group and corresponding amplitude of MEP wave. Four patients (12.5%) showed intraoperative more than 50% drop in waveform amplitude, which translated into their postoperative motor deficit. However, at POD-7 follow-up, deficits were recovered. In one patient (3.13%), there was no intraoperative significant change in MEP waveform (►Fig. 5A),

but there was postoperative deterioration of motor power. Preoperative MRI of this patient had left laterally located contrast enhancing $D_{10}D_{11}$ IDEMSCT that was severely compressing the cord parenchyma (►Fig. 5B, C). Intraoperative MEP tracing had differential amplitude in waveform for both lower limbs. On affected (left) side there were smaller amplitude waves; though there were no intraoperative significant fluctuations in MEP, still patient had drop in motor power of limb after surgery. Postoperative MRI spine showed GTR of tumor (►Fig. 5D); however, there were radiological features of focal cord contusion (►Fig. 5E). Statistically MEP had 80% sensitivity, 100% specificity, 100% PPV, and 96.43% NPV. Its diagnostic accuracy was 96.88% in detection of intraoperative neurological injury (►Table 4).

Patients were clinically assessed at POD 0, 1, 7, and 30. Mean mMC value was higher than baseline on POD 0, but it improved subsequently at every follow-up, that is, POD 1, POD 7, and POD 30. Statistically significant improvement was noticed on POD 7 and POD 30 (►Fig. 6).

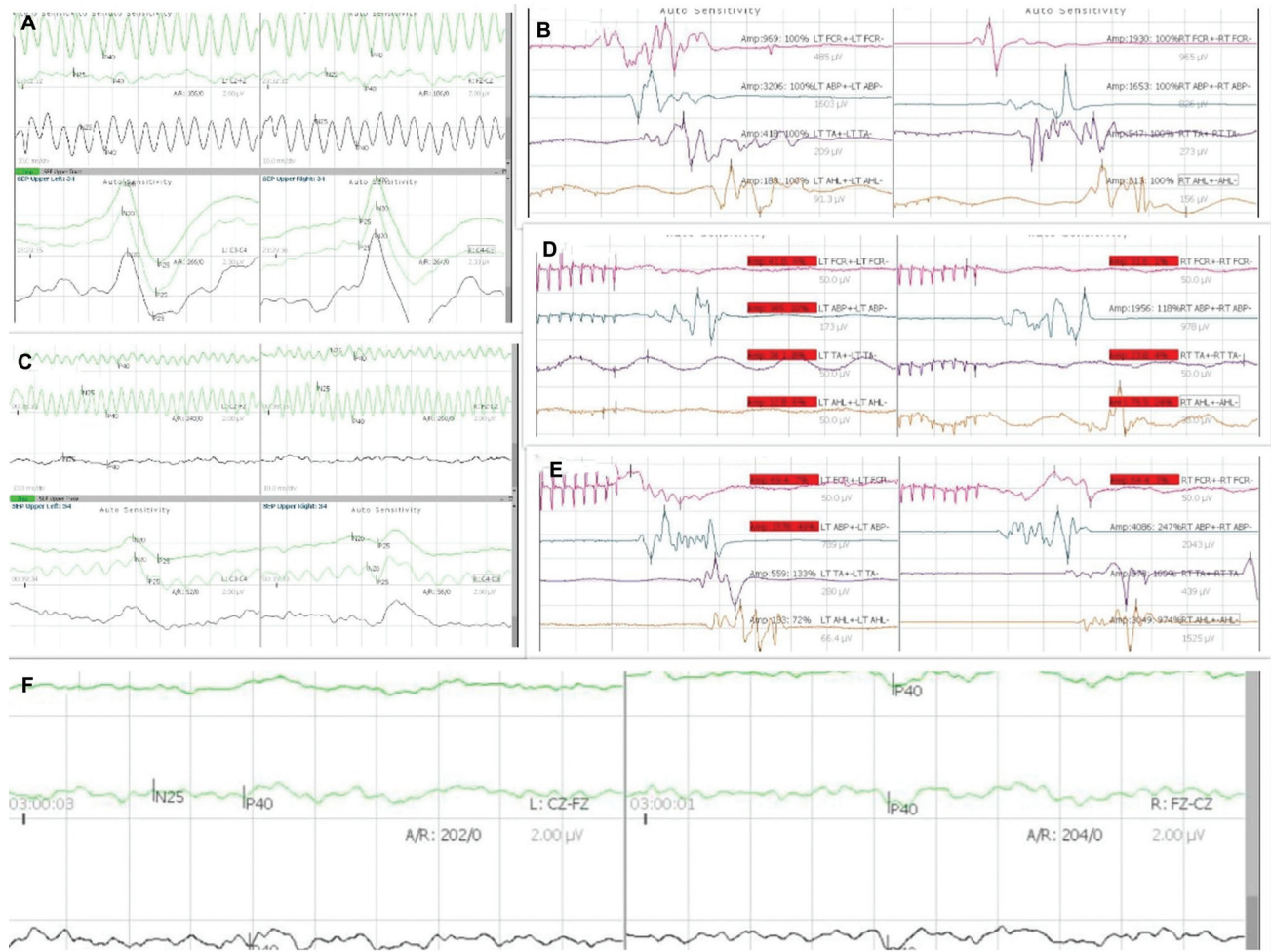


Fig. 3 Somatosensory evoked potential (SSEP) and motor evoked potential (MEP) waveforms (A) Typical baseline SSEP waveform recording from upper and lower limbs while operating cervical intradural extramedullary spinal cord tumor (IDEMSCT). (B) Typical baseline MEP waveform recording while operating cervical IDEMSCT. (C) Waveform showing drop in SSEP amplitude by more than 50% in both upper and lower limb recordings while resecting cervical IDEMSCT. (D) Red-flagged MEP waveform readings due to more than 50% drop in amplitude of most target muscles while resecting cervical IDEMSCT; however, left abductor pollicis brevis MEP amplitude has improved. (E) Most MEP recordings improved while some remained red flagged after following rescue protocol. (F) Baseline SSEP waveform recording from a patient with dorsal IDEMSCT who had Nurick grade IV deficit. NB, here amplitude is very small which is in contrast with ► Fig. 2A.

Table 2 Modified McCormick scale (mMC) scale

Functional grade	Clinical prerequisites
I	Neurologically intact, normal ambulation, minimal dysesthesia
II	Mild sensory or motor deficit, functional independence
III	Moderate deficit, limitation of function, independent with external aid
IV	Severe sensory or motor deficit, limitation of function, dependent
V	Paraplegia or quadriplegia, even with flickering movement

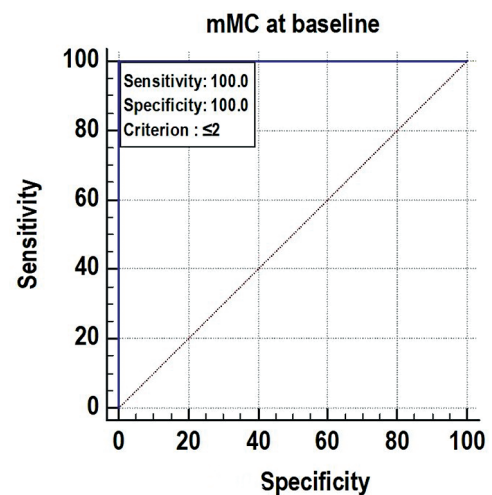


Fig. 4 Receiver-operating characteristic curve showing 100% sensitivity and specificity of somatosensory evoked potential in subset of intradural extramedullary spinal cord tumor patients whose neurological deficit on modified McCormick scale (mMC) is less than or equal to 2.

Table 3 Statistical description of ROC curve of SSEP

Variables	mMC at baseline
Area under the ROC curve (AUC)	1
Standard error	0
95% CI	0.891–1.000
p-Value	<0.0001
Cutoff	≤2
Sensitivity (95% CI)	100% (75.3–100.0%)
Specificity (95% CI)	100% (82.4–100.0%)
PPV (95% CI)	100% (75.3–100.0%)
NPV (95% CI)	100% (82.4–100.0%)
Diagnostic accuracy	100.00%

Abbreviations: AUC, area under the curve; CI, confidence interval; IDEMSCT, intradural extramedullary spinal cord tumor; MEP, motor evoked potential; mMC, modified McCormick scale; NPV, negative predictive value; PPV, positive predictive value; ROC, receiver-operating characteristic; SSEP, somatosensory evoked potential. In the indexed study SSEP had 100% diagnostic accuracy for the subset of IDEMSCT patients whose mMC value was less than or equal to 2.

Table 4 Statistical description of ROC curve of MEP

Variables	Values
Sensitivity (95% CI)	80% (28.36–99.49%)
Specificity (95% CI)	100% (87.23–100.00%)
AUC (95% CI)	0.9 (0.74–0.98)
Positive predictive value (95% CI)	100% (39.76–100.00%)
Negative predictive value (95% CI)	96.43% (81.65–99.91%)
Diagnostic accuracy	96.88%

Abbreviations: AUC, area under the curve; CI, confidence interval; MEP, motor evoked potential; ROC, receiver-operating characteristic;

Discussion

SCTs comprise approximately 15% of all central nervous system neoplasms, which include extradural and intradural tumors.⁷ Intradural spinal cord tumors (IDSCTs) can be extramedullary or intramedullary. IDEMSCTs constitute about 35 to 40% of all SCTs.⁸ Usual presentations of SCTs

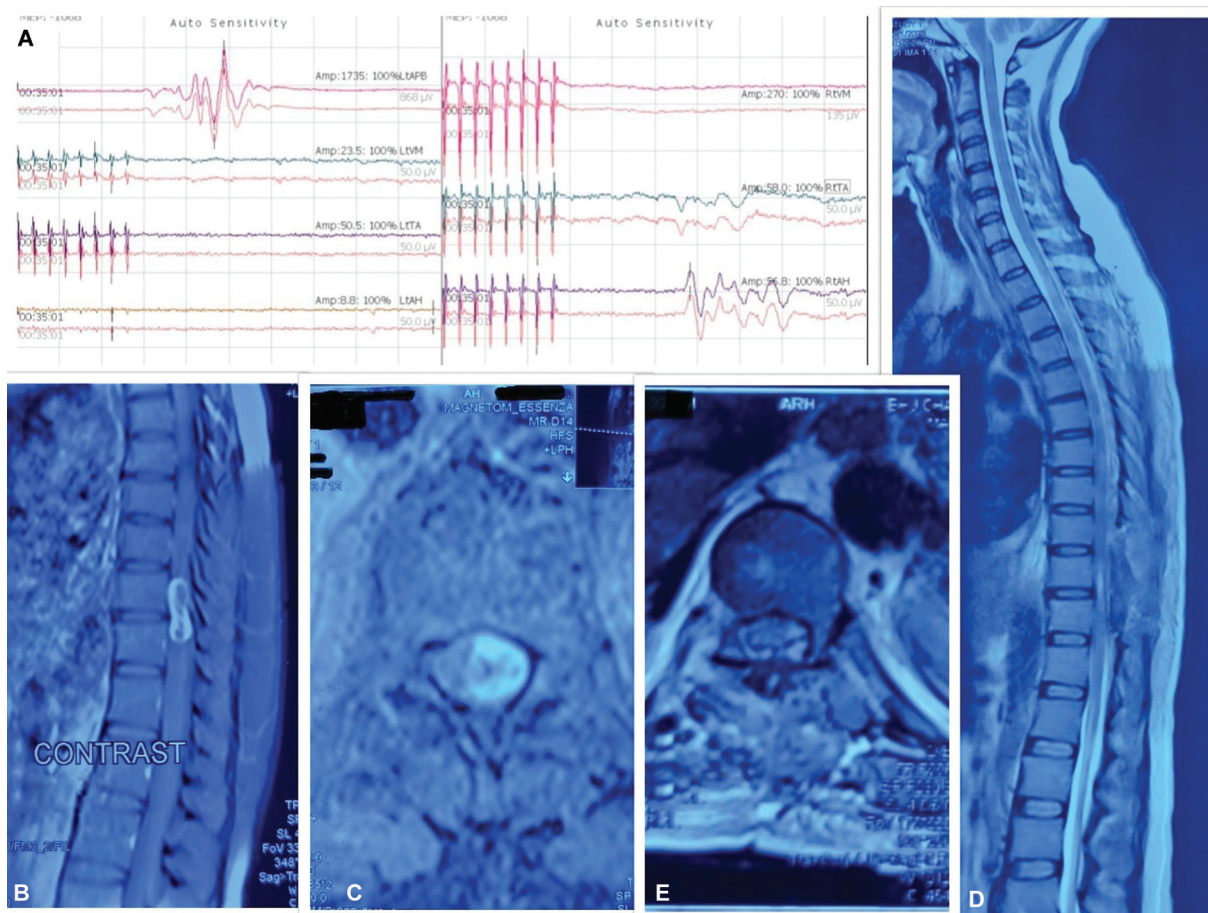


Fig. 5 Motor evoked potential (MEP) recordings and radiological details of the patient whose neurophysiological monitoring was false negative. (A) Control MEP from abductor pollicis brevis has the highest amplitude. Waveform gets progressively smaller in lower limb recordings. Left foot, ipsilateral to tumor, has the smallest waves. (B) Sagittal contrast-enhanced magnetic resonance imaging (MRI) spine of the indexed patient has D₁₀D₁₁ contrast avid intradural extramedullary spinal cord tumor measuring 3.7 × 2.5 × 2.3 cm. (C) Corresponding axial section shows anterolaterally located tumor occupying approximately 65% of thecal space causing significant mass effect on cord. (D) T₂ sequence sagittal MRI spine after gross total resection of tumor with postoperative artifacts. (E) Corresponding axial section has areas of hyperintensity, suggestive of cord contusion.

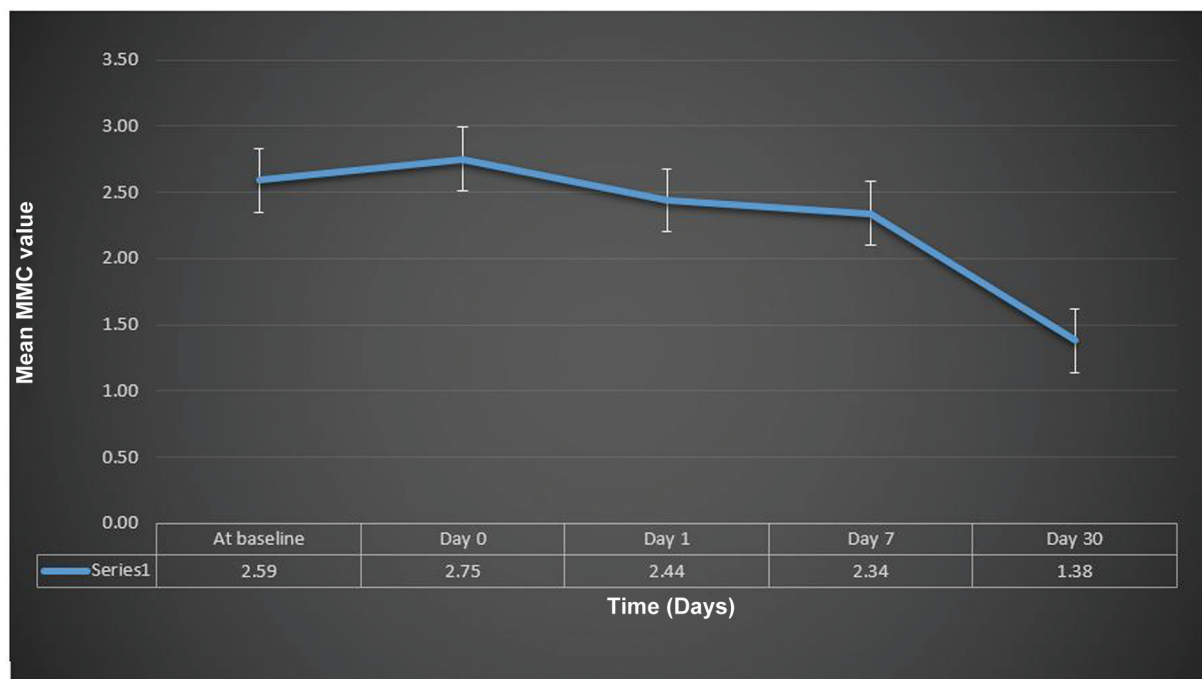


Fig. 6 Graph showing changes in mean modified McCormick value (mMC) of the study group. Statistically significant improvement is noticeable at postoperative day (POD) 7 and POD 30.

are pain and progressive sensory-motor deficits with/without bladder-bowel symptoms. Surgical resection is the cornerstone in the management. Chief complications of IDEMSCT surgeries are surgical site infections, cerebrospinal fluid (CSF)-related complications (namely pseudomeningocele and CSF leak) and new onset/worsening of neurological deficits. Despite incorporation of latest microneurosurgical techniques, 3.7 to 7.5% of postoperative patients endure the torment of neurological deterioration.^{3,4,9} This deterioration may occur due to direct maneuvers being performed on to cord (tumor-cord interface delineation), secondary to systemic blood pressure changes leading to cord hypoperfusion or by traction injury of cord while contemplating tumor debulking/resection.

The never-ending quest of achieving maximum possible safe tumor resection has driven the intraoperative monitoring technique for integrity of neuraxis during spine surgery, from crude “wake up” test to modern sophisticated multi-modal IONM system.⁹ SSEP and MEP have been extensively used in IONM during SCT surgeries. SSEP monitors the dorsal column and medial lemniscus pathways, while MEP monitors the motor pathways. MEP is the most dependable modality in monitoring conus medullaris and cauda equina motor integrity. The major limitation of SSEP is that it requires averaging that prolongs acquisition time. MEP has overcome this limitation and it does not require averaging, but it has variable morphology. Fifty percent drop in latency and/or a 10% prolongation in latency are accepted as warning criteria in SSEP monitoring; while owing to its variable morphology, the warning criteria during MEP monitoring are absence of waves, change in waveform or more than 50% drop in amplitude. There is a consensus to continue the surgery, as long as MEP recordings are stable.^{9,10} The role of

IONM in IDEMSCT surgeries has been highlighted in various studies; however, its routine use in IDEMSCT and extradural SCT is still under debate.^{5,10}

In this study, the mean duration of surgery under IONM was 222.34 minutes. Operative time was minimum for IDEMSCTs located at conus medullaris or cauda equina, while it was maximum for tumors located ventral to cord. In our study since there was no control group of patients undergoing surgery without IONM (ethical committee did not approve), so authors cannot opine whether use of IONM and its warnings lead to a statistically significant increase in the surgical duration or not. Siller et al in their study had mean operative time of 200 minutes while performing resection of IDEMSCTs using IONM.¹¹

SSEP with typical waveform was recordable in 40.63% patients. In patients with higher deficit, amplitude was very small, where tracking of further decrease by more than 50% was difficult. Baig Mirza et al faced similar difficulty while recording SSEP and MEP in his subset of IDEMSCT patients who had greater baseline neurological deficit. SSEP was recordable in 68% patients with ASIA E and 62% patients with ASIA D impairment. They had to preclude patients with higher impairment where no successful readings were obtained.⁵ In our study, we found that patients whose neurological status on mMC scale was up 1 or 2; SSEP had 100% recordability (95% confidence interval). In this subset of patients (13/32), SSEP showed 100% sensitivity, specificity, PPV, NPV, and diagnostic accuracy in prediction of intraoperative neurological injury.

MEP was recordable in all patients of our study, but amplitudes were smaller in the muscle groups with higher deficit. In four (12.5%) patients, it showed more than 50% drop in amplitude in some target muscles, which did not recover to 50% of baseline value. These patients showed

temporary motor worsening. However, in one patient (3.12%), there was deterioration without significant MEP amplitude change during surgery. In literature, there is wide variation in the false-negative reporting of transcranial MEP. Historically, Kurokawa et al have reported 7% false-negative transcranial MEP recordings in his study group of 59 SCT surgeries,¹² while Tamkus et al cite false-negative IONM findings in spine surgery as rare (0.04%) event.¹³ Baig Mirza et al have mentioned in their research about patients who did not exhibit intraoperative change in MEP, but later developed neurological deficits.⁵ Elwakil et al have reported one false-negative case out of 24 patients who underwent spine surgery under transcranial MEP monitoring.¹⁴ Thus, in our study MEP had 80% sensitivity, 100% specificity, 96.43% negative predictive value, 100% PPV, and overall 96.88% diagnostic accuracy. Point to ponder over here is that SSEP had 100% diagnostic accuracy, but it was recordable in a small subset of our study group who had minimal neurological deficits, while transcranial MEP was recordable in all patients of our cohort (mMC grade I to grade IV) and it delivered good diagnostic accuracy. Literature has paucity of studies citing the sensitivity, specificity, PPV, NPV, and diagnostic accuracy for individual modalities of IONM, that is, SSEP and MEP in IDEMSCT surgeries. Niljianskul and Prasertchai in their study on IDSCT (IDEMSCT and IMSCT) patients have reported 66.7% sensitivity, 88.7% specificity, 22.2% PPV, and 98.2% NPV when they used multimodal (SSEP, MEP, EMG) IONM.¹⁵ Siller et al in their retrospective study on elderly patients (≥ 65 -year age) with IDEMSCT who underwent IONM (SSEP and transcranial MEP) guided resection found 42.9% sensitivity, 98.2% specificity, 75.0% PPV, and 93.3% NPV of IONM as a composite modality.¹¹ van der Wal et al have cited 73% sensitivity and 78% specificity of multimodal IONM (SSEP, MEP) when used in IDEMSCT surgery.⁸

In our study, persistent warning changes in SSEP/MEP waveform led to change of tumor resection plan (gross total to subtotal) in four (12.5%) patients. All were neurologically preserved postoperatively. Ghadirpour et al described a series of 68 patients who underwent multimodal IONM (SSEP and MEP) guided IDEMSCT surgery, during which significant IONM changes occurred in 7.35% of patients, inducing a modification of the surgical strategy which prevented and mitigated postoperative neurological sequelae.¹⁶ Baig Mirza et al have reported 17% subtotal resection in IONM-IDEMSCT surgical subgroup and this resection was comparable (15%) to non-IONM IDEMSCT surgical subgroup.⁵

Authors noticed higher mean mMC value on POD 0 than baseline that improved subsequently at every follow-up, that is, POD 1, POD 7, and POD 30. This transient worsening could have been due to postoperative edema and microinsults to neuraxis.

The plan of anesthesia is very important in such cases and cannot be overlooked in discussion. Team work and close communication between neurosurgeons, neuroanesthesiologists, and neurophysiologists are must for better outcomes. But there is paucity of ideal anesthetic technique, which can be universally applied for the optimal generation of evoked potentials. A low-dose inhalational anesthetic agent (up to

0.5 MAC) and low-to-medium dose propofol (50–100 $\mu\text{g}/\text{kg}/\text{min}$ intravenous) with infusion of opioid (fentanyl, remifentanyl) offers a balanced anesthesia approach, which can be modified as per the changes in IONM waveforms.¹⁷

This study has some limitations like small sample size, lack of control arm in design (not approved by ethics committee), and short duration of follow-up. Still the results were encouraging. Studies with larger number of patients and longer follow-up will further strengthen defining the role of IONM in IDEMSCT surgeries.

Conclusion

The two most frequently used modalities of IONM, namely, SSEP and MEP, individually carry high diagnostic accuracy in detection of intraoperative neurological injuries in patients undergoing IDEMSCT surgery. MEP continues to monitor the spinal cord, even in those subset of patients where SSEP fails to record. In opinion of authors, neurological integrity of patients must be respected and in this context SSEP and/or transcranial MEP serve(s) as a reliable adjunct to the dexterity of surgeon while addressing IDEMSCTs.

Note

It has been presented in the “11th Annual Conference of the Neurological Surgeons Society of India” (04 March 2023), at Hyderabad (India) with title “Role of Intraoperative Neurophysiological Monitoring in Spinal Cord Tumor Surgeries: An Institutional Experience.

Authors' Contributions

M.K.M. helped in data collection, statistical analysis, and manuscript writing. N.P. contributed to research idea, manuscript writing, and supervision. H.B.S. helped in data collection and manuscript writing. R.S.P. and A.S. were involved in data collection and supervision. R.S.P. and V.Y. contributed to data collection.

Ethical Approval

Research protocol was approved by Institute's Ethics Committee and the ethical principles outlined by the Helsinki Declaration has been followed.

Funding

None.

Conflict of Interest

None declared.

References

- Ghatol D, Widrich J. Intraoperative Neurophysiological Monitoring. [Updated 2022 Aug 30]. StatPearls. Treasure Island (FL): StatPearls Publishing; 2023
- Buhl LK, Bastos AB, Pollard RJ, et al. Neurophysiologic intraoperative monitoring for spine surgery: a practical guide from past to present. *J Intensive Care Med* 2021;36(11):1237–1249

- 3 Westwick HJ, Yuh SJ, Shamji MF. Complication avoidance in the resection of spinal meningiomas. *World Neurosurg* 2015;83(04):627–634
- 4 Sacko O, Haegelen C, Mendes V, et al. Spinal meningioma surgery in elderly patients with paraplegia or severe paraparesis: a multicenter study. *Neurosurgery* 2009;64(03):503–509
- 5 Baig Mirza A, Vastani A, Syrris C, et al. Intraoperative Neurophysiological Monitoring for Intradural Extramedullary Spinal Tumours. *Global Spine J*. 2024;14(4):1304–1315
- 6 Kumar R, Singh V. Benign intradural extramedullary masses in children of northern India. *Pediatr Neurosurg* 2005;41(01):22–28
- 7 Arnautovic K, Arnautovic A. Extramedullary intradural spinal tumors: a review of modern diagnostic and treatment options and a report of a series. *Bosn J Basic Med Sci* 2009;9(suppl 1, suppl 1):S40–S45
- 8 van der Wal EC, Klimek M, Rijs K, Scheltens-de Boer M, Biesheuvel K, Harhangi BS. Intraoperative neuromonitoring in patients with intradural extramedullary spinal cord tumor: a single-center case series. *World Neurosurg* 2021;147:e516–e523
- 9 Scibilia A, Terranova C, Rizzo V, et al. Intraoperative neurophysiological mapping and monitoring in spinal tumor surgery: sirens or indispensable tools? *Neurosurg Focus* 2016;41(02):E18
- 10 Park JH, Hyun SJ. Intraoperative neurophysiological monitoring in spinal surgery. *World J Clin Cases* 2015;3(09):765–773
- 11 Siller S, Sixta A, Tonn JC, Szelenyi A. Feasibility of multimodal intraoperative neurophysiological monitoring for extramedullary spinal cord tumor surgery in elderly patients. *Acta Neurochir (Wien)* 2023;165(08):2089–2099
- 12 Kurokawa R, Kim P, Itoki K, et al. False-positive and false-negative results of motor evoked potential monitoring during surgery for intramedullary spinal cord tumors. *Oper Neurosurg (Hagerstown)* 2018;14(03):279–287
- 13 Tamkus AA, Rice KS, McCaffrey MT. Perils of intraoperative neurophysiological monitoring: analysis of “false-negative” results in spine surgeries. *Spine J* 2018;18(02):276–284
- 14 Elwakil W, Imam M, Hassan M, Elsaadany W, Gaber O. Impact of multimodal intraoperative neurophysiological monitoring of the spinal cord during spine and spinal cord surgeries. *Egypt Rheumatol Rehabil* 2023;50(01):1–7
- 15 Niljianskul N, Prasertchai P. The effect of intraoperative neurophysiological monitoring on neurological outcomes after spinal tumors operations: a single institution experience. *Interdiscip Neurosurg* 2023;31:101703
- 16 Ghadirpour R, Nasi D, Iaccarino C, et al. Intraoperative neurophysiological monitoring for intradural extramedullary tumors: why not? *Clin Neurol Neurosurg* 2015;130:140–149
- 17 Ali Z. Intraoperative neurophysiologic monitoring and anaesthetic implications. *Indian J Anaesth* 2019;63(02):81–83