

The Apical Extent of Mineral Trioxide Aggregate Apical Barrier Does not Influence the Treatment Outcome in a Nonvital Immature Permanent Anterior Tooth: A Split-Mouth Clinical Study

 Krunal M TABIYAR,  Ajay LOGANI

ABSTRACT

Objective: The study aimed to compare treatment outcomes when MTA apical plugs are placed to different apical extents in nonvital immature permanent anterior teeth with an open apex.

Methods: Six participants (five male & one female) between the age group of 8-18 years exhibiting bilateral traumatized nonvital immature permanent maxillary anterior teeth (n=12) with non-blunderbuss canal (Cvek's stage 4) were included. Standardized endodontic procedures were performed, and an inter-appointment calcium hydroxide medicament placed for one week. Based on the apical position of the MTA apical barrier, two study groups were defined. Accordingly, Group I (n=6) (4mm MTA plug up to the radiographic root end) and Group II (n=6) (4 mm MTA plug 2 mm short of the radiographic root-end). Teeth were obturated after twenty-four hours with thermoplasticized gutta-percha technique. They were evaluated clinically and radiographically at 12 and 24 months. Radiographs were assessed for periapical healing based on the periapical index (PAI) scores that were dichotomized as score <3 as healed and ≥3 as not healed. The data were compared using Mann Whitney U test, Kruskal Wallis and post hoc analysis.

Results: At 24 months, all teeth in Group I and II were healed clinically and radiographically. On inter-group comparison, radiographically, all teeth (n=12) exhibited a PAI score <3 and were categorized as healed (P=1.00).

Conclusion: The apical extent of MTA plug does not influence the treatment outcome. The clinician can place MTA apical plug either up to or 2 mm short of the radiographic root-end.

Keywords: Immature teeth, mineral trioxide aggregate, nonvital tooth, pulp necrosis

HIGHLIGHTS

- This is the first prospective study to assess the effect of apical extent of MTA plug on treatment outcome of immature teeth with open apices.
- The apical extent of MTA plug did not influence the treatment outcome.
- MTA placed 2 mm short of WL was associated with the formation of a radiographically detectable apical barrier.

INTRODUCTION

Traumatic dental injury in children can result in pulp necrosis and subsequent arrest of root maturation (1). These nonvital immature permanent teeth have thin dentinal root walls and wide-open apices. The absence of an apical stop to support conventional obturation is the principal concern. Therefore, it is highly desirable to induce apical root-end closure. Traditionally calcium hydroxide apexification has been attempted. However, it

has inherent drawbacks of prolonged treatment time, porous apical barrier and high incidence of cervical root fracture (2). A biologically-based regenerative procedure (revascularization) has been advocated to induce root maturation with increased root length and thickness. However, the intended outcome is not achieved predictably and an intraradicular post cannot be placed after this procedure (3).

Mineral trioxide aggregate (MTA) as a root-end barrier material has been widely recommended for the successful management of a tooth with an open apex. It has an excellent sealing ability, tissue compatibility and bio-inductive properties (4, 5). The technique for MTA apical barrier placement involves chemo-mechanical preparation, inter-appointment dressing with a suitable

Please cite this article as:

Mukeshkumar Tabiyar K, Logani A. The Apical Extent of Mineral Trioxide Aggregate Apical Barrier Does not Influence the Treatment Outcome in a Nonvital Immature Permanent Anterior Tooth: A Split-Mouth Clinical Study. *Eur Endod J* 2021; 6: 44-9

From the Department of Conservative Dentistry and Endodontics (K.M.T., A.L. ✉ apexlogani@yahoo.co.in), Centre for Dental Education and Research, All India Institute of Medical Sciences, New Delhi, India

Received 30 April 2020,
Accepted 20 August 2020

Published online: February 02 2021
DOI 10.14744/eej.2020.08760

This work is licensed under a Creative Commons Attribution-NonCommercial 4.0 International License.



intracanal medicament and subsequent placement of an MTA apical plug, either in a single or two-step procedure (6, 7). The thickness of the MTA apical barrier has been extensively researched, and it has been documented that a 4mm plug is sufficient for an adequate apical seal (8).

Immature teeth with open-apices have incompletely formed root with irregular apical dentinal walls (9). MTA apical barriers placed up to the radiographic root-end in these teeth, can result in overfill and a less favourable outcome may ensue (10). It is common for case series and prospective studies to place MTA apical barrier up to the radiographic root end (11, 12). The present preliminary clinical study aimed to evaluate the effect of the apical extent of MTA apical barrier on periapical healing of a nonvital immature permanent incisor tooth with an open apex.

MATERIALS AND METHODS

Subject enrolment

The institutional research Ethics Committee approved the study protocol (Ref. No. IESC/T-422/26-08-2015, RT-25/2015) following the principles of Helsinki (version 2008).

Inclusion and exclusion criteria

Healthy participants of either gender in the age group of 8-18 year requiring nonsurgical endodontic therapy in bilateral permanent maxillary central incisor teeth with a diagnosis of pulp necrosis and asymptomatic apical periodontitis exhibiting radiographic periapical index (PAI) score ≥ 3 (13) and associated Cvek's stage 4 of root development (14) were enrolled between July 2015 and December 2017. Radiographic examination was carried using a size-1.5 CMOS RVG sensor (EzSensor Classic™, VaTech, Korea) exposed by paralleling cone technique at standardized X-ray operating parameters (70 kV, 7mA, and 0.12s). Teeth with extensive bone loss, a history of previous endodontic intervention, and non-restorable teeth were excluded. Verbal information regarding the study aim, associated procedures, and written bilingual patient information sheet was provided. Written informed consent was obtained from either of the parent or legal guardian.

Sample selection and randomization method

In the absence of related literature and since this was a preliminary clinical study, a convenience sample size comprising of six participants with traumatized bilateral nonvital immature permanent maxillary central incisor teeth (n=12) were selected for a split-mouth study design. In each subject, the bilateral nonvital immature permanent maxillary central incisor teeth were randomly assigned using permuted block randomization to either group I (n=6, MTA apical barrier up to the radiographic root-end) or group II (n=6, MTA apical barrier 2 mm short of the radiographic root-end). The participants were blinded to the treatment allocation.

Interventions

Nonsurgical endodontic therapy

It was performed by a single operator (KT). A standardized two-visit protocol was followed. The tooth was anaesthetized with 2% lignocaine with 1:200,000 adrenaline (LOX 2%, Neon Laboratories Ltd., Mumbai, India). The access cavity was

prepared under rubber dam isolation using a sterile round carbide bur (Dentsply Maillefer, Ballaigues, Switzerland). The canal terminus was determined and working length (WL) at that position was opted for with an electronic apex locator (Tri Auto-ZX, J Morita USA) operated as per manufacturer's recommendations and confirmed radiographically. In case of discrepancy between the measured WL, the radiographic WL was taken as the final (15). Minimal mechanical instrumentation of the canal was carried out with ISO K-files (Dentsply Maillefer, Ballaigues, Switzerland). The entire instrumentation was supplemented with copious irrigation of the canal with 5.25 % sodium hypochlorite (NaOCl) (PRIME™ Dental Products Pvt. Limited, Pune, Maharashtra, India). The canal was irrigated with 17% Ethylenediaminetetraacetic acid (EDTA) (Largal ultra Septodont, Codex, France) for 1 minute and the final flush was carried out with distilled water. To limit extrusion of the irrigant in the periapical area, the Endovac irrigation delivery system (EndoVac™ system; Kerr Dental, Orange, CA, USA) was used. The canal was dried with a sterile absorbent paper points (Dentsply Maillefer, Ballaigues, Switzerland), and an intracanal medicament of calcium hydroxide slurry was placed with a lentulo spiral (Dentsply Maillefer, Ballaigues, Switzerland). The access cavity was restored with Cavit™ G (3M ESPE Dental AG, Seefeld/Oberbay, Germany). The patients were recalled at a one-week interval. The root canal was re-accessed following the above endodontic protocol. Calcium hydroxide was removed with 10 ml each sequential irrigation of 17% EDTA and 5.25% NaOCl solution. This was aided with ultrasonic activation (16). If there was a persistent discharge from the root canal, another dressing of calcium hydroxide slurry was placed until a dry canal was obtained. Two teeth required additional calcium hydroxide intracanal medication. Subsequently, an MTA (White ProRoot® MTA, Dentsply Maillefer, Ballaigues, Switzerland) apical barrier was placed.

MTA apical barrier

To serve as an internal matrix for placement of the MTA apical barrier, sterile resorbable collagen sponge was sized into a suitable piece. In Group I, the rubber stopper of the hand plugger was adjusted up to established WL, and collagen pellet was placed flush to the radiographic root end. In Group II, the rubber stopper of the hand plugger was adjusted 2 mm short of the established WL and was used to place the collagen pellet short of the radiographic root end. MTA powder was mixed as per the manufacturer's recommendation. It was carried into the root canal in increments using the Dovgan MTA carrier (Dentsply Maillefer, Wey bridge, UK) and condensed with Schilder pluggers (Dentsply Caulk, Milford, USA) until an appropriate thickness of 4 mm was achieved. A moist cotton pellet was placed over it. To confirm the correct placement of the MTA apical plug, a digital intraoral periapical radiograph was exposed at standardized parameters (70 kV, 7mA, and 0.12s) on a size-1.5 CMOS RVG sensor (EzSensor Classic™, VaTech, Korea). The access cavity was restored with Cavit™ G (3M ESPE Dental AG, Seefeld/Oberbay, Germany). The patient was recalled after twenty-four hours. The tooth was re-accessed under aseptic conditions. The setting of the MTA was confirmed. Obturation was performed using an AH plus® sealer (Dentsply DeTreY GmbH, Konstanz, Germany) and Calamus®

Dual thermoplastic injection system (Dentsply Maillefer, Ballaigues, Switzerland). The access cavity was sealed with an Optra Bond® All in one (Dentsply DeTrey GmbH, Konstanz, Germany) and composite resin material (Ceram.X® SphereTEC™ one Composite, Dentsply DeTrey GmbH, Konstanz, Germany).

Clinical evaluation

The cases were evaluated clinically at twelve and twenty-four months. Tenderness to palpation, percussion, mobility, pus discharge, and the absence or presence of sinus were noted and compared with previous records.

Radiographic evaluation

The pre and twenty-four months post-operative PAI scores of the teeth were radiographically evaluated (Figs. 1-3) and compared by two trained endodontist who were blinded to the study objectives and methodology. The examiners repeated the scoring after the one-month interval. Inter-rater and intra-rater agreement scores were calculated using Cohen's kappa analysis. The scores were 0.818 and 0.83, respectively.

Statistical analysis

The data collected was entered in Microsoft Excel and subjected to statistical analysis using Statistical Package for Social Sciences (IBM SPSS Inc., version 20.0, Chicago, IL, USA). The level of significance was fixed at 5% and $P \leq 0.05$ was considered statistically significant. Kolmogorov-Smirnov test and Shapiro-Wilks test were employed to test the normality of data. The categorical data were represented in frequency (n)/percentages (%). Mann Whitney U test, Kruskal Wallis and post hoc analysis was performed for quantitative variables.

RESULTS

No case was lost to follow up at the end of the observation period of twenty-four months. All patients reported no symptoms associated to the teeth in question, suggesting that the treatment was successful. In this study, the PAI score was considered as an ordinal scale. They were dichotomized as healed, PAI scores < 3 or non-healed, PAI scores ≥ 3 . On inter-group comparison between the frequency distribution of baseline

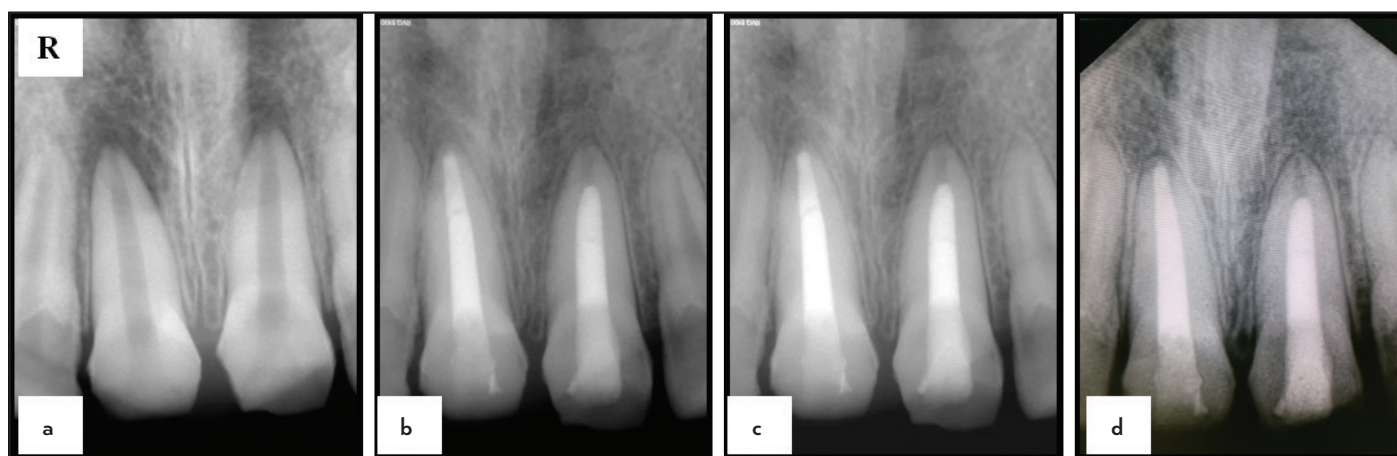

Figure 1. (a) Preoperative intraoral periapical radiograph of teeth #11 and #21 with non-blunderbuss canal and open apex associated PAI scores of 5 and 4 respectively. (b) Immediate postoperative intraoral periapical radiograph of tooth #21 showing MTA apical barrier 2 mm short and tooth #11 showing MTA apical barrier up to radiographic root end. (c) & (d) Follow up intraoral periapical radiograph exhibiting resolution of the periapical lesion at 12 and 24 months

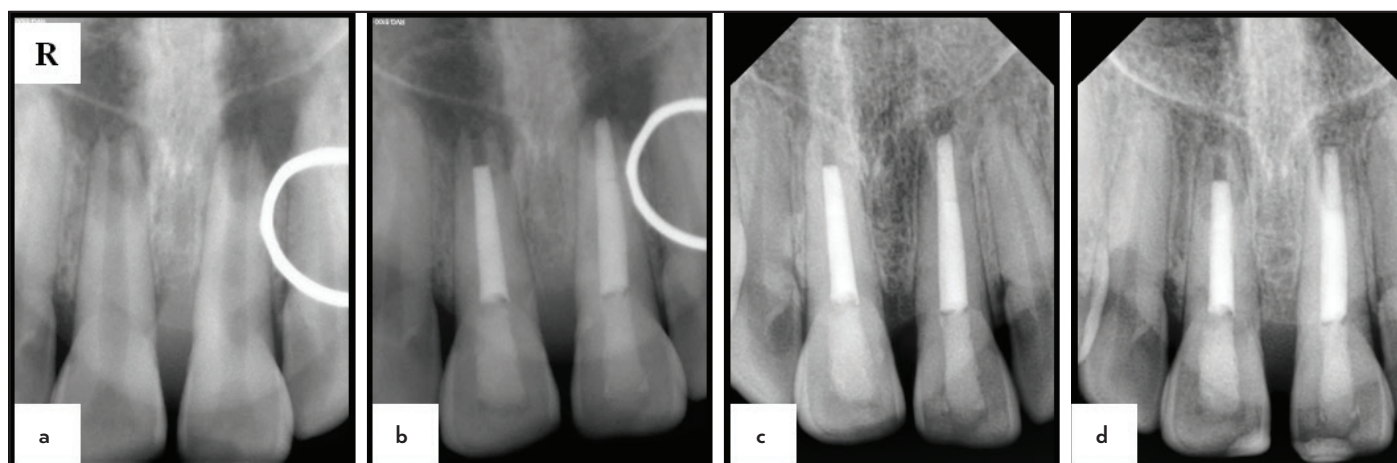


Figure 2. (a) Preoperative intraoral periapical radiograph of teeth #11 and #21 with non-blunderbuss canal and open apex associated PAI scores of 5 and 5 respectively. (b) Immediate postoperative intraoral periapical radiograph of tooth #11 showing MTA apical barrier 2 mm short of radiographic root end and tooth #21 showing MTA apical barrier up to radiographic root end. (c) & (d) Follow up intraoral periapical radiograph exhibiting resolution of the periapical lesion at 12 and 24 months

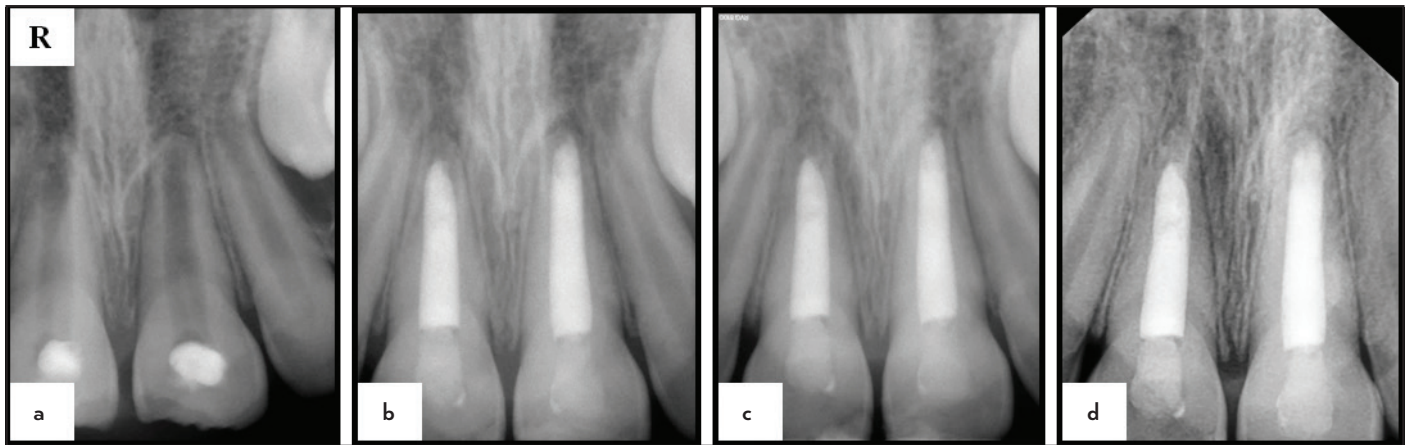


Figure 3. (a) Preoperative intraoral periapical radiograph of teeth #11 and #21 with non-blunderbuss canal and open apex associated PAI scores of 3 and 3 respectively. (b) Immediate postoperative intraoral periapical radiograph of tooth #11 showing MTA apical barrier 2 mm short and tooth #21 showing MTA apical barrier up to radiographic root end. (c) & (d) Follow up intraoral periapical radiograph exhibiting resolution of the periapical lesion at 12 and 24 months

radiographic PAI score, there was no significant difference ($P=1.0$). At 24 months follow up interval, on inter-group comparison between the proportion of teeth healed and non-healed (radiographic), no statistically significant difference was observed ($P=1.0$) (Table 1). This study reported a 100% success rate with a complete resolution of periapical radiolucency in both the groups.

DISCUSSION

This study was aimed to determine the optimal apical extent of the MTA apical barrier in a nonvital immature permanent anterior tooth with an open apex. Based on the results of this study, it was observed that there was no influence on treatment outcome (i.e. healing of apical periodontitis) between the two treatment protocols.

The definition of open apex varies according to the authors (17, 18). In this study, the anterior maxillary tooth that had radiographic evidence of non-blunderbuss canal (Cvek's stage 4) and in which an ISO size #80 K file could passively pass be-

yond the confines of the root-end was considered as an open apex. This type of root canal is an indication for an MTA apical barrier.

MTA has diverse clinical applications (19) and has been extensively used for apical barrier formation in a nonvital tooth with an immature apex (20, 21). In retrospective studies, the clinical and radiographic outcome of teeth treated by MTA apical barrier placement, a success rate of 90-93% was observed. This method produces a predictable apical barrier, reduces treatment time, and is an evidence-based technique for the management of permanent nonvital tooth with an open apex (22, 23). The thickness of the MTA apical barrier has been extensively evaluated, and a 4 mm MTA apical barrier is ideal for preventing bacterial leakage (24). Hence the same thickness was preferred.

The results of the present study demonstrated that despite placing MTA apical barrier up to the radiographic root end periapical healing was evident in all the teeth and there was

TABLE 1. Demographic profile, clinical and radiographic outcome

Case	Age (Years)	Gender	Tooth no.	Demographic profile clinical and radiographic outcome	Outcome 24 months	
					Radiographic postoperative PAI score	Clinical
1	14	M	11*	5	1	Asymptomatic
			21**	4	1	
2	15	M	11*	3	1	Asymptomatic
			21**	3	1	
3	10	M	21*	4	1	Asymptomatic
			11**	4	1	
4	17	M	11*	3	1	Asymptomatic
			21**	4	1	
5	14	F	21*	5	1	Asymptomatic
			11**	5	1	
6	18	M	21*	4	1	Asymptomatic
			11**	5	1	

*MTA placed up to the radiographic root end, **MTA placed 2 mm short of the radiographic root end

no significant difference ($P=1.00$) between the two treatment protocols. This could be attributed to the biocompatibility, antibacterial, sealing ability, osteoinductive and osteoconductive properties of MTA (25, 26). It provides a physical seal that prevents ingress and egress of irritants and thus facilitates periapical healing. At the dentine-MTA interface, calcium ion released reacts with the tissue phosphates yielding hydroxyapatite. Additionally, cementum deposition over MTA forms a biological seal yielding a double seal (27).

There could be certain advantages of placing MTA apical plug 2 mm short of the radiographic root end in a tooth with non-blunderbuss canal and open apex. In immature teeth, the dentinal walls tend to be thinner and fragile towards the root-end, leaving them susceptible to fracture. MTA has an inherent property of expansion on setting (28). This characteristic may initiate crack formation in fragile dentinal walls and subsequent tooth fracture (29). Another perceived advantage of placing MTA short of the radiographic apex could be the formation of a natural barrier beneath the MTA plug. There is a possibility that there may be an ingrowth of periodontal tissue into the apical end of the root canal and, under the influence of the MTA, the undifferentiated mesenchymal cells may differentiate into osteoblasts or cementoblasts (30). The unfilled apical end offers a structure supporting the development of a hard tissue barrier of increased thickness, when compared to traditional apexification. It may strengthen the apical root structure and serve as a natural barrier. In a recent case series, a modified apexification procedure was adopted for the management of immature permanent teeth with pulp necrosis/apical periodontitis. They advocated placing MTA plug 5 mm short of the radiographic root end. All cases showed resolution of periapical pathology, increased root length and apical closure. They postulated that apical barrier placed close to root apex might damage the Hertwig's epithelial root sheath (HERS) and apical papilla cells because of the high pH of MTA. In this study, they modified the apical barrier technique so that they could achieve root lengthening/ thickening. Their proposition was that this would allow placement of a post and core if required in a non-vital immature permanent tooth (31). In our opinion that still would not be possible as the root lengthening is taking place apical to the MTA plug. The root length, coronal to the MTA plug would remain the same. Hence post space length would not increase. Moreover, root lengthening under the influence of MTA is not consistent. When MTA was developed, it was intended to be used as a barrier against which gutta percha could be compacted. In revascularization also, MTA was placed to achieve a coronal seal only. The aim of our study was to evaluate the effect of apical extent of MTA plug on periapical healing. No root lengthening/thickening below the MTA that was placed 2 mm short of the root end was observed.

This was the first clinical study that evaluated the optimal apical extent of MTA plug for the management of a nonvital immature permanent anterior tooth with an open apex. However, it had a limited sample size. Hence, longitudinal studies with a larger sample size would be required to substantiate the results of the present study and give clear guidelines for the optimal apical extent of the mineral trioxide aggregate plug.

CONCLUSION

In a nonvital immature permanent anterior tooth, MTA apical plug can be placed either at or 2 mm short of the radiographic root end.

Disclosures

Conflict of interest: Authors declared no conflict of interest.

Ethics Committee Approval: The institutional research Ethics Committee approved the study protocol (Ref. No. IESC/T-422/26-08-2015, RT-25/2015) following the principles of Helsinki (version 2008).

Peer-review: Externally peer-reviewed.

Financial Disclosure: No financial support is taken.

Authorship contributions: Concept – A.L.; Design – K.M.T., A.L.; Supervision – K.M.T., A.L.; Funding – A.L.; Materials – None; Data collection &/or processing – K.M.T.; Analysis and/or interpretation – K.M.T., A.L.; Literature search – K.M.T.; Writing – K.M.T.; Critical Review – K.M.T., A.L.

REFERENCES

1. Torneck CD. Effects and clinical significance of trauma to the developing permanent dentition. *Dent Clin North Am* 1982; 26(3):481–504.
2. Andreasen JO, Farik B, Munksgaard EC. Long-term calcium hydroxide as a root canal dressing may increase risk of root fracture. *Dent Traumatol* 2002; 18(3):134–7.
3. Shah N, Logani A, Bhaskar U, Aggarwal V. Efficacy of revascularization to induce apexification/apexogenesis in infected, nonvital, immature teeth: a pilot clinical study. *J Endod* 2008; 34(8):919–25.
4. Parirokh M, Torabinejad M. Mineral trioxide aggregate: a comprehensive literature review-Part I: chemical, physical, and antibacterial properties. *J Endod* 2010; 36(1):16–27.
5. Torabinejad M, Parirokh M. Mineral trioxide aggregate: a comprehensive literature review--part II: leakage and biocompatibility investigations. *J Endod* 2010; 36(2):190–202.
6. Simon S, Rilliard F, Berdal A, Machtou P. The use of mineral trioxide aggregate in one-visit apexification treatment: a prospective study. *Int Endod J* 2007; 40(3):186–97.
7. Sarris S, Tahmassebi JF, Duggal MS, Cross IA. A clinical evaluation of mineral trioxide aggregate for root-end closure of non-vital immature permanent incisors in children—a pilot study. *Dent Traumatol* 2008; 24(1):79–85.
8. Valois CR, Costa ED Jr. Influence of the thickness of mineral trioxide aggregate on sealing ability of root-end fillings in vitro. *Oral Surg Oral Med Oral Pathol Oral Radiol Endod* 2004; 97(1):108–11.
9. Friend LA. The treatment of immature teeth with non-vital pulps. *J Br Endod Soc* 1967; 1(2):28–33.
10. Nosrat A, Nekoofar MH, Bolhari B, Dummer PM. Unintentional extrusion of mineral trioxide aggregate: a report of three cases. *Int Endod J* 2012; 45(12):1165–76.
11. Pace R, Giuliani V, Nieri M, Di Nasso L, Pagavino G. Mineral trioxide aggregate as apical plug in teeth with necrotic pulp and immature apices: a 10-year case series. *J Endod* 2014; 40(8):1250–4.
12. Cehreli ZC, Sara S, Uysal S, Turgut MD. MTA apical plugs in the treatment of traumatized immature teeth with large periapical lesions. *Dent Traumatol* 2011; 27(1):59–62.
13. Orstavik D, Kerekes K, Eriksen HM. The periapical index: a scoring system for radiographic assessment of apical periodontitis. *Endod Dent Traumatol* 1986; 2(1):20–34.
14. Cvek M. Prognosis of luxated non-vital maxillary incisors treated with calcium hydroxide and filled with gutta-percha. A retrospective clinical study. *Endod Dent Traumatol* 1992; 8(2):45–55.
15. Kim YJ, Chandler NP. Determination of working length for teeth with wide or immature apices: a review. *Int Endod J* 2013; 46(6):483–91.
16. Capar ID, Ozcan E, Arslan H, Ertas H, Aydinbelge HA. Effect of different final irrigation methods on the removal of calcium hydroxide from an artificial standardized groove in the apical third of root canals. *J Endod* 2014; 40(3):451–4.
17. Mente J, Seidel J, Buchalla W, Koch MJ. Electronic determination of root canal length in primary teeth with and without root resorption. *Int Endod J* 2002; 35(5):447–52.

18. Moore A, Howley MF, O'Connell AC. Treatment of open apex teeth using two types of white mineral trioxide aggregate after initial dressing with calcium hydroxide in children. *Dent Traumatol* 2011; 27(3):166–73.
19. Parirokh M, Torabinejad M. Mineral trioxide aggregate: a comprehensive literature review-Part III: Clinical applications, drawbacks, and mechanism of action. *J Endod* 2010; 36(3):400–13.
20. Bonte E, Beslot A, Boukpepsi T, Lasfargues JJ. MTA versus Ca(OH)₂ in apexification of non-vital immature permanent teeth: a randomized clinical trial comparison. *Clin Oral Investig* 2015; 19(6):1381–8.
21. Alobaid AS, Cortes LM, Lo J, Nguyen TT, Albert J, Abu-Melha AS, et al. Radiographic and clinical outcomes of the treatment of immature permanent teeth by revascularization or apexification: a pilot retrospective cohort study. *J Endod*. 2014; 40(8):1063–70.
22. Bücher K, Meier F, Diegritz C, Kaaden C, Hickel R, Kühnisch J. Long-term outcome of MTA apexification in teeth with open apices. *Quintessence Int* 2016; 47(6):473–82.
23. Jeeruphan T, Jantarat J, Yanpiset K, Suwannapan L, Khewsawai P, Hargreaves KM. Mahidol study 1: comparison of radiographic and survival outcomes of immature teeth treated with either regenerative endodontic or apexification methods: a retrospective study. *J Endod* 2012; 38(10):1330–6.
24. Al-Kahtani A, Shostad S, Schifferle R, Bhambhani S. In-vitro evaluation of microleakage of an orthograde apical plug of mineral trioxide aggregate in permanent teeth with simulated immature apices. *J Endod* 2005; 31(2):117–9.
25. Chen CL, Huang TH, Ding SJ, Shie MY, Kao CT. Comparison of calcium and silicate cement and mineral trioxide aggregate biologic effects and bone markers expression in MG63 cells. *J Endod* 2009; 35(5):682–5.
26. Tani-Ishii N, Hamada N, Watanabe K, Tujimoto Y, Teranaka T, Umemoto T. Expression of bone extracellular matrix proteins on osteoblast cells in the presence of mineral trioxide. *J Endod* 2007; 33(7):836–9.
27. Chong BS, Pitt Ford TR. Root-end filling materials: rationale and tissue response. *Endod Top* 2005; 11(1):114–30.
28. Storm B, Eichmiller FC, Tordik PA, Goodell GG. Setting expansion of gray and white mineral trioxide aggregate and Portland cement. *J Endod* 2008; 34(1):80–2.
29. Silujjai J, Linsuwanont P. Treatment Outcomes of apexification or revascularization in nonvital immature permanent teeth: a retrospective study. *J Endod* 2017; 43(2):238–45.
30. Hakki SS, Bozkurt SB, Hakki EE, Belli S. Effects of mineral trioxide aggregate on cell survival, gene expression associated with mineralized tissues, and biomineralization of cementoblasts. *J Endod* 2009; 35(4):513–9.
31. Songtrakul K, Azarpajouh T, Malek M, Sigurdsson A, Kahler B, Lin LM. Modified apexification procedure for immature permanent teeth with a necrotic pulp/apical periodontitis: a case series. *J Endod* 2020; 46(1):116–23.