

A case of survival after chlorfenapyr intoxication with acute pancreatitis

Jae Eun Ku, Young Seon Joo, Je Sung You, Sung Phil Chung, Hahn Shick Lee

Department of Emergency Medicine, Yonsei University College of Medicine, Seoul, Korea

Chlorfenapyr is a moderately hazardous insecticide. There have been previous reports of chlorfenapyr intoxication, but none have reported patient survival or an association with pancreatitis. A 61-year-old woman was brought to the emergency department with vomiting after ingesting 10 mL chlorfenapyr in a suicide attempt 1 hour before. The patient was treated with gastric lavage and activated charcoal, then transferred to the intensive care unit. Initial laboratory data were unremarkable except for elevated amylase/lipase levels (134/222 U/L), which were even higher 7 days later and remained elevated for 2 weeks. Abdominal computed tomography showed diffuse pancreatic swelling. The patient improved with conservative care and was discharged to home 19 days after admission. This is the first reported case of survival after chlorfenapyr intoxication. We recommend early aggressive management in the emergency department and close monitoring in the intensive care unit to detect and treat potentially fatal deterioration after chlorfenapyr intoxication.

Keywords Chlorfenapyr; Intoxication; Survival; Acute pancreatitis

eISSN: 2383-4625

Received: 14 January 2015

Revised: 12 February 2015

Accepted: 3 March 2015

Correspondence to: Sung Phil Chung
Department of Emergency Medicine,
Gangnam Severance Hospital,
211 Eonju-ro, Gangnam-gu,
Seoul 135-720, Korea
E-mail: emstar@yuhs.ac



How to cite this article:

Ku JE, Joo YS, You JS, Chung SP, Lee HS.
A case of survival after chlorfenapyr
intoxication with acute pancreatitis.
Clin Exp Emerg Med 2015;2(1):63-66.

This is an Open Access article distributed
under the terms of the Creative Commons
Attribution Non-Commercial License (<http://creativecommons.org/licenses/by-nc/3.0/>).

Capsule Summary

What is already known

Most prior cases of chlorfenapyr intoxication have been fatal.

What is new in the current study

We report a case of non-fatal chlorfenapyr intoxication resulting in pancreatitis. Physicians should provide early aggressive management and close monitoring to detect and treat potentially fatal deterioration after chlorfenapyr intoxication.

INTRODUCTION

Chlorfenapyr is classified as a moderately hazardous insecticide by the World Health Organization.¹ According to the limited number of published reports, chlorfenapyr intoxication is characterized by a high fever, rhabdomyolysis, and neurologic symptoms that progressively worsen until death.²⁻⁶ Survival or an association with pancreatitis from chlorfenapyr intoxication has not yet been reported in the literature.

CASE REPORT

A 61-year-old woman with a history of hypertension and chronic alcohol use was brought to the emergency department (ED) with vomiting. She had ingested 10 mL chlorfenapyr in a suicide attempt 1 hour previously. She usually drank alcohol 2 to 3 times a week. Her initial vital signs were stable, but she was drowsy. The patient was treated with endotracheal intubation, gastric lavage, and activated charcoal and subsequently transferred to the intensive care unit (ICU). Her initial laboratory data were unremarkable except for elevated blood levels of amylase/lipase (134/ 222 U/L) and ethanol (140.6 mg/dL). Follow-up laboratory results revealed a pH of 7.16, pCO₂ of 47.4 mmHg, pO₂ of 110.4 mmHg, and HCO₃⁻ of 15.7 mmol/L on arterial blood gas analysis (ABGA). Seven hours later, laboratory data still showed a metabolic acidosis and very high amylase/lipase levels (418/905 U/L), and the patient was administered sodium bicarbonate and ulinastatin to correct these abnormalities. This treatment improved her metabolic acidosis to pH 7.37, pCO₂ 48.2 mmHg, pO₂ 107.5 mmHg, and HCO₃⁻ 28.2 mmol/L on arterial blood gas analysis 10 hours later. Nevertheless, her amylase/lipase levels remained elevated

for 2 weeks, reaching a peak of 846/2,010 U/L 9 days after admission. Abdominal computed tomography (CT) 9 hours after admission showed diffuse swelling of the pancreas without necrosis or fluid collection (Fig. 1A). The pancreatitis was rated as severe, as the patient's Acute Physiology and Chronic Health Evaluation (APACHE) II score was 11 and her Harmless Acute Pancreatitis (HAP) score was 1. On day 2 after admission, the patient's temperature was higher than 38.3°C. The serum creatine phosphokinase was elevated at 859 U/L but never exceeded 1,000 U/L.

With close monitoring in the ICU, the patient's condition improved clinically; she became alert and was extubated on day 4. However, because her amylase/lipase levels continued to rise (Table 1), a follow-up abdominal CT was performed, which still showed diffuse pancreatic swelling (Fig. 1B). Although the patient's symptoms had improved, we extended her hospital stay because previous reports not only warned of possible delayed fatal consequences of chlorfenapyr intoxication, but they also failed to mention the presence of pancreatitis. There were no systemic complications during the admission period. After further observation for 2 weeks, the patient was discharged to home at 19 days after the initial admission; she had no sequelae. One month later, she visited the outpatient gastroenterology clinic, and her amylase/lipase

Table 1. Laboratory data of patient experiencing chlorfenapyr intoxication with acute pancreatitis

Parameter	Unit	Reference range	Initial	After 7 hours	After 7 days
Amylase	U/L	30–115	134	418	538
Lipase	U/L	5–60	222	905	1,259
Aspartate aminotransferase	IU/L	13–34	50	48	69
Alanine aminotransferase	IU/L	5–46	20	17	61
Total bilirubin	mg/dL	0.4–1.5	0.5	0.6	0.9

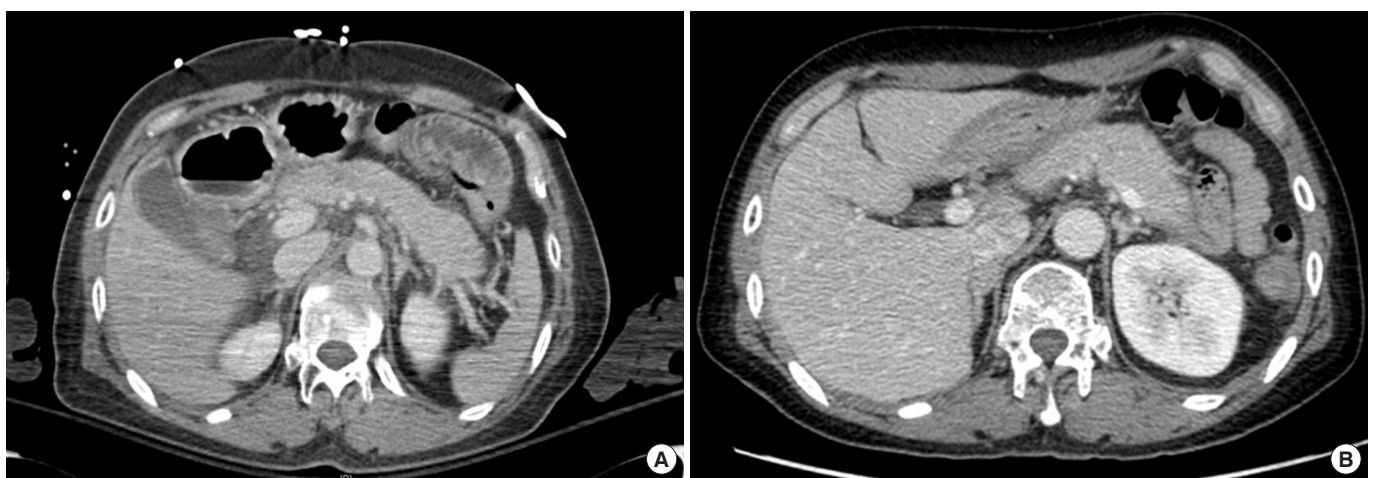


Fig. 1. Abdominal computed tomography (CT) image of the pancreas showing diffuse swelling without necrosis or fluid collection. (A) Initial abdominal CT and (B) follow-up (7 days after admission) abdominal CT.

levels were 97/84 U/L without symptoms.

DISCUSSION

Chlorfenapyr, a pyrrole insecticide, is a pro-insecticide that is converted to an active metabolite by mixed-function oxidases. The metabolite uncouples oxidative phosphorylation by disrupting the proton gradient across mitochondrial membranes, thereby reducing energy production by blocking conversion of adenosine diphosphate to adenosine triphosphate. This leads to cell dysfunction and subsequent death of the organism.^{1,7} There have been a few reports of chlorfenapyr intoxication, but survival or an association with pancreatitis after chlorfenapyr intoxication has not been previously reported.

Chlorfenapyr intoxication has been universally fatal in all previous case reports in humans.²⁻⁶ Most patients with chlorfenapyr intoxication died after a latent period of 7 to 20 days. Whereas the majority of previous cases exhibited high fever, diaphoresis, rhabdomyolysis, neurologic exacerbations, and death, our patient had mild rhabdomyolysis, fever, and acute pancreatitis. One difference between our case and previous reports relates to the dose. Previous doses were reported to be approximately 20 to 250 mL chlorfenapyr, whereas the dose consumed by our patient was only 10 mL, which may have contributed to the lower apparent toxicity. These facts suggest that fatal sequelae from chlorfenapyr intoxication correlate with the dose of the toxin. Although the dose consumed by our patient was relatively small, ingestion of chlorfenapyr led to pancreatitis.

There are many causes of acute pancreatitis; common causes are gallstones and chronic alcohol abuse.⁸ We could not find any evidence of gallstones or biliary pancreatitis in the laboratory results and abdominal CT findings (Fig. 1, Table 1). Because a sudden rise in amylase/lipase levels may signify the presence of pancreatitis, we obtained abdominal CT scans (Fig. 1A) to determine the cause of the rise. Despite higher amylase/lipase levels at 7 days after admission, the follow-up abdominal CT (Fig. 1B) was similar to the initial abdominal CT. Although the severity of the pancreatitis was classified as grade B according to the CT,⁹ the pancreatitis was severe according to the HAP¹⁰ and APACHE II¹¹ scores. HAP scoring is a system for predicting acute pancreatitis severity that can help guide initial management and help in determining the disposition of patients.¹² In our case, both chronic alcohol use and acute toxin ingestion may have been involved. The mechanism of drug-induced acute pancreatitis is not always clear; however, in our case, the first mechanism quite possibly involved direct toxicity to a vulnerable patient,¹³ as indicated by the initial elevation of amylase/lipase levels without a latency period.

The second mechanism may be triggered by accumulation of toxic metabolites,¹⁴ as suggested by the amylase/lipase levels being four times higher than the initial levels after 7 hours. Although pancreatitis had not been reported in previous cases involving large doses of chlorfenapyr, it occurred in our case after a small dose. This difference needs to be studied in future cases.

Metabolic acidosis, which was not observed during the initial admission of our patient but occurred after 4 hours, has also been reported after a latency period in previous cases, suggesting that chlorfenapyr metabolites uncouple oxidative phosphorylation, leading to acidosis. However, because we did not check the lactic acid level, this needs to be confirmed by a further study.

As previous reports of chlorfenapyr intoxication have been associated with a high mortality rate after a latent period even if vital signs are initially stable, immediate aggressive management in the ED and close monitoring in the ICU are necessary to allow early detection and treatment if deterioration occurs. In this case, we surmise that the patient survived because of the relatively small dose of chlorfenapyr, early detection and initial aggressive management in the ED, and close monitoring in the ICU. We thereby recommend initial aggressive ED management and close ICU monitoring to facilitate detection and treatment of potentially fatal consequences in an effort to optimize survival after chlorfenapyr intoxication.

CONFLICT OF INTEREST

No potential conflict of interest relevant to this article was reported.

REFERENCES

1. World Health Organization. The WHO recommended classification of pesticides by hazard and guidelines to classification 2009 [Internet]. Geneva: World Health Organization; 2010 [cited 2015 Jan 10]. Available from: http://www.who.int/ipcs/publications/pesticides_hazard/en/.
2. Hoshiko M, Naito S, Koga M, Mori M, Hara K, Ishitake T. Case report of acute death on the 7th day due to exposure to the vapor of the insecticide chlorfenapyr. *Chudoku Kenkyu* 2007; 20:131-6.
3. Choi UT, Kang GH, Jang YS, Ahn HC, Seo JY, Sohn YD. Fatality from acute chlorfenapyr poisoning. *Clin Toxicol (Phila)* 2010; 48:458-9.
4. Kwon JS, Kim HY, Han HJ, Kim JY, Park JH. A case of chlorfenapyr intoxication with central nervous system involvement. *J Clin Toxicol* 2012;2:147-8.

5. Tharaknath VR, Prabhakar YV, Kumar KS, Babu NK. Clinical and radiological findings in chlorfenapyr poisoning. *Ann Indian Acad Neurol* 2013;16:252-4.
6. Kang C, Kim DH, Kim SC, Kim DS. A patient fatality following the ingestion of a small amount of chlorfenapyr. *J Emerg Trauma Shock* 2014;7:239-41.
7. Raghavendra K, Barik TK, Sharma P, et al. Chlorfenapyr: a new insecticide with novel mode of action can control pyrethroid resistant malaria vectors. *Malar J* 2011;10:16.
8. Forsmark CE, Baillie J; AGA Institute Clinical Practice and Economics Committee; AGA Institute Governing Board. AGA Institute technical review on acute pancreatitis. *Gastroenterology* 2007;132:2022-44.
9. Balthazar EJ, Robinson DL, Megibow AJ, Ranson JH. Acute pancreatitis: value of CT in establishing prognosis. *Radiology* 1990;174:331-6.
10. Lankisch PG, Weber-Dany B, Hebel K, Maisonneuve P, Lowenfels AB. The harmless acute pancreatitis score: a clinical algorithm for rapid initial stratification of nonsevere disease. *Clin Gastroenterol Hepatol* 2009;7:702-5.
11. Knaus WA, Draper EA, Wagner DP, Zimmerman JE. APACHE II: a severity of disease classification system. *Crit Care Med* 1985; 13:818-29.
12. Phillip V, Steiner JM, Algul H. Early phase of acute pancreatitis: assessment and management. *World J Gastrointest Pathophysiol* 2014;5:158-68.
13. Książczyńska D. Drug-induced acute pancreatitis related to medications commonly used in gastroenterology. *Eur J Intern Med* 2011;22:20-5.
14. Kaurich T. Drug-induced acute pancreatitis. *Proc (Bayl Univ Med Cent)* 2008;21:77-81.