




## Case Report

# Chondrosarcoma secondary to hereditary multiple osteochondromas with spinal cord compression: A case report and systematic review

José Elmano Silva<sup>1</sup>, Gabriel de Almeida Monteiro<sup>1</sup>, Stefanie Torres e Silva<sup>1</sup>, Gabriel Marinheiro dos Santos Bezerra<sup>1</sup>, Joaquim Francisco Cavalcante-Neto<sup>1</sup>, Diego de Aragão Bezerra<sup>2,3</sup>, Janssen Loiola Melo Vasconcelos<sup>3</sup>, Paulo Roberto Lacerda Leal<sup>1,4</sup>

Departments of <sup>1</sup>Neurosurgery and <sup>2</sup>Surgical Oncology, Federal University of Ceará, Departments of <sup>3</sup>Surgical Oncology, and <sup>4</sup>Neurosurgery, Santa Casa de Misericórdia's Hospital, Sobral, Ceará, Brazil.

E-mail: \*José Elmano Silva - elmanosilva28@gmail.com; Gabriel de Almeida Monteiro - gabrielmont00@gmail.com; Stefanie Torres e Silva - stefanie-torres88@hotmail.com; Gabriel Marinheiro dos Santos Bezerra - gabrielmsantosb@gmail.com; Joaquim Francisco Cavalcante-Neto - joaquimfcn@hotmail.com; Diego de Aragão Bezerra - diegobezerra.onco@gmail.com; Janssen Loiola Melo Vasconcelos - janssen.loiola@hotmail.com; Paulo Roberto Lacerda Leal - prlleal@hotmail.com



### \*Corresponding author:

José Elmano Silva,  
Department of Neurosurgery,  
Federal University of Ceará,  
Sobral, Ceará, Brazil.

elmanosilva28@gmail.com

Received: 23 September 2023

Accepted: 05 October 2023

Published: 03 November 2023

### DOI

10.25259/SNI\_797\_2023

### Quick Response Code:



## ABSTRACT

**Background:** Hereditary multiple osteochondromas (HMOs) are a rare genetic disorder characterized by the formation of multiple benign osteochondromas that can undergo malignant transformation into chondrosarcoma.

**Case Description:** A 24-year-old male with a history of HMO and osteochondroma surgery 4 years ago, presented with back pain and paresthesias. The magnetic resonance showed a right paravertebral infiltrating mass at the T12–L1 level causing spinal cord compression. Following *en bloc* resection of the tumor, the patient's symptoms/signs resolved. The final pathological diagnosis was consistent with a chondrosarcoma.

**Conclusion:** Chondrosarcomas secondary to HMO with spinal cord compression are rare. These patients often presenting with significant myelopathy/cord compression should undergo gross total resection where feasible to achieve the best outcomes.

**Keywords:** Diaphyseal aclasis, Hereditary multiple exostoses, Hereditary multiple osteochondromas, Secondary chondrosarcoma, Spinal cord compression

## INTRODUCTION

Hereditary multiple osteochondromas (HMOs) are a rare autosomal dominant disease characterized by multiple osteochondromas.<sup>[1]</sup> In 0.5–5% of cases, they can undergo malignant transformation into chondrosarcomas that can cause cord compression.<sup>[1]</sup> Here, a 24-year-old male with HMO originally presented with osteochondromas that evolved into low-grade chondrosarcoma at the T12/L1 level warranting gross-total resection.

## CASE PRESENTATION

A 24-year-old male presented with back pain/paresthesias associated with a growing right-sided, posterior, infiltrating mass magnetic resonance (MR)-documented T12–L1 [Figure 1]. Notably,

This is an open-access article distributed under the terms of the Creative Commons Attribution-Non Commercial-Share Alike 4.0 License, which allows others to remix, transform, and build upon the work non-commercially, as long as the author is credited and the new creations are licensed under the identical terms.

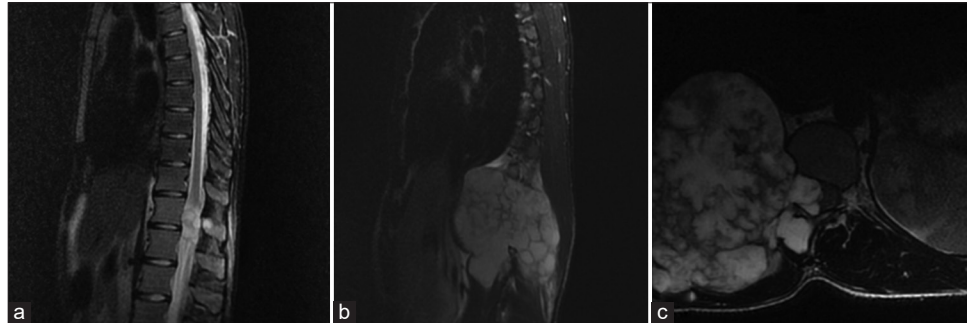
©2023 Published by Scientific Scholar on behalf of Surgical Neurology International

4 years ago, the patient underwent a surgical excision of an osteochondroma in the right distal femur. Through T12–L2 laminectomy tumor was found to invade the T12–L1 vertebral pedicles and T12–L2 nerve roots; they were resected. Next, a transpedicular arthrodesis (T11–L2) was performed. In addition, the tumor was removed from the costal cartilage of the 10–12 ribs (i.e., due to invasion of the thoracic cage/right hemithorax) [Figure 2]. The biopsy was consistent with malignant transformation into a low-grade chondrosarcoma [Figure 3]. Postoperatively, the patient

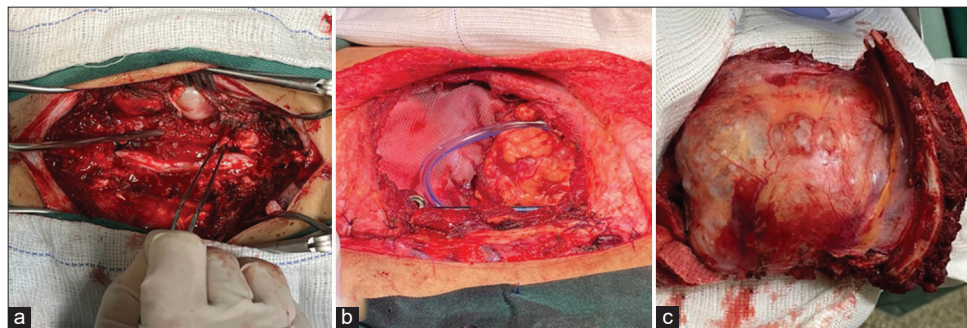
had a pneumothorax that was appropriately treated. The postoperative MR imaging confirmed complete tumoral resection [Figure 4]. He was then discharged neurologically intact.

### Literature epidemiology

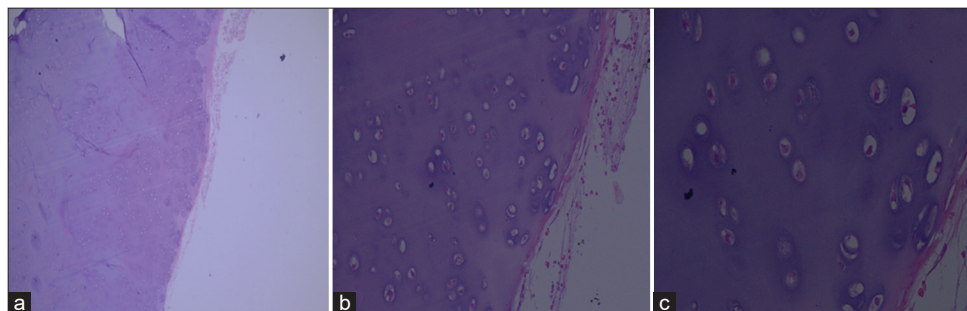
HMO is a rare genetic disorder, with an incidence of 1.5% in the Western population.<sup>[2]</sup> In our review, 80% have a positive family history and more than 80% of the diagnosis is made



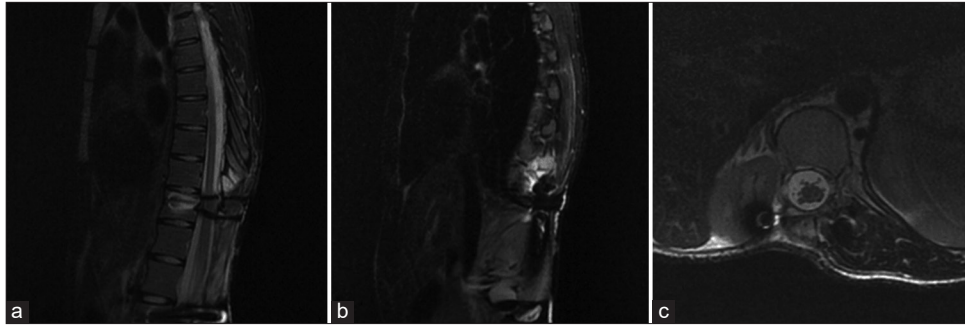
**Figure 1:** Preoperative magnetic resonance imaging. (a) Midsagittal T2-weighted image (T2WI) with fat suppression revealing a hyperintense lesion causing medullary invasion at the T12–L1 levels. (b) Midsagittal T2WI with fat suppression showing a hyperintense expansive lesion in the right paravertebral area. (c) Axial T2WI with fat suppression revealed a significant spinal cord compression by the tumoral mass.



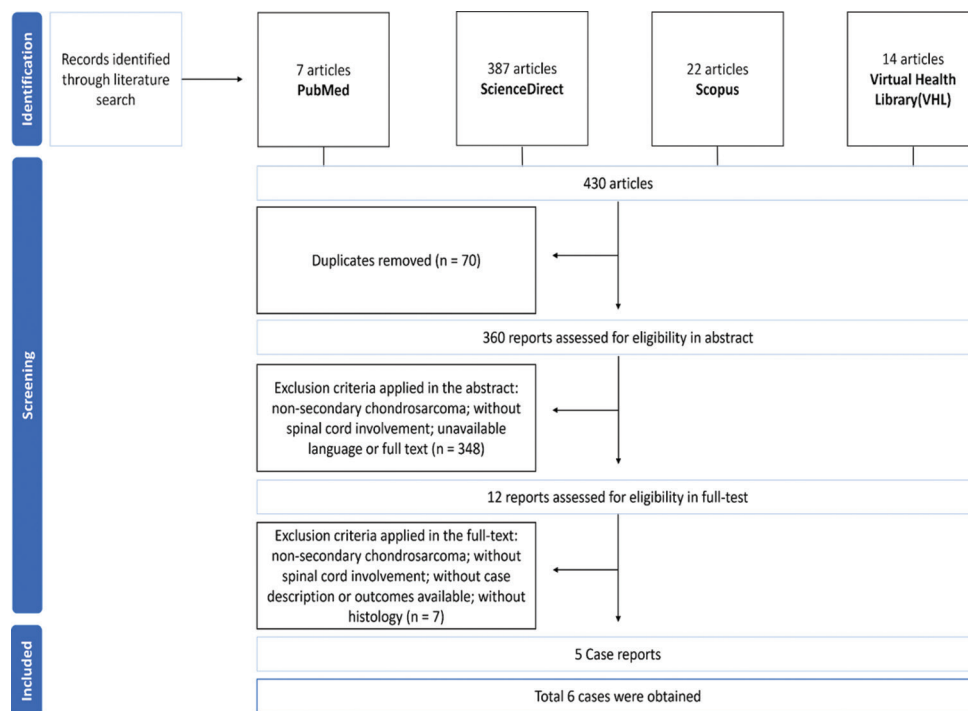
**Figure 2:** Intraoperative images. (a) View of the tumor after posterior laminectomy. (b) View of the paravertebral area after the tumor resection. (c) Tumoral mass after surgical resection.



**Figure 3:** Biopsy examination (histology). (a) Abundant cartilaginous proliferation with chondrocytes embedded in lacunae. (b and c) Minimally increased cellularity and occasional binucleated nuclei and lobular growth pattern.



**Figure 4:** Postoperative magnetic resonance imaging. (a and b) Midsagittal T2-weighted image (T2WI) with fat suppression showing complete resection of the tumoral components. (c) Axial T2WI with fat suppression revealing resolution of the spinal cord compression after the tumor removal, with the right kidney posterior displacement due to surgical procedure.



**Figure 5:** Study flowchart describing the literature search and analysis process.

before the end of the first decade.<sup>[2]</sup> Five articles met our inclusion criteria and included seven patients [Figure 5]. The mean age was 22 years (range 13-30 years), with four males and three females. Symptoms included pain (five patients) and paresthesia (four patients). The spinal cord was involved in two cases in the cervical spine, two cases in the thoracic spine exclusively, two cases in the lumbar spine exclusively, and one case in the thoracic/lumbar spine. Historically, six of seven patients had osteochondromas previously identified in other regions. Complete resection was performed in six cases, and supplemented with adjuvant chemotherapy in one of these cases. Pathologically, five patients had low-grade chondrosarcomas, while two patients had high-grade lesions.

Complete recovery was seen in 3/5 patients, partial recovery in 1/5 patients, and 1/5 patients no recovery [Table 1].

### Complications of malignant transformation

Malignant transformation into secondary chondrosarcoma is still the most feared of all complications of HMO.<sup>[1,7,9]</sup> Paulino Pereira *et al.* reported the following complications occurring up to 90 days after chondrosarcomas resections; dural rupture, respiratory failure, deep infection, fistula (pleuro-incisional), cardiac arrest during surgery, pneumothorax, sepsis, instrumentation failure, recurrence with spinal cord injuries, sternal osteomyelitis, and atrial thrombus.<sup>[10]</sup>

**Table 1:** A literature review of reported cases describing patients with spinal cord involvement due to chondrosarcoma secondary to hereditary multiple osteochondromas.

Author, year (country)	Age	Sex	Level	Family history	Other region osteochondromas	Case presentation	Treatment	Histology	Outcome
Crowell and Wepsic, 1972 (USA) <sup>[5]</sup>	13 years old	M	T1-T2	Yes	Right ulna and bilaterally humerus, radius, and femur	Lower limb paresis	Complete resection ( <i>en bloc</i> )	Low-grade chondrosarcoma	Partial recovery
Crowell and Wepsic, 1972 (USA) <sup>[5]</sup>	18 years old	M	T7-T8	Yes	Rights humerus and femurs	Lower limb paresis	Complete resection ( <i>en bloc</i> )	Low-grade chondrosarcoma	Complete recovery
Hatori et al., 2009 (Japan) <sup>[7]</sup>	28 years old	F	C2-C6	NA	Left scapula, right humerus, and femur	Pain and mild restriction of neck extension	Complete resection and chemotherapy	High-grade chondrosarcoma	No recovery
Anantharamaiah et al., 2012 (India) <sup>[11]</sup>	22 years old	M	L3-L5	No	No	Low back pain	No resection	High-grade chondrosarcoma	NA
Landi 2012 (Italy) <sup>[8]</sup>	30 years old	F	C6	Yes	Right elbow and left knee	Pain and paresthesia	Complete resection ( <i>en bloc</i> )	Low-grade chondrosarcoma	Complete recovery
Mesfin et al., 2013 (USA) <sup>[9]</sup>	19 years old	F	L3-L5	NA	Rights femur and tibia	Low back pain	Complete resection ( <i>en bloc</i> )	Low-grade chondrosarcoma	NA
Present study, 2023 (Brazil)	24 years old	M	T12-L2	Yes	Right femur	Low back pain and paresthesia	Complete resection ( <i>en bloc</i> )	Low-grade chondrosarcoma	Complete recovery

NA: Not available, M: Male, F: Female

### Pathology of HMO

Secondary chondrosarcoma occurs in only 0.5–5% of cases and is characterized by malignant transformation of anterior cartilaginous lesions. Myxoid change may be characterized by the loss of the lacunar pattern with pleomorphic spindle or stellate cells floating in a myxoid stroma.<sup>[6]</sup> The histological grade determines the prognosis of secondary chondrosarcomas; 10-year survival rates of 83% were reported for Grade I versus 29% for Grade III lesions.<sup>[11]</sup> We found that the complete resolution rate was higher in patients with low-grade chondrosarcomas.

### Genetics of HMO

HMO is a genetically heterogeneous disease caused by tumor suppressor genes Exostosin-1 (EXT1) on chromosome 8, and Exostosin-2 (EXT2) on chromosome 11.<sup>[8]</sup> The patient's peripheral blood can be screened for germline mutations in EXT1 or EXT2 (i.e., point mutations or crude deletions in almost 90% of HMO patients).<sup>[4]</sup> Some studies have suggested the involvement of a third gene (EXT3) on chromosome 19, which could also be associated with HMO.<sup>[6]</sup>

### Surgical resection to optimize survival of chondrosarcomas

Optimally, HMO lesions are treated surgically, and best with *en bloc* resection of thoracic tumors. Thoracic surgical options include; anterior, posterior, anterior approach first and posterior second, and finally, the posterior approach first followed by simultaneous anterior/posterior surgery.<sup>[3]</sup> For low-grade chondrosarcomas (Grade I), the best long-term survival depends on good local control (i.e., *en bloc* resection with negative margins (R0 resection) is currently the best predictor of overall survival). Intermediate-grade (Grade II) and high-grade (Grade III) chondrosarcomas should also be treated with R0 resection. For lesions treated with positive or marginal margins (R1/R2), recurrence is inevitable.<sup>[11]</sup>

### Resistance to radiation therapy (RT)

Chondrosarcomas are resistant to RT. Therefore, RT should only be reserved for those who are not candidates for surgery.<sup>[5,11]</sup>

## CONCLUSION

Malignant transformation to chondrosarcoma may occur in patients with underlying HMO. Once, identified optimal outcomes are associated with gross total *en bloc* excision.

## Declaration of patient consent

The authors certify that they have obtained all appropriate patient consent.

## Financial support and sponsorship

Nil.

## Conflicts of interest

There are no conflicts of interest.

## Use of artificial intelligence (AI)-assisted technology for manuscript preparation

The authors confirm that there was no use of artificial intelligence (AI)-assisted technology for assisting in the writing or editing of the manuscript and no images were manipulated using AI.

## REFERENCES

1. Anantharamaiah H, Kalyani R, Kumar ML, Manohar PV. Secondary chondrosarcoma of the lumbosacral region: Are any bones spared in the multiple hereditary exostoses? *J Clin Diagn Res* 2012;6:1778-80.
2. Beltrami G, Ristori G, Scoccianti G, Tamburini A, Capanna R. Hereditary multiple exostoses: A review of clinical appearance and metabolic pattern. *Clin Cases Miner Bone Metab*

- 2016;13:110-8.
3. Boriani S, Bandiera S, Colangeli S, Ghermandi R, Gasbarrini A. *En bloc* resection of primary tumors of the thoracic spine: Indications, planning, morbidity. *Neurol Res* 2014;36:566-76.
4. Bovée JV. Multiple osteochondromas. *Orphanet J Rare Dis* 2008;3:3.
5. Crowell RM, Wepsic JG. Thoracic cord compression due to chondrosarcoma in two cousins with hereditary multiple exostoses. Report of two cases. *J Neurosurg* 1972;36:86-9.
6. Hameetman L, Bovée JV, Taminiau AH, Kroon HM, Hogendoorn PC. Multiple osteochondromas: Clinicopathological and genetic spectrum and suggestions for clinical management. *Hered Cancer Clin Pract* 2004;2:161-73.
7. Hatori M, Watanabe M, Tanaka Y, Ozawa K, Itoi E. Dedifferentiated chondrosarcoma of the cervical spine in a patient with multiple osteochondromas. *Eur J Orthop Surg Traumatol* 2009;19:577-80.
8. Landi A, Rocco P, Mancarella C, Tarantino R, Raco R. Malignant transformation of cervical osteochondroma in patient with hereditary multiple exostoses (HME): Case report and review of the literature. *J Solid Tumors* 2012;2:63.
9. Mesfin A, Ghermandi R, Castiello E, Donati DM, Boriani S. Secondary chondrosarcoma of the lumbar spine in hereditary multiple exostoses. *Spine J* 2013;13:1158-9.
10. Paulino Pereira NR, Janssen SJ, Stoop N, Hartveldt S, Chen YE, DeLaney TF, *et al.* Physical function and quality of life after resection of mobile spine chondrosarcoma. *Global Spine J* 2019;9:743-53.
11. Pennington Z, Ehresman J, Pittman PD, Ahmed AK, Lubelski D, McCarthy EF, *et al.* Chondrosarcoma of the spine: A narrative review. *Spine J* 2021;21:2078-96.

**How to cite this article:** Silva JE, Monteiro GA, Silva ST, Bezerra GMDS, Cavalcante-Neto JF, Bezerra DA, *et al.* Chondrosarcoma secondary to hereditary multiple osteochondromas with spinal cord compression: A case report and systematic review. *Surg Neurol Int* 2023;14:387.

## Disclaimer

The views and opinions expressed in this article are those of the authors and do not necessarily reflect the official policy or position of the Journal or its management. The information contained in this article should not be considered to be medical advice; patients should consult their own physicians for advice as to their specific medical needs.