



## Original research

## Intraoperative Radiographic Detection of Intrapelvic Acetabular Screw Penetration: Lessons Learned From Our Trauma Colleagues

Jacob M. Wilson, MD <sup>\*</sup>, Jeremiah A. Pflederer, MD, Andrew M. Schwartz, MD, Kevin X. Farley, BA, Nickolas B. Reimer, MD

Department of Orthopaedic Surgery, Atlanta, GA

## ARTICLE INFO

## Article history:

Received 4 September 2020  
Received in revised form  
13 November 2020  
Accepted 13 February 2021  
Available online xxx

## Keywords:

Acetabular  
Total hip  
Fluoroscopy  
Screw  
Radiology  
Arthroplasty

## ABSTRACT

**Background:** Intraoperative vascular injury during total hip arthroplasty represents a catastrophic complication. Acetabular screw placement represents one possible mode of injury. The purpose of this study was to evaluate the utility of various fluoroscopic views in the detection of intrapelvic screw penetration.

**Methods:** A radiopaque pelvis Sawbones model was instrumented with a hemispherical acetabular component. Four intrapelvic quadrants were defined. Screws were placed, 3 in each quadrant, and imaged sequentially at 3 depths: 0 mm, 5 mm, and 10 mm penetrated. Eight fluoroscopic images were used: anteroposterior, inlet, outlet, iliac oblique, obturator oblique, “down the wing,” obturator outlet, and a “quad” view. Three blinded, independent surgeons evaluated the images for intrapelvic screw penetration. Images were analyzed in isolation and as a “triple-shot series” consisting of the “quad,” obturator outlet, and iliac oblique views. Sensitivity and specificity values were then calculated.

**Results:** In isolation, the “quad” view had the highest sensitivity for screw penetration (62%). The triple-shot series was found to be 100% sensitive in all 4 quadrants for detecting 10 mm of screw penetration. The specificity of the series was found to be 100% in all quadrants except for the posterior superior quadrant where it was 67%. Interobserver agreement approached perfection (Kappa  $\geq 0.947$ ) between all surgeons ( $P < .001$ ) when using the 3-view series.

**Conclusions:** This study is the first to assess the use of fluoroscopy in the detection of intrapelvic penetration of transacetabular screws. We found that a 3-radiograph series provided a sensitive and specific metric for the detection of intrapelvic screw penetration.

© 2021 The Authors. Published by Elsevier Inc. on behalf of The American Association of Hip and Knee Surgeons. This is an open access article under the CC BY-NC-ND license (<http://creativecommons.org/licenses/by-nc-nd/4.0/>).

## Introduction

Total hip arthroplasty (THA) is well established as one of the most successful procedures performed in medicine [1]. As such, it is unsurprising that the incidence of this procedure continues to climb [2–4]. While the complication profile of primary THA is generally favorable, [5] the potential for both intraoperative and postoperative complications persists. While not universally used, surgeons range from selective to generalized usage of acetabular screw augmentation of press-fit fixation.

The placement of transacetabular screws is recognized to have associated risk, and close attention must be paid to the extrapelvic acetabular quadrant in which these are placed [6–9]. A multitude of complications have been reported with aberrant screw placement including arterial laceration, [10] arterial pseudoaneurysm formation, [11–14] bladder injury, [15] and nerve irritation, [16] among others [17]. Arterial injury, in particular, during THA has been reported to occur in 0.08%–0.3% of cases [18–21]. In recent years, the direct anterior approach, and its associated use of fluoroscopy, has been popularized [22]. Fluoroscopy is useful in evaluating component position [23,24] and may also be useful in assessing trajectory of transacetabular screws. However, the effectiveness of intraoperative fluoroscopy to determine acetabular screw position has not been assessed.

Prior investigations regarding the radiographic evaluation of acetabular screws have been limited in both the views evaluated

Investigation performed at Emory University, Atlanta, Georgia.

<sup>\*</sup> Corresponding author. Jacob M Wilson, 59 S Executive Park NW, Atlanta, GA 30329. Tel.: +1 404-778-7777.

E-mail address: [Jacobmwilson12@gmail.com](mailto:Jacobmwilson12@gmail.com)

and reliance on formal radiography—making the generalization to intraoperative evaluation difficult [25]. Given the implications of aberrant screw penetration and the potential for catastrophic acute and chronic complications after THA, the diagnostic capacity of fluoroscopy must be clarified. Therefore, the purpose of this study was to evaluate the sensitivity and specificity of fluoroscopic detection of intrapelvic acetabular screw penetration. We hypothesized that a 3-image series would provide a sensitive and specific measure.

## Methods

### Sawbones model

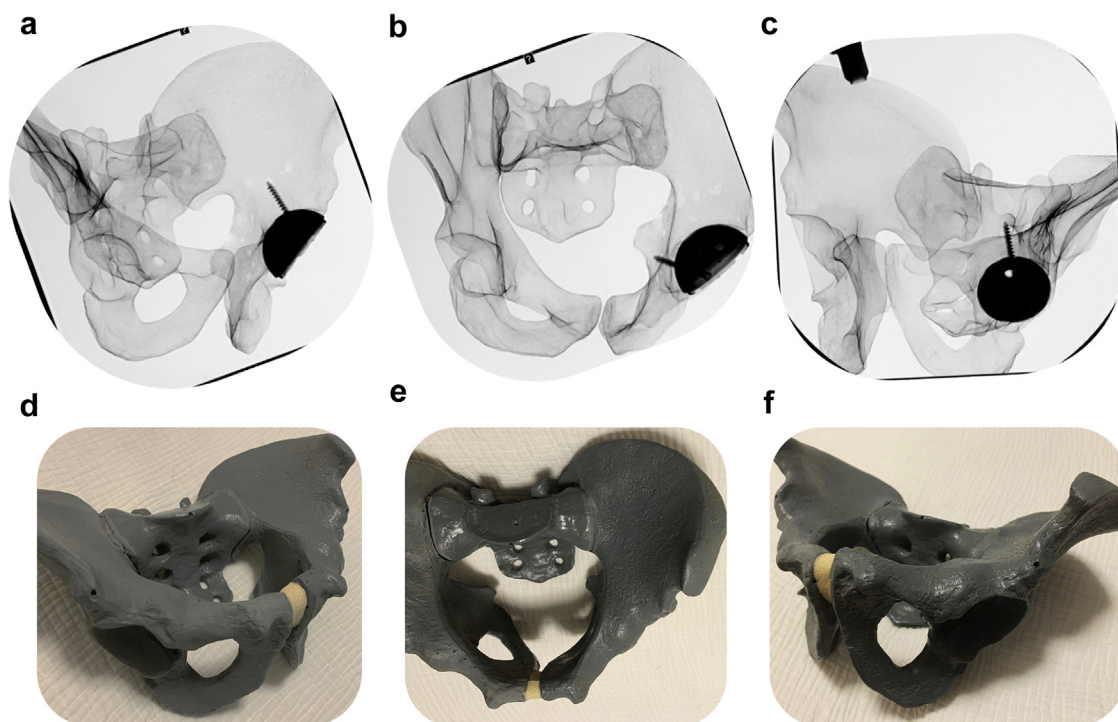
For the purposes of this study, a Sawbones pelvis model with a radiopaque coating was used (Sawbones, SKU: 1301-212; A Pacific Research Company, Vashon Island, WA). The acetabulum of the pelvis was then divided into 4 quadrants as previously described by Wasielewski et al. [8]. In brief, we drew a line from the anterior superior iliac spine through the center of the acetabulum and then a second line perpendicular to this first line that intersected the first at the center of the acetabulum, as previously described [8]. Because we were primarily interested in the intrapelvic region of screw penetration, we translated these well-described quadrants to the intrapelvic anatomy. In order to do this, we first drilled a small hole through the quadrilateral surface at the center of the acetabulum (at the center as determined previously) to mark the intrapelvic center of the acetabulum. We determined the corresponding intrapelvic quadrants by drawing a line from the anterior superior iliac spine to the center of the acetabulum and a line perpendicular to this first line. We then reamed the acetabulum as would be performed in a standard THA. After the appropriate size and medialization was achieved, an uncemented hemispherical acetabular component (Trident II; Stryker Orthopedics,

Mahwah, NJ) was impacted into position using line-to-line press-fit technique.

### Experimental trials

We then drilled for and inserted screws into each quadrant in a sequential manner. A total of 3 screws with independent trajectories were placed in each quadrant. These screws were inserted sequentially (1 per fluoroscopic trial) to facilitate easier radiographic analysis. A depth gauge was used to measure ideal screw length, and 3 screw length iterations were conducted with each drilled screw path. For the first, the screw was placed such that the tip of the screw was flush with the intrapelvic bony surface; the second was placed with 5 mm of penetration; and the third was placed with 10 mm of penetration. Penetration was measured directly along the screw trajectory, using a ruler to confirm each screw had penetrated the exact desired amount.

For each screw trial, 8 radiographic images were obtained. These included the following: anteroposterior (AP), inlet, outlet, obturator oblique, iliac oblique, “down the wing,” “quad view,” and obturator outlet, as previously described [26]. The “down the wing” (DTW), “quad,” and obturator outlet views are combination images frequently used in percutaneous pelvis and acetabular fixation procedures. In brief, the quad view provides an image looking directly parallel to the quadrilateral surface and is useful for detecting medial wall penetration. This typically is a combination of some inlet and some obturator oblique. The obturator outlet is a standard obturator oblique but with the fluoroscopy tube tilted into an outlet orientation. The “down the wing” view allows the surgeon to visualize the medial and lateral cortices of the iliac wing and is obtained by rotating the fluoroscopy machine about the patient, toward the side of interest with the addition of some inlet [26]. The precise angles at which these views are obtained will vary slightly from patient to patient (Figure 1).



**Figure 1.** Example of the triple shot series of a screw placed in the anterior-superior quadrant with 10 mm of screw penetration. (a) Iliac oblique, (b) quad view, and (c) obturator outlet. The photos of the model pelvis taken at the trajectory of the fluoroscopy tube to obtain (d) iliac oblique, (e) quad view, and (f) obturator outlet.

After each screw was inserted and confirmed to have reached the desired depth of penetration, each of the aforementioned views was obtained using a fluoroscopic machine in a standardized fashion (C-arm fluoroscopic machine model: OEC Elite CFD; GE Healthcare, Chicago, IL). That is, each screw trajectory was imaged a total of 24 times (8 images at 3 different depths). Therefore, in total, 72 images were obtained of screws in each quadrant, and 288 images were obtained and analyzed in total. Each image was numbered, and a log was kept such that a key was available denoting the quadrant, view, and screw penetration depth of each image.

Thereafter, 3 independent and blinded orthopedic surgeons were asked to evaluate all 288 images as separate entities and binarily decide whether each image screw had definitively penetrated the intrapelvic bone. We additionally compiled a 3-view series of each screw (hence forth referred to as the “triple shot series”) and asked each surgeon to again binarily analyze the screw penetration using all 3 views in conjunction. This series consisted of the obturator outlet, iliac oblique, and quad views (Figure 1). These answers were tabulated categorically. Intraobserver and interobserver reliabilities were then calculated. In rare cases of surgeon disagreement, the surgeons undertook *post hoc* review of the discrepant image together and came to a consensus conclusion, per precedence [24]. Sensitivities, specificities, negative predictive value, and positive predictive values were then calculated. These were calculated for each radiographic view individually as well as for the 3-view combination. Subgroup analysis was performed for each quadrant. All analyses were conducted using Microsoft Excel (Microsoft Corporation, Redmond, WA).

## Results

### Individual radiographic views

In isolation, no single radiographic image was particularly sensitive. When considering all screws (in all 4 quadrants), the “quad” view had the best sensitivity at 0.62 at both 5 and 10 mm of screw penetration. The iliac oblique view was the least sensitive view (0.08 and 0.23 at 5 and 10 mm of screw penetration, respectively). Nearly all views were more sensitive for the detection of screw penetration at 10 mm than at 5 mm. The quad view was the least specific (0.85), while the AP, DTW, Iliac oblique, and inlet views all were 100% specific (Tables 1 and 2). Interobserver reliability was found to be high between reviewers (Kappa statistic  $\geq 0.814$ ,  $P < .001$ ).

### Triple shot series

When our standardized triple shot series was analyzed as a single metric, the sensitivity and specificity were significantly improved. When analyzed by quadrant, the triple shot series was found to be 100% sensitive in all but the posterior inferior (67%) and posterior superior (86%) quadrants. At 5-mm screw penetration, the series was 100% sensitive in the anterior quadrants, but only 33% sensitive in the posterior-inferior quadrant, and 75% sensitive in the posterior superior quadrant. At 10-mm screw penetration, the triple shot series was 100% sensitive and specific in all but the posterior superior quadrant, where it was only 67% specific (Table 3).

## Discussion

Intrapelvic acetabular screw penetration during THA is known to be potentially hazardous with serious and often immediate associated complications [10–18]. While mispositioned acetabular

**Table 1**

Diagnostic performance of each radiographic view by penetration depth.

Radiograph	Depth	Sensitivity	Specificity
AP	0	-	1.00
	5	0.31	-
	10	0.38	-
DTW	0	-	1.00
	5	0.31	-
	10	0.46	-
Iliac oblique	0	-	1.00
	5	0.08	-
	10	0.23	-
Inlet	0	-	1.00
	5	0.54	-
	10	0.62	-
Obturator oblique	0	-	0.92
	5	0.31	-
	10	0.46	-
Obturator outlet	0	-	0.92
	5	0.46	-
	10	0.54	-
Outlet	0	-	0.92
	5	0.38	-
	10	0.46	-
Quad	0	-	0.85
	5	0.62	-
	10	0.62	-

AP, anteroposterior; DTW, down the wing.

screws typically have acute or subacute implications, intrapelvic screw penetration may also be problematic remote from the index procedure [14]. Therefore, immediate identification of this error is paramount. With the rising popularity of intraoperative fluoroscopy, direct fluoroscopic confirmation of screw placement holds promise. However, the literature regarding the optimal radiographic view to detect intrapelvic screw penetration is sparse [25].

The results of this study indicate that the no single radiographic view is particularly sensitive for intrapelvic screw penetration. However, of the 8 studied radiographic views, the most sensitive view was the “quad” view. While this view achieved 62% sensitivity for the detection of 5 and 10 mm of screw penetration, it had the lowest specificity of studied views at 85%. We anecdotally found that the quad view was best, as may be anticipated, at detection of medial wall penetration. However, this view struggled to detect supra-pectineal screw penetration and sometimes projected penetration on screws that were intraosseous, but with a trajectory toward the ischial spine or greater sciatic notch. Therefore, a 3-view series to address these weaknesses (obturator outlet, iliac oblique, and quad views) was chosen and evaluated. This triple shot series, in our model, was found to be 100% sensitive for 10 mm of intrapelvic screw penetration in all 4 acetabular quadrants. This combination was also found to be 100% specific in all but the posterior superior quadrant, where it was 66% specific. Therefore, we propose our 3-view series as a clinically applicable intraoperative

**Table 2**

Diagnostic performance—all screw depths combined.

Radiograph	Sensitivity	Specificity	PPV	NPV
AP	0.35	1.00	1.00	0.43
DTW	0.38	1.00	1.00	0.45
Iliac Oblique	0.15	1.00	1.00	0.37
Inlet	0.58	1.00	1.00	0.54
Obturator Oblique	0.38	1.00	1.00	0.45
Obturator Outlet	0.50	0.92	0.93	0.48
Outlet	0.42	0.92	0.92	0.44
Quad	0.62	0.85	0.89	0.52

AP, anteroposterior; DTW, down the wing; PPV, positive predictive value; NPV, negative predictive value.

**Table 3**  
Diagnostic performance of 3-view radiographic series.

Radiograph	Sensitivity	Specificity	PPV	NPV
Anterior inferior all	1.00	1.00	1.00	1.00
Anterior superior all	1.00	1.00	1.00	1.00
Posterior inferior all	0.67	1.00	1.00	0.60
Posterior superior all	0.86	0.67	0.86	0.67
Anterior inferior 5	1.00	1.00	1.00	1.00
Anterior superior 5	1.00	1.00	1.00	1.00
Posterior inferior 5	0.33	1.00	1.00	0.60
Posterior superior 5	0.75	0.67	0.75	0.67
Anterior inferior 10	1.00	1.00	1.00	1.00
Anterior superior 10	1.00	1.00	1.00	1.00
Posterior inferior 10	1.00	1.00	1.00	1.00
Posterior superior 10	1.00	0.67	0.75	1.00

PPV, positive predictive value; NPV, negative predictive value.

assessment tool to detect clinically meaningful intrapelvic screw penetration.

While many of the combination views assessed in this study are well known in the orthopedic trauma operating room where they are frequently used for the placement of percutaneous screws, [26] the utility of these radiographic views has not been assessed in arthroplasty [25]. Prior literature has focused on the characterization of screw position before undertaking revision arthroplasty [25,27]. These studies either focused on computer tomography scans [27] or assessed only traditional pelvic radiographic views (AP, inlet, outlet, judets) [25]. In addition, in one study assessing plain film radiography, metallic acetabular components were not used, limiting its contemporary generalizability [25]. Finally, given the popularity of the anterior approach, [22] and the associated increasing popularity of intraoperative fluoroscopy, fluoroscopic evaluation (as opposed to plain film radiography) is increasingly clinically relevant.

Given the potential implications of mispositioned acetabular screws, we propose that our triple shot series be used intraoperatively to confirm acetabular screw position. This series allows for rapid detection of screw penetration into the true and false pelvises, using the quad and obturator outlet views, respectively. The addition of the iliac oblique view allows for the detection of screw penetration in the greater sciatic notch and also helps differentiate between true medial wall penetration and screws that are simply directed toward the ischial spine. This series consequently was 100% sensitive for screw penetration in all 4 intrapelvic quadrants at 10 mm of screw penetration. Of note, in both anterior quadrants, we also found a 100% sensitivity for the detection of even 5 mm of screw penetration.

The acetabular quadrant system is well described, and each quadrant contains distinct at-risk anatomical structures [8]. Wasielewski et al. have previously established that the posterior quadrants are relatively safe when compared to the anterior quadrants where the external iliac and obturator neurovascular bundle are at risk in the superior and inferior quadrants, respectively [8,17,28,29]. Injury to these vessels, particularly the external iliac, are known to occur [7,9,11,17,20,21,30–36]. Other authors have characterized the distance to danger from the acetabular surface, and in the anterior acetabulum, this distance is nearly universally <20 mm [28]. Similarly, in the posterior quadrants, the neurovascular at-risk structures are known to be over 10 mm from the bony surface, which is in contrast to the anterior quadrants where the at-risk structures can be in direct contact with the bone [29]. This is important as it indicates that our 3-view series provides adequate detection of clinically relevant screw penetration ( $\leq 5$  mm in the anterior quadrants and  $\leq 10$  mm in the posterior quadrants). It should be noted that standard views, particularly an AP pelvis, do not provide the same benefit.

While this study provides novel information and is of clinical utility, there are some limitations which must be considered. First, we chose to use a radiopaque Sawbones model. While the use of Sawbones in orthopedic research is well established, [37,38] the degree to which our results are reproducible in vivo where pelvic morphology may vary cannot be definitively determined. In addition, we used a hemispherical acetabular component and did not test other acetabular component designs, nor more complex reconstruction options. Similarly, the component position in our study was consistent (45 degrees abduction and 15 degrees anteversion), and it is possible that variably positioned acetabular components may have implications regarding the sensitivity of some radiographic views. However, this effect is anticipated to be minimal. Finally, while we imaged our pelvis model on an operating room table, this clearly represents ideal imaging conditions given the lack of soft tissue overlying the bony pelvis. The implications of this are, again, unknown. However, given the quality of images obtained by contemporary fluoroscopy machines, this, too, is anticipated to have little effect on our results.

## Conclusions

In conclusion, standard radiographic views of the pelvis (AP, inlet, outlet, judet views) have low sensitivity for the detection of intrapelvic screw penetration—even at 1 cm of screw penetration. We found that the most sensitive view for screw penetration was the quad view, although this achieved a sensitivity of only 62% in isolation. The most important finding of this study is that a 3-view series of radiographic images—obturator outlet, quad view, and an iliac oblique—is 100% sensitive for the detection of intrapelvic screw penetration at 5 mm in the anterior quadrants and at 10 mm in the posterior quadrants. Therefore, we propose that these images be obtained when placing transacetabular screws to confirm screw position and rule out intrapelvic screw penetration intraoperatively. The anticipated negligible additional operative time added with our reliable and repeatable protocol alleviates the uncertainty and unactionable nature of postoperative radiography. Therefore, this can help minimize screw misposition and potentially prevent devastating complications.

## Conflicts of interest

One author receives royalties from Onkos, Inc; One author is a paid consultant for Onkos, Inc. and Bone Support.

For full disclosure statements refer to <https://doi.org/10.1016/j.artd.2021.02.011>.

## Acknowledgments

The authors would like to acknowledge Stryker Corporation for supplying the implants and models used in this study. No other financial assistance was received.

## References

- [1] Learmonth ID, Young C, Rorabeck C. The operation of the century: total hip replacement. *Lancet* 2007;370(9597):1508.
- [2] Wagner ER, Wilson JM, Higgins I, Daly C, Gottschalk MB. The incidence of shoulder arthroplasty: rise and future projections compared to hip and knee arthroplasty. *J Shoulder Elbow Surg* 2020.
- [3] Kurtz S, Ong K, Lau E, Mowat F, Halpern M. Projections of primary and revision hip and knee arthroplasty in the United States from 2005 to 2030. *J Bone Joint Surg Am* 2007;89(4):780.
- [4] Sloan M, Premkumar A, Sheth NP. Projected volume of primary total joint arthroplasty in the U.S., 2014 to 2030. *J Bone Joint Surg Am* 2018;100(17):1455.
- [5] Grosso MJ, Neuwirth AL, Boddapati V, Shah RP, Cooper HJ, Geller JA. Decreasing length of hospital stay and postoperative complications after



- primary total hip arthroplasty: a decade analysis from 2006 to 2016. *J Arthroplasty* 2019;34(3):422.
- [6] Preston JS, Mennona S, Kayiaros S. Phlegmasia cerulea dolens and external iliac vein disruption after revision total hip arthroplasty. *Arthroplast Today* 2018;4(4):401.
- [7] Tavares RLP, Arcenio Neto E, Taki W. Total hip revision arthroplasty of high-risk pelvic vascular injury associated with an endovascular approach: a case report. *Rev Bras Ortop* 2018;53(5):626.
- [8] Wasielewski RC, Cooperstein LA, Kruger MP, Rubash HE. Acetabular anatomy and the transacetabular fixation of screws in total hip arthroplasty. *J Bone Joint Surg Am* 1990;72(4):501.
- [9] Keating EM, Ritter MA, Faris PM. Structures at risk from medially placed acetabular screws. *J Bone Joint Surg Am* 1990;72(4):509.
- [10] An S, Shen H, Feng M, Li Z, Wang Y, Cao G. Femoral artery injury during total hip arthroplasty. *Arthroplast Today* 2018;4(4):459.
- [11] Mallory TH, Jaffe SL, Eberle RW. False aneurysm of the common femoral artery after total hip arthroplasty. A case report. *Clin Orthop Relat Res* 1997;338:105.
- [12] Bechet FR, Himmer O, Mairy Y, Lootvoet L. [Arterial false aneurysm after total hip arthroplasty. A case report]. *Rev Chir Orthop Reparatrice Appar Mot* 2004;90(4):365.
- [13] Ha YC, Ahn IO, Jeong ST, Park HB, Koo KH. Iliacus hematoma and femoral nerve palsy after revision hip arthroplasty: a case report. *Clin Orthop Relat Res* 2001;385:100.
- [14] Wilson JM, Escobar GA, Badrinathan B, Reimer NB. External iliac pseudoaneurysm secondary to medial wall penetration of an acetabular screw: a rare cause of total hip arthroplasty failure 15 years after implantation. *Arthroplast Today* 2019;5(3):264.
- [15] Kinmont JC. Penetrating bladder injury caused by a medially placed acetabular screw. *J South Orthop Assoc* 1999;8(2):98.
- [16] Yoon SJ, Park MS, Matsuda DK, Choi YH. Endoscopic resection of acetabular screw tip to decompress sciatic nerve following total hip arthroplasty. *BMC Musculoskelet Disord* 2018;19(1):184.
- [17] Fricker RM, Troeger H, Pfeiffer KM. Obturator nerve palsy due to fixation of an acetabular reinforcement ring with transacetabular screws. A case report. *J Bone Joint Surg Am* 1997;79(3):444.
- [18] Hwang SK. Vascular injury during total hip arthroplasty: the anatomy of the acetabulum. *Int Orthop* 1994;18(1):29.
- [19] Avisar E, Elvey MH, Bar-Ziv Y, Tamir E, Agar G. Severe vascular complications and intervention following elective total hip and knee replacement: a 16-year retrospective analysis. *J orthopaedics* 2015;12(3):151.
- [20] Nachbur B, Meyer RP, Verkkala K, Zurcher R. The mechanisms of severe arterial injury in surgery of the hip joint. *Clin Orthop Relat Res* 1979;141:122.
- [21] Parvizi J, Pulido L, Slenker N, Macgibeny M, Purtill JJ, Rothman RH. Vascular injuries after total joint arthroplasty. *J Arthroplasty* 2008;23(8):1115.
- [22] Patel NN, Shah JA, Erens GA. Current trends in clinical practice for the direct anterior approach total hip arthroplasty. *J Arthroplasty* 2019;34(9):1987.
- [23] Lin TJ, Bendich I, Ha AS, Keeney BJ, Moschetti WE, Tomek IM. A comparison of radiographic outcomes after total hip arthroplasty between the posterior approach and direct anterior approach with intraoperative fluoroscopy. *J Arthroplasty* 2017;32(2):616.
- [24] Wilson JM, Schwartz AM, Farley KX, Anastasio AT, Bradbury TL, Guild 3rd GN. Postoperative acetabular component position in revision hip arthroplasty: a comparison of the anterior and posterior approaches. *Hip Int* 2020. 1120700020942451.
- [25] Galat DD, Petrucci JA, Wasielewski RC. Radiographic evaluation of screw position in revision total hip arthroplasty. *Clin Orthop Relat Res* 2004;419:124.
- [26] Bates PSA, Reinert C. The percutaneous treatment of pelvic and acetabular fractures Bates. Dallas, TX: Starr and Reinert; 2010.
- [27] Fehring TK, Guilford WB, Baron J. Assessment of intrapelvic cement and screws in revision total hip arthroplasty. *J Arthroplasty* 1992;7(4):509.
- [28] Ohashi H, Kikuchi S, Aota S, Hakozaaki M, Konno S. Surgical anatomy of the pelvic vasculature, with particular reference to acetabular screw fixation in cementless total hip arthroplasty in Asian population. *J Orthop Surg (Hong Kong)* 2017;25(1). 2309499016685520.
- [29] Feugier P, Fessy MH, Bejui J, Bouchet A. Acetabular anatomy and the relationship with pelvic vascular structures. Implications in hip surgery. *Surg Radiol Anat* 1997;19(2):85.
- [30] van Bockel JH, Koopmann MD, van Langelaan EJ. False aneurysm in the groin and femoral nerve palsy following total hip replacement. *Vasa* 1980;9(3):214.
- [31] Todd BD, Bintcliffe IW. Injury to the external iliac artery during hip arthroplasty for old central dislocation. *J Arthroplasty* 1990;5:S53.
- [32] Tkaczuk H. False aneurysm of the external iliac artery following hip endoprosthesis. *Acta Orthop Scand* 1976;47(3):317.
- [33] Smith GH, Nutton RW, Fraser SC. Iliac artery pseudoaneurysm rupture following excision of an infected hip prosthesis. *J Arthroplasty* 2011;26(6):977.
- [34] Proschek D, Proschek P, Hochmuth K, Balzer JO, Mack MG, Vogl TJ. False aneurysm of the left femoral artery and thrombosis of the left femoral vein after total hip arthroplasty. *Arch Orthop Trauma Surg* 2006;126(7):493.
- [35] Parvizi J. Vascular injury and orthopaedics. *Arthroplast Today* 2018;4(4):399.
- [36] Hopkins NF, Vanhegan JA, Jamieson CW. Iliac aneurysm after total hip arthroplasty. Surgical management. *J Bone Joint Surg Br* 1983;65(3):359.
- [37] Sternheim A, Kashigar A, Daly M, et al. Cone-beam computed tomography-guided navigation in complex osteotomies improves accuracy at all competence levels: a study assessing accuracy and reproducibility of joint-sparing bone cuts. *J Bone Joint Surg Am* 2018;100(10):e67.
- [38] Sternheim A, Daly M, Qiu J, et al. Navigated pelvic osteotomy and tumor resection: a study assessing the accuracy and reproducibility of resection planes in Sawbones and cadavers. *J Bone Joint Surg Am* 2015;97(1):40.