

Exudative retinal detachment as an initial presentation of retinopathy of prematurity: Clinical profile and outcomes of a rare presentation

Komal Agarwal¹, Sushma Jayanna^{1,2}, Tapas Ranjan Padhi³, Subhadra Jalali¹

Purpose: To describe the clinical profile and treatment outcomes of infants with retinopathy of prematurity (ROP) presenting with isolated exudative retinal detachment (ERD). **Methods:** Retrospective interventional case series. Preterm infants diagnosed with ROP with ERD at presentation were included. All demographic details, clinical findings, and treatment given were documented. The anatomical outcome was categorized as good, fair, and poor. Refractive outcome was classified into mild, moderate, and severe according to spherical equivalent at the last visit. **Results:** Fifteen eyes (8 patients) were included. Mean gestational age was 31.3 weeks, and birth weight was 1462.6 g. All eyes presented with aggressive ROP. Patches of retinal edema in avascular retina were seen in all eyes. A total of 86.6% of eyes had vascular sclerosis while 86.6% of eyes had subretinal exudates. The anatomical outcome was good in all eyes. In addition, 40% of eyes had a mild refractive error. **Conclusion:** Exudative retinal detachment in ROP is rare. The use of unregulated oxygen can be a contributory factor. Vascular sclerosis is consistent with hyperoxia-induced retinopathy models. Retinal edema and subretinal exudates indicate disrupted inner and outer blood-retinal barrier. Treatment outcomes are good when diagnosed and treated in time.

Key words: Exudative retinal detachment, pediatric retina, retinopathy of prematurity

Exudative retinal detachment (ERD) in retinopathy of prematurity (ROP) can sometimes occur after extensive laser photocoagulation and is attributed mainly to inflammation.^[1,2] A combined tractional and exudative RD is seen in cases with chronic traction or acute bleb-like configuration of tractional detachment.^[3,4] An isolated ERD without traction as an initial presentation in ROP is extremely rare. An earlier case report had compared this presentation with animal models of oxygen-induced retinopathy (OIR).^[5] There are also isolated case reports, including one from our group.^[5-8] Isolated primary ERD in ROP differs from the typical presentation of staged ROP and/or aggressive ROP (AROP). The pathogenic mechanisms of such presentation are largely unknown, and due to the rarity of the presentation, clinical features and outcomes have also not been described. We describe the clinical profile, treatment, and the anatomical and refractive outcomes of a series of patients with subretinal exudation and ERD without any tractional features, as the initial presentation in ROP.

Methods

We reviewed the medical records of preterm infants (<36 weeks) with ROP examined at a tertiary eye care institute in south India between January 2018 and December 2020. Infants diagnosed as staged ROP or AROP with ERD at presentation were included in the series. Infants diagnosed with other etiologies causing ERD were excluded. The study was approved by the

Institutional Ethics Committee (LEC-08088) and followed the Declaration of Helsinki.

Demographic details included: gestational age (GA), birth weight (BW), and postmenstrual age (PMA). Systemic risk factors associated with ROP, including details of oxygen therapy, were collected in the database. All infants were screened and treated following the Indian National Guidelines for ROP screening by a trained pediatric retina specialist.^[9] Details of the anterior segment and fundus findings, treatment given, and follow-up details were analyzed. The treatment included the use of intravitreal bevacizumab (0.625 mg/0.02 mL), laser photocoagulation, and/or vitreoretinal surgery. The choice and selection of treatment were left to the discretion of the treating pediatric retina/ROP specialist.

The anatomical outcome was defined by the retinal status at the last follow-up. It was categorized into: a) Good: attached retina without any folds or dragging of the retina, b) Fair: attached retina with folds or drag involving the macula, and c) Poor: partial or total detached retina.

Objective refraction (under cycloplegic) at the last follow-up was assessed. Spherical equivalent was calculated according to the following formula:

Spherical Equivalent (SE) = Spherical value + Cylindrical Value/2.

¹Smt Kanuri Santhamma Center for Vitreo-Retinal Diseases, L V Prasad Eye Institute, Hyderabad, Telangana, India, ²Department of Ophthalmology, Jigme Dorji Wangchuk National Referral Hospital, Thimpu, Bhutan, ³Retina and Vitreous Service, Mithu Tulsi Chanrai Campus, L V Prasad Eye Institute, Bhubaneswar, Odisha, India

Correspondence to: Dr. Sushma Jayanna, Department of Ophthalmology, Jigme Dorji Wangchuk National Referral Hospital, Thimpu, Bhutan. E-mail: sushmarj89@gmail.com

Received: 10-Feb-2022

Revision: 10-May-2022

Accepted: 31-May-2022

Published: 30-Jun-2022

Access this article online

Website:

www.ijo.in

DOI:

10.4103/ijo.IJO_407_22

Quick Response Code:



This is an open access journal, and articles are distributed under the terms of the Creative Commons Attribution-NonCommercial-ShareAlike 4.0 License, which allows others to remix, tweak, and build upon the work non-commercially, as long as appropriate credit is given and the new creations are licensed under the identical terms.

For reprints contact: WKHLRPMedknow_reprints@wolterskluwer.com

Cite this article as: Agarwal K, Jayanna S, Padhi TR, Jalali S. Exudative retinal detachment as an initial presentation of retinopathy of prematurity: Clinical profile and outcomes of a rare presentation. Indian J Ophthalmol 2022;70:2486-9.

The refractive outcome was categorized as follows: a) Mild error: equal or less than ± 3 D, b) Moderate error: greater than ± 3.00 D up to ± 6.00 D, and c) Severe error: greater than ± 6.00 D. Descriptive statistics was used to analyze the demographic data.

Results

A total of 2573 babies with ROP were evaluated and managed during the study period.

Fifteen eyes of eight patients were diagnosed as having isolated acute primary ERD. All infants were male. Mean GA was 31.3 weeks (28–34 weeks). Mean PMA at presentation was 34.9 weeks (32–38 weeks). Mean birth weight was 1462.6 g (1200–1800 g). All infants had a history of respiratory distress syndrome (RDS) and oxygen use during the neonatal intensive

care unit (NICU) stay. Three patients (5 eyes) had required ventilator, two patients (4 eyes) had required continuous positive airway pressure (CPAP), one patient (2 eyes) had required oxygen with nasal prongs in the perinatal period. The details of the percentage of oxygen used or pulse oximetry record and the cause of RDS like bronchopulmonary dysplasia (BPD), however, were not available in the records. None of the patients had a history of nephropathy or electrolyte imbalance.

Clinical features

The disease was bilateral in seven out of eight babies, but the severity was asymmetrical. All eyes presented with features consistent with AROP. This was limited to zone I in five eyes and posterior zone II in the remaining 10 eyes. Plus disease was present in all eyes. At presentation, two eyes showed persistent tunica vasculosa.

Fundus examination in all eyes revealed yellowish-white patches of retinal edema, characteristically located between the vessels (black arrow, Fig. 1a). Thirteen of 15 eyes (86.6%) showed patches of vascular sclerosis in one or more quadrants (white arrow, Fig. 1a, b). The peripheral retina beyond the termination of vessels was avascular in all eyes. Retinal break (s) was not identified in any eye. Subretinal exudates were noted in 13 eyes (86.6%) along with ERD (white arrowhead, Fig. 1b). However, no eye showed telangiectasia consistent with Coat's disease.

Treatment, outcome, and complications

Seven babies (13 eyes) were treated with intravitreal bevacizumab (IVB) injection (0.625 mg/0.02 mL). Twelve eyes were further treated with laser photocoagulation. These included eight eyes where the laser was planned as a part of combined treatment, two eyes received laser due to recurrence of plus disease, and two eyes received laser to the only persistent peripheral avascular retina on follow-up. One baby (1 eye) did not require laser, and the disease regressed after IVB alone; one baby (2 eyes) required only laser photocoagulation (small, multiple sittings), not IVB.

One baby (case 1, Table 1) was initially diagnosed with exudative ROP and possibly the early stage of neonatal endogenous endophthalmitis (case dilemma). One eye of this baby underwent vitreous biopsy with intravitreal antibiotic injections in addition to ROP-related treatment and the other eye received only IVB. This was the first case of our series and was reported earlier.⁶ No vitreoretinal surgical intervention was required in any other patients.

Mean follow-up was 257.7 days (40–833 days). The anatomical outcome was classified as "good" in all eyes at the final follow-up. None of the eyes showed residual retinal folds or retinal detachment at the last follow-up. Refractive outcome was available for nine eyes in our records. Refractive error was classified as "mild," "moderate," and "high" in six, two, and one eye, respectively. The mean refractive error was -2.3 D. One eye developed localized cataract after IVB; one eye developed post-IVB vitreous hemorrhage, and one eye developed hyphema, which resolved subsequently. Table 1 summarizes the clinical features and treatment of the 15 eyes.

Discussion

Exudative retinal detachments as a primary acute-phase ROP presentation were relatively rare (0.003%) in our large ROP database. The exudative components included distinct patches of retinal edema, subretinal exudation, and ERD that resolved substantially and rapidly with anti-vascular endothelial growth factor (anti-VEGF) injections. Additional laser as combined

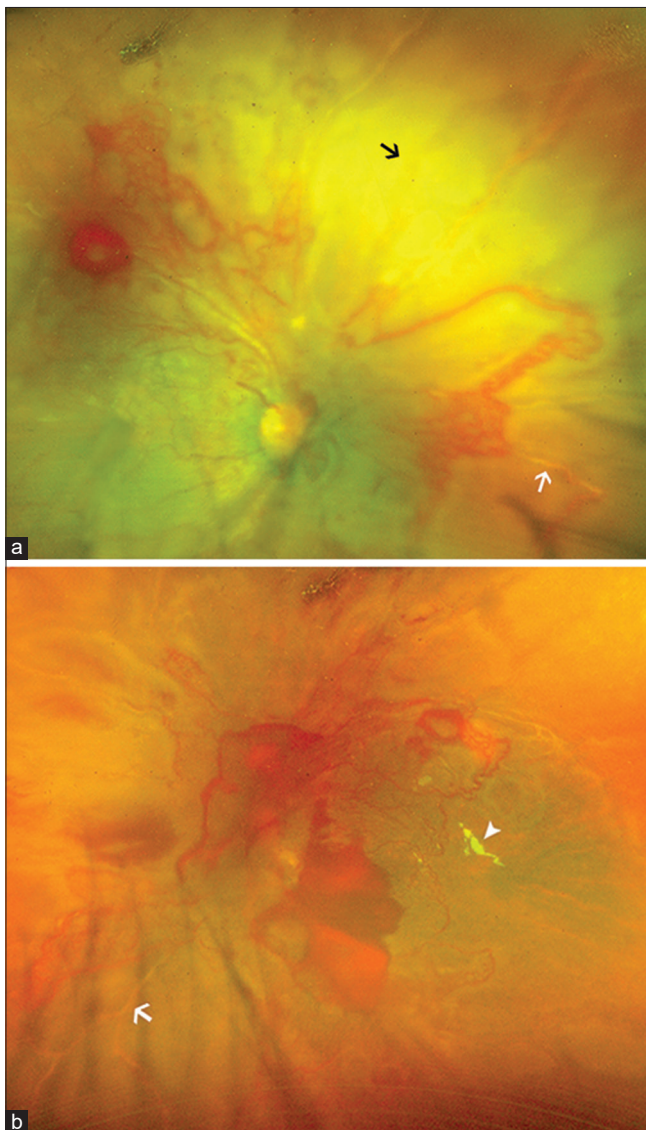


Figure 1: Wide-field fundus photograph of an infant born at a gestational age of 32 weeks. The baby had exudative retinal detachment in both eyes at presentation. Both eyes showed patches of retinal edema (black arrow, Figure 1a) and patches of vascular sclerosis (white arrow, Figure 1a, b). Subretinal exudates were present in the left eye (white arrowhead, Figure 1b)

Table 1: Demographic details, fundus findings, treatment, and outcomes of eyes with exudative retinal detachment

Gender	GA (weeks)/ BW (g)	PMA at presentation (weeks)	Laterality	Fundus findings	Treatment	Anatomical outcome	Systemic risk factors
M	28/1500	32	Bilateral	BE: APROP, Yellowish white patches, retinal edema, subretinal exudates, ERD, vascular sclerosis	Combined (RE vitreous biopsy - negative)	Good	RDS, necrotizing enterocolitis
M	33/1400	38	Bilateral	BE: APROP, Yellowish white patches, retinal edema, subretinal exudates, vascular sclerosis with frank ERD in LE	Combined	Good	RDS, CPAP
M	29/1200	32	Bilateral	BE: APROP, Yellowish white patches, retinal edema, subretinal exudates, ERD with vascular sclerosis in LE	Intravitreal bevacizumab followed by laser on recurrence of plus	Good	RDS, Ventilator
M	30/1400	34	Unilateral	RE: APROP, Yellowish white patches, retinal edema, subretinal exudates, vascular sclerosis	Intravitreal bevacizumab	Good	RDS, CPAP, Ventilator, MRSA sepsis
M	30/1700	34	Bilateral	BE: APROP, Yellowish white patches, retinal edema, subretinal exudates, vascular sclerosis with frank ERD in LE	Intravitreal bevacizumab followed by laser to persistent avascular retina only	Good	RDS, nasal prong oxygen support
M	34/1200	36	Bilateral	BE: APROP, Yellowish white patches, retinal edema, subretinal exudates, ERD, vascular sclerosis with NVI	Combined	Good	RDS, Ventilator
M	34/1800	37	Bilateral	BE: APROP, Yellowish white patches, retinal edema, vascular sclerosis with Subretinal exudates, and ERD in LE	Laser	Good	RDS
M	32/1470	36	Bilateral	BE: APROP, Yellowish white patches, retinal edema, subretinal exudates, ERD, vascular sclerosis	Combined	Good	RDS, Hyperbilirubinemia

APROP, aggressive posterior ROP; CPAP, continuous positive airway pressure; ERD, exudative retinal detachment; GA, gestational age; MRSA, methicillin-resistant *Staphylococcus aureus*; PMA, postmenstrual age; RDS, respiratory distress syndrome; ROP, retinopathy of prematurity RE: Right eye, LE: Left eye, BE: Both eye, NVI: Neovascularization of Iris

therapy or recurrence consolidated the gains and seemed to provide a complete cure with good anatomical and functional outcomes. The refractive outcome was comparable with earlier ROP treatment studies.

We have earlier published bleb-like posterior combined exudative and tractional RD.^[4] The clinical presentation and outcomes were markedly different from the currently described primary ERD. Our cases presented with isolated exudative retinal detachment with ROP, whereas those with bleb-like configuration have a posterior tractional element along the subretinal exudation and detachment. The bleb-like posterior combined exudative and tractional RD did not do as well

despite multiple interventions, including injections/laser and vitreoretinal surgeries while our cases had a good anatomical outcome. It seems the pathogenesis in those eyes is different than the series presented here. However, the exact pathogenesis of either condition is unknown.

Exudative retinal detachment results from an accumulation of excessive fluid in the subretinal space. Disruption of the blood-retinal barriers has been widely implicated in the pathogenesis of ERD through several mechanisms.^[10] Inner blood-retinal barrier is formed by the tight junctions between endothelial cells of the vascular plexuses in the retina. ROP presents with improper vasculogenesis and/or angiogenesis.

Severely disorganized retinal vessels in AROP with intertwining areas of avascularity can lead to abnormal exudation—both subretinal and perivascular.^[11] Also, in the event of extensive choroidal ischemia, fibrinoid necrosis of choroidal arterioles can disrupt the outer retinal barrier causing exudative detachment.^[12] Prominent unusual yellowish-white edematous patches of the avascular retina were a consistent feature in all eyes of our cohort, which may point toward choroidal ischemia with overlying retinal ischemia. However, Fundus fluorescein angiography (FFA) or Indocyanine green (ICG) could not be done in any of our cases due to a lack of availability.

Earlier reports have hypothesized hyperoxia-induced ischemia and release of fibrinogen to be the probable cause.^[5] Hyperoxia can induce intense initial vasoconstriction and vaso-obliteration, leading to poor scaffold for retinal angiogenesis.^[10] Thirteen eyes in our study showed patches of vascular sclerosis. All cases had a history of oxygen requirements during the NICU stay. However, since the exact mode, concentration, and duration of the oxygen delivery are not known, the role of oxygen in ERD in ROP cannot be conclusive in the present study.

We observed that all cases in our cohort, presented with signs suggestive of AROP, despite a relatively higher GA. It is rather not unusual to see aggressive posterior ROP (APROP) in relatively large infants in middle-income countries like India.^[13,14]

Familial exudative vitreoretinopathy (FEVR) presents with intra and subretinal exudation with peripheral avascular retina. ERD can be seen in late cases of FEVR. It is differentiated from ROP based on the history of prematurity present in the latter. Family history of similar illness is present in about 34% of cases of FEVR.^[15] Genetic analysis and systematic family screening can give clues to differentiate between the two.^[16] None of our patients had a history of full-term delivery or similar family history. Genetic analysis could not be done. The vascular changes in the babies in this cohort did not clinically resemble the pruned appearance described in ROP vs. FEVR (ROPER), although FFA could not be done.

The study is limited due to its retrospective nature and small sample size. However, this was unavoidable due to the rarity of the presentation. Dye angiography and optical coherence tomography could have given us additional information. Fundus examination of the babies at risk of ROP at birth, periodic evaluation thereafter, and serial documentation of systemic events, including oxygen usage, could give one a better insight into the pathogenesis of these unique observations. There are no defined guidelines to treat ERD in ROP. Hence, the treatment decisions were made by the treating retina specialist; they were inclined more to use anti-VEGF injections as a primary modality of treatment in most eyes.

Conclusion

In conclusion, exudative retinal detachment as an initial finding is rare in ROP. Extensive areas of the avascular retina with retinal edema, subretinal exudates are a consistent feature in these cases. Vascular sclerosis is common. These cases show dramatic improvement with intravitreal anti-VEGF, and laser can be used for the sustained response. Anatomical and refractive outcomes are good and comparable with staged ROP/AROP.

Sources of support

Hyderabad Eye Research Foundation, Hyderabad, India. The funders had no role in the preparation, review, or approval of the manuscript.

Financial support and sponsorship

Nil.

Conflicts of interest

There are no conflicts of interest.

References

- Ehmann D, Greve M. Intravitreal bevacizumab for exudative retinal detachment post laser therapy for retinopathy of prematurity. *Can J Ophthalmol* 2014;49:228-31.
- Moshfeghi DM, Silva RA, Berrocal AM. Exudative retinal detachment following photocoagulation in older premature infants for retinopathy of prematurity: Description and management. *Retina* 2014;34:83-6.
- Hovland P, Mukai S HT. Advanced retinopathy of prematurity. In: Albert & Jakobiec's Principles and Practice of Ophthalmology. Philadelphia: Elsevier; 2008. p. 1829-35.
- Patel A, Padhy SK, Saoji K, Saldna M, Multani PK, Khalsa A, *et al.* Bleb-like posterior combined retinal detachment in severe retinopathy of prematurity: Clinical characteristics, management challenges and outcome [published online ahead of print, 2020 Oct 17]. *Eye (Lond)* 2021;35:3152-5.
- Sen P, Yusufali H, Khetan V, Rao C, Banerjee A. Exudative retinal detachment, a primary presentation in retinopathy of prematurity. *Can J Ophthalmol* 2018;53:e74-7
- Jayanna S, Agarwal K, Padhi TR, Jalali S. Exudative retinal detachment as an initial presentation in retinopathy of prematurity. *J AAPOS* 2020;24:374-6.
- Mittal K, Chawla R, Vukkadala T, Azad SV, Vohra R, Daga J. A rare case of aggressive posterior retinopathy of prematurity presenting with exudative retinal detachment [published online ahead of print, 2020 Nov 2]. *J AAPOS* 2020;S1091-8531(20)30226-3.
- Mohideen SK, Jaffar J, Halder U, Shetty AP. Exudative retinal detachment in treatment naïve aggressive posterior retinopathy of prematurity: A case report. *Indian J Ophthalmol Case Rep* 2021;1:343-5.
- Rashtriya Bal Swasthya Karyakram, Ministry of Health and Family Welfare, Government of India. Guidelines for universal eye screening in newborns including Retinopathy of prematurity, June 2017. Available from: https://nhm.gov.in/images/pdf/programmes/RBSK/Resource_Documents/Revised_ROP_Guidelines-Web_Optimized.pdf. [Last accessed on 2020 May].
- Amer R, Nalci H, Yalçındağ N. Exudative retinal detachment. *Surv Ophthalmol* 2017;62:723-69.
- Hartnett ME. Pathophysiology and mechanisms of severe retinopathy of prematurity. *Ophthalmology* 2015;122:200-10.
- de Venecia G, Jampol LM. The eye in accelerated hypertension II. Localized serous detachments of the retina in patients. *Arch Ophthalmol* 1984;102:68-73.
- Sanghi G, Dogra M, Katoch D, Gupta A. Aggressive posterior retinopathy of prematurity in infants ≥ 1500 g birth weight. *Indian J Ophthalmol* 2014;62:254-7.
- Shah PK, Narendran V, Kalpana N. Aggressive posterior retinopathy of prematurity in large preterm babies in South India. *Arch Dis Child Fetal Neonatal Ed* 2012;97:F371-5.
- Shukla D, Singh J, Sudheer G, Soman M, John RK, Ramasamy K, *et al.* Familial exudative vitreoretinopathy (FEVR). Clinical profile and management. *Indian J Ophthalmol* 2003;51:323-8.
- John VJ, McClintic JI, Hess DJ, Berrocal AM. Retinopathy of prematurity versus familial exudative vitreoretinopathy: Report on clinical and angiographic findings. *Ophthalmic Surg Lasers Imaging Retina* 2016;47:14-9.