



Laparoscopic Hartmann's Reversal: Application of a Single-Port Approach Through the Colostomy Site

Byung Mo Kang¹, Chang Woo Kim², Suk-Hwan Lee²

¹Department of Surgery, Chuncheon Sacred Heart Hospital, Hallym University College of Medicine, Chuncheon; ²Department of Surgery, Kyung Hee University Hospital at Gangdong, Kyung Hee University School of Medicine, Seoul, Korea

Purpose: Recently, laparoscopic reversal of Hartmann's colostomy was performed with favorable outcomes by many surgeons. We partially applied the concepts of single-port laparoscopic procedure through the colostomy site to remove intraperitoneal adhesion during initial step of the laparoscopic Hartmann's reversal. This study aimed to evaluate the feasibility and safety of the laparoscopic reversal of Hartmann's colostomy with the application of single-port laparoscopic techniques through the colostomy site.

Methods: From October 2008 to November 2018, the laparoscopic Hartmann's reversal was attempted in 20 patients. After colostomy take-downs, the single-port device was installed at the colostomy site and the single-port laparoscopic procedure was performed to remove intraperitoneal adhesions to provide space for additional trocars. After additional trocars were inserted, the descending colon and rectal stump were mobilized, and the colorectal anastomosis was completed. We retrospectively reviewed the medical records and analyzed the data to identify the perioperative complication rates as the primary outcome.

Results: Of the 20 patients, 3 patients (15.0%) had open conversions due to severe adhesions. Intraoperative small bowel injuries occurred in 2 patients (10.0%) and these were repaired through the colostomy site. Postoperative complications developed in 4 patients (20.0%) and were managed with medical treatments or wound closures under local anesthesia.

Conclusion: The single-port laparoscopic procedure through the colostomy site is sufficiently safe in order to complete the Hartmann's reversal. We recommend that the colostomy site should be used as the access route into the abdominal cavity for the Hartmann's reversal.

Keywords: *Hartmann's reversal; Laparoscopic surgery; Postoperative outcome, Single-port laparoscopy*

INTRODUCTION

In the early days of laparoscopic surgery, a history of previous abdominal surgery was considered a contraindication. Intraperitoneal dense adhesions were obstacles to laparoscopic surgery in which tactile feedback was limited and proper traction and coun-

ter-traction was difficult. Moreover, Hartmann's colostomy procedures were usually performed in emergent situations in which intraperitoneal contamination was extensive and the patient's general health condition was poor. Therefore, intraperitoneal adhesions became firmer and more extensive after Hartmann's procedures, and reversals were considered to be more suitable for open surgery than using a laparoscopic approach.

As the successes of laparoscopic surgeries increased, the classic indications have gradually expanded. Several studies demonstrated promising results for laparoscopic reversals of Hartmann's procedures [1-8]. In most of these studies, fascial defect in the colostomy site was closed immediately after end colostomy take-down, or only one trocar was inserted at the colostomy site. Recently, single-port laparoscopic surgery (SPLS) was introduced as an innovative procedure to reduce the incision at the abdominal wall and to improve cosmetic results [9-11]. In SPLSs, multiple laparoscopic instruments entered through a single entry in the

Received: Apr 20, 2020 • Revised: Jul 22, 2020 • Accepted: Sep 21, 2020

Correspondence to: Suk-Hwan Lee, M.D.

Department of Surgery, Kyung Hee University Hospital at Gangdong, Kyung Hee University School of Medicine, 892 Dongnam-ro, Gangdong-gu, Seoul 05278, Korea

Tel: +82-2-440-6134, Fax: +82-2-440-6073

E-mail: leeshdr@khu.ac.kr

ORCID: <https://orcid.org/0000-0001-6470-8620>

© 2021 The Korean Society of Coloproctology

This is an open-access article distributed under the terms of the Creative Commons Attribution Non-Commercial License (<https://creativecommons.org/licenses/by-nc/4.0>) which permits unrestricted non-commercial use, distribution, and reproduction in any medium, provided the original work is properly cited.

abdominal wall.

We designed a new surgical approach that incorporated the concept of SPLS into the conventional laparoscopic reversal of Hartmann's colostomy procedure. We used the existing colostomy site as the single entry for SPLSs. Through this single entry, single-port laparoscopic procedures were performed for intraperitoneal exploration and removal of intraperitoneal adhesions creating sufficient space to allow insertion of additional trocars. This new approach was expected to reduce surgical trauma to the abdominal wall and to reduce the technical difficulties of conventional laparoscopic reversals of Hartmann's colostomy procedures. This study aimed to evaluate the feasibility and safety of laparoscopic reversals of Hartmann's colostomies with the aid of a single-port laparoscopic technique through a colostomy site.

METHODS

This retrospective, observational study was performed using patients who have had Hartmann's colostomies. From August 2008 to November 2018, 20 patients underwent laparoscopic reversals of Hartmann's colostomy procedures at 2 university hospitals in South Korea. The initial Hartmann's colostomy procedures were performed for perforated or obstructive sigmoid colon pathologies or severe inflammatory pelvic diseases. Three experienced laparoscopic surgeons performed the laparoscopic reversals of Hartmann's colostomies. Patient selection was based on each participant's suitability for a laparoscopic reversal of Hartmann's colostomy and general anesthesia concerns. Laparoscopic reversals of Hartmann's procedure were performed in patients who had sufficient lengths of rectal stumps and descending colons for anastomoses using staplers. Open surgery was performed in patients with severe cardiopulmonary disease, severe organ dysfunction, or who refused laparoscopic surgery.

Procedures

Mechanical bowel preparations with whole bowel irrigations were performed 2 days prior to the surgery. Second-generation cephalosporins were administered just prior to the surgery. Under general anesthesia, the patient was placed in a lithotomy position. The surgeon stood on the left side of the patient. An elliptical peristomal incision was made and the Hartmann's colostomy was completely freed from the abdominal wall.

Single-port laparoscopic phase

A single-port device was installed through the abdominal wall opening at the colostomy site. Single-port devices with multiple channels (OCTO Port, DalimsurgNET Inc., Seoul, Korea; Surgi-Tractor, SurgiCore Co., Gwangju, Korea; or home-made glove port) were selected at the surgeon's discretion. The home-made glove port was assembled by combining a wound retractor (ALEXIS wound retractor XS, Applied Medical, Rancho Santa Margarita, CA, USA) and a surgical glove in which one 10-mm trocar and

two 5-mm trocars were inserted through the 1st, 3rd and 5th fingertips. The anvil of a circular stapler was inserted at the end of the colostomy and the colon was returned to the abdominal cavity. After establishing a pneumoperitoneum with the intraperitoneal pressure of up to 12 mmHg, surgeons inspected the intraperitoneal condition especially with regard to the degree and location of adhesions. Using single-port laparoscopic techniques, intraperitoneal adhesions in the abdominal wall, especially in the midline incision site, were dissected to open a space to allow for the safe insertion of additional trocars.

Multiport laparoscopic phase

The surgeon moved to the right side of the patient. A 10-mm trocar was inserted in the supraumbilical area and 1 or 2 of 5-mm trocars were inserted into the right upper and/or lower quadrants. The descending colon was mobilized, and the splenic flexure was fully mobilized to perform tension-free anastomoses whenever needed. After a sufficient length of the colon was mobilized, the rectal stump was identified. When Hartmann's procedure was initially performed, we usually tagged a couple of 3-0 prolene sutures at the rectal stump to make it easier to identify the correct orientation and location of the rectal stump for revisional surgery. After the area around the rectal stump was dissected, a circular stapler was inserted through the anus and intraperitoneal anastomosis was completed. An air-leak test was performed to detect any anastomotic defects, and laparoscopic repairs were performed if any were found. A drainage tube was inserted under the anastomotic site at the surgeon's discretion. The wound at the colostomy site was left to heal by using purse-string closures for secondary healing or delayed primary closures (Fig. 1). Foley catheters were removed at postoperative day 1.

Outcome measurement

With the approval of the Institutional Review Board at each hospital, data were collected by reviewing medical records (No. KH-NMC 2018-11-022, CHUNCHEON 2018-11-002-002). Primary outcomes of this study were the rates of intraoperative and 30-day postoperative complications. Data included sex, age, body mass index, American Society of Anesthesiologists physical status classification, indication and types of Hartmann's procedures, conversions, operation times, estimated blood loss, adhesion grades, intraoperative and 30-day postoperative complications, time to functional recoveries, and postoperative lengths of hospital stays. Intraoperative findings of intraperitoneal adhesions were stratified according to the Mazuji classification of adhesion grades [12]: adhesion grade 0 indicated no adhesions; grade 1 indicated scattered filmy adhesions; grade 2 indicated moderately dense, scattered adhesions with no difficulties in lysis; grade 3 indicated dense, continuous adhesions with no difficulties in lysis; and grade 4 indicated very dense homogenous adhesions with difficulties in lysis. The postoperative complications were graded according to the Clavien-Dindo classification [13]. Wound infection

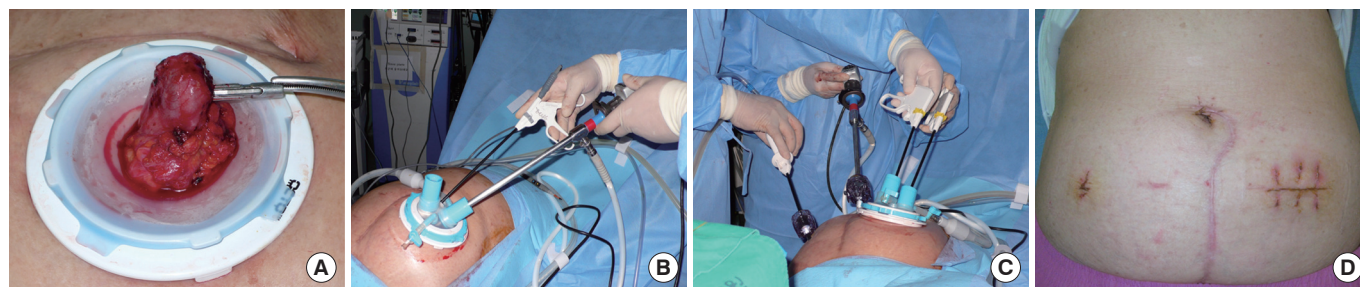


Fig. 1. (A) Insertion of the anvil of the circular stapler through the colostomy site. (B) Single-port laparoscopic phase. (C) Multiport laparoscopic phase. (D) Surgical wound at postoperative day 14.

was defined as a wound in which purulent discharge or pus was drained. A prolonged ileus was defined as failure of flatus passage combined with small intestine distension until postoperative day 3 and a resultant delay of oral intake. Anastomotic leakage was defined as drainage of feces or pus from the surgical drains or radiological findings of abscess formation around the anastomosis. An intraperitoneal abscess was defined as abscess formation outside the anastomotic site. Statistical analyses were performed using IBM SPSS software for Windows, ver. 22.0 (IBM Corp., Armonk, NY, USA).

RESULTS

Twenty patients (8 male and 12 female) underwent laparoscopic reversals of Hartmann's colostomies during the 10-year study period. The mean age was 61.0 years (range, 40 to 88 years). Three patients had a previous history of abdominal surgery other than Hartmann's colostomies. Most of the initial Hartmann's procedures were performed using open surgery (16, 80.0%), but 4 patients (20.0%) received laparoscopic surgeries. The reasons for performing Hartmann's colostomies were sigmoid colon diverticulitis perforations (8, 40.0%), sigmoid colon cancer perforations (6, 30.0%), sigmoid colon cancer obstructions (4, 20.0%), and others (2, 10.0%). The median time interval between Hartmann's colostomies and Hartmann's colostomy reversals was 243 days (range, 111 to 3,790 days) (Table 1).

Three patients (15.0%) required the conversion to open surgery due to severe intraperitoneal adhesions (Mazuji grade 4). All of the decisions regarding conversions were determined during the multiport laparoscopic phase. The mean operation time was 224.2 minutes (range, 85 to 436 minutes) and the median estimated blood loss was 10 mL (range, 2 to 800 mL). According to the Mazuji classification for adhesion grades, intraperitoneal adhesions were grade 2 in 5 patients (25.0%), grade 3 in 9 patients (45.0%), and grade 4 in 6 patients (30.0%). Two patients with grade 4 adhesions had small bowel injuries during dissections of adhesions around the pelvic cavity and their damaged small bowels were withdrawn through their colostomy sites and repaired using open techniques. Intraperitoneal drains were inserted around the anas-

Table 1. Baseline characteristics of the study population

Variable	Data (n = 20)
Sex, male:female	8 (40.0):12 (60.0)
Age (yr)	61.0 ^a (40–88)
Body mass index (kg/m ²)	25.8 ^a (20.1–38.9)
ASA PS classification	
I/II	17 (85.0)
III/IV	3 (15.0)
History of previous abdominal surgery other than HP, yes	3 (15.0)
Indications for HP	
Sigmoid colon diverticulitis perforation	8 (40.0)
Sigmoid colon cancer perforation	6 (30.0)
Sigmoid colon cancer obstruction	4 (20.0)
Others	2 (10.0)
Type of HP	
Open surgery	16 (80.0)
Laparoscopic surgery	4 (20.0)
Time interval from HP to reversal (day)	243 ^b (111–3,790)

Values are presented as number (%) of patients, mean^a (range), or median^b (range). ASA, American Society of Anesthesiologists; PS, physical status; HP, Hartmann's procedure.

tomosis sites in 18 patients (90.0%) (Table 2).

Four patients (20.0%) had postoperative complications. According to the Clavien-Dindo classification, 2 patients (10.0%) had grade II complications (1 with an intraperitoneal abscess and 1 with a prolonged ileus), and 2 patients (10.0%) had grade IIIa complications (wound infections at the colostomy site that required frequent wound dressings and wound closures under local anesthesia). There were no anastomotic leaks or mortalities. The mean time to first passage of flatus was 3.3 days (range, 2 to 5 days) and to initiation of a soft diet was 5.0 days (range, 3 to 8 days). The mean duration of postoperative hospital stays was 8.2 days (range, 3 to 16 days) (Table 3).

Table 2. Operative outcomes

Variable	Data (n = 20)
Conversion into open surgery, yes	3 (15.0)
Operation time (min)	224.2 ^a (85–436)
Estimated blood loss (mL)	10 ^b (2–800)
Mazuij adhesion grade	
0/1	0 (0)
2	5 (25.0)
3	9 (45.0)
4	6 (30.0)
Single-port device in the colostomy site	
OCTO Port	8 (40.0)
SurgiTractor	7 (35.0)
Home-made glove port	3 (15.0)
Others	2 (10.0)
Splenic flexure mobilization	2 (10.0)
Surgical drainage insertion	18 (90.0)
Intraoperative complication	2 (10.0)

Values are presented as number (%) of patients, mean^a (range), or median^b (range). OCTO Port, DalimSurgNET Inc., Seoul, Korea; SurgiTractor, SurgiCore Co., Gwangju, Korea.

DISCUSSION

The reversal procedure of Hartmann's colostomy is undertaken to reestablish intestinal continuity in the patients with Hartmann's colostomies. Hartmann's reversal procedures have been considered major surgeries with relatively high morbidities of >40% [14–16]. With increased proficiencies in laparoscopic surgeries, Hartmann's reversal procedures also began to be performed using laparoscopic techniques. Gorey et al. [17] reported the first case of laparoscopic reversal of Hartmann's colostomy in 1993. Since that time, several authors have reported on the safety and feasibility of laparoscopic reversals of Hartmann's colostomies with rapid functional recoveries [2–4, 18–22].

In previous comparative studies, laparoscopic reversals of Hartmann's colostomies showed equivalent or somewhat superior outcomes compared to open revisions and were considered to be an alternative to reconstructing the colonic continuity [5–7, 23]. Mazeh et al. [5] reported less blood loss, faster bowel function recoveries, shorter lengths of hospital stays, and lower major complication rates in their laparoscopic group with similar mean operative times in the open and laparoscopic groups. Haughn et al. [6] showed that 6-month complication and reoperation rates were lower in their laparoscopic group with the causes for readmission mostly due to surgical problems in the open group and medical problems in the laparoscopic group; although their 6-month readmission rates were similar. Faure et al. [7] demonstrated less morbidity, faster postoperative recoveries, and significantly shorter

Table 3. Postoperative outcomes

Variable	Data (n = 20)
Postoperative complication	
Overall	4 (20.0)
Grade II ^a	2 (10.0)
Grade IIIa ^b	2 (10.0)
Time to passage of first flatus (day)	3.3 (2–5)
Time to water intake (day)	3.5 (2–7)
Time to resuming soft diet (day)	5.0 (3–8)
Postoperative length of hospital stay (day)	8.2 (3–16)
Readmission	1 (5.0)
Mortality	0 (0)

Values are presented as number (%) of patients or mean (range).

^aIntraperitoneal abscess, 1; prolonged ileus, 1. ^bWound infections.

operation times for their laparoscopic group (143 minutes vs. 180 minutes; $P = 0.048$).

Over the past 10 years, single-port laparoscopic surgeries were introduced for the treatment of acute appendicitis [9], cholecystitis [10], and even colorectal disease [11] to maximize the benefits of minimally invasive surgeries. SPLSs were conducted using multiple laparoscopic instruments through a single entry in the umbilicus or stoma site. Some surgeons reported successful single-port laparoscopic reversals of Hartmann's colostomies [24, 25]. However, totally single-port laparoscopic Hartmann's reversals had inherent issues such as a narrow viewing angle and a limited range of motion for laparoscopic instruments because manipulation of the left colon was performed through the single entry located in the left side of the abdomen. We also attempted a totally single-port approach but felt that using this difficult technique was somewhat dangerous to patients and required too much time to complete Hartmann's reversal procedures.

In this study, we applied the concept of SPLS in the initial phase of laparoscopic reversals of Hartmann's colostomies and attempted to evaluate the feasibility and safety of our newly designed operation. In the initial phase of the operation, the single-port laparoscopic technique through the colostomy site was used to remove omental adhesions and the small bowel from the abdominal wall by directly viewing the laparoscopic images. A better view of the operative field ensured safe insertions of additional trocars. Our results showed a relatively low rate of conversion to open surgery (15.0%) and intraoperative complications (10.0%). Postoperative complications occurred in 4 patients (20.0%), but there were no major complications > grade IIIb according to the Clavien-Dindo classification. The times to functional recoveries and postoperative lengths of hospital stays were also acceptable.

During early studies involving laparoscopic reversals of Hartmann's colostomies, surgeons dissected intraperitoneal adhesions and mobilized the colon through the colostomy site using open techniques [17, 20, 22]. As a result, peristomal incisions became

longer and poorer operative views were obtained. Furthermore, most of the laparoscopic procedures were performed after the closure of the opening of colostomy site to maintain a pneumoperitoneum [4, 17, 19, 21, 22]. The colostomy site could then no longer be used as an entry to access the abdominal cavity. In other studies, a single trocar was placed in the colostomy site allowing only 1 laparoscopic instrument to be introduced into the abdominal cavity [2, 3, 20]. After introduction of additional trocars and instruments, more complicated laparoscopic dissections were possible.

In the present study, single-port laparoscopic procedures through the colostomy site were performed at the initial step of the laparoscopic Hartmann's reversal procedure and these enabled thorough dissections of intraperitoneal adhesions, especially on the abdominal wall, to secure adhesion-free surfaces for additional trocar placements. Further, the opening in the colostomy site was continued to be used as another access route to the abdominal cavity, which helped in managing unexpected intraoperative adverse events. If needed, hand-assisted laparoscopic surgery could be performed through the colostomy site. The premade opening in the abdominal wall did not need to be closed until the operation was complete. This method should be used as a multipurpose access route for the abdominal cavity by single-port laparoscopic techniques.

With our new surgical approach, we used the premade opening at the colostomy site as the entry point for SPLSs. As a result, the number of additional trocars could be reduced and surgical trauma was minimized. Furthermore, the single-port laparoscopic procedure at the colostomy site could be used to identify and remove any intraperitoneal adhesions and additional trocars could be safely inserted without injuring adjacent organs. Finally, intraoperative small bowel injuries could be adequately repaired with open techniques through the opening at the colostomy site.

Our study has several limitations. First, this study had a retrospective, single-arm design, which might have potential selection bias. In the near future, prospective and comparative study is needed to build a better evidence. Secondly, only a small number of patients were included in the analysis. Thirdly, long-term outcomes, such as incisional hernias and anastomotic strictures, could not be evaluated.

In conclusion, laparoscopic Hartmann's reversal procedures were performed safely and efficiently by applying a single-port laparoscopic procedure through the colostomy site. It is our belief that the opening created after the colostomy takedown can be used as an additional access point to the abdominal cavity in the laparoscopic reversals of Hartmann's colostomies.

CONFLICT OF INTEREST

No potential conflict of interest relevant to this article was reported.

REFERENCES

1. Petersen M, Köckerling F, Lippert H, Scheidbach H. Laparoscopically assisted reversal of Hartmann procedure. *Surg Laparosc Endosc Percutan Tech* 2009;19:48-51.
2. Rosen MJ, Cobb WS, Kercher KW, Sing RF, Heniford BT. Laparoscopic restoration of intestinal continuity after Hartmann's procedure. *Am J Surg* 2005;189:670-4.
3. Khaikin M, Zmora O, Rosin D, Bar-Zakai B, Goldes Y, Shabtai M, et al. Laparoscopically assisted reversal of Hartmann's procedure. *Surg Endosc* 2006;20:1883-6.
4. Holland JC, Winter DC, Richardson D. Laparoscopically assisted reversal of Hartmann's procedure revisited. *Surg Laparosc Endosc Percutan Tech* 2002;12:291-4.
5. Mazeh H, Greenstein AJ, Swedish K, Nguyen SQ, Lipskar A, Weber KJ, et al. Laparoscopic and open reversal of Hartmann's procedure: a comparative retrospective analysis. *Surg Endosc* 2009; 23:496-502.
6. Haughn C, Ju B, Uchal M, Arnaud JP, Reed JF, Bergamaschi R. Complication rates after Hartmann's reversal: open vs. laparoscopic approach. *Dis Colon Rectum* 2008;51:1232-6.
7. Faure JP, Doucet C, Essique D, Badra Y, Carretier M, Richer JP, et al. Comparison of conventional and laparoscopic Hartmann's procedure reversal. *Surg Laparosc Endosc Percutan Tech* 2007;17: 495-9.
8. Onder A, Gorgun E, Costedio M, Kessler H, Stocchi L, Benlice C, et al. Comparison of short-term outcomes after laparoscopic versus open Hartmann reversal: a case-matched study. *Surg Laparosc Endosc Percutan Tech* 2016;26:e75-9.
9. Markar SR, Karthikesalingam A, Di Franco F, Harris AM. Systematic review and meta-analysis of single-incision versus conventional multiport appendectomy. *Br J Surg* 2013;100:1709-18.
10. Arezzo A, Scozzari G, Famiglietti F, Passera R, Morino M. Is single-incision laparoscopic cholecystectomy safe? Results of a systematic review and meta-analysis. *Surg Endosc* 2013;27:2293-304.
11. Maggiori L, Gaujoux S, Tribillon E, Bretagnol F, Panis Y. Single-incision laparoscopy for colorectal resection: a systematic review and meta-analysis of more than a thousand procedures. *Colorectal Dis* 2012;14:e643-54.
12. Mazuji MK, Kalambaheti K, Pawar B. Prevention of adhesions with polyvinylpyrrolidone. Preliminary report. *Arch Surg* 1964; 89:1011-5.
13. Clavien PA, Barkun J, de Oliveira ML, Vauthey JN, Dindo D, Schulick RD, et al. The Clavien-Dindo classification of surgical complications: five-year experience. *Ann Surg* 2009;250:187-96.
14. Vermeulen J, Coene PP, Van Hout NM, van der Harst E, Gosse-link MP, Mannaerts GH, et al. Restoration of bowel continuity after surgery for acute perforated diverticulitis: should Hartmann's procedure be considered a one-stage procedure? *Colorectal Dis* 2009;11:619-24.
15. Banerjee S, Leather AJ, Rennie JA, Samano N, Gonzalez JG, Pappagrigoriadis S. Feasibility and morbidity of reversal of Hart-

- mann's. *Colorectal Dis* 2005;7:454-9.
16. Antolovic D, Reissfelder C, Ozkan T, Galindo L, Büchler MW, Koch M, et al. Restoration of intestinal continuity after Hartmann's procedure: not a benign operation. Are there predictors for morbidity? *Langenbecks Arch Surg* 2011;396:989-96.
 17. Gorey TE, O'Connell PR, Waldron D, Cronin K, Kerin M, Fitzpatrick JM. Laparoscopically assisted reversal of Hartmann's procedure. *Br J Surg* 1993;80:109.
 18. Sosa JL, Sleeman D, Puente I, McKenney MG, Hartmann R. Laparoscopic-assisted colostomy closure after Hartmann's procedure. *Dis Colon Rectum* 1994;37:149-52.
 19. Costantino GN, Mukalian GG. Laparoscopic reversal of Hartmann procedure. *J Laparoendosc Surg* 1994;4:429-33.
 20. Macpherson SC, Hansell DT, Porteous C. Laparoscopic-assisted reversal of Hartmann's procedure: a simplified technique and audit of twelve cases. *J Laparoendosc Surg* 1996;6:305-10.
 21. Regadas FS, Siebra JA, Rodrigues LV, Nicodemo AM, Reis Neto JA. Laparoscopically assisted colorectal anastomose post-Hartmann's procedure. *Surg Laparosc Endosc* 1996;6:1-4.
 22. Anderson CA, Fowler DL, White S, Wintz N. Laparoscopic colostomy closure. *Surg Laparosc Endosc* 1993;3:69-72.
 23. van de Wall BJ, Draaisma WA, Schouten ES, Broeders IA, Consten EC. Conventional and laparoscopic reversal of the Hartmann procedure: a review of literature. *J Gastrointest Surg* 2010;14:743-52.
 24. Smith BM, Bettinger DA. Single-incision laparoscopic reversal of Hartmann procedure via the colostomy site only: first report. *Surg Innov* 2011;18:NP5-7.
 25. Borowski DW, Kanakala V, Agarwal AK, Tabaqchali MA, Garg DK, Gill TS. Single-port access laparoscopic reversal of Hartmann operation. *Dis Colon Rectum* 2011;54:1053-6.