

A comparative clinical evaluation of analgesic efficacy of Tapentadol and ketorolac in mandibular third molar surgery

ABSTRACT

Introduction: The surgical removal of impacted mandibular third molars is one of the most commonly performed dentoalveolar procedures in oral and maxillofacial surgery and is associated with varying degrees of postoperative discomfort. Pain, trismus, and swelling are the most common postoperative complaints, and these influence a patient's quality of life in the days after surgery.

Materials and Methods: A comparative study of the 32 patients, 16 were allocated to receive ketorolac and 16 patients were allocated to receive tapentadol. As the data for this study were collected at different time points, analysis for the longitudinal study was done. The main outcome variable, pain level was measured in five-ordered categories. As we had ordinal data in our study, we first checked for marginal homogeneity through Cochran–Mantel–Haenszel test.

Results: In the present study, the results show that there is no statistically significant difference between the two treatment groups ($P=0.1184$). According to results, there is no significant group by time interaction, which means both drugs have shown almost equal efficacy at different time points. Similarly, there is no difference in efficacy of the two drugs across gender level.

Conclusion: The present findings showed that there is no statistically significant difference between the two treatment groups, although ketorolac is more effective for immediate pain reduction than tapentadol. However, the overall reduction of pain using both groups has no significant difference.

Keywords: Impaction, nonsteroidal anti-inflammatory drugs, opioid analgesics, third molar

INTRODUCTION

Pain is the most common complaint of the human beings. Dental pain specifically third molar extraction is said to be one of the most acute postsurgical painful conditions.^[1] Extractions of the third molars account for a large volume of cases in contemporary oral surgical practice and require much planning and surgical skill during both preoperative diagnosis and postoperative management.^[2] The pain experienced following the third molar surgery under local anesthesia has been shown to be of short duration and reaches its maximum intensity in the early postoperative period and in the most cases, patients require some form of analgesic to deal with it.^[3]

Treating the patient before the development of significant pain is a more humane, enlightened approach to patient

care and is consistent with the current trends toward more aggressive, preventive, and systematic approaches to pain management. Moreover, it has become recognized that longer the pain remains uncontrolled, more sensitive patient may become to the painful stimuli.^[4] It is generally accepted that pain following the third molar surgery reaches

DIXIT SHAH, SANKET SHAH, AMIT MAHAJAN, NAVIN SHAH, DARSHAN SANGHVI, RISHABH SHAH


Department of Oral and Maxillofacial Surgery, K. M. Shah Dental College and Hospital, Vadodara, Gujarat, India

Address for correspondence: Dr. Amit Mahajan, A-29, 1st Floor, Shrenik Park Society, Opposite Akota Stadium, Productivity Road, Akota, Vadodara - 390 020, Gujarat, India. E-mail: dramitmds@gmail.com

This is an open access article distributed under the terms of the Creative Commons Attribution-NonCommercial-ShareAlike 3.0 License, which allows others to remix, tweak, and build upon the work non-commercially, as long as the author is credited and the new creations are licensed under the identical terms.

For reprints contact: reprints@medknow.com

How to cite this article: Shah D, Shah S, Mahajan A, Shah N, Sanghvi D, Shah R. A comparative clinical evaluation of analgesic efficacy of Tapentadol and ketorolac in mandibular third molar surgery. Natl J Maxillofac Surg 2017;8:12-8.

Access this article online	
Website: www.njms.in	Quick Response Code 
DOI: 10.4103/njms.NJMS_4_17	

moderate-to-severe intensity within the first 5 h after surgery. However, there are studies showing that the postoperative pain reaches its peak intensity during the first 8 h after the surgery.^[5]

Opiates are the standard of care for moderate-to-severe postoperative pain. Most opioids used in clinical practice produce analgesia by activating opioid receptors on neurons within the pain transmission pathway.

Tapentadol is a centrally acting analgesic with a dual mode of action (i.e., m-opioid receptor agonism and norepinephrine uptake inhibition), distinguishing it from other commercially available opioids.^[6] Opioid receptor binding has shown that tapentadol has higher binding affinity to m-opioid receptors than for delta(d)- and kappa(k)-opioid receptors.

Ketorolac having prolonged analgesic activity (Power *et al.*, 1990) has neither sedative nor anxiolytic properties (Brown *et al.*, 1990). Ketorolac does appear to have a significant analgesic efficacy and has been used successfully to replace opioid in some situation involving mild-to-moderate postsurgical pain.^[7]

This study focuses on the comparison of the efficacy of two different analgesics. The use of tapentadol has not reported very widely after extraction of the third molar, so we compared its pain relief efficiency.

MATERIALS AND METHODS

This study was done at the Department of Oral and Maxillofacial Surgery, where 32 patients who required surgical extraction of impacted mandibular third molars. All the patients who were included in the study were given information regarding the procedure. The patients were randomly divided into two groups. Patients were allocated to Group A and B in which an odd number of patients were included in Group A, and even number of patients were included in Group B. Group A patients were given ketorolac 10 mg BD, and Group B patients were given tapentadol 50 mg BD postoperatively.

Inclusion criteria

- Age group 18–60 years
- Patients who are willing to participate.

Exclusion criteria

- Medically compromised patients
- Patients who have had any type of analgesic in the past 48 h
- Patients who are not willing to participate
- Patients allergic to the drugs.

All the patients were operated under local anesthesia using infiltration or inferior alveolar nerve block of involved side. Incision was given, and the operation site was exposed by reflecting mucoperiosteal flap, guttering of buccal bone, and sectioning of the third molar was done if required as per the standard impacted third molar surgery. After the surgery, operating site was irrigated with betadine and saline. Then, the flap was primarily closed with 3-0 silk. Patients were asked to take medicine 1 h after the surgery in both groups. Pain intensity was recorded at 1 h, 4 h, 10 h, 1 day, 2 day, and 3 day after the procedure using the visual analog scale as said by the patients through telephonic conversation. The patients were recalled at the 7th day postoperatively for suture removal.

RESULTS

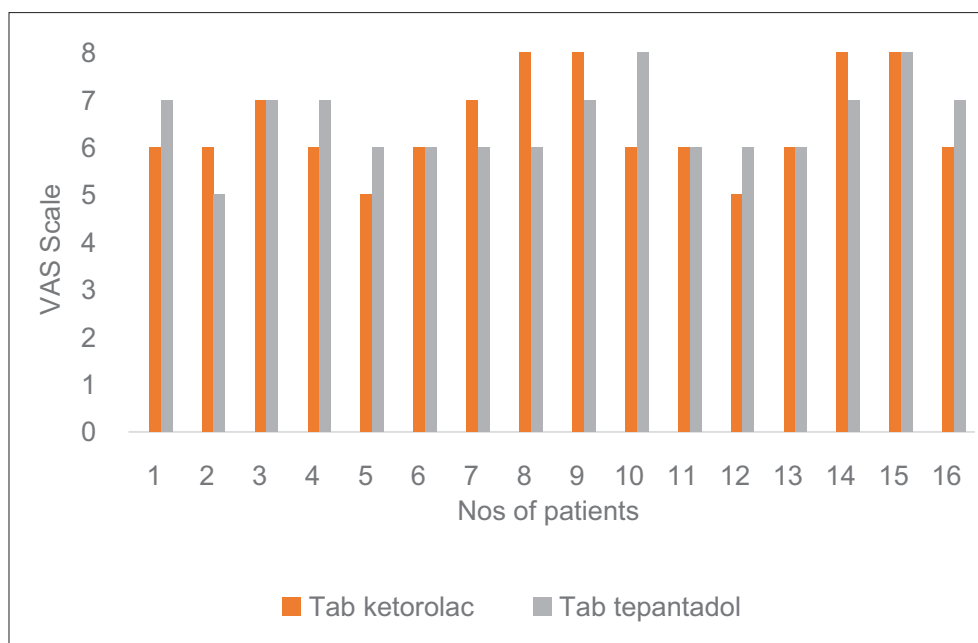
Of the 32 patients, 16 were allocated to receive ketorolac and 16 patients were allocated to receive tapentadol. As the data for this study were collected at different time points, analysis for the longitudinal study was done. The main outcome variable, pain level was measured in five-ordered categories. Figure 1 shows the results of 1 h after surgery, Figure 2 shows the results of 4 h after surgery, Figure 3 shows the results of 10 h after surgery, Figure 4 shows the results of the 1st postoperative day, Figure 5 shows the results of the 2nd postoperative day, and Figure 6 shows the results of the 3rd postoperative day.

DISCUSSION

Postoperative pain control is one of the most important aspects of management of surgical patients. Various drugs, which are used to control the postoperative pain, are mainly categorized into two groups, i.e., nonsteroidal anti-inflammatory drugs (NSAIDs) and opioids.^[8]

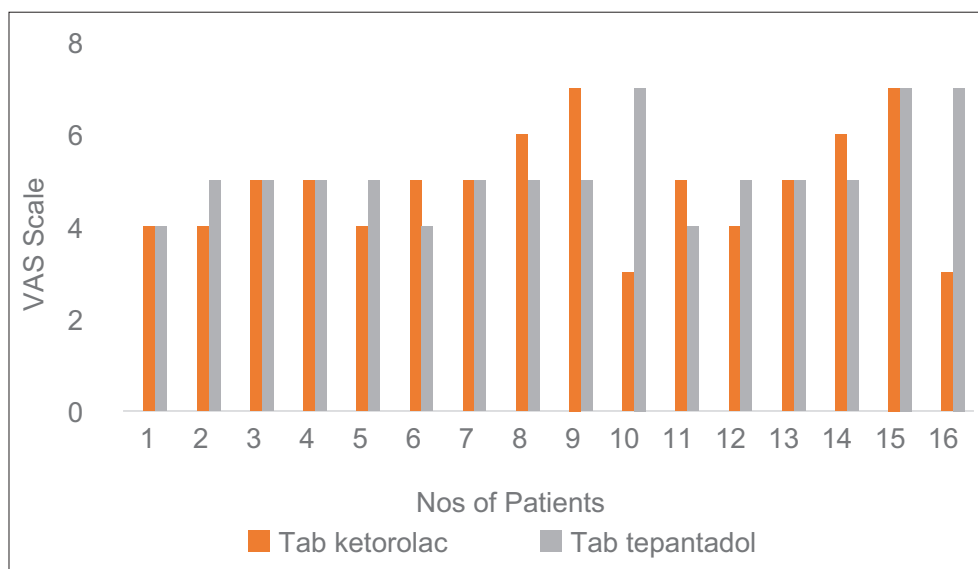
Surgical removal of impacted third molar is the most common outpatient procedure in oral surgery. Normally, it is followed by an inflammatory reaction characterized by pain, swelling, and trismus.^[9] The management of this postoperative pain has been extensively studied with several NSAIDs.^[10] Sometimes, the patients experience severe pain after the surgical removal of the impacted teeth. NSAIDs have become popular for pain relief after different major and minor surgical procedures.

NSAIDs reduce the biosynthesis of prostaglandins by inhibition of the enzyme cyclooxygenase (COX). Mechanism of action of NSAIDs prostaglandins, prostacyclin (PGI₂), and thromboxane A₂ (TXA₂) are produced from arachidonic acid by the enzymes cyclooxygenase which exists in a



Drugs	Comparison after 1 st h															
Tablet ketorolac	6	6	7	6	5	6	7	8	8	6	6	5	6	8	8	6
Tablet tapentadol	7	5	7	7	6	6	6	6	7	8	6	6	6	7	8	7

Figure 1: One hour after surgery

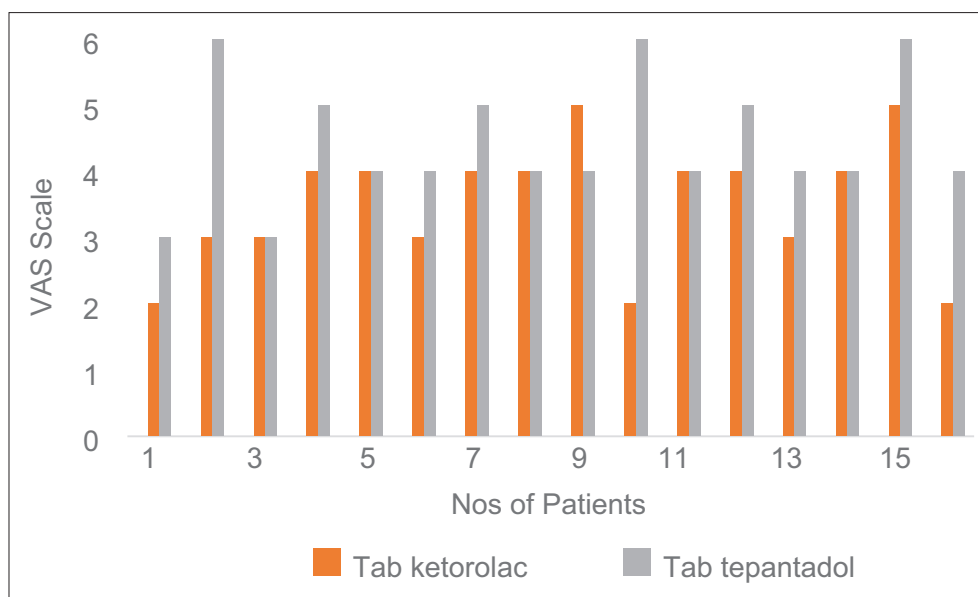


Drugs	Comparison after 4 h															
Tablet ketorolac	4	4	5	5	4	5	5	6	7	3	5	4	5	6	7	3
Tablet tapentadol	4	5	5	5	5	4	5	5	5	7	4	5	5	5	7	7

Figure 2: Four hours after surgery

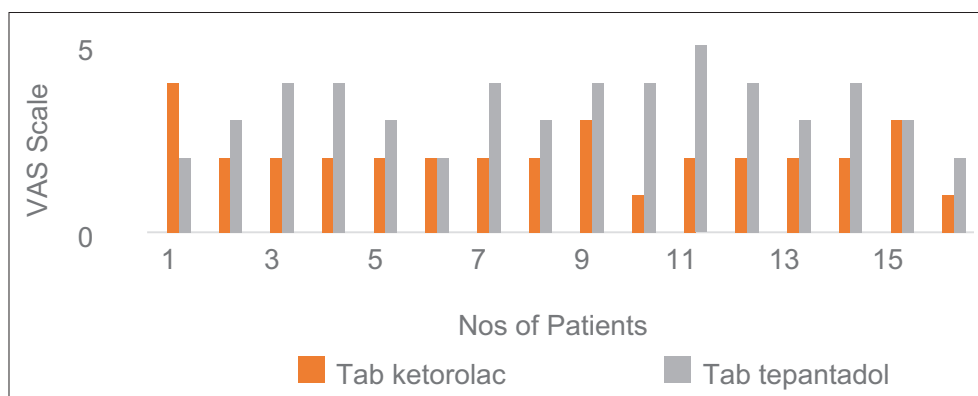
constitutive (COX-1) and an inducible (COX-2) isoforms. COX-1 – “housekeeping” functions and present in most of the cells of the body. COX-2 – normally not present but induced by certain serum factors, cytokines, and other signal molecules at the site of inflammation.^[11-15]

Opioid analgesics act as agonists at opioid receptors in the central nervous system, although some opioids have both agonist and antagonist effects. Compared to pure agonists, agonist-antagonist drugs have less potential for abuse in patients with a known history of abuse/addiction, and studies have shown



Drugs	Comparison after 10 h															
Tablet ketorolac	2	3	3	4	4	3	4	4	5	2	4	4	3	4	5	2
Tablet tapentadol	3	6	3	5	4	4	5	4	4	6	4	5	4	4	6	4

Figure 3: Ten hours after surgery



Drugs	Comparison after 1 st day															
Tablet ketorolac	4	2	2	2	2	2	2	2	3	1	2	2	2	2	3	1
Tablet tapentadol	2	3	4	4	3	2	4	3	4	4	5	4	3	4	3	2

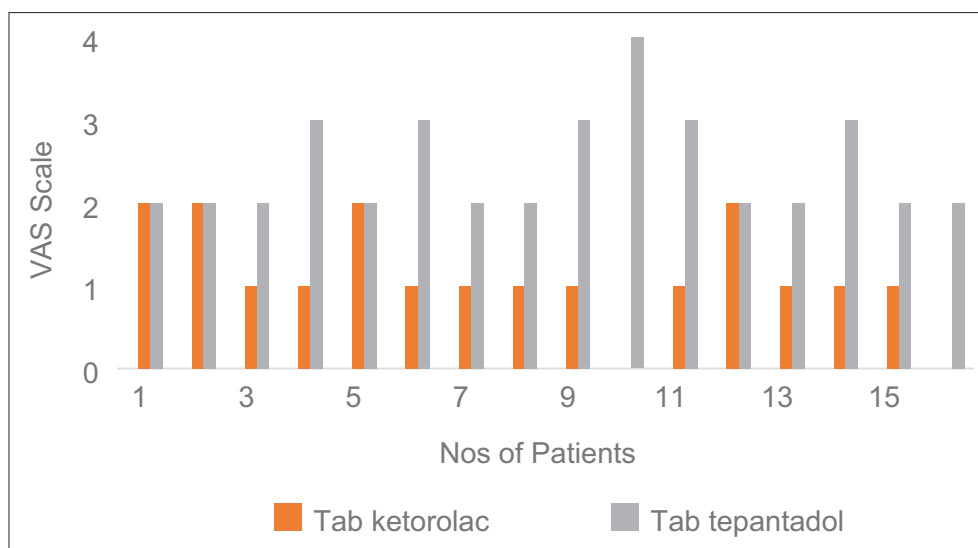
Figure 4: First postoperative day

that they may not induce a withdrawal syndrome in patients already physically dependent on opioids, although caution is advised in this setting. However, agonist-antagonist medications have a ceiling effect for analgesia. In general, acute pain is best treated with short-acting pure agonist drugs, whereas chronic pain is best treated with longer-acting pure agonist drugs. Adverse effects related to opioids include sedation, constipation, nausea, vomiting, and pruritus. Respiratory depression is also possible but rare when opioids are given in appropriate doses.^[16]

Ketorolac is a member of the pyrrolopyrrole group of nonsteroidal anti-inflammatory drugs. Ketorolac is also a

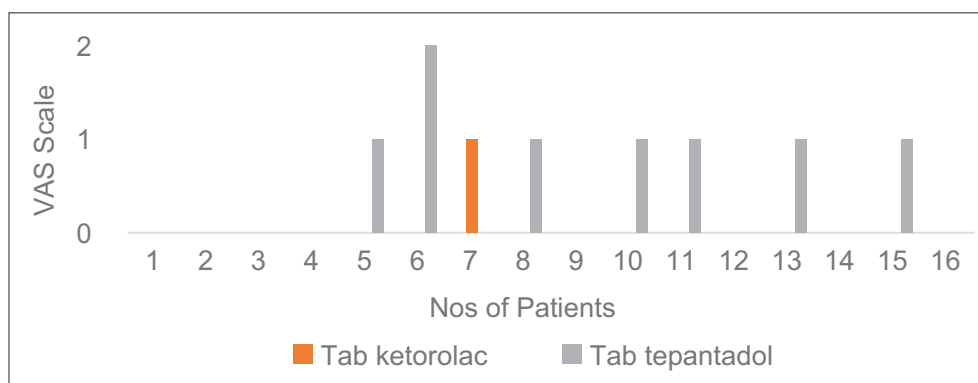
NSAID, which has been compared and found effective with pethidine 50–100 mg, morphine 6–12 mg, and pentazocine 30 mg.^[16] Ketorolac has been proved to be more potent than several other NSAIDs studied under similar experimental conditions.

In a study, the efficacy and safety of NSAIDs analgesic in the treatment of acute postoperative dental pain have revealed that ketorolac has a greater global efficacy. In another study of the third molar extraction, Fricke *et al.*^[17] found 30 mg of ketorolac was significantly better than 50 and 100 mg pethidine. Ketorolac exhibits analgesic activity mediated



Drugs	Comparison after 2 nd day															
Tablet ketorolac	2	2	1	1	2	1	1	1	1	0	1	2	1	1	1	0
Tablet tapentadol	2	2	2	3	2	3	2	2	3	4	3	2	2	3	2	2

Figure 5: Second postoperative day



Drugs	Comparison after 3 rd day															
Tablet ketorolac	0	0	0	0	0	0	1	0	0	0	0	0	0	0	0	0
Tablet tapentadol	0	0	0	0	1	2	0	1	0	1	1	0	1	0	1	0

Figure 6: Third postoperative day

by peripheral effects. At analgesic doses, it has minimal anti-inflammatory and antipyretic activities. It is also a potent platelet aggregation inhibitor. Ketorolac is not an anesthetic agent and possesses no sedative or anxiolytic properties. It is stated that ketorolac is a useful alternative to opioid and to other nonsteroidal analgesics in ameliorating moderate-to-severe postsurgical pain.^[17]

Tapentadol is a centrally active analgesic with a dual mode of action (i.e., m-opioid receptor agonism and norepinephrine uptake inhibition), distinguishing it from other commercially available opioids. Tapentadol is an immediate-release (IR) formulation for the relief of acute pain in adults, as an

extended-release formulation for the management of chronic pain in adults, and in the US, for neuropathic pain associated with diabetic peripheral neuropathy. Tapentadol is also approved as an oral solution for the relief of acute pain in adults.^[18,19] Clinical trials of patients with various types of moderate-to-severe acute pain have shown that tapentadol IR provides analgesia comparable to that of the pure m-opioid agonist, oxycodone IR, with improved gastrointestinal tolerability (lower incidence of nausea, vomiting, and constipation).^[16]

We evaluated tapentadol IR for effects on moderate-to-severe pain after minor oral surgery, which is an established pain

model for the assessments of analgesia, the results of which can be generalized to other surgical procedures. The model is ideal for evaluating analgesia for a number of reasons. The pain model employs standardized surgical and anesthetic procedures, with less interpatient variability in pain. Furthermore, patients undergoing surgery experience a predictable and sustained level of moderate-to-severe pain following the procedure that requires analgesic treatment for several days.

We evaluated both drugs comparison after 1 h which shows no significant difference with $P = 0.850$ and after 4 h also no significant difference with $P = 0.428$. Both drugs give a significant different after 10 h, 1st day, 2nd day, and 3rd day with $P < 0.005$. So, basically with a comparison of both drugs, there is no significant difference between these two drugs for pain control postoperatively, but for immediate pain relief, ketorolac is marginally superior in compare with tapentadol.

Of the 32 patients, 16 were allocated to receive ketorolac and 16 patients were allocated to receive tapentadol. As the data for this study were collected at different time points, analysis for the longitudinal study was done. The main outcome variable, pain level was measured in five-ordered categories. As we had ordinal data in our study, we first checked for marginal homogeneity through Cochran–Mantel–Haenszel test. The results show that there is no statistically significant difference between the two treatment groups ($P = 0.1184$). According to the results, there is no significant group by time interaction, which means both drugs have shown almost equal efficacy at different time points. Similarly, there is no difference in efficacy of the two drugs across gender level.

CONCLUSION

Hence, we conclude that there is no statistically significant difference between the two treatment groups, although ketorolac is more effective for immediate pain reduction than tapentadol. However, the overall reduction of pain using both groups has no significant difference. Hence, we can use both drugs for the management of mild-to-moderate pain.

Financial support and sponsorship

Nil.

Conflicts of interest

There are no conflicts of interest.

REFERENCES

1. Abbas SM, Kamal RS, Afshan G. Effect of ketorolac on postoperative pain relief in dental extraction cases – A comparative study with pethidine. *J Pak Med Assoc* 2004;54:319-22.
2. Srinivas M, Susarla AB, Dodsan TB. Risk factors for third molar extraction difficulty. *J Oral Maxillofac Surg* 2004;62:1363-71.
3. Comfort MB, Tse AS, Tsang AC, McGrath C. A study of the comparative efficacy of three common analgesics in the control of pain after third molar surgery under local anaesthesia. *Aust Dent J* 2002;47:327-30.
4. Seymour RA, Meechan JG, Blair GS. An investigation into post-operative pain after third molar surgery under local analgesia. *Br J Oral Maxillofac Surg* 1985;23:410-8.
5. Khorshidi Khiavi R, Pourallahverdi M, Pourallahverdi A, Ghorani Khiavi S, Ghertasi Oskouei S, Mokhtari H. Pain control following impacted third molar surgery with bupivacaine irrigation of tooth socket: A prospective study. *J Dent Res Dent Clin Dent Prospects* 2010;4:105-9.
6. Lee YK, Ko JS, Rhim HY, Lee EJ, Karcher K, Li H, *et al.* Acute postoperative pain relief with immediate-release tapentadol: Randomized, double-blind, placebo-controlled study conducted in South Korea. *Curr Med Res Opin* 2014;30:2561-70.
7. Uddin MD, Mosharraf Hossain AK, Alam MM, Shakhawat Hossain AZ. Ketorolac and pethidine in post-operative pain relief. *Bangladesh J Pharmacol* 2007;2:35-42.
8. Raritan NJ. Tapentadol [package insert]. Titusville, NJ, USA: Ortho-McNeil Janssen Pharmaceuticals, Inc.; 2008.
9. Cork RC, Isaac I, Elsharydah A, Saleemi S, Zavisca F, Alexander L. A comparison of the verbal rating scale and the visual analog scale for pain assessment. *Internet J Anesthesiol* 2004;8:50-2.
10. Swadia VN, Shah MB. Comparative evaluation of ketorolac, tramadol and diclofenac for postoperative pain relief in minor surgical procedures. *Indian J Anaesth* 1999;43:64-6.
11. Wade WE, Spruill WJ. Tapentadol hydrochloride: A centrally acting oral analgesic. *Clin Ther* 2009;31:2804-18.
12. Afilalo M, Etropolski MS, Kuperwasser B, Kelly K, Okamoto A, Van Hove I, *et al.* Efficacy and safety of tapentadol extended release compared with oxycodone controlled release for the management of moderate to severe chronic pain related to osteoarthritis of the knee: A randomized, double-blind, placebo- and active-controlled phase III study. *Clin Drug Investig* 2010;30:489-505.
13. Singh DR, Nag K, Shetti AN, Krishnaveni N. Tapentadol hydrochloride: A novel analgesic. *Saudi J Anaesth* 2013;7:322-6.
14. Kleinert R, Lange C, Steup A, Black P, Goldberg J, Desjardins P. Single dose analgesic efficacy of tapentadol in postsurgical dental pain: The results of a randomized, double-blind, placebo-controlled study. *Anesth Analg* 2008;107:2048-55.
15. Hawker GA, Mian S, Kendzerska T, French M. Measures of adult pain: Visual analog scale for pain (VAS pain), numeric rating scale for pain (NRS pain), McGill Pain Questionnaire (MPQ), short-form McGill Pain Questionnaire (SF-MPQ), chronic pain grade scale (CPGS), short form-36 bodily pain scale (SF-36 BPS), and measure of intermittent and constant osteoarthritis pain (ICOAP). *Arthritis Care Res (Hoboken)* 2011;63 Suppl 11:S240-52.
16. Williamson A, Hoggart B. Pain: A review of three commonly used pain rating scales. *J Clin Nurs* 2005;14:798-804.
17. Fricke J, Halladay SC, Bynum L, Francisco CA. Pain relief after dental impaction surgery using ketorolac, hydrocodone plus acetaminophen, or placebo. *Clin Ther* 1993;15:500-9.
18. Hartrick C, Van Hove I, Stegmann JU, Oh C, Upmalis D. Efficacy and tolerability of tapentadol immediate release and oxycodone HCl

immediate release in patients awaiting primary joint replacement surgery for end-stage joint disease: A 10-day, phase III, randomized, double-blind, active- and placebo-controlled study. *Clin Ther* 2009;31:260-71.

19. Stegmann JU, Weber H, Steup A, Okamoto A, Upmalis D, Daniels S. The efficacy and tolerability of multiple-dose tapentadol immediate release for the relief of acute pain following orthopedic (bunionectomy) surgery. *Curr Med Res Opin* 2008;24:3185-96.