



# Intraobserver and interobserver reliability of computed tomography measurements of the soft palate in French bulldogs

Pauline Deprez <sup>1</sup>, Iban Irubetagoiena,<sup>2</sup> Jean-Guillaume Grand,<sup>2</sup> Nathaniel Harran<sup>1</sup>

**To cite:** Deprez P, Irubetagoiena I, Grand J-G, *et al.* Intraobserver and interobserver reliability of computed tomography measurements of the soft palate in French bulldogs. *Veterinary Record Open* 2019;**6**:e000373. doi:10.1136/vetreco-2019-000373

Received 10 September 2019  
Revised 18 November 2019  
Accepted 27 November 2019

## ABSTRACT

**Background** CT imaging has been used to document the soft palate dimensions in brachycephalic dogs but reliability of such measurements has not been evaluated. The aims of this study were to propose a method of measurements of the soft palate in French bulldogs and determine its reliability.

**Methods** Thirty French bulldogs were prospectively included. Five measurements of the soft palate were performed on soft tissue and bone window mid-sagittal images: length, thickness at 25, 50 and 75 per cent of its length and sagittal plane cross-sectional area. Three sets of data were separately acquired by three observers. Intraobserver and interobserver reliability for all measurements was assessed using intraclass correlation coefficient (ICC).

**Results** The median ICCs showed excellent reliability (0.90 to 0.99) for all intraobserver measurements except for thickness at 75 per cent which showed good (0.80 to 0.89) to excellent reliability. The median ICC showed excellent reliability for all interobserver measurements.

**Conclusion** The soft palate measurements on a single CT image are reproducible and repeatable. Further study is needed to assess the reliability of these measurements in the same patient with different endotracheal tube positions.

## INTRODUCTION

Brachycephalic obstructive airway syndrome (BOAS) is an established cause of respiratory distress in French bulldogs and other brachycephalic breeds.<sup>1</sup>

While elongation of the soft palate has long been a known contributor to BOAS, thickening of the soft palate has more recently been proposed to contribute to the disease.<sup>1–3</sup> The dogs with severe BOAS had significantly thicker soft palates compared with dogs with absent or minimal BOAS and control dogs.<sup>2</sup> Histologically, thickening of the superficial epithelium, extensive oedema of the connective tissue, mucous glands hyperplasia and muscular alterations had all been associated to the thickening of the soft palate.<sup>3</sup>

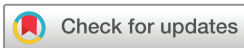Although some studies have specifically reported the use of CT imaging to document the length and thickness of the soft palate, little is known about the intra/interobserver reliability of these anatomical measurements.<sup>2,4–6</sup>

The aims of this study were to propose, based on previous publications, a method to evaluate the soft palate dimensions on CT images and to determine the intraobserver and interobserver reliability of these CT measurements. We hypothesised that measurements of the length, thickness and cross-sectional area of the soft palate on the mid-sagittal plane would be associated with good to high intraobserver and interobserver reliability.

## MATERIALS AND METHODS

### Subjects

A total of 30 consecutive client-owned French bulldogs that underwent CT scanning at our institution were prospectively included in this study between May 2017 and March 2018. Informed consent was obtained from owners to extend the CT scan to the head when this area was not included in the initial protocol. A clinical examination and a serum biochemistry analysis were conducted for each dog before induction of anaesthesia. The median age of the dogs was 5.5 years (range: 1–10 years) and the median bodyweight was 14 kg (range: 9.5–18.5 kg). Nineteen patients were male, three were neutered male, three were female and five were spayed female. Dogs were included in the study if they underwent CT in the time frame, regardless of their respiratory or digestive status. The dogs were admitted for intervertebral disc herniation (n=20), intracranial evaluation (n=3), discospondylitis (n=2), otitis media (n=2),



© British Veterinary Association 2019. Re-use permitted under CC BY-NC. No commercial re-use. Published by BMJ.

<sup>1</sup>Diagnostic Imaging, Aquivet Clinique Veterinaire, Eysines, France

<sup>2</sup>Surgery, Aquivet Clinique Veterinaire, Eysines, France

### Correspondence to

Dr Pauline Deprez; p.deprez@aquivet.fr

rhinitis (n=1), whole body staging of polyadenopathy (n=1) and lumbosacral syndrome (n=1).

### Computed tomography

All dogs were under general anaesthesia for the CT scanning. All dogs had premedication with 1 mg/kg maropitant and/or 0.01 mg/kg of acepromazine. Dogs were induced either with alfaxalone or propofol to effect. Isoflurane in 100 per cent oxygen was used for maintenance of anaesthesia during the procedure via a cuffed endotracheal (ET) tube. The size and type of the tube were selected by the veterinarian in charge of anaesthesia. All dogs were in sternal recumbency. The mouth was held open using a plastic needle cap (18G) between the ipsilateral maxillary and mandibular canine teeth.

CT was performed with a 16-slice multislice CT scanner (Activion 16, Toshiba Medical France, Puteaux, France). The images were acquired in helical mode with 0.5 mm detector width and a pitch of 0.938. Tube rotation time was one second and KVp=120, mAs=200. The images were reconstructed in 1 mm slices with a 0.8 reconstruction interval using a 512 x 512 matrix and bone and soft tissue algorithms (bone: window width 4500 Hounsfield unit (HU), window level 750 HU; soft tissue: window width 100 HU, window level 40 HU). For each dog, images of the entire head were acquired. The field of view was collimated to the head in the lateral dimension and adapted for each dog to start rostral to the nares and to extend to the second cervical vertebra. Postcontrast CT images were acquired after intravenous injection of iohexol (600 mgI/kg; 2 ml/kg, Omnipaque 300 mI/ml, GE Healthcare, Vélizy-Villacoublay, France). Intravenous contrast administration was part of the initial protocol and was not administered for the purpose of the study.

### Soft palate measurements

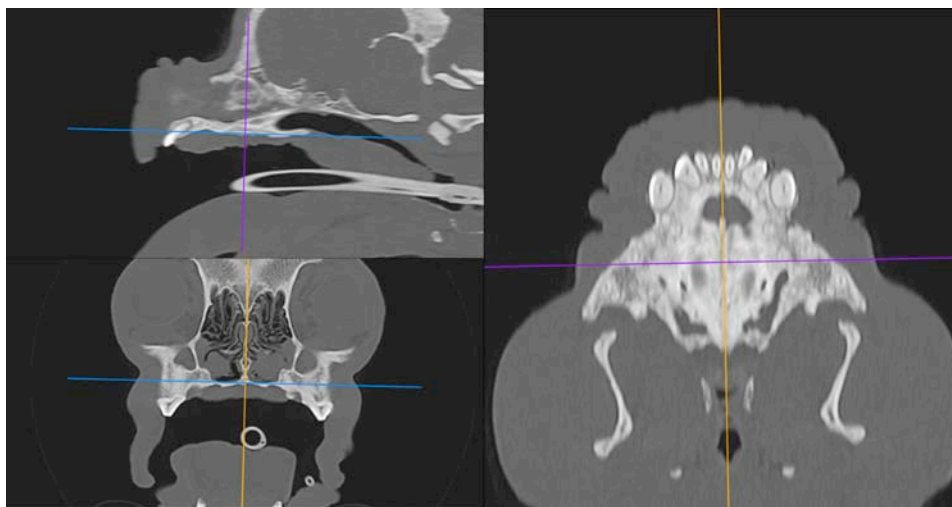
Image analysis was performed using an open source software (Horos, open source code software, Lesser General Public License (LGPL) at [horosproject.org](http://horosproject.org)). Studies

were anonymised and randomised. Before initiating the measurement protocol, multiplanar reconstructions were created to align the three planar axes with the hard palate, centred on the suture between maxillary bones (figure 1). A mid-sagittal image of the soft palate was then created and used for the measurements. All measurements were evaluated independently on three separate occasions by three observers (one European College Veterinary Diagnostic Imaging (ECVDI) diplomate, one European College Veterinary Surgeons (ECVS) diplomate and one third-year ECVDI resident) who were blinded to the patient's medical history and clinical status. To limit biased interpretation, the three evaluations for each dog were performed at two weeks interval.

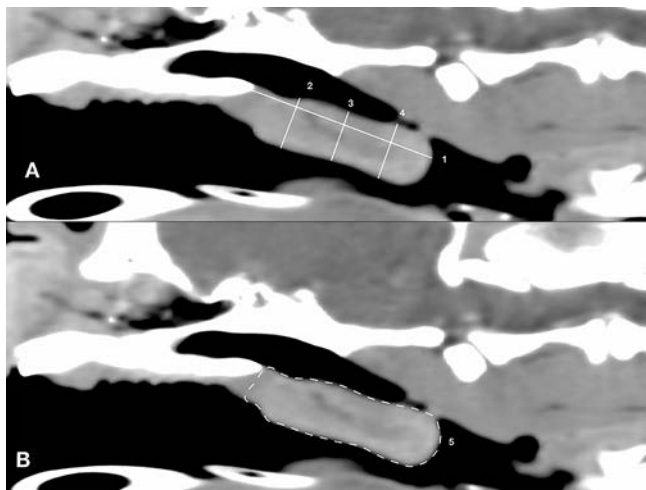
Adapted from the previously described method of measurements by Grand and Bureau,<sup>2</sup> five measurements were performed on all dogs on both soft tissue window (SW) and bone window (BW) (figure 2). These five measurements included: (1) soft palate length, from the end of the hard palate to the caudal end of the soft palate (SW length and BW length); (2) soft palate thickness at 25 per cent of its length (SW25 and BW25); (3) soft palate thickness at 50 per cent of its length (SW50 and BW50); (4) soft palate thickness at 75 per cent of its length (SW75 and BW75); and (5) soft palate sagittal plane cross-sectional area (SW area and BW area), drawn on the peripheral margins of the soft palate. Thickness measurements were all acquired perpendicular to the long axis of the soft palate. Only postcontrast images were used for the SW measurements.

### Statistical analysis

All statistical analyses were performed using the SPSS statistical package V.17 (SPSS). Intraobserver reliability for all measurements was assessed using intraclass correlation coefficient (ICC). For each observer and dog, the ICC (with 95% CI) was calculated based on the three sets of data using a two-way random effects. Interobserver



**Figure 1** Multiplanar reconstruction showing how the three axes were aligned with the hard palate, centred on the suture between maxillary bones.



**Figure 2** Mid-sagittal CT reconstruction image on soft tissue window showing the five CT measurements. (A) Length of the soft palate (1); thickness of the soft palate at 25 per cent (2), 50 per cent (3) and 75 per cent (4) of the soft palate length; (B) sagittal cross-sectional area (5).

reliability between the three observers was calculated in a similar manner. The following categories for expressing levels of reliability were used: excellent reliability, 0.90 to 0.99; good reliability, 0.80 to 0.89; fair reliability, 0.70 to 0.79; moderate reliability, 0.59 to 0.69; and poor reliability, <0.59.<sup>7,8</sup>

## RESULTS

### Intraobserver reliability

The intraobserver reliability for the 10 soft palate measurements (SW length, SW25, SW50, SW75, SW area, BW length, BW25, BW50, BW75 and BW area) using ICC and their 95% CI is reported in table 1. The median ICC showed excellent reliability for all intraobserver measurements except for BW75 and SW75 associated with good to excellent reliability.

### Interobserver reliability

The interobserver reliability for the 10 soft palate measurements (SW length, SW25, SW50, SW75, SW area, BW length, BW25, BW50, BW75 and BW area) using ICC is reported in table 1. The median ICC for the 10 measurements showed excellent interobserver reliability.

## DISCUSSION

The findings of our study support our initial hypothesis that CT measurements of the length, thickness and cross-sectional area of the soft palate on the mid-sagittal plane would be associated with good to excellent intraobserver and interobserver reliability. Soft palate length, soft palate thickness at 25 and 50 per cent of its length and cross-sectional area of the soft palate on the mid-sagittal plane are all associated with excellent intraobserver and interobserver reliability on both SW and BW images and may be used as reliable measurements for future BOAS studies.

Despite good to excellent intraobserver and interobserver reliability, measurements of the soft palate thickness at 75 per cent of its length may not be as reliable. In our study, this measurement showed the lowest intraobserver and interobserver reliability on both SW and BW images. These results could be explained by the fact that elongated soft palate may reach the nasopharyngeal wall dorsally and the tongue ventrally resulting in effacement of its peripheral margins. For instance, figure 3 shows that the soft palate is deflected dorsally in the caudal region of the nasopharynx and is in contact with the tongue ventrally, decreasing the conspicuity of its margins.

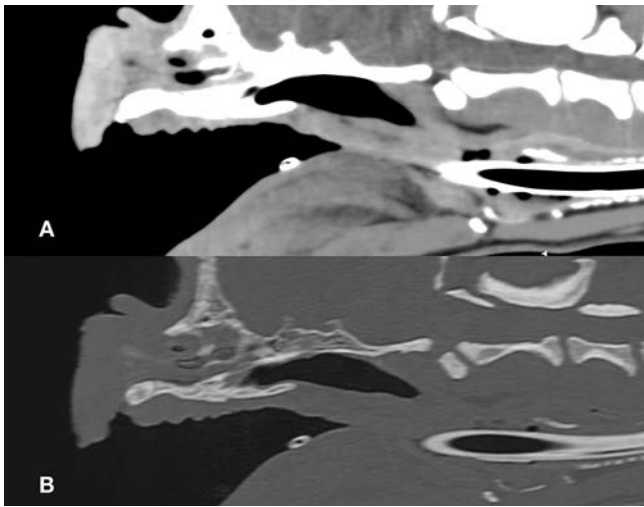
The measurements of the most experienced observer (observer 2) showed high intraobserver reliability for SW75 and BW75. As expected, increasing experience levels resulted in more accurate assessment of the soft palate margins even when the soft palate reaches the nasopharyngeal wall. In addition, lower end of the CI

**Table 1** Intraobserver and interobserver reliability for the 10 soft palate measurements using intraclass correlation coefficients (ICC) and their 95% CI

Measurements	Intraobserver reliability (ICC) (95% CI)			Interobserver reliability (ICC) (95% CI)
	1	2	3	
SW25	0.988 (0.979 to 0.994)	0.988 (0.979 to 0.994)	0.986 (0.975 to 0.993)	0.981 (0.966 to 0.991)
SW50	0.940 (0.891 to 0.970)	0.987 (0.976 to 0.993)	0.974 (0.952 to 0.987)	0.969 (0.943 to 0.984)
SW75	0.842 (0.711 to 0.920)	0.975 (0.954 to 0.987)	0.890 (0.797 to 0.944)	0.913 (0.843 to 0.956)
SW length	0.978 (0.978 to 0.994)	0.988 (0.978 to 0.994)	0.991 (0.983 to 0.995)	0.978 (0.960 to 0.989)
SW area	0.951 (0.911 to 0.975)	0.988 (0.978 to 0.994)	0.973 (0.950 to 0.986)	0.965 (0.937 to 0.982)
BW25	0.995 (0.990 to 0.997)	0.990 (0.982 to 0.995)	0.994 (0.989 to 0.997)	0.988 (0.978 to 0.994)
BW50	0.951 (0.910 to 0.975)	0.974 (0.951 to 0.987)	0.980 (0.962 to 0.990)	0.962 (0.928 to 0.980)
BW75	0.892 (0.802 to 0.945)	0.961 (0.929 to 0.980)	0.951 (0.910 to 0.975)	0.937 (0.888 to 0.969)
BW length	0.986 (0.975 to 0.993)	0.984 (0.972 to 0.992)	0.994 (0.989 to 0.997)	0.980 (0.963 to 0.990)
BW area	0.979 (0.962 to 0.989)	0.982 (0.966 to 0.991)	0.994 (0.988 to 0.997)	0.976 (0.945 to 0.986)

BW, bone window; SW, soft tissue window.





**Figure 3** (A) Soft tissue window image and (B) bone window image showing the soft palate reaching the nasopharyngeal wall dorsally and the tongue ventrally making difficult to differentiate precisely the margins of these anatomical structures.

range was higher for the less experienced observers 1 and 3 on the BW (BW75) than on the SW (SW75). This could be explained by the sharper edges on the bone algorithm facilitating identification of the margins of the soft palate. Therefore, BW images may be preferred to evaluate the thickness of the soft palate at 75 per cent of its length especially for less experienced observers. Measurements performed using a bone kernel could be used alone to measure the soft palate therefore removing the requirement of intravenous contrast administration.

Protocols for soft palate measurements using CT have been previously reported in dogs with BOAS but the level of soft palate measurement, reconstruction kernel and degree of opening of the mouth varied widely across studies.<sup>2-4,6</sup> In previous studies, the level of soft palate thickness measurements was assessed on mid-sagittal images either at 25, 50 and 75 per cent of its length, at its greatest thickness, or at the rostral and middle level of the soft palate.<sup>2,4,6</sup> Salguero *et al*<sup>5</sup> measured the thickness of the soft palate on transverse images immediately caudal to the hard palate. The CT scans were acquired with the mouth in a closed or opened position and in bone or SW images.<sup>2,4,6</sup> In the present study, we performed open-mouth head CT scans to increase the visibility of nasopharyngeal structures.<sup>9</sup>

In the present study, only French bulldogs were included to limit bias related to anatomical variations of the soft palate length and thickness among breeds. Future studies are needed to know if this protocol could be used in other brachycephalic breeds. In order to avoid selection bias on the subjects, a total of 30 consecutive client-owned dogs that underwent CT scan were included with no relation to their clinical respiratory or digestive status. This is a limitation of the study as the protocol of measurements is proposed to be used in affected brachycephalic dogs. The reliability of the measurements could

be mildly affected in a population of clinically affected BOAS dogs.

Another limitation of this study is that patients were intubated for CT scan and ET tube was not perfectly aligned on the midline in all dogs. Recently, Liu *et al*<sup>6</sup> investigated the effect of the ET tube placement during CT of brachycephalic dogs and showed that ET tube placement significantly decreased the cross-sectional area of the soft palate on the mid-sagittal plane and altered soft palate length while the rostral soft palate thickness (measured at the level of the caudal border of the hard palate) was only minimally affected. We decided to perform all measurements in intubated patients due to anaesthetic safety concerns. Intubation of brachycephalic dogs for delivering oxygen remains the standard of care. In this study, the three sets of measurements were made from the same CT images for each patient where the ET tube did not change in position between measurements. However, the ET tube position could change slightly between acquisitions performed at different times thus preventing comparison of measurements made on separate sets of images. Further study is warranted to assess this potential bias in order to confirm that the proposed method of measurements can be used to compare soft palate size of a patient over time.

In conclusion, the intraobserver and interobserver reliability varied on different measurements of the soft palate. Soft palate length, soft palate thickness at 25 and 50 per cent and cross-sectional area of the soft palate are all associated with excellent intraobserver and interobserver reliability and may be considered as reliable measurements on the same image. Measurement of the soft palate thickness at 75 per cent of its length showed the lowest intraobserver and interobserver reliability of the measurements performed although the reliability remained good to excellent between observers. Further study is needed to assess the reliability of soft palate measurements in the same patient with different ET tube positions.

**Funding** The authors have not declared a specific grant for this research from any funding agency in the public, commercial or not-for-profit sectors.

**Provenance and peer review** Not commissioned; externally peer reviewed.

**Data availability statement** All data relevant to the study are included in the article or uploaded as supplementary information.

**Open access** This is an open access article distributed in accordance with the Creative Commons Attribution Non Commercial (CC BY-NC 4.0) license, which permits others to distribute, remix, adapt, build upon this work non-commercially, and license their derivative works on different terms, provided the original work is properly cited, an indication of whether changes were made, and the use is non-commercial. See: <http://creativecommons.org/licenses/by-nc/4.0/>.

#### ORCID iD

Pauline Deprez <http://orcid.org/0000-0001-8428-807X>

#### REFERENCES

- 1 Dupré G, Heidenreich D. Brachycephalic syndrome. *Vet Clin North Am Small Anim Pract* 2016;46:691–707.
- 2 Grand J-GR, Bureau S. Structural characteristics of the soft palate and meatus nasopharyngeus in brachycephalic and

- non-brachycephalic dogs analysed by CT. *J Small Anim Pract* 2011;52:232–9.
- 3 Pichetto M, Arrighi S, Roccabianca P, *et al.* The anatomy of the dog soft palate. II. histological evaluation of the caudal soft palate in brachycephalic breeds with grade I brachycephalic airway obstructive syndrome. *Anat Rec* 2011;294:1267–72.
  - 4 Heidenreich D, Gradner G, Kneissl S, *et al.* Nasopharyngeal dimensions from computed tomography of pugs and French bulldogs with brachycephalic airway syndrome. *Vet Surg* 2016;45:83–90.
  - 5 Salguero R, Herrtage M, Holmes M, *et al.* Comparison between computed tomographic characteristics of the middle ear in nonbrachycephalic and brachycephalic dogs with obstructive airway syndrome. *Vet Radiol Ultrasound* 2016;57:137–43.
  - 6 Liu N-C, Troconis EL, McMillan M, *et al.* Endotracheal tube placement during computed tomography of brachycephalic dogs alters upper airway dimensional measurements. *Vet Radiol Ultrasound* 2018;59:289–304.
  - 7 Shrout PE, Fleiss JL. Intraclass correlations: uses in assessing rater reliability. *Psychol Bull* 1979;86:420–8.
  - 8 Portney LG, Watkins MP. *Foundations of clinical research: applications to practice*. 2 edn. Upper Saddle River, New Jersey: Prentice Hall Health, 2000.
  - 9 Laurensen MP, Zwingenberger AL, Cissell DD, *et al.* Computed tomography of the pharynx in a closed vs. open mouth position. *Vet Radiol Ultrasound* 2011;52:357–61.