

# Neurosurgical Treatment of Patients with Posterior Fossa Acute Subdural Hematoma Right after Cardiac Surgery

Jin KIKUCHI,<sup>1</sup> Kimihiko ORITO,<sup>1</sup> Kiyohiko SAKATA,<sup>1</sup> Masafumi YAMAMOTO,<sup>1</sup>  
Yu HASEGAWA,<sup>1,2</sup> Takahiro SHOJIMA,<sup>3</sup> Eiki TAYAMA,<sup>3</sup> and Motohiro MORIOKA<sup>1</sup>

<sup>1</sup>Department of Neurosurgery, Kurume University School of Medicine, Kurume, Fukuoka, Japan

<sup>2</sup>Department of Pharmaceutical Sciences, School of Pharmacy at Fukuoka,  
International University of Health and Welfare, Okawa, Fukuoka, Japan

<sup>3</sup>Division of Cardiovascular Surgery, Department of Surgery,  
Kurume University School of Medicine, Kurume, Fukuoka, Japan

## Abstract

As posterior fossa acute subdural hematoma (ASDH) right after cardiac surgery is extremely rare, the clinical course and optimal treatment strategy remain undetermined. We performed a retrospective analysis of patients with posterior fossa ASDH right after cardiac surgery requiring neurosurgical treatment at our institution over a 7-year period and, in this study, discussed the neurosurgical strategy and clinical course. Collected data included clinical history, laboratory results, time course, symptoms, neurosurgical treatment, outcome at discharge, and imaging studies. All six patients were women who had no history of head trauma and had received antithrombotic therapy during the perioperative period of cardiac surgery. All patients showed lower platelets count and were diagnosed with ASDH within 3 days (longest time 64 h) right after cardiac surgery. After discontinuation of anticoagulation therapy and administration of reversal agents, they underwent emergency hematoma evacuation craniotomy (n = 5) or burr hole drainage surgery (n = 1), which were performed in the prone (n = 4) or lateral (n = 2) positions. Four of these patients showed favorable outcomes, and two showed poor outcomes. One of the poor-outcome patients received three antithrombotic therapies, and another developed rapidly progressive ASDH. Posterior fossa ASDH associated with antithrombotic therapy right after cardiac surgery is frequently found in women, and emergent neurosurgical treatment with anticoagulation discontinuation and reversal agent administration can be performed safely. Burr hole drainage surgery might be acceptable in nonsevere cases. By contrast, we must pay attention to cases receiving both anticoagulant and antiplatelet drugs and rapid progression cases.

Keywords: acute subdural hematoma, antithrombotic therapy, cardiac surgery, posterior fossa, reversal agent

## Introduction

Intracranial hemorrhage is one of the significant complications of cardiac surgery because of the need for antithrombotic therapies.<sup>1-6)</sup> The rate of acute subdural hematoma (ASDH) after cardiac surgery is approximately 0.1%,<sup>1,6,7)</sup> and it mostly occurs in the supratentorial region. Hence, posterior fossa ASDH right after cardiac surgery is extremely rare and life-threatening because of its anatomical

characteristics of limited space and brain stem proximity. Until now, the treatment strategy remains controversial, including surgery and management of antithrombotic therapy, and there are few cohesive reports on neurosurgical intervention for posterior fossa ASDH right after cardiac surgery.

In this study, we describe six patients who developed posterior fossa ASDH right after cardiac surgery and underwent emergency neurosurgical treatment. We also dis-

Received September 28, 2021; Accepted February 2, 2022

Copyright © 2022 The Japan Neurosurgical Society

This work is licensed under a Creative Commons Attribution-NonCommercial-NoDerivatives International License.

**Table 1** Characteristics of the six cases before neurosurgical intervention

No.	Sex	Age	Past medical history	Cardiac surgery	Anti-coagulant	Anti-platelet	PT-INR	APTT (s)	Platelet count (/μL)	Reversal agents
1	F	51	–	AVR, MVP, CABG	Warfarin Heparin	–	1.6	36.1	$8.7 \times 10^4$	Protamine Vitamin K
2	F	79	HT	AVR, MAP, TAP, CABG, Maze	Warfarin Heparin	–	1.67	52.9	$6.4 \times 10^4$	Protamine Vitamin K
3	F	77	HT	AVR, CABG	Warfarin Heparin	Aspirin	1.07	36.1	$7.1 \times 10^4$	Protamine Vitamin K
4	F	66	HT, HL, breast cancer	AVR	Warfarin Heparin	Aspirin	0.98	42.1	$10.8 \times 10^4$	Protamine Vitamin K
5	F	75	HT, CI, asthma	AVR, re MVP	Heparin	–	1.1	51.9	$3.6 \times 10^4$	Protamine
6	F	73	HT, asthma, colon cancer	AVR, MVP	Heparin	–	1.3	74.7	$3.7 \times 10^4$	Protamine

Abbreviations: F, female; HT, hypertension; HL, hyperlipidemia; CI, cerebral infarction; AVR, aortic valve replacement; MVP, mitral valvuloplasty; CABG, coronary artery bypass grafting; TAP, tricuspid annuloplasty; MAP, mitral annuloplasty; MVR, mitral valve replacement; PT-INR, prothrombin time–international normalized ratio; APTT, activated partial thromboplastin time.

Discuss the unique comprehensive features of these patients.

## Materials and Methods

We retrospectively collected data on all patients at our institution who developed posterior fossa ASDH right after cardiac surgery during a 7-year period from January 2013 to December 2019. We assessed their clinical data, including sex, age, past medical history, type of cardiac surgery, use of antithrombotic medications, laboratory data including prothrombin time–international normalized ratio, activated partial thromboplastin time, platelet count, the time from the end of cardiac surgery to the onset of ASDH, the time from onset to neurosurgical operation, ASDH-related symptoms, Glasgow Coma Scale score, site of the ASDH, the presence of mixed density on computed tomography (CT) indicating its active form,<sup>8)</sup> the type of neurosurgery, surgical positioning, reversal agents, complications, and outcome at discharge.

When the patients developed neurological symptoms right after cardiac surgery, they underwent CT imaging, and the therapeutic strategy was discussed with a neurosurgeon. Cardiovascular and neurosurgeons engaged in a multidisciplinary approach to discuss the treatment plan, including the management of antithrombotic medications and the best neurosurgical approach. Neurosurgical indications in each case depended on the neurological severity, hematoma size, and the presence of brain stem and cerebellar compression caused by the ASDH. Antithrombotic therapies were restarted after surgery at a suitable time on the basis of the patient's condition. Outcomes at discharge were evaluated using the Glasgow Outcome Scale.

This study was performed according to the tenets of the Declaration of Helsinki. Approval was granted by the local

institutional ethics review board (approval number 2020-077). Informed consent was obtained from the individual patients or their families. Patients or their families signed informed consent regarding the publishing of the data and photographs.

## Results

During the study period, 1,885 patients (1,062 men and 823 women) underwent cardiac surgery using a heart-lung machine, and six patients required neurosurgical treatment for posterior fossa ASDH that developed right after cardiac surgery. All six were female patients, and their mean age was  $70.2 \pm 9.5$  years (range: 51–79). In terms of the operative procedures, all patients had undergone aortic valve replacement (AVR), four had undergone mitral valvuloplasty (MVP)/mitral annuloplasty, three had coronary artery bypass grafting (CABG), one maze procedure, and another tricuspid annuloplasty (Table 1).

None of the patients had any evidence of head trauma during the perioperative period, and all of them had received heparin (clotting time, >480 s) during the cardiopulmonary bypass. Additionally, all patients received anticoagulant therapy during the perioperative period and did not show any evidence of hypercoagulability. The patients underwent CT imaging when they developed neurological symptoms such as headache, vomiting, and altered level of consciousness. Symptoms appeared within 3 days (the longest time 64 h) right after cardiac surgery (Table 2). All patients were diagnosed with posterior fossa ASDH, which had mixed density on CT. Neurosurgical treatment was considered when patients showed severe symptoms, rapidly deteriorated, or significant mass effect on the brain stem or cerebellum on the image. Upon the decision to

**Table 2** Characteristics related to the neurosurgical treatment

No.	Interval of cardiac surgery to the symptom of ASDH (h)	Interval of ASDH symptoms to neuro-surgical operation (h)	Symptom(s)	GCS	Site of bleeding	Mixed density	Neurosurgical procedure	Positioning	Complication(s)	Antithrombotic therapy resumption after neuro-surgical treatment	GOS
1	60	12	Headache	4	Bilateral	+	Evacuation, craniectomy, ventricular drainage	Prone	–	3 days	GR
2	51	20	Vomiting	12	Bilateral	+	Evacuation, craniectomy, ventricular drainage	Prone	–	24 days	MD
3	58	11	Headache, vomiting	15	Left	+	Evacuation, craniotomy	Lateral	–	7 days	GR
4	61	10	Headache, vomiting	15	Bilateral	+	Evacuation, craniectomy	Prone	Cerebellar bleeding, edema	Not resumed	D
5	50	13	LOC	4	Bilateral	+	Evacuation, craniectomy, ventricular drainage	Prone	Re-bleeding	11 days	VS
6	64	24	Vomiting	15	Bilateral	+	Burr hole drainage	Lateral	–	13 days	GR

Abbreviations: ASDH, acute subdural hematoma; POD, postoperative day; LOC, loss of consciousness; GCS, Glasgow Coma Scale; GOS, Glasgow Outcome Scale; GR, good recovery; MD, moderately disabled; D, dead; VS, vegetative state.

undergo surgery, anticoagulant reversal was administered, as described in Table 1. The patients underwent emergent hematoma evacuation with craniotomy or burr hole surgery with drainage, which was performed with the patient in the prone or lateral position. In one case, venous bleeding from the surface of the brain was observed, but in the other cases, a clear bleeding point was not found. The patients of cases 4 and 5 developed significant hemorrhagic complications and poor outcomes, whereas the rest were discharged from our hospital with favorable outcomes (Table 2).

### Case presentations

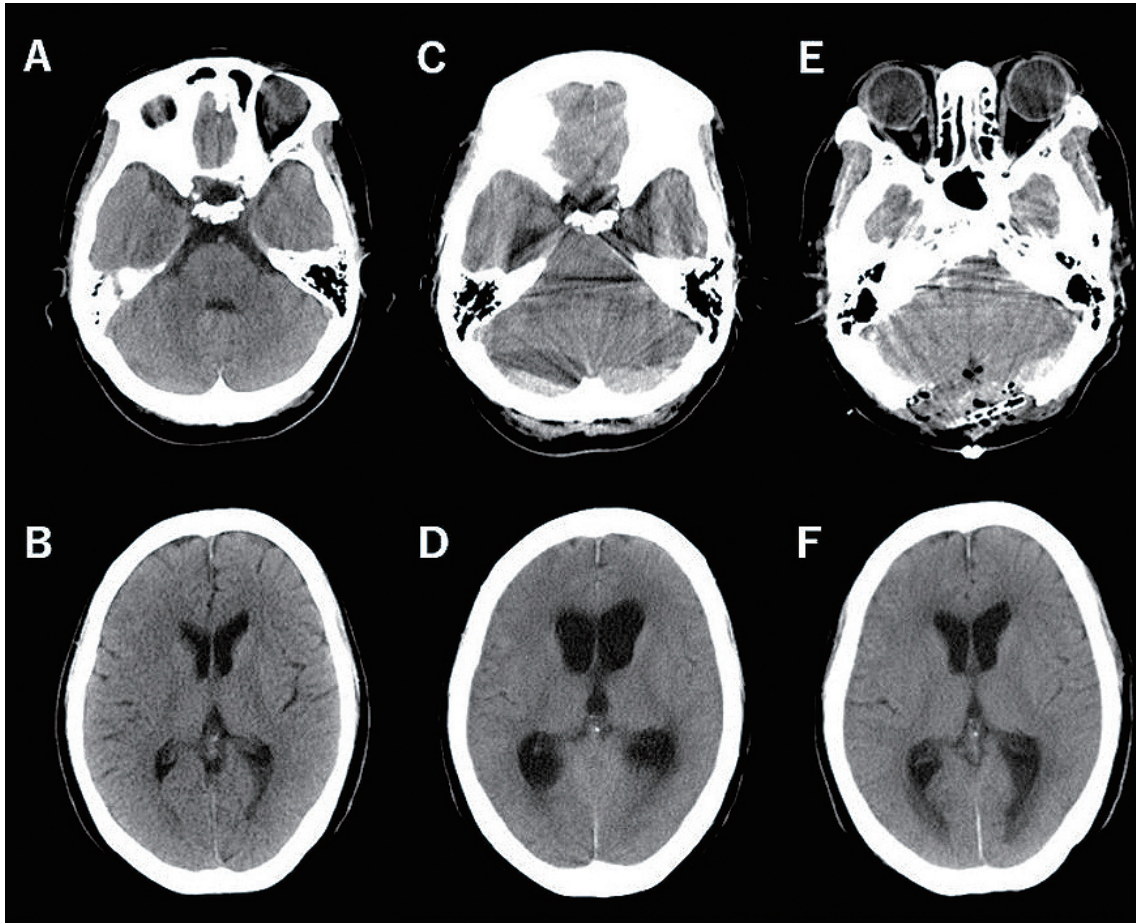
#### Case 1

A 51-year-old female patient underwent AVR because of a stenotic valve, MVP for mitral regurgitation, and CABG for coronary stenosis. Anticoagulant therapy of continuous heparin (10,000 U/day) and oral warfarin was initiated on day 2 after cardiac surgery. On 60 h right after cardiac surgery, the patient reported headaches, and a CT scan revealed thin bilateral ASDHs in the cerebellar hemisphere, whereas preoperative imaging revealed no apparent hematomas (Fig. 1A and 1B). Since the patient did not have any

neurological symptoms at the time, she was managed conservatively with heparin discontinuation. Unfortunately, her level of consciousness deteriorated, and she was comatose for 6 h. Follow-up CT imaging revealed a marked increase in the size of the hematoma, besides obstructive hydrocephalus (Fig. 1C and 1D). Vitamin K2 and protamine were administered, and the patient subsequently underwent neurosurgical evacuation in the prone position. The foramen magnum was resected with a rongeur, and external decompression was performed with duraplasty using fascia. The bleeding point was not found, and no arterial bleeding was noted. Postoperative CT imaging revealed sufficient decompression of the cerebellar hemispheres without any evidence of hydrocephalus (Fig. 1E and 1F). Her symptoms gradually improved, and heparin was restarted on day 3 after hematoma evacuation. There were no thrombotic complications, and the patient was discharged from our hospital with positive outcomes. No postoperative chest wound complications were noted.

#### Case 4

A 66-year-old female patient underwent AVR because of a stenotic valve. This patient was taking aspirin for inter-



**Fig. 1** Radiological images of Case 1.

Computed tomography imaging acquired in the preoperative stage did not reveal any abnormalities (A and B). There was an obvious subdural hematoma in the posterior fossa and obstructive hydrocephalus on day 3 right after cardiac surgery (C and D). Hematoma evacuation was successfully performed (E and F).

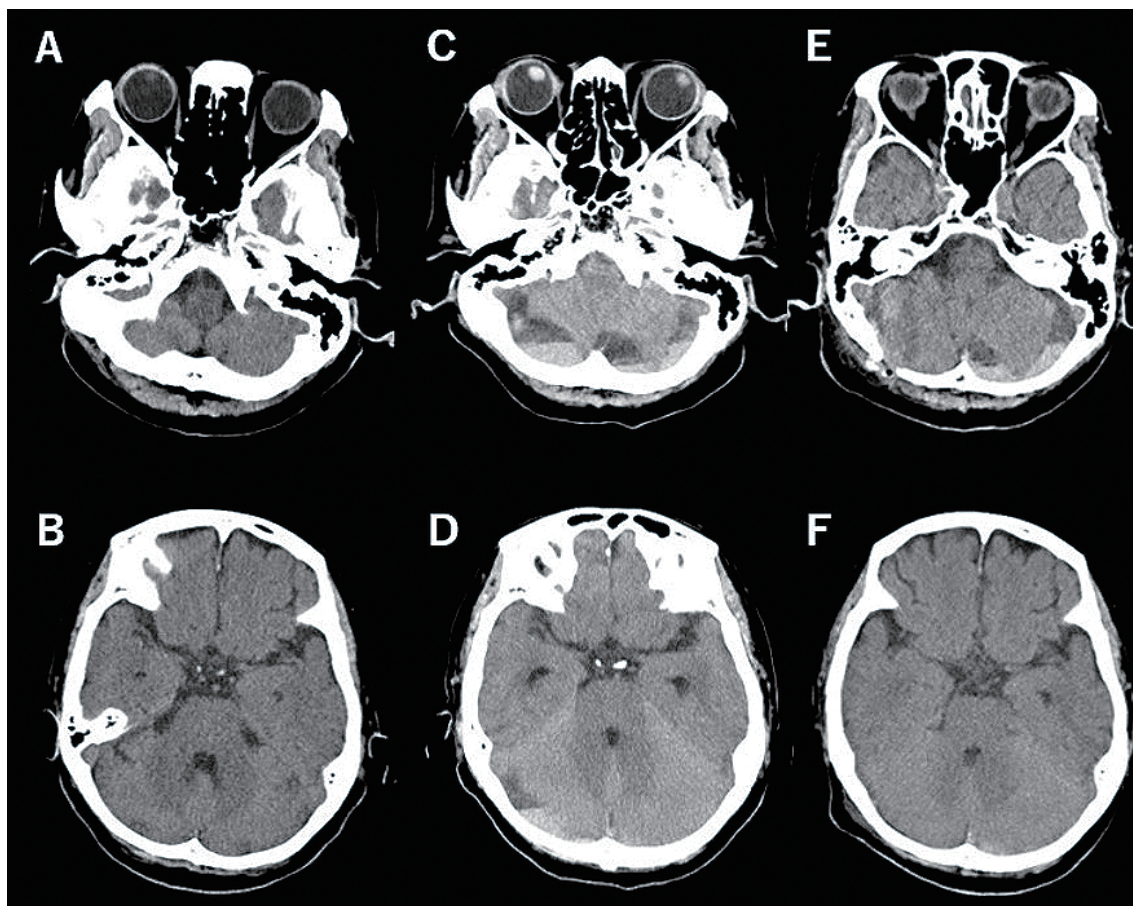
nal carotid artery stenosis before cardiac surgery. Preoperative magnetic resonance imaging revealed no obvious intracranial lesions (Supplementary Fig. 1A and 1B). Oral administration of aspirin was discontinued after the operation. Continuous administration of heparin (10,000 U/day) was initiated on day 1 after cardiac surgery and oral warfarin therapy on day 2. On 61 h right after cardiac surgery, the patient complained of severe headaches and frequent vomiting. Emergency CT imaging revealed thick bilateral ASDHs in the cerebellar hemisphere (Supplementary Fig. 1 C and 1D). Vitamin K2 and protamine were administered, and the patient subsequently underwent emergency neurosurgical hematoma evacuation in the prone position. The foramen magnum was resected with a rongeur, and external decompression was performed. However, because of continuous venous bleeding around the brain surface, complete hemostasis could not be achieved. On day 4, the patient developed dilated pupils bilaterally, and CT imaging revealed marked swelling and bilateral cerebellar hemorrhage (Supplementary Fig. 1E and 1F). The patient un-

derwent emergent hematoma evacuation and ventricular drainage in the prone position. She remained comatose and died on day 28 after cardiac surgery. No postoperative chest wound complications were noted.

#### Case 6

A 73-year-old female patient underwent AVR and MVP for a valvular disorder. Preoperative CT imaging revealed no obvious intracranial lesions (Fig. 2A and B). Continuous administration of heparin (10,000 U/day) was initiated on day 1 after cardiac surgery. On 64 h right after cardiac surgery, the patient complained of headaches and vomiting. Emergent CT imaging revealed bilateral ASDHs in the posterior fossa. Given that the patient had a low platelet count of 37,000/ $\mu$ L, she was managed conservatively with heparin discontinuation and protamine to decrease its effect. CT imaging performed at 90 h right after cardiac surgery revealed a marked right-sided hematoma increase (Fig. 2C and D). She underwent aspiration and irrigation through a single burr hole in the left lateral position with





**Fig. 2** Radiological images of Case 6.

Computed tomography imaging acquired in the preoperative stage did not reveal any abnormalities (A and B). There was an obvious posterior fossa right-side dominant subdural hematoma on day 3 right after cardiac surgery (C and D). Evacuation through a burr hole was performed, and the hematoma on the right side decreased on the postoperative computed tomography scan (E and F).

platelet transfusion. Because of the laterality of the ASDH (right-side dominance) and the slow progression, we first chose burr hole surgery with drainage. We had prepared for a craniotomy in case achieving hemostasis was difficult, but there was no need. Since it was a burr hole surgery, no apparent bleeding point could be confirmed. Postoperative CT imaging revealed sufficient decompression of the cerebellar hemisphere (Fig. 2E and F), and the patient's symptoms improved immediately after surgery. Thrombotic complications did not occur, and heparin was restarted on day 13 after the neurosurgical operation. The patient was discharged from our hospital with a favorable outcome, and hematoma recurrence was not observed during the follow-up period. No postoperative chest wound complications were noted.

### Discussion

In this study, we described six cases of posterior fossa ASDH that developed right after cardiac surgery, all of

whom underwent neurosurgical treatment.

Posterior fossa ASDH is broadly divided into traumatic and nontraumatic, and most are traumatic.<sup>9-11)</sup> Posterior fossa ASDH is rare with a frequency of less than 3% of head injuries,<sup>12,13)</sup> and it is also reported to have a poor prognosis and a high mortality rate (33%-100%).<sup>12,13)</sup> Although fracture with laceration of the cerebellar cortex seems to be the main mechanism involved in traumatic cases,<sup>12-14)</sup> injury of bridging veins were bleeding origin in some cases.<sup>9)</sup>

Nevertheless, our cases had no obvious traumatic episodes and were considered spontaneous like the cases described previously.<sup>9,11,15,16)</sup> The causes of nontraumatic posterior fossa ASDH include antithrombotic therapy, cerebrovascular diseases such as arteriovenous malformation, aneurysms, brain tumors, and intracranial hypotension due to spinal drainage or osmotic diuretics.<sup>9-11)</sup> The reported nontraumatic posterior fossa ASDH were 10 cases as far as we searched, and most of them had some kind of blood coagulation abnormality.<sup>1,3,9-11,16-18)</sup> In many reported cases,

**Table 3** Reported cases of posterior fossa ASDH after cardiac surgery

Study	Sex	Age	Cardiac surgery	POD (occurrence)	Symptom(s)	Site of bleeding	Neurosurgical procedure	GOS
Maruyama et al. 1987	F	54	MVR	2	Headache	Bilateral	Drainage	MD
Kasahara et al. 1994	F	59	MVR	3	LOC	Bilateral	Conservative	GR
Nakajima et al. 2003	F	49	DVR + TAP	2	LOC	Bilateral	Drainage	GR
Oka et al. 2008	F	44	CABG	3	Headache, LOC	Right	Evacuation, ventricular drainage	GR
Oka et al. 2008	F	79	CABG	3	LOC	Left	Evacuation, ventricular drainage	GR

Abbreviations: F, female; MVR, mitral valve replacement; DVR, double valve replacement; TAP, tricuspid annuloplasty; CABG, coronary artery bypass grafting; POD, postoperative day; LOC, loss of consciousness; GOS, Glasgow Outcome Scale; GR, good recovery; MD, moderately disabled.

the pathogenic mechanism was considered to be the bridging vein injury in the posterior fossa with minor trauma, and bleeding expanded in a short time with abnormal blood coagulation.<sup>9)</sup>

Most neurological complications after cardiac surgery are thromboembolic events.<sup>3,6)</sup> Intracranial hemorrhagic events occurring following cardiac surgery are uncommon but may be proved devastating because of enhanced bleeding tendency caused by heparin administration, hypothermia, and postoperative anticoagulation therapy.<sup>1,2,5-7)</sup> ASDH right after cardiac surgery has been reported to have a rate of 0.1%,<sup>1,6,7)</sup> and posterior fossa ASDH in the early stage is extremely rare.<sup>1,3,17,18)</sup> There have been five reports of posterior fossa ASDH right after cardiac surgery (Table 3).<sup>1,3,17,18)</sup> During the perioperative period of cardiac surgery, strong antithrombotic therapy is given, including during surgery. Antithrombotic therapy was associated with a higher risk of subdural hematoma.<sup>19)</sup> The cause of ASDH after cardiac surgery is a tearing of bridging veins that occurs with a fluid shift to the brain and a bleeding tendency induced by the antithrombotic therapy.<sup>2,7,20)</sup> Arterial bleeding was not apparent in all of our cases, and the bleeding point could only be identified in cases with venous bleeding from the surface of the cerebellum. None of the past reports of posterior fossa ASDH after cardiac surgery described the bleeding point in detail. In our case, sudden fluctuations in intracranial pressure during extracorporeal circulation caused damage to the bridging veins, and intensive antithrombotic therapy promoted bleeding, resulting in subdural hematoma.

In the patients described here, mild platelet count reduction and coagulation function were observed, and both are sufficient to enhance the risk of intracranial bleeding. It has been reported that ASDH right after cardiac surgery occurs more frequently in the group with less platelet transfusion during cardiac surgery.<sup>5)</sup> In our study, the platelet level at the onset of ASDH was low in all the cases. Low platelet levels may be involved in the development of ASDH. There have been reports of spontaneous posterior fossa ASDH associated with thrombocytopenia in three cases in the past.<sup>11,15,16)</sup> Pollo et al. discussed that thrombo-

cytopenia may result in a hypocoagulable state, increasing the risk of spontaneous intracranial hemorrhage.<sup>15)</sup> Aggressive platelet transfusion may prevent the onset and severity of ASDH right after cardiac surgery. Additionally, antithrombotic therapy has been reported to increase the frequency of ASDH.<sup>19,20)</sup> Based on the fact that the patients had no obvious cerebrovascular disease and had not undergone spinal drain placement, we speculated that mild antithrombotic effects and the low platelet level enhanced bleeding due to mild vascular injuries.

Interestingly, in this study, all six patients were women (Table 1). Additionally, the reported cases of posterior fossa ASDH (Table 3) after cardiac surgery were also all female. Kochi et al. have reviewed rare cases of spontaneous posterior fossa ASDH and reported that 12 out of the 13 cases (92.3%) were female patients.<sup>21)</sup> The reason for female predominance is unclear, but sexual anatomical features and/or vascular differences might exist in the posterior fossa.

In our cases, as a feature on the image, in all six cases, the hematoma had a low-density area and a high-density area forming a horizontal plane on CT images. This was a finding called "fluid blood level," which is considered to be related to an abnormality in the hemostatic function and related to the rapid growth of hematoma and poor prognosis in the patients with antithrombotic medication.<sup>22,23)</sup>

Patients right after cardiac surgery are less active because of the large invasiveness of the surgery and the prolonged effects of anesthetic agents.<sup>6)</sup> Additionally, various lines are connected, making the immediate diagnosis of neurological complications difficult.<sup>6)</sup> When headache, vomiting, or loss of consciousness occur, as in our case, the possibility of neurological complications should always be considered, and the image examination should be performed.

The neurosurgical strategy and timing are important for the treatment of ASDH. The six patients underwent neurosurgical treatment within 1 day after the ASDH diagnosis. Since the posterior fossa is relatively small and contains the brain stem and cerebellum, an ASDH in this region can be life-threatening because of acute hydrocephalus

and brain stem compression. In our patients, symptomatic features and mixed density findings (indicating active form)<sup>8)</sup> were observed on CT imaging. Moreover, we observed excellent surgical outcomes in the three patients who had supratentorial ASDH right after cardiac surgery.<sup>24)</sup> Even in cases of traumatic ASDH in the posterior fossa, de Amorim et al. recommended neurosurgical intervention if the hematoma thickness is greater than 10 mm or in the presence of a mass effect.<sup>13)</sup> Thus, the patients in this study were treated surgically by an emergency procedure, and anticoagulant therapy was discontinued.

Although the clinical course of four patients was favorable, two patients (numbers 4 and 5 in Tables 1 and 2) demonstrated poor outcomes. Patient number 4 was administered with the strongest antithrombotic therapy comprising heparin, warfarin, and aspirin. By contrast, patient number 5 received only one antithrombotic drug but experienced rapid deterioration. Although we could not determine the factors contributing to poor outcomes in this study, the rapid progression and strong antithrombotic medications may be critical factors. David Gaist et al. reported that the risk of subdural hematoma was highest when a vitamin K antagonist was used concurrently with an antiplatelet drug.<sup>19)</sup>

In terms of the neurosurgical approach, the evacuation of the ASDH, decreasing intracranial pressure by wide craniotomy, and foramen magnum decompression in the prone position are pivotal factors. Alternatively, a small craniotomy or irrigation through a single burr hole performed in the lateral position could be an option for the treatment of unilateral or slowly progressive ASDH. We do not exclude the efficacy of conservative management for the treatment of these patients. Nevertheless, no studies have compared the neurosurgical and conservative approaches. We recommend that neurosurgical management be considered for patients with clinical deterioration due to ASDH-related symptoms, hydrocephalus, and hematoma expansion. We planned to evacuate the hematomas in the posterior fossa with external decompression in the prone position. In five of the cases, this was done through a craniotomy. For patient number 6, burr hole surgery with drainage was performed in the lateral position, which showed unilateral slow progression of ASDH, and good outcomes could be obtained. Hence, burr hole drainage surgery might be chosen for the nonsevere cases.

No obvious postoperative cardiac complications were noted, including the surgical wound and embolization issues. Since the midline chest incision is commonly wide after cardiac surgery, we focused on avoiding excessive pressure with prone positioning in the early stage after cardiac surgery. Consequently, none of the patients developed any skin problems in the chest. Additionally, we were obliged to stop antithrombotic therapy and use anticoagulant reversal drugs. Although none of our patients showed any evidence of cardiac complications in the perioperative

period, we should consider the best treatment approach in each case to avoid thrombotic complications. Based on our experience, emergency neurosurgical treatment with discontinuation of anticoagulant therapy should be considered for patients with posterior fossa ASDH right after cardiac surgery, and both prone and lateral positionings are acceptable.

By accumulating the number of cases in the future, it will be possible to construct more optimal treatment management, including burr hole surgery.

## Conclusion

We analyzed six cases of an extremely rare complication of posterior fossa ASDH right after cardiac surgery, which showed female dominancy. For the four cases, emergent neurosurgical treatment with anticoagulation discontinuation and reversal agent administration has been performed safely, and burr hole drainage surgery might be acceptable. By contrast, we must pay attention to the cases that have received both anticoagulant and antiplatelet drugs and the cases showing rapid progression.

## Supplementary Material

<https://doi.org/10.2176/jns-nmc.2021-0314>

## Acknowledgments

The authors thank Editage ([www.editage.jp](http://www.editage.jp)) for English language editing.

## List of abbreviations

ASDH, acute subdural hematoma  
AVR, aortic valve replacement  
CABG, coronary artery bypass grafting  
CT, computed tomography  
MVP, mitral valvuloplasty

## Conflicts of Interest Disclosure

The authors have no conflicts of interest to declare.

## References

- 1) Kasahara S, Sakai A, Isomatsa Y, Akishima S, Nie N, Oosawa M: Subdural hematoma complicated after open heart surgery: a report of two cases with successful treatment. *Kyobu Geka* 47: 732-735, 1994 (Japanese)
- 2) Krous HF, Tenckhoff L, Gould NS, Stamm SJ: Subdural hematoma following open-heart operations. *Ann Thorac Surg* 19: 269-276, 1975
- 3) Maruyama M, Kuriyama Y, Sawada T, Fujita T, Omae T: Subdural hematoma following cardiovascular surgery. *Jpn J Stroke* 9: 408-414, 1987 (Japanese)



- 4) Nishimura K, Koga M, Minematsu K, et al.: Intracerebral hemorrhage in patients after heart valve replacement. *J Neurol Sci* 363: 195-199, 2016
- 5) Osada H, Marui A, Tanaka S, Meshii K, Ohnaka M, Nakajima H: Acute subdural hematoma after aortic surgery: A retrospective comparative study. *J Asian Cardiovasc Thorac Ann* 23: 24-30, 2015
- 6) Osaka M, Konishi T, Koishizawa T: Bilateral subdural hematoma following aortic root and subtotal aortic arch replacement. *Gen Thorac Cardiovasc Surg* 57: 33-36, 2009
- 7) Uchida T, Hamasaki A, Ohba E, Yamashita A, Hayashi J, Sadahiro M: Life-threatening subdural hematoma after aortic valve replacement in a patient with Heyde syndrome: A case report. *J Cardiothorac Surg* 12: 65, 2017
- 8) Subramanian SK, Roszler MH, Gaudy B, Michael DB: Significance of computed tomography mixed density in traumatic extra-axial hemorrhage. *Neurol Res* 24: 125-128, 2002
- 9) Finger G, Martin OG, Basso LS, et al.: Acute spontaneous subdural hematoma in posterior fossa: Great outcome. *World Neurosurg* 119: 146-150, 2018
- 10) Kanter R, Kanter M, Kirsch W, Rosenberg G: Spontaneous posterior fossa subdural hematoma as a complication of anticoagulation. *Neurosurgery* 15: 241-242, 1984
- 11) Spina A, Boari N, Gagliardi F, Mortini P: Bilateral spontaneous acute subdural hematoma of the posterior fossa: Case report. *Neurosurg Q* 26: 154-157, 2016
- 12) d'Avella D, Servadei F, Scerrati M, et al.: Traumatic acute subdural haematomas of the posterior fossa: clinico-radiological analysis of 24 patients. *Acta Neurochir (Wien)* 145: 1037-1044, 2003
- 13) de Amorim RLO, Stiver SI, Paiva WS, et al.: Treatment of traumatic acute posterior fossa subdural hematoma: Report of four cases with systematic review and management algorithm. *Acta Neurochir (Wien)* 156: 199-206, 2014
- 14) Takeuchi S, Takasato Y, Wada K, et al.: Traumatic posterior fossa subdural hematomas. *J Trauma Acute Care Surg* 72: 480-486, 2012
- 15) Pollo C, Meuli R, Porchet F: Spontaneous bilateral subdural haematomas in the posterior cranial fossa revealed by MRI. *Neuroradiology* 45: 550-552, 2003
- 16) Saito K, Sakurai Y, Uenohara H: A case of acute subdural hematoma in the posterior fossa with idiopathic thrombocytopenic purpura. *No To Shinkei* 44: 377-381, 1992 (Japanese)
- 17) Nakajima M, Tsuchiya K, Kanemaru K, et al.: Subdural hemorrhagic injury after open heart surgery. *Ann Thorac Surg* 76: 614-615, 2003
- 18) Oka K, Kamota T, Satou M, et al.: Subdural Hematoma Following Cardiac Surgery. *Kyobu Geka* 61: 868-872, 2008 (Japanese)
- 19) Gaist D, Rodríguez LAG, Hellfritsch M, et al.: Association of antithrombotic drug use with subdural hematoma risk. *JAMA* 317: 836-846, 2017
- 20) Lagares A, Domínguez J, Lobato RD, González P: Bilateral posterior fossa subdural haematomas secondary to anticoagulant therapy. *Acta Neurochir (Wien)* 140: 1097-1098, 1998
- 21) Kochi R, Mino M, Sonobe S, Yoshida M, Tominaga T: Spontaneous development of encapsulated subdural hematoma in the posterior cranial fossa after cardiac surgery: A case report. *NMC Case Rep J* 5: 87-90, 2018
- 22) Kawamata T, Takeshita M, Kubo O, Izawa M, Kagawa M, Takakura K: Management of intracranial hemorrhage associated with anticoagulant therapy. *Surg Neurol* 44: 438-442, 1995
- 23) Pflieger MJ, Hardee EP, Contant CF, Hayman LA: Sensitivity and specificity of fluid-blood-levels for coagulopathy in acute intracerebral hematomas. *AJNR Am J Neuroradiol* 15: 217-223, 1994
- 24) Aoyagi S, Kosuga T, Fukunaga S, Tayama E, Ueda T: Subdural hematoma after open-heart surgery. *J Heart Valve Dis* 16: 450-453, 2007

---

Corresponding author: Jin Kikuchi, MD

Department of Neurosurgery, Kurume University School of Medicine, 67 Asahimachi, Kurume City, Fukuoka 830-0011, Japan.

e-mail: d08sm040@outlook.jp