

Available online at www.sciencedirect.com

ScienceDirect

journal homepage: www.elsevier.com/locate/radcr

Case Report

Percutaneous screw-reinforced cement osteoplasty for palliation of postremission pain in larger lytic sacro-acetabular iliac cavities

Daniel K. Powell, MD*, Allen Ardestani, MD, PhD

Oncologic Radiologist, West Cancer Center and Research Institute, University of Tennessee Health Science Center, 7945 Wolf River Blvd, Germantown, TN 38138, USA

ARTICLE INFO

Article history:

Received 22 June 2019

Revised 24 June 2019

Accepted 26 June 2019

Available online 12 July 2019

Keywords:

Pain

Bone

Osteotomy

Cancer

ABSTRACT

We present 2 cases of palliative percutaneous screw fixation for refractory pain from periacetabular residual cavities, after clinical remission, from osteolytic iliac masses involving the cortices of the sacroiliac joint (SIJ). Two patients—1 with a treated 8 cm breast metastasis and another with a treated 14 cm plasmacytoma—were selected for osseous stabilization based on imaging criteria and physical signs of iliac deformability and SIJ dysfunction. Neither lesion exhibited active malignancy following systemic therapy or discrete fracture. Following computed tomography-guided screw fixation across the mass and SIJ, with surrounding cement osteoplasty, to reduce mechanical stress on abnormal bone, both patients reported pain resolution beyond 1-year. This technique may be a suitable palliation even for large treated pelvic metastatic cavities and in the absence of fracture.

© 2019 The Authors. Published by Elsevier Inc. on behalf of University of Washington.

This is an open access article under the CC BY-NC-ND license.

[\(http://creativecommons.org/licenses/by-nc-nd/4.0/\)](http://creativecommons.org/licenses/by-nc-nd/4.0/)

Introduction

Tumor-related pain can cause significant morbidity in cancer patients [1], requiring localized intervention in approximately 15% of patients for whom systemic therapy and narcotic analgesia provide inadequate relief [1]. In addition to surgery [2] and radiation therapy [3], the role of “interventional strategies” for palliation of painful lytic masses is also listed in the National Comprehensive Cancer Networks guidelines for treating adult cancer pain [4]. One such strategy, percutaneous cement osteoplasty, has been shown to relieve pain

in approximately 90% of patients following percutaneous cementoplasty of extra-vertebral lytic metastases averaging 3 cm in size [5]. Notably, the success rate of this technique does not significantly differ when used alone or in combination with ablation, suggesting that its mechanism of pain-relief stems in large part from structural stabilization. While screw fixation and cement reinforcement has been widely used for pathologic pelvic fractures and prophylactic stabilization of impending pathologic fractures [6–13], less is known about the suitability of cement-reinforced screw fixation for lesions larger than 3–6 cm, that are not traditionally considered at risk for impending fracture, display no active tumor, and that significantly involve the bone adjacent to a cartilaginous joint. In such periacetabular/perisacral iliac lesions of larger size, the associated instability from cortical destruction and

* Corresponding author.

E-mail address: danielkpowell@gmail.com (D.K. Powell).<https://doi.org/10.1016/j.radcr.2019.06.009>1930-0433/© 2019 The Authors. Published by Elsevier Inc. on behalf of University of Washington. This is an open access article under the CC BY-NC-ND license. (<http://creativecommons.org/licenses/by-nc-nd/4.0/>)

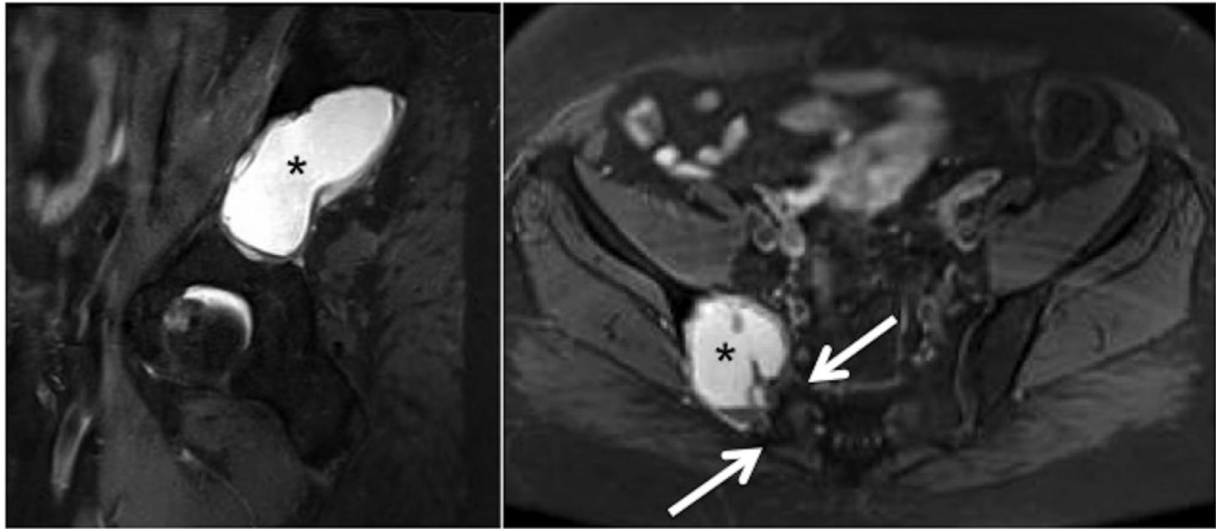


Fig. 1 – (Patient 1) Sagittal and axial short tau inversion recovery magnetic resonance sequences through the pelvis show the 8 cm fluid-signal cavity (*), at the site of the initially 12 cm mass, eroding large portions of the sacroiliac joint (white arrows), and causing signal abnormalities in the sacral ala, with approximately 70% complete erosion of involved iliac cortex.

deformability across thinned bone presumably contribute in large part to the etiology of pain, especially when adjacent to or involving a load-transferring structure such as the sacroiliac joint (SIJ) [14]. As such, the present report details 2 cases of patients with osteolytic pelvic lesions referred for palliation of opioid-refractory pain. Though in clinical remission following systemic therapies, both continued to experience debilitating pain at the site of their treated pelvic cavities in which large size, bone involvement adjacent to the SIJ and acetabulum, and apparent osseous deformability from thinning and deficiency suggested the need for strong mechanical support and stabilization. To that end, cement-reinforced screw fixation was used as a modified approach to achieve pain control. Institutional Review Board approval was not required for these case reports.

Case report 1

The first patient had an oncologic history notable for a 12 cm hypermetabolic and enhancing lytic soft tissue breast cancer metastasis causing expansion and extensive cortical erosion of the iliac wing for which she had received definitive radiation and hormone therapy 18 months prior. The mass deformed a large portion of the SIJ with iliac side cortical thinning and focal disruption as well as abnormal ground glass density in the sacral ala. At presentation for pain palliation, she was 67 years old and the iliac cavity had decreased in size to 8 cm, no longer exhibited contrast enhancement, had developed homogeneous fluid-bright T2-hyperintensity on magnetic resonance imaging (Fig. 1), and exhibited no residual hypermetabolism on positron emission tomography for over a year, suggesting resolution of the metastatic mass, but significant residual distortion and deficiency of the ilium and the bone comprising the SIJ.

The cavity qualified as an Enneking Zone II (periacetabular region) lesion, at risk for mechanical failure (with extension into the iliac wing, Zone I; as well as into the sacral region, Zone IV), but was no greater than Harrington class I (with sufficient bone to permit conventional arthroplasty, without medial or acetabular dome defects, nor suitable for complete resection with reconstruction) [2]. There was no evidence of a discrete fracture, neural compression, or active malignant disease. Physical examination findings of reproducible tenderness and deformability elicited by SIJ palpation, flexion-abduction-external-rotation maneuver, compression of the lateral iliac wing, and sacral thrust maneuvers, combined with clinical symptoms of localized nonradiating pain, further corroborated a sacroiliac etiology of the symptoms. The lateral iliac wing compression test also demonstrated hyperflexibility of the bone. Straight leg and piriformis (flexion-adduction-internal-rotation) testing were negative.

This constellation of findings pointed to abnormal distribution of force through the pelvis from loss of iliac structural integrity and altered distribution of flexion force through the deformed adjacent bone causing iliac pain and abnormal SIJ and acetabular stress—rather than disease progression—as the underlying cause of pain. The treatment approach aimed primarily to stabilize the structural compromise from iliac bone thinning and focal erosions, including along the SIJ and regional to the acetabulum. Screw fixation along the long axis of the mass was chosen to better distribute force across the iliac cavity, as the size of the lesion would not allow for complete cement osteoplasty. The addition of a crossing screw at the upper third of the SIJ was chosen to address joint hyperflexion stress, including on the damaged iliac and sacral bone as well as normal tissues. The addition of cement was chosen, as the amount of bone remaining and the degree of osseous thinning would not allow for adequate stabilization with screws alone given lack of sufficient native bone for anchoring, particularly in the residual acetabulum, or to accommodate multiple pins.

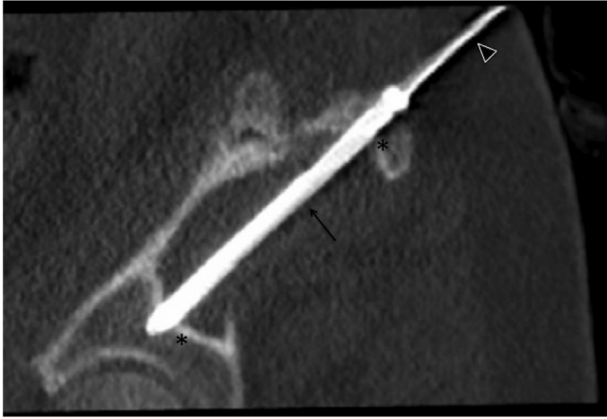

Fig. 2 – (Patient 1) Sagittal-oblique reformatted computed tomography image shows a 105 mm long \times 6.5 mm wide screw (arrow) placed over a Kirchner guide wire (arrowhead) through the long axis of the lytic cavity (*) embedded in the residual acetabulum without articular disruption despite scant native bone.

Cement osteoplasty was not added to the sacral alar portion of the SIJ as the screws would not traverse lytic masses in the sacral portions.

Multi-planar oblique reformatting of the pelvis was performed on a workstation (TeraRecon, Inc., Foster City, CA) to plan screw trajectory, screw sizes, and cement volume. The procedure was performed by an interventional radiologist with 8 years of experience under moderate sedation to allow patient feedback about pain intensity and location/radiation. All elements of the procedure were performed with computed tomography (CT) guidance, including 3-slice CT fluoroscopy. The patient was placed prone on a fixed gantry CT table (64-slice Somatom Definition AS, Siemens, Washington, DC) with a full surgical skin preparation and draping. Multiplanar reformatted imaging was used for intermittent image guidance (Basic CT Intervention Package/Adaptive 3D Intervention Suite, Siemens, Washington, DC). A multitool orthopedic drive and cannulated (over-the-wire) screw system was employed (DePuy Synthese, Johnson and Johnson, West Chester, PA). A 30 cm rigid 2.8 mm Kirchner wire was advanced percutaneously through a skin puncture and then the long-axis of the iliac mass (sagittal-oblique pelvic plane) with an over-the-wire cannulated hand drive, and the bone tract was widened with a cannulated drill bit. The distance to span the mass and anchor a screw was measured with a cannulated ruler and confirmed by measurements on the reformatted CT images.

A 105 mm \times 6.5 mm cannulated fully-threaded titanium screw was advanced over-the-wire through the iliac mass long-axis using the drive until near-final position. The screw was secured into final position using a cannulated manual screwdriver to enhance tactile sensation, with engagement of the head in the proximal cortex and embedding of the distal tip within preserved acetabular bone, sparing the articular surface (Fig. 2). A similar procedure was employed to place a wire in the orthogonal axial-oblique plane through the mass across the cephalad aspect of the SIJ. A 45 mm \times 6.5 mm fully-

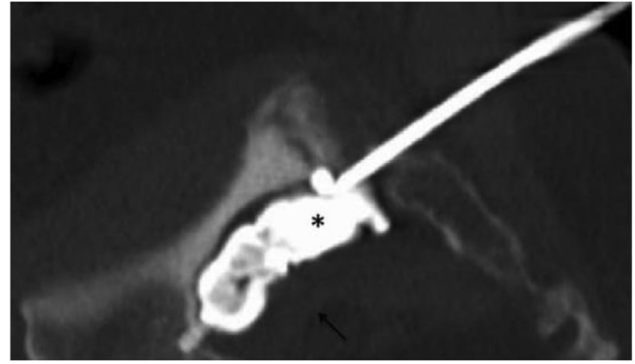

Fig. 3 – (Patient 1) Sagittal-oblique reformatted computed tomography image shows excellent filling of the lytic cavity with poly(methylmethacrylate) bone cement (*), surrounding the screw and not penetrating the capsule (arrow).

threaded titanium screw was placed with the head in the near cortex and the tip embedded in the sacral wing. Next, a 10-gauge Jamshidi needle (Medtronic, Minneapolis, MN) was advanced, parallel to the iliac screw, to the anteroinferior aspect of the lesion. Balloon osteoplasty with a high-pressure balloon (Medtronic, Medtronic, Minneapolis, MN) was performed along the length of the mass to augment cement packing. Approximately 15 mL of poly(methylmethacrylate) (PMMA) (Medtronic, Minneapolis, MN) were then injected into the lesion cavity until filling was visually near complete, the screws appeared well-supported, the patient noted discomfort suggesting periosteal stress/support, and there was no visual impending leak at the sites of cortical loss. CT images confirmed that there was no capsular leakage at the eroded cortices, with satisfactory filling of the mass and envelopment of the screws (Fig. 3). The relatively short length of the sacral wing traversed by the SIJ screw was accepted as the screw tip was not placed in a lytic lesion and the proximal screw portion was cemented in the iliac cavity (Fig. 4). Though SIJ screw placement through the sacral promontory and into the contralateral wing would confer stronger stabilization, the long-axis of the iliac mass and subsequent crossing-screw orientation were not conducive to placement of the SIJ screw into the sacral promontory.

At 1 week postprocedure, Patient 1 had halved her use of hydrocodone and reported a decrease in pain from 6/10 to 0/10 on the Visual Analog Scale for pain with self-reported “significant” improvement in ability to perform daily activity. By 1 month, her mobility was restored and her pain had resolved without the need for oral analgesics or complication (Fig. 5). At 17 months postprocedure, she remained fully ambulatory without recurrence of hip pain or osteoplasty complication on imaging, such as migration or fracture.

Case report 2

The second patient was a 61 year-old male at the time of presentation for pain palliation. He was experiencing

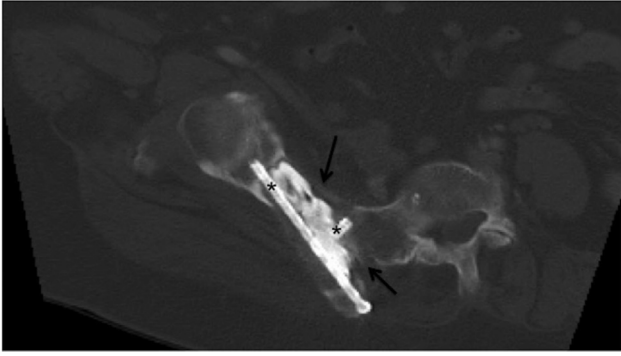


Fig. 4 – (Patient 1) Axial-oblique reformatted computed tomography image also shows the near-complete filling of the lytic cavity as well as the crossing screws (*) through the iliac mass and the sacro-iliac joint. Mass involvement of bone to the edge of the joint with areas of cortical thinning and frank disruption (arrows) on both sides of the joint are shown.

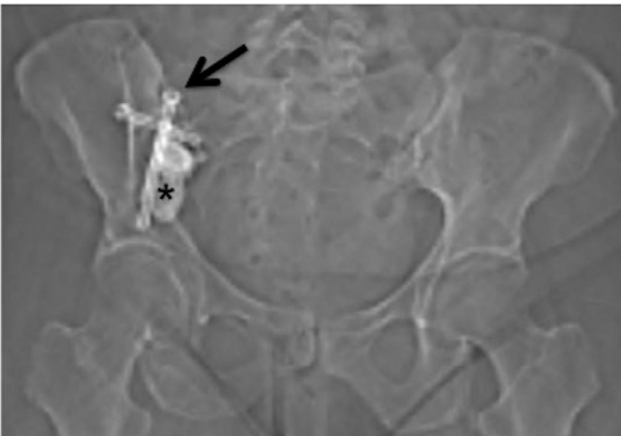

Fig. 5 – (Patient 1) Scout topogram image from computed tomography within the first month postprocedure, shows a limited over-view of the procedural implants (better depicted than on maximal intensity projection reformats or multiplanar computed tomography) with anterior projections of the iliac and sacral fixation screws (arrows) and cement osteoplasty (*) without complication.

persistent pain from a treated 14 cm plasmacytoma of the iliac wing at the SIJ, despite 2 months of complete serologic response to systemic chemotherapy for a recurrence of his multiple-myeloma, which had been treated over the past 5 years. The patient had been previously successfully treated surgically for other myeloma-related pain, including right hip hemiarthroplasty 9 months prior for pathologic femoral neck fracture; and left femoral shaft rod—femoral neck compression screw internal fixation for pathologic intertrochanteric fracture 8 months prior. His new hip pain coincided with detection of recurrent enhancing and hypermetabolic plasmacytoma in his right periacetabular cavity without fracture, in addition to other wide-spread malignant disease. However,

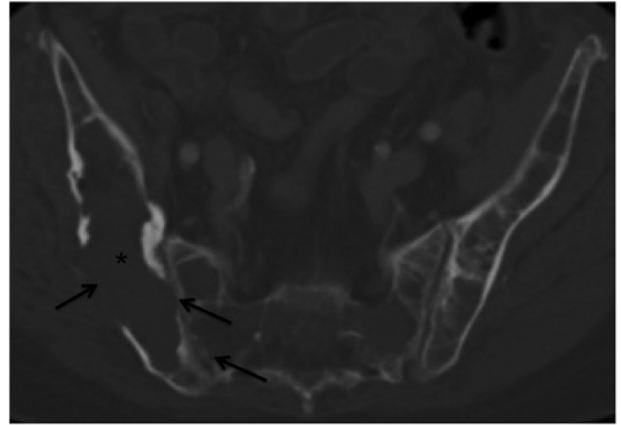


Fig. 6 – (Patient 2) Axial computed tomography image through the pelvis shows the upper portion of the right iliac deforming mass cavity (*) with lateral cortical destruction and multiple areas of medial near-complete cortical loss along the sacro-iliac joint in the ilium more than the sacral wing (arrows). A smaller right anterior sacral wing lytic cavity is also present.

similar to that of Patient 1, when he presented for pain palliation after treatment for his myeloma, the distorting residual lytic cavity with cortical thinning and deformation of the ilium and SIJ was no longer enhancing or hypermetabolic and had developed homogenous fluid-signal intensity on magnetic resonance imaging. Smaller less than 2 cm lytic cavities were also present in the sacral ala adjacent to the SIJ, which contributed to the abnormal bone along the SIJ (Fig. 6).

The physical exam findings in Patient 2 mirrored those in Patient 1, and lack of active malignant disease on imaging and serology suggested a similar structural pelvic compromise from this patient's periacetabular lesion, involving the iliac wing and sacrum. As such, a similar treatment approach was taken.

For Patient 2, the procedure was the same as that described above for Patient 1, using multiplanar CT-fluoroscopic imaging (Fig. 7), over the wire percutaneous screw placement and surrounding cement placement through bone trocars. However, a 120 mm × 6.5 mm cannulated fully threaded titanium screw was delivered across the long-axis of the iliac mass and a 50 mm × 6.5 mm screw was placed across the SIJ (Fig. 8). Additionally, 3 separate Jamshidi needles were advanced, parallel to the iliac screw, at multiple levels to distribute cement and provide broader reinforcement across the multilobulated mass. Approximately 60 mL of hydroxyapatite-PMMA bone cement were injected after balloon osteoplasty to the point of contact with proximal and distal portions of the screws, near complete filling of the largest lytic cavity (Fig. 9) and at least partial bridging contact with the smaller pockets of the mass cavity (Fig. 10).

The pain reported by Patient 2 improved immediately postprocedure from 6/10 to 3/10 on the Visual Analog Scale. At 1 week, he reported feeling “dramatically better” with completely restored ambulation, cessation of all opioid use, and no complication (Fig. 11). At most recent follow-up, 13 months




Fig. 7 – (Patient 2) Sagittal-oblique and axial-oblique reformatted computed tomography images using a CT intervention software package show the destructive iliac cavity (*) distorting the sacro-iliac joint with ground-glass change of the sacral ala (white arrow) as well as the planned trajectory and measurements overlays (black arrow).

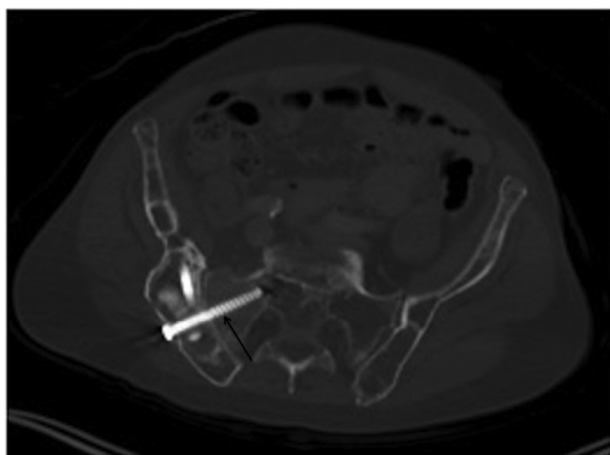


Fig. 8 – (Patient 2) Axial-oblique reformatted computed tomography image shows a 50 mm long x 6.5 mm wide screw (arrow) across the upper sacroiliac joint crossing the lytic cavity in the iliac bone and a ground glass portion in the sacral ala. Just over half the screw length is embedded in the more solid sacral wing, conferring better joint fixation stability than in patient 1.

postprocedure, his pain had completely resolved without the need for opioids or change in imaging appearance of the cement-screw fixation.

Discussion

Surgical management remains the standard of care for many osteolytic metastatic bone tumors, particularly for femoral

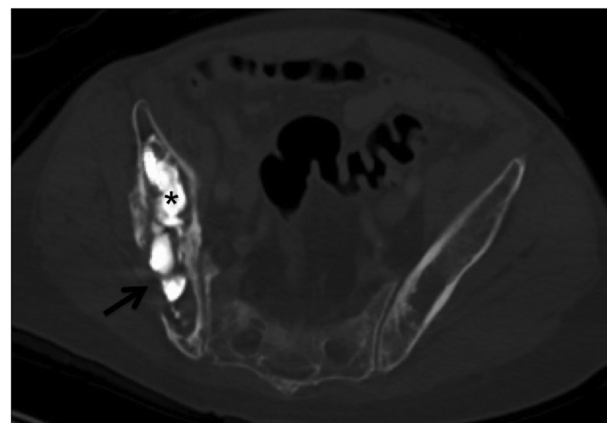


Fig. 9 – (Patient 2) Axial computed tomography image shows satisfactory bone cement (*) distribution throughout the lytic tumor cavity and one of the many areas of complete cortical erosion (arrow) without capsular leakage of cement.

lesions at risk for impending fracture, with reported rates of pain relief in up to 100% of studied patients [2,7]. Radiation therapy has been reported to successfully treat cancer-related bone pain with and without fracture in up to 80% of patients [2,3], though it is most efficacious in the setting of active disease without fracture and in lesions that do not significantly impair the structural integrity of the affected bone. Percutaneous surgical methods—such as curettage, pinning, and cement osteoplasty [2]; combination ablation and osteoplasty [2]; and PMMA packing [5] for periacetabular Harrington I lesions—have been reported to provide complete pain relief in 59%-100% of studied patients. For patients whose comorbidities result in unacceptably high surgical risk, often the case in

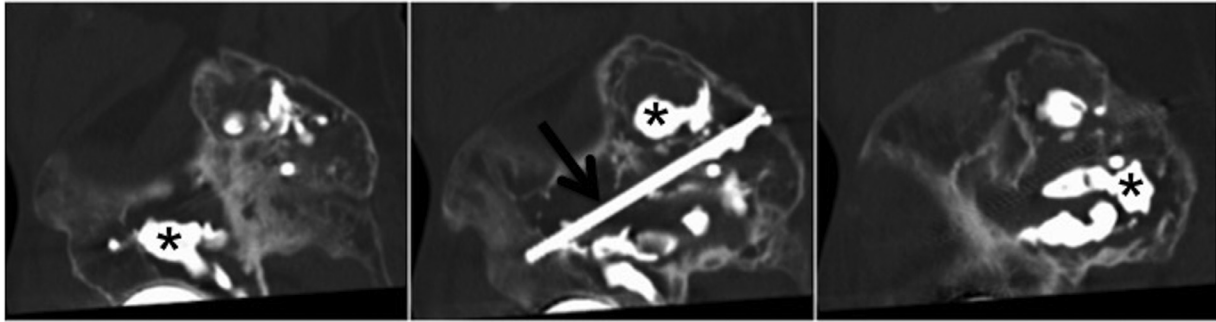


Fig. 10 – (Patient 2) Sagittal-oblique medial to lateral reformatted computed tomography series shows satisfactory bone cement (*) distribution throughout the lytic tumor cavity pockets and a 120 mm long x 6.5 mm wide screw (arrow) across the long axis of the mass, embedded in the residual acetabulum and the cortex.

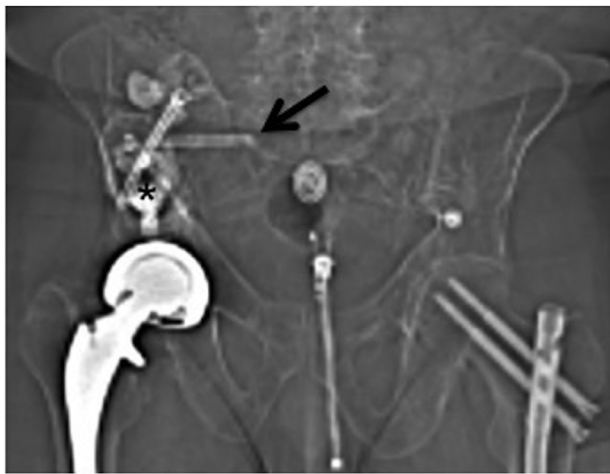

Fig. 11 – (Patient 2) Scout topogram image from computed tomography within the first month postprocedure, shows a limited over-view of the procedural implants with anterior projections of the iliac and sacral fixation screws (arrows) and cement osteoplasty (*) without complication.

cancer patients, less invasive interventions under moderate sedation are increasingly employed [2]. For instance, a series of reports by Kelekis et al demonstrates significant relief of symptoms caused by nonfractured lytic long-bone lesions measuring up to 6 cm after coaxial implantation of overlapping 22 gauge needles with cement osteoplasty [8]. Similarly, others have demonstrated significant improvements in performance status and pain scores using hand-cut 11-gauge modified trocars to augment cement osteoplasty in proximal femoral lytic metastases involving 2-4 cm of cortex [9].

While isolated benign iliac wing fractures are often managed conservatively [15], up to 87% symptomatic improvement and 100% functional improvement has been reported after screw fixation with PMMA instillation for various pathological pelvic fractures [6,7,10] similar to the benefit seen from screw fixation of benign fracture with SIJ dislocation [16] or SIJ instability [17]. By extension, even if not grossly fractured, large Enneking Zone II lesions may benefit from osteoplasty as they are likely subject to significant rotational, flexion, and

distraction forces across the residual compromised bone and SIJ, which can cause pain, possibly from ongoing microfracturing [5]. Inasmuch as large lesion size and irregularity can limit effective cement packing (for instance only up to 63% even despite prior ablation) [10], additional screw support may be vital to ensure adequate structural consolidation in larger lesions where notable volumes may be left unfilled and cement packing may be more irregular. Furthermore, given the relatively decreased tolerance of PMMA for rotational forces, compared to shearing and loading forces [8], and the variable torsional and bending strengths of smaller needles and pins, implementation of mechanically standardized orthopedic screws with cement reinforcement may provide more robust transfer of force to preserved bone.

Pusceddu et al reports significant pain relief from 27 painful bone metastases, 10 in the ilium, after osteoplasty using fenestrated screws through which cement was injected. The fenestrated screw technique in that study may have limited the injectable volume (with a maximum of 15 mL volume achieved) and only lesions with fractures or greater than 3 cm of cortical disruption were treated [7]. Another retrospective report of 48 patients with >5cm periacetabular masses, all treated with cryoablation followed by cement osteoplasty (median 15 mL of cement injected) mostly (85%) under general anesthesia, showed good short-term (<3 month) pain relief. However, because of the large size and invasion of the tumors, large portions of the tumor were left untreated [13]. Little has been reported regarding the suitability of such approaches in the nonfractured pelvis without ablation, particularly for larger (greater than 8 cm) post-treatment lesions within which mechanical reinforcement would presumably play a larger therapeutic and preventive role. In the current report, the patients experienced subjective complete pain relief and restoration of mobility: by 1 month in Patient 1 and 1 week in Patient 2.

Various classification systems have been used to determine the need for osteolytic mass stabilization, with and without fracture. Of note, patients with Enneking Zone II periacetabular lesions are often not treated with joint replacement [11], and the Harrington classification may not always be relevant in the consideration for predicted functional improvement and pain relief from intervention or even for risk of impending fracture, especially in nonsurgical candidates. For example, painful periacetabular masses successfully pal-

liated in a small series with thermal ablation and screw osteoplasty included Harrington classification I-III lesions, but none were treated with joint replacement [11]. The Mirels scoring system—based on lesion site, extent of cortical involvement, character, and degree of associated pain—is used for assessing pathological fracture risk in the long bones, with a score of 8 or more indicating prophylactic fixation [18], but it has also been loosely applied to periacetabular pelvic lesions not meeting the criteria for joint replacement [2,7]. Reporting of modified Harrington procedures often mentions “impending” fracture without always delineating criteria or justification for joint replacement [12], therefore it may also be useful to conceptualize these Ennking zone 2 lesions based on Mirels (long bone) criteria for impending fracture [7,10,16] when determining the need for nonsurgical percutaneous intervention.

The physical exam testing and imaging were compelling in the cases reported here to suggest SIJ and generalized iliac cortical instability. However, nerve block testing before definitive osteoplasty, for instance of the sacral lateral branches and superior gluteal nerve could help predict success of the intervention in equivocal cases, particularly the need for the crossing SIJ screw. Additionally, consideration may be given to cement injection into the sacral wings if the screw tips are placed in lytic sacral masses, particularly when it is difficult to cross the sacral promontory. This would have to be weighed against risk of sacral foraminal leaking from procedural or metastatic disruption.

Large painful nonfractured lytic pelvic lesions even without evidence of active tumor, with corroborating physical exam and imaging findings that support a component of osseous and SIJ deformability, particularly in the periacetabular region, may benefit from the screw and cement osteoplasty described above with lasting pain relief and functional improvement.

Conflicts of interest

The authors have no conflicts of interest to disclose.

REFERENCES

- [1] Birthi P, Sloan P. Interventional treatment of refractory cancer pain. *Cancer J* 2013;19:390–6 Sep-Oct. doi:10.1097/PPO.0b013e3182a631a2.
- [2] Muller DA, Capanna R. The surgical treatment of pelvic bone metastases. *Adv Orthop* 2015;2015:525363. doi:10.1155/2015/525363.
- [3] De Felice F, Piccioli A, Musio D, Tombolini V. The role of radiation therapy in bone metastases management. *Oncotarget* 2017;8:25691–9. doi:10.18632/oncotarget.14823.
- [4] National Comprehensive Cancer Network. *Adult Cancer Pain* (Version 2.2016). https://www.nccn.org/professionals/physician_gls/pdf/pain.pdf. [accessed 26.08.2018].
- [5] Anselmetti GC, Manca A, Ortega C, Grignani G, DeBernardi F, Regge D. Treatment of extraspinal painful bone metastases with percutaneous cementoplasty: a prospective study of 50 patients. *Cardiovasc Intervent Radiol* 2008;31:1165–73. doi:10.1007/s00270-008-9396-3.
- [6] Cazzato RL, Koch G, Buy X, Ramamurthy N, Tsoumakidou G, Caudrelier J, et al. Percutaneous image-guided screw fixation of bone lesions in cancer patients: double-centre analysis of outcomes including local evolution of the treated focus. *Cardiovasc Intervent Radiol* 2016;39:1455–63. doi:10.1007/s00270-016-1389-z.
- [7] Pusceddu C, Fancellu A, Ballicu N, Fele RM, Sotgia B, Melis L. CT-guided percutaneous screw fixation plus cementoplasty in the treatment of painful bone metastases with fractures or a high risk of pathological fracture. *Skeletal Radiol* 2017;46:539–45. doi:10.1007/s00256-017-2584-y.
- [8] Kelekis A, Filippiadis D, Anselmetti G, Broutzos E, Mavrogenis A, Papagelopoulos P, et al. Percutaneous augmented peripheral osteoplasty in long bones of oncologic patients for pain reduction and prevention of impending pathologic fracture: the rebar concept. *Cardiovasc Intervent Radiol* 2016;39:90–6. doi:10.1007/s00270-015-1138-8.
- [9] He C, Tian Q, Wu CG, Gu Y, Wang T, Li M. Feasibility of percutaneous cementoplasty combined with interventional internal fixation for impending pathologic fracture of the proximal femur. *J Vasc Interv Radiol* 2014;25:1112–17. doi:10.1016/j.jvir.2014.03.014.
- [10] Kurup NA, Morris JM, Schmitz GD, Atwell TD, Schmitz JJ, Rose PS, et al. Balloon-assisted osteoplasty of periacetabular tumors following percutaneous ablation. *J Vasc Radiol* 2015;26:588–94. doi:10.1016/j.jvir.2014.11.023.
- [11] Hartung MP, Tutton SM, Hohenwarter EJ, King DM, Neilson JC. Safety and efficacy of minimally invasive acetabular stabilization for periacetabular metastatic disease with thermal ablation and augmented screw fixation. *J Vasc Interv Radiol* 2016;27:682–8 May 1. doi:10.1016/j.jvir.2016.01.142.
- [12] Vielgut I, Sadoghi P, Gregori M, Kovar FM, Pichler K, Maurer-Ertle W, et al. The modified Harrington procedure for metastatic peri-acetabular bone destruction. *Int Orthop* 2013;37:1981–5.
- [13] Coupal TM, Pennycooke K, Mallinson PI, Ouellette HA, Clarkson PW, Hawley P, et al. The hopeless case? Palliative cryoablation and cementoplasty procedures for palliation of large pelvic bone metastases. *Pain Physician* 2017;20:E1053–61.
- [14] Vleeming A, Schuenke MD, Masi AT, Carreiro JE, Danneels L, Willard FH. The sacroiliac joint: an overview of its anatomy, function and potential clinical implications. *J Anat* 2012;221:537–67. doi:10.1111/j.1469-7580.2012.01564.x.
- [15] Abrassart S, Stern R, Peter R. Morbidity associated with isolated iliac wing fractures. *J Trauma* 2009;66:200–3. doi:10.1097/TA.0b013e31814695ba.
- [16] Starr AJ, Walter JC, Harris RW, Reinert CM, Jones AL. Percutaneous screw fixation of fractures of the iliac wing and fracture-dislocations of the sacro-iliac joint (OTA Types 61-B2.2 and 61-B2.3, or Young-Burgess “lateral compression type II” pelvic fractures). *J Orthop Trauma* 2002;16:116–23 Feb.
- [17] Bottlang M, Schemitsch CE, Nauth A, Routh M Jr, Egol KA, Cook GE, et al. Biomechanical concepts for fracture fixation. *J Orthop Trauma* 2015;29(Suppl 12):S28–33 Dec. doi:10.1097/BOT.0000000000000467.
- [18] Mirels H. Metastatic disease in long bones. A proposed scoring system for diagnosing impending pathological fracture. *Clin Orthop Rel Res* 1989;249:256–64.