

Oncology

Bladder melanosis with concurrent urothelial carcinoma

Susanna E. Yau^{*}, Eric J. Singer, Yue Sun, Michael H. Johnson^a Johns Hopkins School of Medicine, Baltimore, MD 21287, USA

ARTICLE INFO

Article history:

Received 13 July 2017

Received in revised form

2 September 2017

Accepted 7 September 2017

Available online 12 September 2017

1. Introduction

Bladder melanosis is a rare condition that has been incidentally discovered and reported fewer than 20 times. While independently benign, it has been reported with urothelial cell carcinoma and melanoma. The source of the melanocytes and cause of the melanosis is currently unknown; the presence of melanin pigment is pathognomonic for the disorder. Lesions appearing throughout the bladder are characterized by a brown or black hue and contain melanin pigment that disappear with bleaching. There are no specific symptoms or protocols for follow up. In this case report, we discuss a woman with bladder melanosis and concurrent urothelial carcinoma, found during a hematuria evaluation.

2. Case presentation

A 50-year-old African American woman with hypertension and a 20-year history of intermittent smoking presented with gross hematuria and urinary obstruction. Prior to this she reported right-flank pain, fatigue, hematuria, chest pain, fever and chills and was instructed to self-catheterize. A urine sample was read as negative for high grade urothelial carcinoma. An office cystoscopy was performed, which revealed an extensively pigmented bladder (Fig. 1) and a 3.3 × 2 × 2.8 cm intramural fungating mass arising from the right UVJ with associated obstructive effect and marked right hydronephrosis. Intraoperatively, there was no discernible border to the mass, and tissue was

resected for a pathologic diagnosis. In addition, melanotic lesions were seen on the inside of the bladder inconsistent with typical urinary cancer. The lesions were initially diagnosed as melanosis, lipofucinos, hemosiderosis or melanoma, all of which have similar symptoms. These lesions were scattered throughout her bladder, with sparing of the bladder dome. After discovering the lesions, special stains were performed; stains for melanin were positive and became negative with bleaching (Fig. 2), while a stain for iron was only focally positive. Multiple melanophages in the lamina propria were seen (Fig. 3).

Given the ongoing suspicion for malignancy, a repeat transurethral removal of bladder tumor (TURBT) was performed, revealing the presence of muscle invasive urothelial carcinoma with squamous features. Of note, no slides containing both urothelial carcinoma and melanosis were found. A right nephrostomy tube was placed to alleviate obstruction and she began neoadjuvant chemotherapy with planned cystectomy and urinary diversion.

3. Discussion

Melanosis of the urinary bladder is an extremely rare, benign condition. Common symptoms found throughout these cases include hematuria, incontinence, retention, dysuria and urinary frequency. Due to the finite number of cases reported, these symptoms must be linked to the presence of melanosis in more cases before they can concretely be considered the result of the condition. The condition occurs in both men and women between the ages of 43 and 90; all instances have been discovered incidentally. In the limited number of cases where race was reported, 6 patients were Caucasian, while 1 was African American.¹ Applying stains such as Fontana Masson, iron, Periodic Acid Schiff, bleach treatment, and immunohistochemical stains for S100 protein and HMB45 can aid in diagnosis. Melanin pigment that disappears when bleached is typically found within the black or brown lesions found throughout the bladder.²

There is no known connection between bladder melanosis and malignancy. Of the reported cases of bladder melanosis, three were reported in conjunction with urothelial carcinoma and three were associated with melanoma.¹ In some cases, melanosis preceded the tumors, while in others the two were synchronous. Due to the small number of reports and the lack of follow up, it cannot be determined whether melanosis is a premalignant lesion. Of the three

^{*} Corresponding author. Johns Hopkins Hospital, 600 N. Wolfe Street/Marburg 148, Baltimore, MD 21287, USA.

E-mail address: sey2@rice.edu (S.E. Yau).

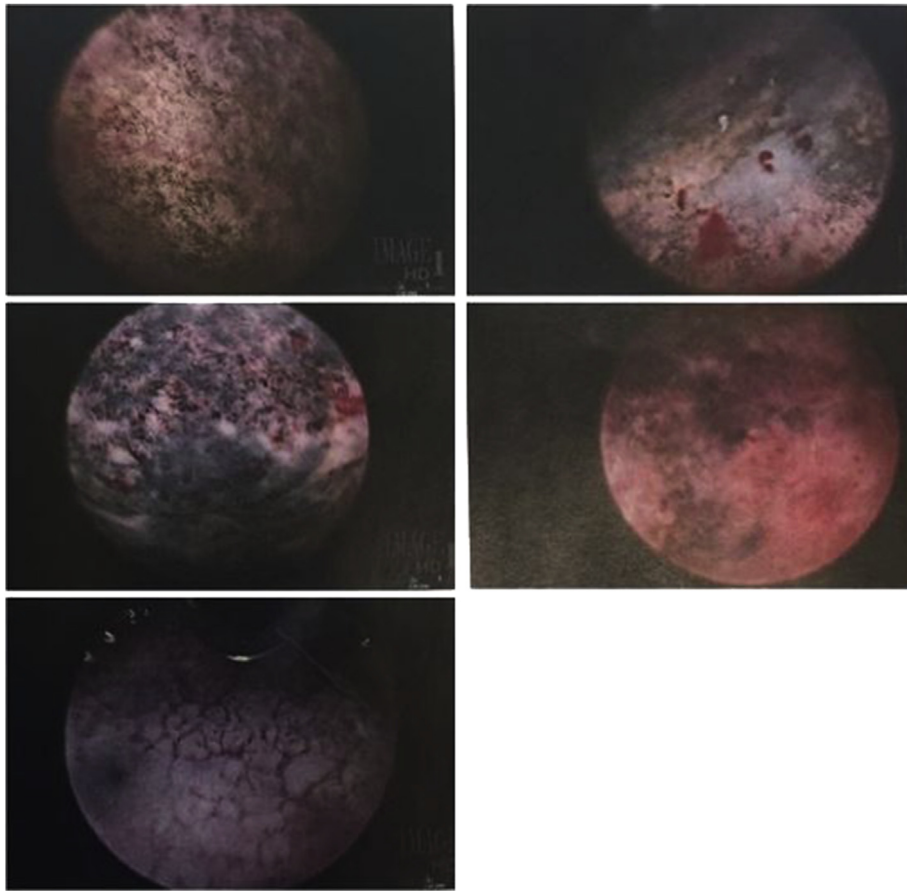


Fig. 1. Representative cystoscopic images of bladder melanosis.

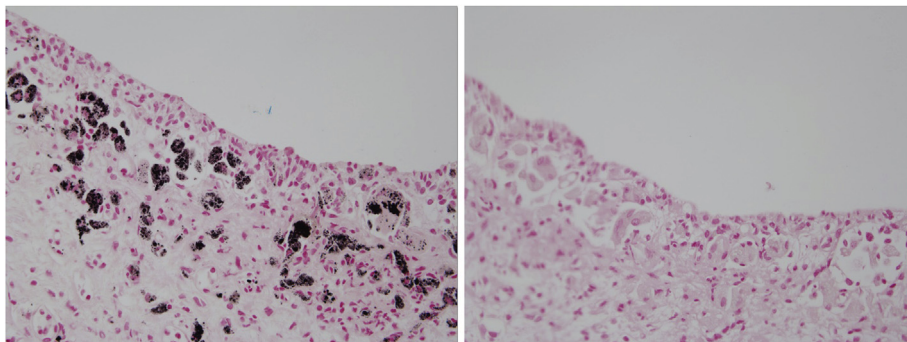


Fig. 2. Melanocytes before and after bleaching.

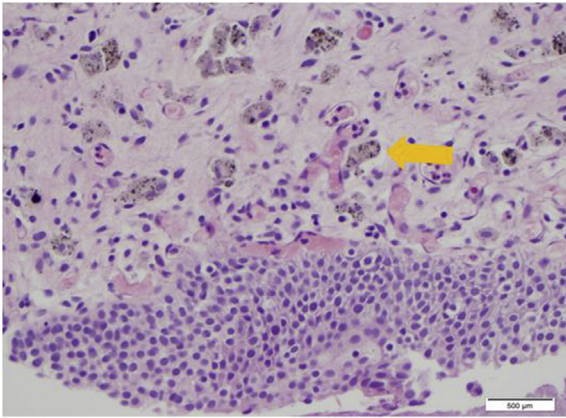


Fig. 3. Normal bladder histology with interspersed melanocytes (arrow).

melanoma patients presenting melanosis and melanoma, all of which were reported before 1992, two underwent cystectomy. Cases reporting melanosis alone lacked follow up, with only two of the eleven reporting post-diagnosis treatment. One patient was treated with two 6-week courses of Ciprofloxacin, and a cystoscopy after the first treatment showed normal mucosa, while another with urothelial carcinoma underwent Bacillus Calmette–Guerin therapy.¹ Many have suggested ongoing surveillance via cystoscopies and biopsies.³

Urothelial carcinoma, also known as transitional cell carcinoma

(TCC), is the most common type of bladder cancer and accounts for around 90% of all renal pelvic cancers. While the exact cause is unknown, smoking is the leading acquired risk factor. In this case, it is relevant to note that the patient had a 20-year intermittent smoking history, which heightened her risk for developing urothelial carcinoma. The standard-of-care treatment for muscle-invasive bladder cancer includes chemotherapy and radical extirpative surgery, while trimodality treatment (radical TURBT, chemotherapy, radiation therapy) is emerging as an alternative in patients who do not opt for cystectomy.

4. Conclusion

In this case report, we describe an African-American woman with hematuria and a CT scan concerning for bladder cancer, who was found to have concurrent bladder melanosis and urothelial carcinoma. While data surrounding this diagnosis is limited, treatment decision-making should mirror that of standard urothelial carcinoma, as there is no known connection between bladder melanosis and mortality.

References

1. Patel P, Kavanagh A, Bashir S Al, Bismar TA, Gotto G, Trpkov K. Urinary bladder melanosis associated with urothelial dysplasia and invasive urothelial carcinoma: a report of 2 cases. *Anal Quant Cytol Histol.* 2013;35:1–7.
2. Harikrishnan JA, Chilka S, Jain S. Urinary tract transitional cell carcinoma and melanosis of the bladder: a case report and review of the literature. *Ann R Coll Surg Engl.* 2012;94:152–154.
3. Talmon GA, Khan AU, Koerber RK, Johansson SL. Simple melanosis of the bladder: a rare entity. *Int J Surg Pathol.* 2010;18(6):547–549.