

## Oncology

## Primary prostatic squamous cell carcinoma

Kevin Hanna<sup>a, \*\*</sup>, Subodh M. Lele<sup>b</sup>, Grant McCormick<sup>a</sup>, Amber McMahon<sup>a</sup>, Brett Hill<sup>c</sup>,  
Shawna L. Boyle<sup>c, \*</sup>

<sup>a</sup> College of Medicine, University of Nebraska Medical Center, 985520 Nebraska Medical Center, Omaha, NE 68198-5520, United States

<sup>b</sup> Department of Pathology, University of Nebraska Medical Center, 983135 Nebraska Medical Center, Omaha, NE 68198-3135, United States

<sup>c</sup> Department of Surgery, Division of Urologic Surgery, University of Nebraska Medical Center, 984110 Nebraska Medical Center, Omaha, NE 68198-4110, United States

## ARTICLE INFO

## Keywords:

Non-small cell carcinoma  
Prostate cancer  
Squamous differentiation

## ABSTRACT

Primary prostate squamous cell malignancies are rare and very aggressive. A 65-year-old man presented to our institution with clinical and radiographic findings concerning for advanced prostatic malignancy. Surgical pathology of the tumor revealed poorly differentiated carcinoma with squamous differentiation, and histopathological markers were positive for markers of squamous differentiation negative for all urothelial and prostatic markers.

## Introduction

Most carcinomas of the prostate show characteristics of glandular histologic features. Non-adenocarcinoma histologic variants are associated with different treatment regimens and clinical outcomes.<sup>1</sup> Few cases of primary squamous cell carcinoma of the prostate have been reported in the literature, and optimal management is unknown.<sup>2</sup> Patients with this histologic variant typically present with advanced locally invasive or metastatic disease, and prognosis is poor.

## Case presentation

We present the case of a 65-year-old man who presented to his primary care physician with a 2-day history of acute right flank pain with nausea. Abdominal CT scan at that time revealed an irregular enlargement of the prostate near the apex of the gland with protrusion into the urinary bladder and involvement of the right ureterovesical junction. PSA at that time was noted to be 2.25 ng/mL. Prostate MRI revealed a mass centered in the region of the left seminal vesicle involving the bladder, prostate, and likely rectum, with a dilated right UVJ thought to likely be due to distal ureteral obstruction, concerning for advanced prostate malignancy (Fig. 1).

The patient underwent a cystoscopy with transrectal ultrasound-guided biopsy of his prostate. Cystoscopy revealed papillary fungating mass of the right and middle trigone, with the right ureteral orifices difficult to visualize secondary to the mass. Pathology from transrectal

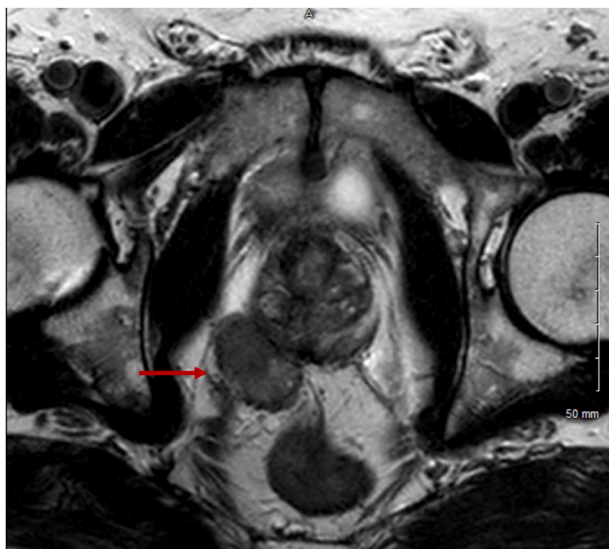
biopsy and biopsy of the mass revealed invasive, high-grade, non-small cell carcinoma with squamous differentiation. The patient subsequently underwent a radical cystoprostatectomy with ileal conduit and urinary diversion. Intraoperatively, the patient appeared to have a mass located between the prostate and the colon on the right side with some adherence to the levator muscle. On inspection of the sigmoid colon, there was a centimeter-sized area which appeared to be a tumor deposit. It was then determined that radical dissection would be necessary for adequate debulking. During anterior dissection of the tumor deposit, the tumor appeared to invade the levator muscle on the right side, and an extra-levator approach was necessary to achieve a negative margin. The patient was left with an end colostomy and a separate ileal conduit.

Surgical pathology revealed a 3.9 cm poorly differentiated carcinoma with squamous differentiation (Fig. 2, Fig. 3) on histology and immunohistochemical staining. The tumor expressed positive staining for markers of squamous differentiation (p40, p63 and CK5/6) while all prostatic markers (NKX3.1, ERG, PSA) and markers of urothelial differentiation (Gata3, CK7, CK20) were negative. Although very rare foci revealed small gland-like spaces, these were negative for prostatic markers. Therefore, the tumor was classified as a poorly differentiated squamous cell carcinoma. The tumor appeared to arise within the prostate and infiltrated the bladder wall, seminal vesicles (bilateral), and peri-prostatic soft tissue. Additionally, focal infiltration of the perirectal soft tissue was noted. 2/17 lymph nodes were involved with metastatic squamous carcinoma. Margins were negative. A discontinuous focus of carcinoma involved the intestinal wall of the sigmoid

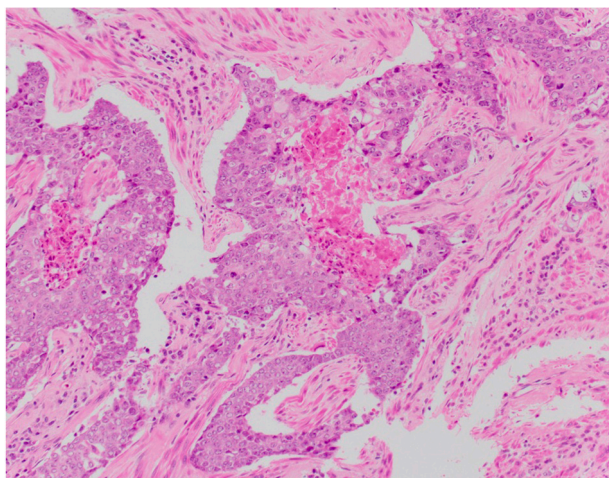
\* Corresponding author.

\*\* Corresponding author.

E-mail address: [shawna.boyle@unmc.edu](mailto:shawna.boyle@unmc.edu) (S.L. Boyle).



**Fig. 1.** Axial T2 MRI showing irregular, solid, enhancing mass, with large, exophytic component, cemented from this mass and protruding to the right and inferiorly, along the right prostate margin, measuring  $3 \times 1.9$  cm, indicated by red arrow. (For interpretation of the references to colour in this figure legend, the reader is referred to the Web version of this article.)



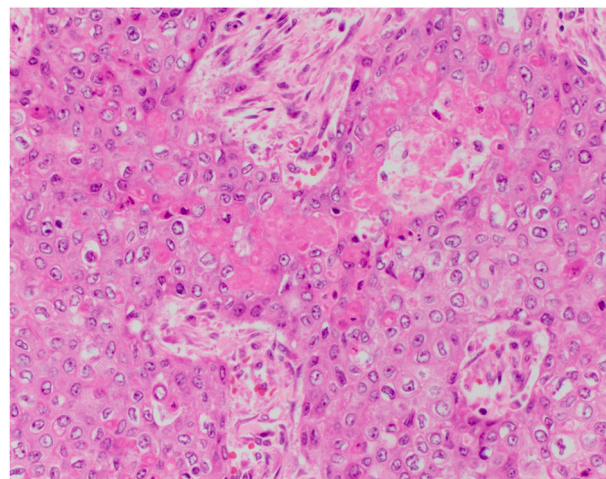
**Fig. 2.** Photomicrograph of the prostatic carcinoma showing squamous differentiation.

colon. The patient's tumor was staged as T4N1pM1.

The patient's case was reviewed at our institution's multidisciplinary tumor board with recommendation for a PET scan to evaluate for evidence of metastatic disease. Postoperative PET scan revealed an indeterminate lytic lesion in the left iliac wing, concerning for a focus of metastatic disease, with diffuse regional hypermetabolic activity, likely due to postoperative changes. The decision was made to pursue adjuvant chemotherapy, and the patient is currently undergoing four cycles of adjuvant docetaxel and carboplatin.

## Discussion

Squamous cell carcinoma of the prostate is a very rare malignancy, accounting for less than 1% of all prostate carcinomas.<sup>1</sup> Squamous differentiation can arise because of squamous metaplasia from adenocarcinoma secondary to endocrine therapy or radiation therapy. Our case is unique in that our patient's cancer arose *de novo* in the absence of past



**Fig. 3.** Photomicrograph of the prostatic carcinoma showing squamous differentiation.

urologic history. Fewer than 100 cases of primary squamous cell carcinoma of the prostate have been reported in the literature.<sup>2</sup> Because of their rarity, optimal treatment regimen is controversial. Proposed regimens include a combination of surgery, systemic chemotherapy, and radiation.

The average age at diagnosis is 68 years. The most common presenting symptoms are obstructive urinary symptoms including straining, weak stream, and hesitancy, as well as irritative urinary symptoms including dysuria. Squamous cell carcinoma of the prostate is very aggressive and commonly metastasizes early to the bone, liver, and lungs. Bone pain due to metastasis may arise. It is clinically difficult to distinguish squamous cell carcinoma of the prostate from prostate adenocarcinoma. One clinical feature that distinguishes the two is the presence of osteolytic bone metastasis in squamous cell carcinoma, versus osteoblastic bone metastasis in adenocarcinoma.<sup>3</sup> On the PET scan, our patient demonstrated lytic bony lesions, concerning for metastasis as opposed to osteoblastic lesions.

Diagnosis is based on histopathologic examination. One proposed set of criteria for the diagnosis of primary squamous cell carcinoma include 1) clearly malignant features including disorganized growth, anaplastic cellularity, and presence of local invasion 2) features of squamous differentiation including keratinization, squamous pearls, or intercellular bridging 3) absence of glandular components 4) no prior estrogen therapy 5) absence of squamous cell carcinoma in any other location.<sup>4</sup> Immunohistochemistry can support tissue diagnosis. Squamous cell differentiation loses reactivity for prostate specific antibodies including PSA, PSAP, PSMA, and P501S.<sup>4</sup> In our patient, squamous markers of (p40, p63 and CK5/6) were positive, and prostatic markers (PSA) were negative. Of note, surgical pathology did reveal small and rare foci of gland-like spaces. It is possible this could represent a unique glandular prostatic component in a tumor that is comprising squamous in differentiation.

Squamous cell carcinoma of the prostate has a worse prognosis than adenocarcinoma, with an average survival of 14 months after diagnosis.<sup>5</sup> Treatment options are typically limited. Of note, long term survival has been reported with combined chemotherapy and low-dose radiation with cisplatin and 5-fluorouracil.<sup>5</sup> The decision was made to pursue adjuvant docetaxel and carboplatin due to our patient's other medical comorbidities. Adjuvant radiation therapy was not pursued due to evidence of metastatic disease on surgical pathology and post-operative PET imaging.

## Conclusion

Squamous cell carcinoma of the prostate is an uncommon but highly aggressive neoplasm. Due to their rarity, treatment regimens are not well understood. Here, we display how the histological and immunohistochemical findings are helpful for making an accurate diagnosis of a squamous cell carcinoma.

## Funding

No funding was received for this work.

## Declaration of competing interest

K.F.H., S.M.L, G.M., A.M., B.H., S.L.B. have no financial conflicts of interest to declare.

## Acknowledgements

The authors thank the patient and his entire care team at the University of Nebraska Medical Center.

## References

1. Randolph TL, Amin MB, Ro JY, Ayala AG. Histologic variants of adenocarcinoma and other carcinomas of prostate: pathologic criteria and clinical significance. *Mod Pathol.* 1997;10:612–629.
2. Biswas T, Podder T, Lepera PA, Walker P. Primary squamous cell carcinoma of the prostate: a case report of a rare clinical entity. *Future Sci OA.* 2015;1:FSO18.
3. Sarma DP, Weilbaecher TG, Moon TD. Squamous cell carcinoma of prostate. *Urology.* 1991;37:260–262.
4. Arva NC, Das K. Diagnostic dilemmas of squamous differentiation in prostate carcinoma case report and review of the literature. *Diagn Pathol.* 2011;6:46.
5. Onoda M, Sugimoto R, Uesugi N, et al. Novel combination chemotherapy with radiotherapy for prostate squamous cell carcinoma. *Int Cancer Conf J.* 2017;6:25–28.