

Review Article

## Treatment Result of the Mucopexy-Recto Anal Lifting Method for Hemorrhoids in Comparison with Ligation and Excision, and Aluminum Potassium Sulfate and Tannic Acid Sclerotherapy

Takashi Sameshima<sup>1)</sup>, Kiyoshi Niwa<sup>1)</sup>, Tadaaki Eto<sup>1)</sup>, Kanako Sameshima<sup>1)</sup>, Shunji Ogata<sup>1)</sup>, Yuuko Yamamoto<sup>1)</sup>, Yoshiro Imamura<sup>2)</sup>, Nobuaki Nishimata<sup>2)</sup>, Asami Hirakawa<sup>2)</sup>, Hitomi Hamamoto<sup>2)</sup> and Yukinori Sameshima<sup>2)</sup>

1) Department of Surgery, Junaikai Medical Corporation Sameshima Hospital, Kagoshima, Japan

2) Department of Internal Medicine, Junaikai Medical Corporation Sameshima Hospital, Kagoshima, Japan

### Abstract

The outcomes of Mucopexy-Recto Anal Lifting (MuRAL) in hemorrhoid surgery were compared with ligation and excision (LE), and aluminum potassium sulfate and tannic acid sclerotherapy (ALTA). In this study, we conducted a 3-year follow-up study of MuRAL (380 cases) and compared it with LE (1417 cases) and ALTA (541 cases) performed at the same period. Operative time, mean hospital stay, postoperative pain, postoperative complications, and recurrence were compared and examined retrospectively. The mean operative time was the longest for MuRAL, followed by LE, and then ALTA at 29.1, 21.5, and 12.4 minutes, and the mean length of hospital stay was 6.2, 10.6, and 1.3, days, respectively. Based on the frequency of injectable analgesic use, postoperative pain was clearly milder in MuRAL and ALTA than in LE. The recurrence rates were 3.2% with MuRAL, 1.1% with LE, and 12.4% with ALTA. Early postoperative low-grade fever and bowel movement urgency were observed in all surgeries, but these were minor and did not pose a safety problem. LE is painful and requires prolonged hospitalization but is the most curative; ALTA is simple and can be performed as a day surgery but has a high recurrence rate. MuRAL was less painful than LE and had a lower recurrence rate than ALTA. In recent years, there have been various innovations in the surgical treatment of hemorrhoids, and choosing a technique that is appropriate for the condition of the hemorrhoid and patient's needs is necessary. MuRAL can be one of the options for hemorrhoid treatment as a "cure without cutting" method.

### Keywords

internal hemorrhoid surgery, Mucopexy-Recto Anal Lifting technique, HemoPex System (HPS)

J Anus Rectum Colon 2022; 6(3): 143-149

### Introduction

Recently, much attention has been paid for hemorrhoid surgery. In Japan, the advent of aluminum potassium sulfate and tannic acid sclerotherapy (ALTA) has revolutionized the surgical treatment of hemorrhoids, which until then was mainly performed using ligation and excision (LE). Depending on the pathogenesis of the hemorrhoid, treatment op-

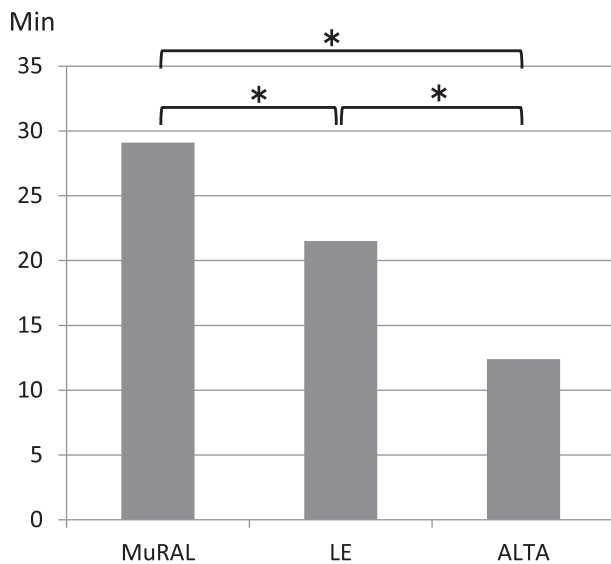
tions have expanded to include ALTA alone, a combination of LE and ALTA, and LE alone[1-9]. Furthermore, the Procedure for Prolapse and Hemorrhoid, Anal Cushion Lifting, and Mucopexy-Recto Anal Lifting (MuRAL) have been developed to elevate hemorrhoids by suturing the rectal mucosa[10-14].

In this study, we conducted a 3-year follow-up study of MuRAL and compared MuRAL with LE and ALTA alone

**Table 1.** Number of Cases and Average Age by Surgical Type and Gender.

Operation	Gender	n	Mean age
MuRAL	Male	167	60.2
	Female	213	67.8
LE	Male	850	63.7
	Female	567	64.2
ALTA	Male	318	58.2
	Female	223	55.3

There was a trend toward older age in MuRAL women and younger age in ALTA cases.



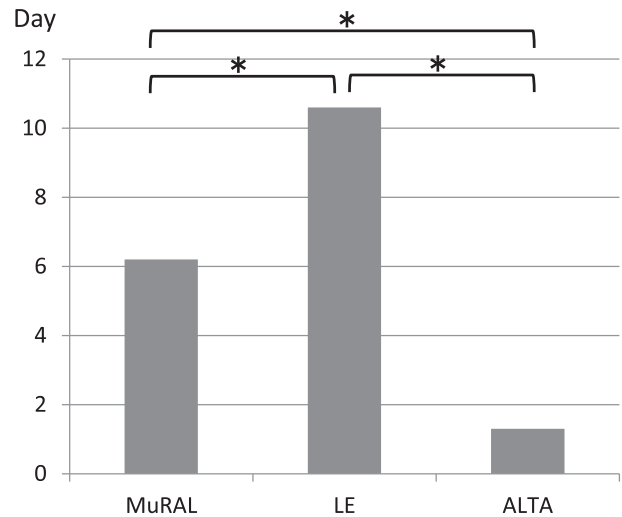
**Figure 1.** Operation time. MuRAL has a significantly longer operative time than the other surgeries. \*p < 0.05.

performed at the same period.

### Methods

A total of 2338 hemorrhoid surgery cases (MuRAL, 380; LE, 1417; and ALTA, 541) between January 2018 and December 2020 were included in this study. Operative time, mean hospital stay, postoperative pain, postoperative complications, and recurrence were compared and examined retrospectively. The degree of prolapse of hemorrhoids was determined using the Goligher classification (G-I, swelling of the anus during defecation without prolapse; G-II, prolapses outside the anus during defecation but returns spontaneously after defecation; G-III, prolapses during defecation and needs to be retracted by fingers; G-IV, always prolapses outside the anus and cannot be retracted)[15].

The t-test and  $\chi$ -square test were used for the significance test, and the difference was considered to be significant at p



**Figure 2.** Hospitalization. The hospital stay for LE is significantly longer than for the other surgeries. \*p < 0.05.

< 0.05.

This clinical research was reviewed and approved by the Institutional Review Board of the Sameshima Hospital (approval number: 20171201).

### Results

MuRAL consisted of 167 males (age: 60.2 ± 13.4 years) and 213 females (age: 67.8 ± 16.4 years); LE consisted of 850 males (age: 63.7 ± 18.2 years) and 567 females (age: 64.2 ± 9.8 years); ALTA consisted of 318 males (age: 58.2 ± 10.7 years) and 223 females (age: 55.3 ± 8.3 years).

There was a trend toward older age in MuRAL women and younger age in ALTA cases (Table 1).

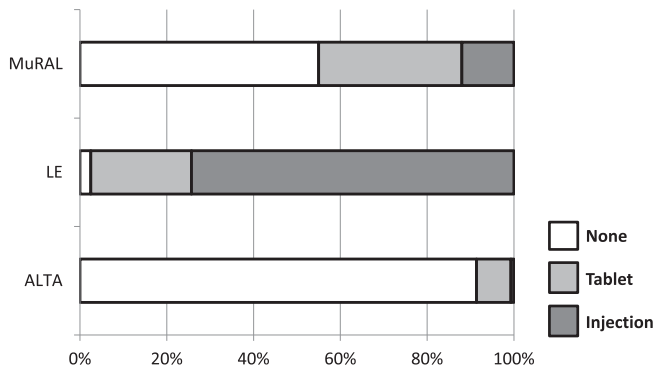
MuRAL was performed in 380 of the 2661 cases (14.3%), including 323 cases of combined LE and ALTA performed in the same period.

The mean operative time was 29.1 ± 9.2, 21.5 ± 7.4, and 12.4 ± 5.2 minutes for MuRAL, LE, and ALTA, respectively (Figure 1).

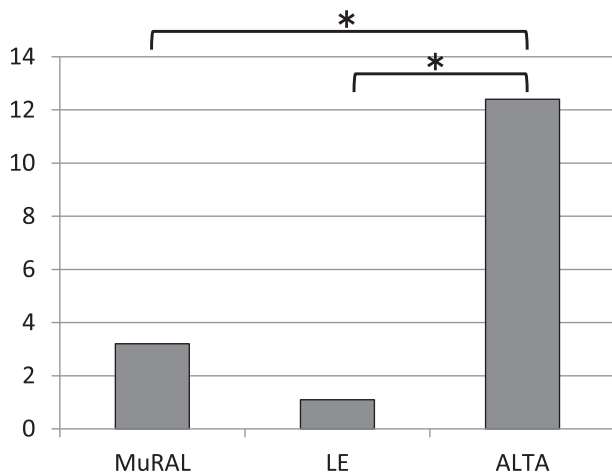
The mean hospital stay was 6.2 ± 3.3, 10.6 ± 2.6, and 1.3 ± 1.8 days, for MuRAL, LE, and ALTA, respectively (Figure 2).

For postoperative pain, analgesic treatment on the day of surgery was compared. Overall, 209 (55%) patients received no treatment, 125 (33%) received only oral medication, and 46 (12%) received injections for MuRAL; 35 (2.5%) patients received no treatment, 329 (23.2%) received only oral medication, and 1053 (74.3%) received injections for LE; and 494 patients (91.3%) received no treatment, 43 (7.9%) received only oral medication, and 4 (0.7%) received injections for ALTA (Figure 3).

Other events during the first few days after surgery in-



**Figure 3.** Pain management on the surgery day. Either unnecessary or limited to oral medication in 88% of MuRAL and 99.3% of ALTA patients, compared with 25.7% of LE patients. MuRAL and ALTA have a clear advantage in postoperative pain.  $\chi$ -squared test: MuRAL, ALTA vs LE.  $p < 0.05$ .

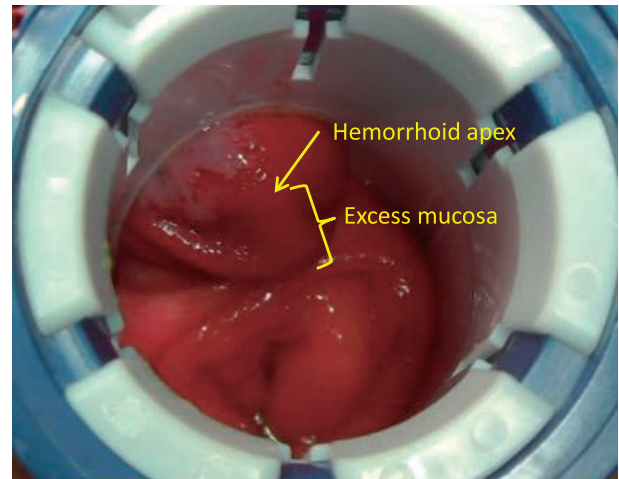


**Figure 4.** Recurrence rate. During the maximum observation period of 3 years. ALTA had a significantly higher recurrence rate than the other surgeries.  $*p < 0.05$ .

cluded fever of 37.5°C or higher in 45 patients (11.8%) with MuRAL, 129 patients (9.1%) with LE, and 26 patients (4.8%) with ALTA. Postoperative bleeding requiring hemostasis under anesthesia was observed in 3 (0.8%) patients in MuRAL, 9 (0.6%) patients in LE, and none in ALTA.

As for abnormalities in defecation, urgency to defecate was observed in 34 patients (8.9%) in MuRAL, 71 patients (5%) in LE, and 65 patients (12%) in ALTA. Difficulty in defecation due to anal pain was observed in 103 (7.3%) patients with LE, but not in MuRAL and ALTA.

During the maximum observation period of 3 years, re-prolapse was observed in 12 patients (3.2%) with MuRAL, 16 patients (1.1%) with LE, and 67 patients (12.4%) with ALTA (Figure 4).



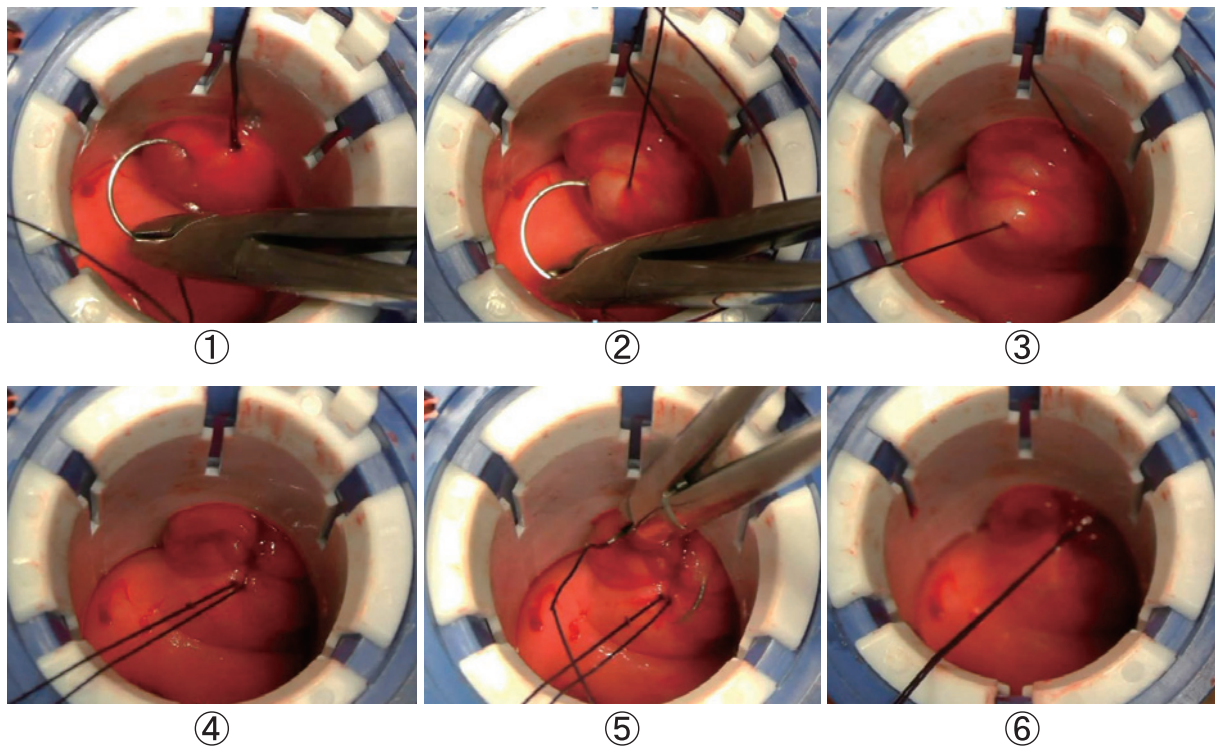
**Figure 5.** Lithotripsy position. Direct visualization of a G-III internal hemorrhoid at 11 o'clock. Manipulation begins slightly anally at the apex of the hemorrhoid. Image from Sameshima et al. [Result of the Mucopexy-Recto Anal Lifting Method for prolapsed internal hemorrhoids] JACP 2021 Jun 4: 57-62. Reprint permission was granted.

### Operation Technique

The technique of MuRAL is described below. Spinal anesthesia was used as in usual anorectal surgery, and the surgical position is lithotomy. As the surgery progresses, the patient may complain of lower abdominal pressure and traction pain as the rectum is elevated, so intravenous anesthesia is added as appropriate.

First, with the hemorrhoid to be prolapsed returned into the anus, the special surgical device, the HemorPex System (HPS), is inserted, and the handle is fixed in the 12 o'clock position. A 2 × 3 cm slit is made in the suturing area, and turning the rotor in the hand locks the slit in the direction of the surgical operation. The surgery should be started under direct vision of the redundant rectal mucosa on the hemorrhoidal side (Figure 5). Using a No. 0 absorbable thread with a folded needle, a series of longitudinal stitches are carried from the anal side to the oral side. The length of the stitches should be 2-4 mm, but not more than 5 mm. The width of each stitch should not be too wide, and the submucosa should be applied firmly. After 5-6 stitches, the suture can be closed, and the hemorrhoids and rectal mucosa elevated 2-3 cm approximately (Figure 6). Six surgical operations are performed starting at 11 o'clock in the order of 1, 9, 3, 7, and 5 o'clock to raise and fix the entire fragile rectal mucosa, submucosa, and prolapsed hemorrhoids. In other words, it is a technique to cure prolapse by suturing and elevating at the same time without resection[11-13].

On postoperative day 10, endoscopic findings show ulceration from mucosal necrosis due to ligature strangulation. This scarring and fibrosis fix the elevated mucosa. At 6



**Figure 6.** MuRAL surgical technique.

- ① The apex of the hemorrhoid is ligated slightly to the anus, and the supporting thread is used to start the needle from the anus to the mouth.
- ② The length of the needle should be 2-4 mm, but not more than 5 mm. The width of the needle is small, and it is applied to the submucosa.
- ③~④ After 5-6 stitches, the sutures are ligated, and sutures can be sutured about 2-3 cm per site.
- ⑤~⑥ The needle at the ligation site is folded back to the anal side from the starting point, and the needle is carried and ligated to finish the operation.

Image from Sameshima et al. [Result of the Mucopexy-Recto Anal Lifting Method for prolapsed internal hemorrhoids] JACP 2021 Jun 4: 57-62. Reprint permission was granted.

months postoperatively, a cystic scar of the mucosa can be seen (Figure 7).

LE is the gold standard for hemorrhoid surgery[1,2]. The hemorrhoid is dissected from the external and internal sphincters, and the root of the hemorrhoid is resected 2-3 cm from the upper pole of the hemorrhoid. The author uses 2-3 sutures from the root of the hemorrhoid to the dentate line and leaves the surface of the anal canal to the outside of the anus open for drainage.

The mechanism of ALTA therapy is a strong inflammatory response to potassium aluminum sulfate, which induces inflammation within the hemorrhoid. During this process, tannic acid inhibits the excessive inflammatory response and prevents tissue damage. Acute inflammation of the hemorrhoidal interstitium increases vascular permeability and rapidly decreases and blocks blood flow to the hemorrhoids from concentrating. In the process of repairing inflammation, granulation and fibrosis occur, resulting in the hardening, retraction, and adhesion of hemorrhoids, thereby elimi-

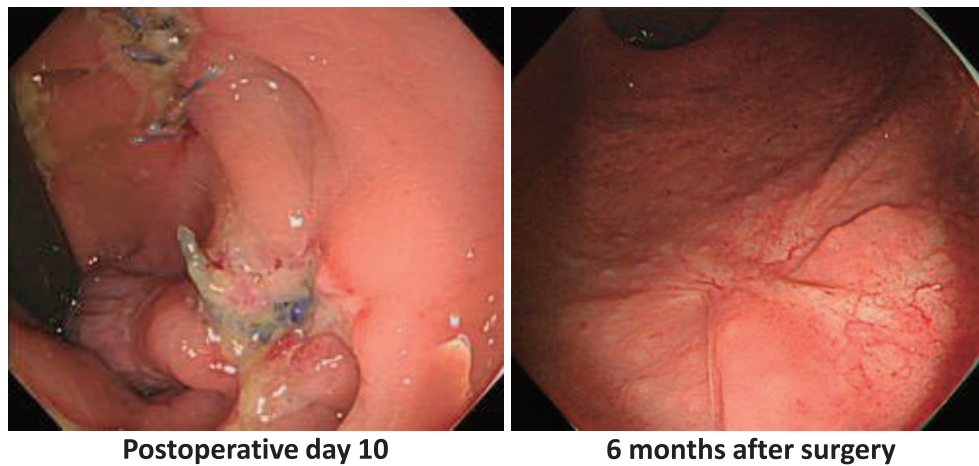
nating hemorrhoid prolapse[3-7].

ALTA is injected at four sites for one hemorrhoid. The following are the locations of the injection and the amount that should be injected:

1. Submucosa of the upper pole of the hemorrhoid, 3-4 mL;
2. Central submucosa of the hemorrhoid, 2 to 4 mL;
3. Intrinsic mucosa of the central hemorrhoid, 1 to 2 mL; and
4. Submucosa of the lower pole of the hemorrhoid, 3 to 4 mL.

### Indications for Surgery

LE can be performed for all hemorrhoids. ALTA is suitable for relatively mild conditions of G-II to G-III[1]. MuRAL is best for circumferential G-II to G-III hemorrhoids without an external hemorrhoidal component or internal hemorrhoids with rectal mucosal prolapse because of the



**Figure 7.** Colonoscopy findings at the surgical wound site.

On postoperative day 10, mucosal necrosis due to ligature strangulation, surrounding inflammation, and ulceration were observed.

Healing scarring of the ulcer is seen at 6 months postoperatively.

Image from Sameshima et al. [Result of the Mucopexy-Recto Anal Lifting Method for prolapsed internal hemorrhoids] JACP 2021 Jun 4: 57-62. Reprint permission was granted.

rectal mucosal elevation for hemorrhoid lifting. G-IV hemorrhoids are not recommended due to the difficulty of complete lifting[11-13].

### Considerations

MuRAL was invented by Claudio Pagano in Italy in 2013[11]. The concept is to ligate and suture the excess rectal mucosa and submucosa longitudinally with continuous sutures while the hemorrhoid is returned into the rectum. Pagano et al. indicated up to G-IV, but I have the impression that the standard technique is not enough to suspend the hemorrhoid[12]. The size of the HPS is designed for Western patients and is not suitable for Japanese patients with a small body size, which may result in insufficient lifting because the surgical operation is performed slightly more orally than the optimal site.

The surgical technique is relatively easy. The starting point of the suture is slightly lateral to the apex of the hemorrhoid, making it easy to identify. However, the end point is considered to be the border between the hemorrhoid and the normal rectal mucosa and is difficult to identify. Pagano et al. stated that surgical manipulation is performed only on the excess mucosa at the oral side of the hemorrhoid, which is elevated at the time of the insertion of the HPS[11]. When viewing hemorrhoids with HPS, the author uses the border between the slightly reddish mucosal tone of the hemorrhoidal area and the rectal mucosal tone at the oral side of the hemorrhoid as an indicator. As a result, 4-6 needle strokes are needed to get there[12].

The mean operative times for MuRAL, LE, and ALTA were  $29.1 \pm 9.2$ ,  $21.5 \pm 7.4$ , and  $12.4 \pm 5.2$  minutes. The

mean operative time for MuRAL was initially over 40 minutes, but after 30 cases, it became around 25 minutes. We believe that the time reduction was due to the fact that we became able to judge the procedure and the starting and ending points of the needle[12,13].

The average lengths of hospital stay for MuRAL, LE, and ALTA were  $6.2 \pm 3.3$ ,  $10.6 \pm 2.6$ , and  $1.3 \pm 1.8$  days, respectively (Figure 3). MuRAL averaged 6.2 days, which is slightly longer than the other reports. Initially, it took 10 days for LE. After 50 cases, it shortened to less than 7 days, and recently, it has become less than 5 days[12]. Pagano et al. reported that most of the procedures were performed as a day case or 3-day hospitalization at the most[11] since there was less pain and less complications in the early postoperative period.

Postoperative pain is minimal because the surgical wound does not extend into the anal canal. The management for postoperative pain at our hospital consists of (1) oral NSAIDs, (2) intravenous flurbiprofen axetil (Lopion<sup>®</sup>), (3) intramuscular pentazocine (Pentadine<sup>®</sup>), and (4) intramuscular buprenorphine hydrochloride (Repetane<sup>®</sup>) when the patient complains, in that order. As for analgesic treatment on the day of surgery, 88% of patients in MuRAL did not need analgesics or took only oral medication, whereas 25.7% of patients in LE and 99.3% of patients in ALTA did. Xu et al. analyzed that the postoperative pain of LE is stronger than the other techniques[16], and MuRAL and ALTA have a clear advantage in postoperative pain.

In addition, MuRAL pain was characterized by traction pain in the lower abdomen, which was more common in females (41 of 167 (24%) males and 96 of 213 (45%) females). Shimojima et al. also reported similar results[13].

The cause of the pain is unknown, but it is thought to be caused by the traction on the peritoneum due to excessive suturing of the rectal mucosa. The pain disappeared the day after the surgery.

Among other events, fever of 37.5°C or higher was observed in 45 patients (11.8%) with MuRAL, 129 patients (9.1%) with LE, and 26 patients (4.8%) with ALTA. Bacterial infection of the surgical wound and fever caused by the healing process of the wound are possible causes, but the obvious cause is unknown. However, these events were not clinically problematic in the postoperative course.

Postoperative bleeding requiring hemostasis under anesthesia occurred in three patients (0.8%) with MuRAL, nine patients (0.6%) with LE, and none with ALTA. The safety of both techniques is high.

In terms of defecation abnormalities, urgency to defecate was observed in 21 of 167 (12.5%) males and 13 of 213 (6.1%) females with MuRAL, 42 of 850 (4.9%) males and 29 of 567 (5.1%) females with LE, 47 of 318 (14.8%) males and 18 of 223 (8.1%) females with ALTA, with a relatively high incidence in males with MuRAL and ALTA. These symptoms disappeared within 1 week after surgery. It was thought to be due to the temporary restriction of rectal distension. Difficulty in defecation due to anal pain was observed in 103 patients (7.3%) with LE, but not with MuRAL or ALTA.

During the maximum observation period of 3 years, re-prolapse was observed in 12 patients (3.2%) with MuRAL, 16 patients (1.1%) with LE, and 67 patients (12.4%) with ALTA. According to various authors, the rates were 5%-16.7% for MuRAL, 0%-2.5% for LE, and 10%-35% for ALTA, depending on the observation period[3,7,17,18].

We believe that MuRAL and ALTA can reduce the recurrence rate by not overestimating and strictly controlling the surgical indications.

In cases of recurrence, the technique should be selected according to the situation. However, re-treatment of the oral side of the hemorrhoid is an additional procedure to an already scarred area and is not expected to be sufficiently effective, so radical resection with LE is considered appropriate.

## Summary

The results of MuRAL were compared with those of LE and ALTA performed at the same period. MuRAL is associated with less postoperative pain, shorter hospitalization, and similar curative results than LE; LE is associated with more postoperative pain and longer hospitalization but better curative results; ALTA is simple and can be performed as a day case but has a higher recurrence rate.

Currently, there are a number of innovations in the surgical treatment of hemorrhoids. MuRAL can be one of the op-

tions for hemorrhoid treatment as it is a “cure without cutting” method.

## Conflicts of Interest

There are no conflicts of interest.

## References

1. Clinical Practice guidelines for anorectal disease (hemorrhoids, anal fistulas, anal fissures) and rectal prolapses. 2020; 16-24.
2. Tsuji N. [Effectiveness of haemorrhoid ligation and excision and ALTA for haemorrhoids]. *Surg Ther.* 2008; 99: 301-4. Japanese.
3. Hachiro Y, Kunimoto M, Abe T, et al. Aluminum potassium sulfate and tannic acid (ALTA) injection as the mainstay of treatment for internal hemorrhoids. *Surg Today.* 2011 Jun; 41(6): 806-9.
4. Hachiro Y, Abe T, Kunimoto M. [ALTA induration therapy for anal diseases- after experiencing 1000 cases]. *J Jpn Soc Coloproctol.* 2008; 61: 216-20. Japanese.
5. Abe T, Hachiro Y, Kunimoto M. [Comparison between ALTA therapy and ligation and excision for inner haemorrhoids]. *J Jpn Soc Coloproctol.* 2007; 60: 213-7. Japanese.
6. Tokunaga Y, Sasaki H. Impact of less invasive treatments including sclerotherapy with a new agent and hemorrhoidopexy for prolapsing internal hemorrhoids. *Int Surg.* 2013 Jul-Sep; 98(3): 210-3.
7. Ohara M. [Clinical outcomes in 4,126 patients who underwent aluminum potassium sulfate and tannic acid (ALTA) therapy]. *J Jpn Soc Coloproctol.* 2014 Feb; 67: 80-5. Japanese.
8. Iwadore J. [Ligation and excision for hemorrhoids: aluminum potassium sulfate and tannic Acid (ALTA) combination therapy]. *Surgery.* 2011 Sep; 73(9): 919-25. Japanese.
9. Uchida M, Yamamoto Y, Satou T. [Future of position and indications in ALTA therapy alone for internal hemorrhoids]. *J Jpn Soc Coloproctol.* 2015; 68: 523-9. Japanese.
10. Iachino C, Saccone M, Milone L, et al. Hemor-Pex system: result of the first 1000 cases. *Chirurgia.* 2009 Oct; 22(5): 217-9.
11. Pagano C, Vergani C, Invernizzi C, et al. Mucopexy-recto anal lifting: a standardized minimally invasive method of managing symptomatic hemorrhoids, with an innovative suturing technique and the HemorPex System®. *Minerva Chir.* 2018 Oct; 73(5): 469-74.
12. Sameshima T, Niwa K, Eto T, et al. [Result of the Mucopexy-Recto Anal Lifting method for prolapsed internal hemorrhoids]. *JACP.* 2021 Jun 4: 57-62.
13. Shimojima Y, Matsushima M, Matsushima S, et al. [Evaluation of Mucopexy-Recto Anal Lifting (MuRAL): a new method for treating hemorrhoids]. *J Anus Rectum Colon.* 2020 Apr; 4(2): 51-8.
14. Ishiyama G, Nishidate T, Ishiyama Y, et al. Anal cushion lifting method is a novel radical management strategy for hemorrhoids that does not involve excision or cause postoperative anal complications. *World J Gastrointest Surg.* 2015 Oct; 7(10): 273-8.
15. Goligher JC. *Surgery of the anus, rectum and colon*, 5th ed. London: Baillière Tindall; 1984. 101 p.
16. Xu L, Chen H, Lin G, et al. Ligation versus Ferguson hemorrhoidectomy in the treatment of hemorrhoids: a meta-analysis of randomized control trials. *Surg Laparosc Endosc Percutan Tech.* 2015 Apr; 25(2): 106-10.
17. Elmer SE, Nygren JO, Lenander CE. A randomized trial of transanal hemorrhoidal dearterialization with anopexy compared with open hemorrhoidectomy in the treatment of hemorrhoids. *Dis Colon Rectum.* 2013 Apr; 56(4): 484-90.

- 18.** Denoya PI, Fakhoury M, Chang K, et al. Dearterialization with mucopexy versus haemorrhoidectomy for grade III or IV haemorrhoids: short-term results of a double-blind randomized controlled trial. *Colorectal Dis.* 2013 May; 15(10): 1281-8.

Journal of the Anus, Rectum and Colon is an Open Access journal distributed under the Creative Commons Attribution-NonCommercial-NoDerivatives 4.0 International License. To view the details of this license, please visit (<https://creativecommons.org/licenses/by-nc-nd/4.0/>).