

Transplantation of iliac bone flaps pedicled with sartorius muscular fascia around superficial circumflex iliac vessels in the treatment of osteonecrosis of the femoral head

GUOFENG CUI^{1*}, RONG WEI^{2*}, CHUNYING HOU¹ and ZHENGANG BI¹

¹Department of Orthopedics, The First Affiliated Hospital of Harbin Medical University, Harbin, Heilongjiang 150001;

²Department of Orthopedics, Luoyang Central Hospital Affiliated to Zhengzhou University, Luoyang, Henan 471009, P.R. China

Received June 17, 2014; Accepted March 10, 2015

DOI: 10.3892/etm.2016.3202

Abstract. The aim of this study was to evaluate the efficacy and clinical application of iliac bone flaps pedicled with sartorius muscular fascia around superficial circumflex iliac vessels for the treatment of Association for Research on Osseous Circulation (ARCO) stage II-III osteonecrosis of the femoral head (ONFH) in young adults. In total, 35 patients with ONFH at ARCO stage II-III were treated with iliac bone flaps pedicled with sartorius muscular fascia around superficial circumflex iliac vessels. Patients were classified according to etiological factors and ARCO stages. Postoperative clinical assessment was accomplished with Harris hip scores (HHS), and ARCO stage change was evaluated with imaging. All 35 patients completed the follow-up. The HHS results indicated that hip function was improved significantly from the preoperative status of 56.53 ± 7.66 points to the postoperative status of 87.49 ± 5.89 points ($P < 0.0001$). Postoperative imaging displayed apparent osteogenesis and satisfactory structural remodeling in 32 patients, presenting no staging progress. Three patients exhibited mild collapse (< 2 mm) compared with preoperative collapse. No patients developed osteoarthritis or required total hip arthroplasty. The clinical success rate was 91.43%. Iliac bone flaps pedicled with sartorius muscular fascia around superficial circumflex iliac vessels is a feasible means for treating ARCO stage II-III ONFH in young adults, who have abundant blood circulation, good osteogenesis and

function of the hip. It is also an effective means for retaining the femoral head.

Introduction

Osteonecrosis of the femoral head (ONFH), also known as avascular necrosis of the femoral head (AVNFH), is a common, intractable disease. It is a multifactorial disease that occurs at any age and presents clear clinical symptoms (1). The etiology of the disease, however, remains unclear, although common contributors are long-term use of hormones, chronic alcoholism and smoking (2). Approximately 80% of untreated patients present with femoral head collapse (3). As the incidence of ONFH in adults is rising, early diagnostic methods and related treatments are increasingly being developed. Total hip replacement is being performed more often in young patients, for instance, and should be approached with great care. Maintaining the integrity of the femoral head is considered a particularly important topic. Another significant consideration is how to prevent collapse of a necrotic femoral head and thus delay joint replacement. Transplantation of vascularized bone flap grafts not only provides mechanical support and prevents collapse of the femoral head but also offers a new source of blood supply, thereby improving blood circulation of the necrotic femoral head (2). There are numerous methods of using vascularized bone flap grafts, but the use of iliac bone flaps pedicled with sartorius muscular fascia around superficial circumflex iliac vessels is rarely reported. This study aimed to evaluate the efficacy of iliac bone flaps pedicled with sartorius muscular fascia around superficial circumflex iliac vessels for the treatment of ARCO stage II-III ONFH in young adults.

Materials and methods

General information

Inclusion criteria. Inclusion criteria for the study included the following: i) Patients had complete data that included clinical and follow-up material; ii) the affected hip had not undergone surgery; iii) etiological factors had already been removed, for example, alcohol drinkers became abstinent and patients taking hormones stopped using them; iv) patients were aged

Correspondence to: Professor Zhenggang Bi, Department of Orthopedics, The First Affiliated Hospital of Harbin Medical University, 23 Youzheng Street, Harbin, Heilongjiang 150001, P.R. China
E mail: drbizhenggang@163.com

*Contributed equally

Key words: superficial circumflex iliac vessels, fascia of sartorius muscle, iliac bone flap transplantation, osteonecrosis of femoral head, clinical research

Table I. General information of the patients.

Variable	Minimum	Maximum	Mean \pm SD
Age (years)	14	63	40.26 \pm 10.28
Follow-up time (months)	3	96	41.71 \pm 24.26
Surgery time (min)	105	320	182.71 \pm 51.14
Intraoperative blood loss (ml)	100 ^a	1,000 ^b	478.51 \pm 261.58
Hospital stay (days)	11	36	20.29 \pm 5.82

^aUnilateral; ^bbilateral.

Table II. ARCO stages and incidence rates.

ARCO stage	Preoperative		Postoperative	
	No. of hips	Incidence rate (%)	No. of hips	Incidence rate (%)
IIA	14	32.56	16	37.21
IIB	8	18.60	7	16.28
IIC	9	20.93	8	18.60
IIIA	8	18.60	9	20.93
IIIB	3	6.98	2	4.65
IIIC	1	2.33	1	2.33
Total	43	100.00	43	100.00

ARCO, Association for Research on Osseous Circulation.

10-65 years, with the diagnosis of ONFH at ARCO stage II-III; v) the femoral head was intact with no evident collapse and no osteoarthritis; vi) imaging indicated that femoral head collapse was <2 mm; vii) the lesions were small or medium sized (<50%); viii) patients were in good health and had no other complications, including cerebrovascular, severe heart and lung disease; ix) patients were able to tolerate surgery; and x) patients and their families requested and agreed with this surgical treatment.

Exclusion criteria. Exclusion criteria for this study were as follows: i) Incomplete follow-up results or clinical information that could not be supplemented; ii) other treatment methods had been used on the affected hip and it was inappropriate to use this surgical treatment; iii) risk factors, including drinking and hormone use, were not removed; iv) patients were senile, aged >65 years, with the diagnosis of ONFH at ARCO stage IV; v) the femoral head exhibited collapse and symptoms of osteoarthritis; vi) imaging indicated that femoral head collapse was >2 mm; vii) patients had large-sized lesions (>50%); viii) patients were overly obese or had respiratory, urinary and/or other infections; ix) patients had mental illness and were unable to cooperate with the treatment; and x) patients and their families did not agree with the use of this method.

Patients. In strict accordance with the inclusion and exclusion criteria, a total of 35 patients (43 hips) were included in this study, including 27 male and 8 female patients, with both hips in 8 cases and a single hip in 27 cases. The included patients

were 14-63 years of age, with a mean of 40.26 \pm 10.28 years (Table I). The preoperative imaging data were evaluated by two orthopedic specialists and according to ARCO staging. There were 14 stage IIA hips, 8 stage IIB hips, 9 stage IIC hips, 8 stage IIIA hips, 3 stage IIIB hips and 1 stage IIIC hip. Preoperatively, the incidence rates of these stages were 32.56, 18.60, 20.93, 18.60, 6.98 and 2.33%, respectively (Table II). The etiology of the ONFH was steroid use in 14 patients, alcohol in 13 patients, trauma in 4 patients and uncertain in 4 patients. The Harris hip scores (HHSs) ranged from 44 to 72 points preoperatively, average 56.53 \pm 7.66 points (Fig. 1). The patients with steroid-induced ONFH had discontinued steroid application and the patients with alcohol-induced ONFH had abstained for \geq 3 months prior to admission. The lengths of the affected limbs and their contralateral limbs were measured preoperatively in all patients. The difference between the two limbs was <1 cm.

Surgical methods. The surgical strategy comprised six steps. i) Incision: A modified hip anterolateral incision, also known as a modified Smith-Peterson incision, in which an incision starting from the middle of the iliac crest was continued along the outer lip of the iliac crest to the anterior superior iliac spine, and then turned down for a posterolateral curved extension of 10-12 cm. ii) Release and exposure: After the skin, subcutaneous tissue and fascia latae were cut, between the subcutaneous tissue and the fascia layer, the fascia around

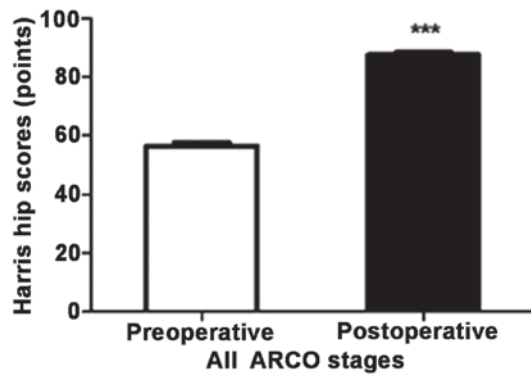


Figure 1. Harris hip scores of all ARCO stages prior to surgery and at the last follow-up. Preoperatively, the maximum score was 72 points and the minimum was 44 points [mean \pm standard deviation (SD), 56.53 \pm 7.66 points]. At follow-up, the maximum score was 97 points and the minimum was 75 points (mean \pm SD, 87.49 \pm 5.89) points). ***P<0.0001 compared with the preoperative score. ARCO, Association for Research on Osseous Circulation.

the sartorius was freed to a sufficient size. As the superficial circumflex iliac vessels are contained in this fascia, care should be taken not to damage it in during the surgery. Along the gap between the tensor fascia latae and sartorius muscles, from the outer lip of the iliac crest, the origin of the tensor fascia latae was peeled from the outer lip of the iliac crest. The vascular branching between the sartorius and tensor fascia latae muscles was ligated in order to reduce bleeding. After retracting the tensor fascia latae muscle and sartorius, the deep rectus femoris was exposed. The origin of the rectus femoris and iliopsoas was then freed. From the anterior superior iliac spine, at the origin of the sartorius, the sartorius muscular fascia around the superficial circumflex iliac vessels was freed again. The reflected head of the rectus femoris, part of the hip joint capsule, was removed from the acetabulum and the hip joint capsule was exposed.

iii) Decompression by fenestration: Following the opening of the joint capsule and protection of the articular cartilage, a bone trough measuring 2x1 cm was established in front of the junction of the femoral head and neck. Hardened or cystic lesions around the femoral head were removed using a spatula scraper or small chisel. When the subchondral femoral head had been cleaned, it was rinsed with saline.

iv) Dissociating and harvesting the bone flap: The superficial circumflex iliac vessels and surrounding fascia were isolated, a rectangular bone flap, measuring 3x2 cm, was cut from the origin of the sartorius at the anterior superior iliac spine along the iliac crest and trimmed. Blood circulation of the bone flap was observed while a section of iliac cancellous bone was harvested by rongeur to fill the space around the bone flap after the bone flap was implanted. A gelatin sponge was used for hemostasis.

v) Bone flap and implantation: The iliac flap penetrated the iliopsoas and rectus femoris muscle to the bone trough in front of the junction between the femoral head and neck. The bone flap was trimmed again and implanted into the bone trough; the proximal end was inserted into the femoral head, and if there was any space around the bone flap, it was filled with iliac cancellous bone or allogeneic bone.

vi) Bone grafting and fixation: The bone flap was fixed with 1 or 2 absorbable screws (Fig. 2).

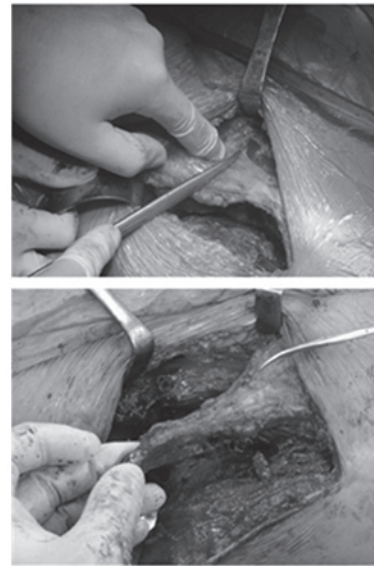


Figure 2. Method used in the process of surgery to expose the superficial circumflex iliac vessels and harvest the bone flap.

All of the patients were supplied with preemptive analgesia with analgesics preoperatively, massaged at the adductor muscle to relieve tension and pressure within the femoral head, treated with antibiotics at 30 min preoperatively, intraoperatively and postoperatively to prevent infection, and were also treated with drugs to promote bone microcirculation and to relieve pain. The negative pressure drainage tube was removed 24–48 h after the surgery. The affected hip was placed in 30° flexion and mild pronation for \geq 6 weeks. It was subject to skin traction bracing for 6 weeks. During bracing, patients underwent training for ankle joint flexion and isometric contraction of the quadriceps femoris. Three months later, patients were allowed to walk on crutches while bearing weight. The walking distance was restricted to a maximum of 500 m and the walking time to a maximum of 30 min each time. At 6 months, the affected limbs were able to bear progressive amounts of while walking. The walking distance and time were restricted to 1,000 m and 1 h, respectively, each time. At 9 months, the patients were allowed to walk with only one crutch while bearing weight. The walking distance and time were restricted to 2,000 m and 2 h, respectively. The use of crutches was discontinued at 1 year. All patients were followed up at 1, 3, 6, 9 months and 1 year postoperatively with radiography to confirm normal pelvic anatomy, computed tomography (CT) or emission computed tomography (ECT) and magnetic resonance imaging (MRI) to evaluate the survival of the bone flap and to adjust the strategy of functional rehabilitation exercise.

Main outcome measures. Joint function was assessed using the HHS (total 100 points), which included assessment of pain (total 44 points), joint function (total 47 points), range of motion (total 5 points) and deformity (total 4 points). The excellent, good and poor ratings corresponded to HHSs of 90–100, 80–89 and <80 points, respectively. All patients were subjected to pelvic radiography, CT and MRI evaluation of the femoral head, and systemic bone ECT at the final follow-up. The findings were compared with preoperative imaging data

Table III. Harris hip scores of different ARCO stages prior to surgery and at the last follow-up.

ARCO stage	No. of hips	Mean HHS (points)		P-value
		Preoperative	Postoperative	
Stage II	31	58.94±7.13	89.55±4.65	<0.0001
Stage III	12	50.33±5.71	82.17±5.81	<0.0001
Total	43	56.53±7.66	87.49±5.89	<0.0001

HHS, Harris hip scores; ARCO, Association for Research on Osseous Circulation.

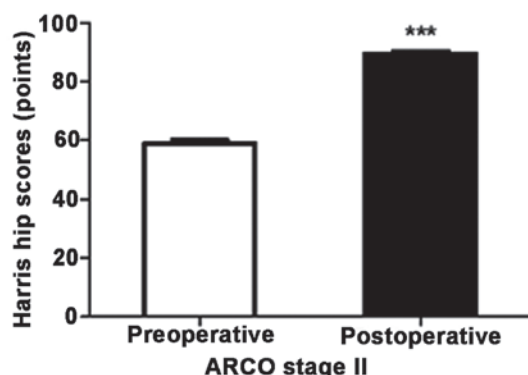


Figure 3. Harris hip scores of ARCO stage II prior to surgery and at the last follow-up. Preoperatively, the maximum score was 72 points and the minimum was 47 points [mean ± standard deviation (SD), 58.94±7.13 points]. At follow-up, the maximum score was 97 points and the minimum was 87 points (mean ± SD, 89.55 ± 4.65 points). ***P<0.0001 compared with the preoperative score. ARCO, Association for Research on Osseous Circulation.

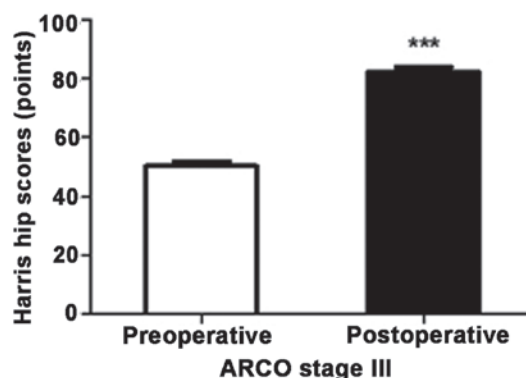


Figure 4. Harris hip scores of ARCO stage III prior to surgery and at the last follow-up. Preoperatively, the maximum score was 62 points and the minimum was 44 points [mean ± standard deviation (SD), 50.33±5.71 points]. At follow-up, the maximum score was 91 points and the minimum was 75 points (mean ± SD, 82.17±5.81 points). ***P<0.0001 compared with the preoperative score. ARCO, Association for Research on Osseous Circulation.

to determine if there were any changes in staging. The clinical success rate was defined on the basis of excellent and good ratings determined by HHS and no changes in ARCO stage.

Statistical analysis. Collected data were analyzed using SPSS software, version 21.0 (SPSS, Inc., Chicago, IL, USA) with a paired sample t-test. P<0.05 was considered to indicate a significant difference. The results are expressed as the mean ± standard deviation.

Results

General observations. The 35 patients were followed up postoperatively for 3-96 months (mean, 41.71±24.26 months; Table I). All patients underwent transplantation of iliac bone flaps pedicled with sartorius muscular fascia around superficial circumflex iliac vessels. The surgery duration (including anesthesia time) ranged from 105 to 320 min, with an average of 182.71±51.14 min (Table I). Intraoperative blood loss ranged from 100 ml unilaterally to 1,000 ml bilaterally (mean, 478.51±261.58 ml; Table I). The hospital stay was 11-36 days (mean, 20.29±5.82 days; Table I).

HHS

Overall. The HHS improved significantly from the preoperative status of 56.53±7.66 points to the postoperative status of

87.49±5.89 points (P<0.0001, t-test; Fig. 1). Preoperatively, the maximum score was 72 points and the minimum score was 44 points; postoperatively, the maximum score was 97 points and the minimum score was 75 points. A HHS of <80 points was observed in 3 patients; therefore, the clinical success rate was 91.43%.

HHS according to ARCO stage. Statistical analysis based on ARCO stage revealed that the HHS of ARCO stage II improved significantly from a preoperative status of 58.94±7.13 points to a postoperative status of 89.55±4.65 points (P<0.0001; Table III). Preoperatively, the maximum score was 72 points and the minimum was 47 points; at follow-up, the maximum score was 97 points and the minimum was 87 points (Fig. 3). The HHS of ARCO stage III improved significantly from a preoperative status of 50.33±5.71 points to a postoperative status of 82.17±5.81 points (P<0.0001; Table III). Preoperatively, the maximum score was 62 points and the minimum was 44 points; at follow-up the maximum score was 91 points and the minimum was 75 points (Fig. 4).

HHS according to etiology. The HHS of steroid-induced ONFH improved significantly from a preoperative status of 55.28±6.98 points to a postoperative status of 84.56±5.86 points (P<0.0001; Table III). Preoperatively, the maximum score was 66 points and the minimum was 45 points; at follow-up the maximum score was 94 points and minimum was 75 points (Fig. 5). Alcohol-induced ONFH improved significantly

Table IV. Harris hip scores (HHSs) according to etiology prior to surgery and at the last follow-up.

Etiology	No. of patients	Mean HHS (points)		P-value
		Preoperative	Postoperative	
Steroid-induced	14	55.28±6.98	84.56±5.86	<0.0001
Alcohol-induced	13	58.50±8.26	90.75±3.09	<0.0001
Trauma-induced	4	55.75±8.26	82.50±6.35	0.002
Unknown	4	55.40±9.61	91.60±5.81	0.001
Total	35	56.53±7.66	87.49±5.89	0.0001

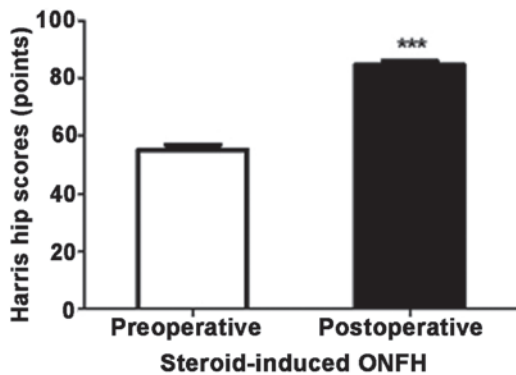


Figure 5. Harris hip scores of steroid-induced ONFH prior to surgery and at the last follow-up. Preoperatively, the maximum score was 66 points and the minimum was 45 points [mean ± standard deviation (SD), 55.28±6.98 points]. At follow-up, the maximum score was 94 points and minimum was 75 points (mean ± SD, 84.56±5.86 points). ***P<0.0001 compared with the preoperative score. ONFH, osteonecrosis of the femoral head.

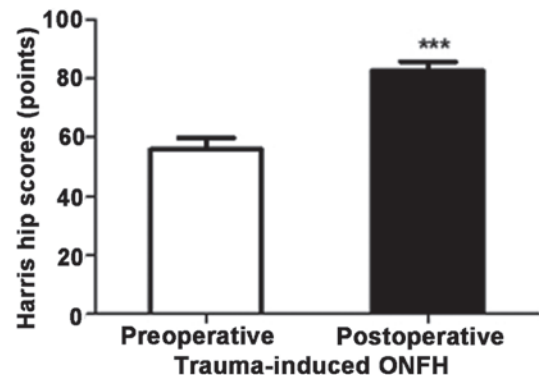


Figure 7. Harris hip scores of trauma-induced ONFH prior to surgery and at the last follow-up. Preoperatively, the maximum score was 62 points and the minimum was 44 points [mean ± standard deviation (SD), 55.75±8.26 points]. At follow-up, the maximum score was 91 points and minimum was 76 points, (mean ± SD, 82.75±6.35 points). ***P=0.002 compared with the preoperative score. ONFH, osteonecrosis of the femoral head.

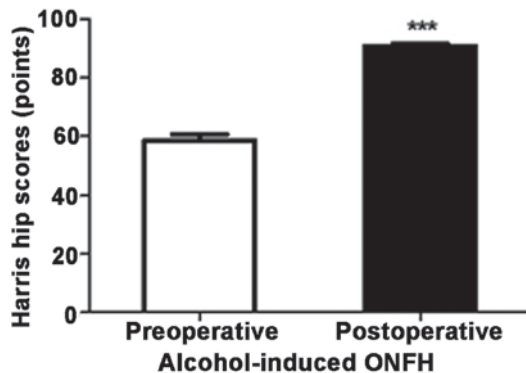


Figure 6. Harris hip scores of alcohol-induced ONFH prior to surgery and at the last follow-up. Preoperatively, the maximum score was 72 points and the minimum was 46 points [mean ± standard deviation (SD), 58.50±8.26 points]. At follow-up, the maximum score was 96 points and minimum was 85 points, (mean ± SD, 90.75±3.09 points). ***P<0.0001 compared with the preoperative score. ONFH, osteonecrosis of the femoral head.

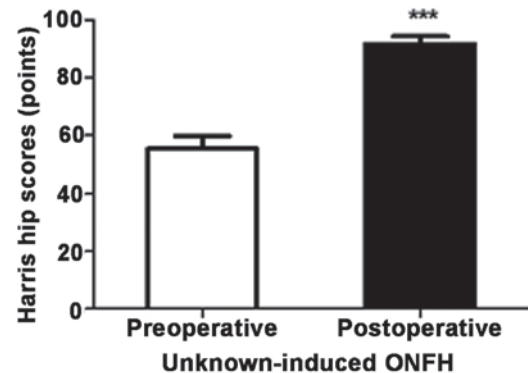


Figure 8. Harris hip scores of ONFH of unknown etiology prior to surgery and at the last follow-up. Preoperatively, the maximum score was 72 points and the minimum was 47 points [mean ± standard deviation (SD), 55.40±9.61 points]. At follow-up, the maximum score was 97 points and the minimum was 85 points (mean ± SD, 91.60±5.81 points). ***P=0.001 compared with the preoperative score. ONFH, osteonecrosis of the femoral head.

from a preoperative status of 58.50±8.26 points to a postoperative status of 90.75±3.09 points (P<0.0001; Table IV). Preoperatively, the maximum score was 72 points and the minimum was 46 points; at follow-up the maximum score was 96 points and minimum was 85 points (Fig. 6). Trauma-induced ONFH improved significantly from a preoperative status of 55.75±8.26 points to a postoperative status of 82.50±6.35 points

(P=0.002; Table III). Preoperatively, the maximum score was 62 points and the minimum was 44 points; at follow-up, the maximum score was 91 points and the minimum was 76 points (Fig. 7). ONFH of unknown etiology improved significantly from a preoperative status of 55.40±9.61 points to a postoperative status of 91.60±5.81 points (P=0.001; Table III). Preoperatively, the maximum score was 72 points

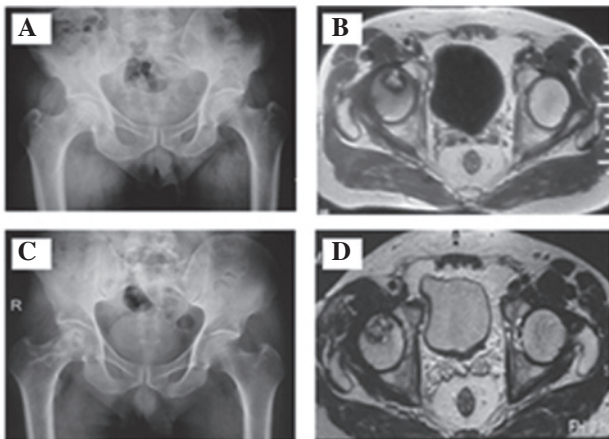


Figure 9. Preoperative (A) X-ray and (B) MRI and postoperative (C) X-ray and (D) MRI at the 1-year follow-up. A 49-year-old man with a 30-year history of heavy drinking (average, 50 ml/day) was admitted to hospital on April 29, 2012 with complaints of right hip pain for more than 3 months and progressive, aggravated claudication. Physical examination revealed limited motion of the right hip joint, a positive Patrick's sign, and feelings of pain under flexion, abduction and extension. The patient was diagnosed with avascular necrosis of the femoral head at ARCO stage IIB. On May 8, 2012, the patient underwent transplantation with iliac bone flaps pedicled with sartorius muscular fascia around the superficial circumflex iliac vessels. MRI, magnetic resonance imaging; ARCO, Association for Research on Osseous Circulation.

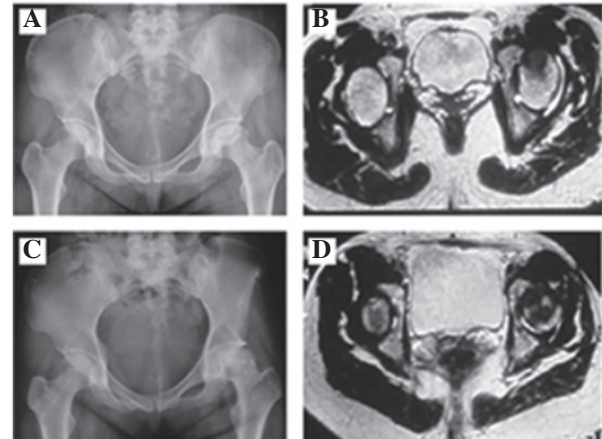


Figure 10. Preoperative (A) X-ray and (B) MRI and postoperative (C) X-ray and (D) MRI at the 1-year follow-up. A 39-year-old woman with a history of hormone use was admitted to hospital on November 28, 2011 with the complaint of having difficulty walking for 16 months owing to problems with her left lower extremity. Physical examination revealed limited motion of the left hip joint, particularly abduction and outward rotation. It was sensitive to percussion and positive for Patrick's sign. The diagnosis was bilateral avascular necrosis of the femoral head at ARCO stage IIC. On December 5, 2011, the patient underwent transplantation with left iliac bone flaps pedicled with sartorius muscular fascia around the superficial circumflex iliac vessels, as well as right femoral head core decompression. MRI, magnetic resonance imaging; ARCO, Association for Research on Osseous Circulation.

and the minimum was 47 points; at follow-up, the maximum score was 97 points and the minimum was 85 points (Fig. 8). Pain. The pain disappeared in 23 patients. Pain continued to be felt in 12 patients, but was considered tolerable. None of the patients required oral analgesics.

Imaging results. The postoperative imaging data were evaluated by two orthopedic specialists and according to ARCO staging, there were 16 hips of stage IIA, 7 of stage IIB, 8 of stage IIC, 9 of stage IIIA, 2 of stage IIIB and 1 of stage IIIC. The postoperative incidence rates were 37.21, 16.28, 18.60, 20.93, 4.65 and 2.33% respectively (Table I), which the proportion of stage IIA and IIIA was increased and that of stage IIB, IIC, IIIB and IIIC was reduced. Postoperative radiography, CT and MRI revealed no significant differences in the ARCO staging of 32 patients compared with preoperative findings, observing that they had good osteogenesis (Figs 9 and 10), no appearance of cystic necrosis, hardening or the 'crescent sign'. However, another 3 patients at ARCO stage III appeared to have mild collapse (<2 mm) compared with the preoperative collapse. None of the patients developed osteoarthritis, and none required total hip arthroplasty.

Discussion

In recent years, the incidence of ONFH has been increasing annually. The reasons for this phenomenon are the wide application and abuse of hormones as well as changes in lifestyles (1). Although its etiology, pathogenesis and treatment have made considerable advances, there is no effective, universally applicable method of treatment (2). Currently, surgery is a common method of curbing the osteonecrotic process and preventing collapse. Therefore, the key to treating ONFH

is to choose the optimal surgical option (single surgery or a combination of methods) based on the condition and staging of the patient.

With the rising incidence of ONFH and development of means to arrive at an early diagnosis, the treatment of ONFH has been greatly improved. The use of total hip replacement in young patients, for instance, is being cautiously established. Maintaining the integrity of the femoral head is a topic of great interest. Transplantation of vascularized bone flap grafts not only provides mechanical support and prevents collapse of the femoral head, but also offers a new source of revascularization and improves blood circulation of the necrotic femoral head. The treatments for ONFH involving a muscle pedicle flap that are currently used in China include: i) a greater trochanter bone graft of the gluteus medius branch of the lateral femoral circumflex vessel's ascending branch; ii) an upper-middle periosteal flap of the femur pedicled with the descending branch of the lateral femoral circumflex artery; iii) a lateral femoral circumflex artery transverse branch combined with greater trochanter bone graft of the gluteus medius branch; iv) a double iliac bone flap with iliac crest and anteroinferior iliac spine of the lateral femoral circumflex vessel's ascending branch; v) vascularized fibula graft with unilateral fibula; vi) vascularized pedicle with an osteoperiosteal flap of the deep iliac circumflex vessels combined with a vascular bundle; and vii) iliac bone flaps pedicled with sartorius muscular fascia and an intermuscular septum vessel (4-15). Iliac bone flaps pedicled with sartorius muscular fascia around superficial circumflex iliac vessels have been rarely reported.

In the application of procedures involving a greater trochanter bone flap graft of the gluteus medius branch of the lateral femoral circumflex vessel's ascending branch, Zhao *et al* (4,5) found that the outer diameter of the gluteal

muscle branch was 1.0 ± 0.3 mm, the length from the starting point to the end point of the greater trochanter was 4.0 ± 1.3 mm, and the bone flap dimension was $1.5\times 2.5\times 1.5$ cm. This surgery has many advantages, such as a constant and straight route, easy harvesting and minimal surgical wounds. It promotes venous return and new bone regeneration and neovascularization. It increases the bone supporting force within the femoral head and prevents femoral head collapse. A total of 17 patients with ONFH at Ficat stages II-IV were treated with this surgery and were followed up for an average of 2.6 years. The results indicated that it is a simple and feasible method causing little trauma that can provide a rich blood supply for the femoral head and induce osteogenesis. Thus, it is an effective treatment for avascular necrosis of the femoral head.

When conducting procedures involving an upper-middle periosteal flap of the femur pedicled with the descending branch of the lateral femoral circumflex artery, Zhao *et al* (6) reported that the periosteal branches originated from 4.0 ± 1.1 cm of the descending artery, the outer diameter was 1.2 ± 0.5 mm, and the length was 7.1 ± 1.0 cm. There is an abundant blood supply, a large range of periosteal flap can be harvested, the vascular pedicle is constant, and the surgical methods are flexible with less damage to, or no impact on, limb function. This procedure can antegradely repair femoral neck fractures and retrogradely repair femoral nonunion and ONFH.

When treatment with a greater trochanter bone graft of the lateral femoral circumflex artery transverse branch combined with a gluteus medius branch was carried out, Zhao *et al* (7,8) reported that the outer diameter of the lateral femoral circumflex artery transverse branch origin was 2.5 ± 0.8 mm. The distance from the gluteal muscle branch origin to the muscle entering point was 3.5 ± 0.8 cm. This surgery is characterized by a reliable, abundant blood supply, and is easy to conduct with a flexible surgical approach. Following its use to treat 32 hips in 32 patients with ONFH at Ficat stages II-III, the clinical success rate was 90.6%, with a radiographic success rate of 87.5%. The femoral head demonstrated revascularization and the procedure had good efficacy.

According to further studies conducted by Zhao *et al* (9,10), where a double iliac bone flap graft with iliac crest and antero-inferior iliac spine of the lateral femoral circumflex vessel's ascending branch was used, the length of the antero-inferior iliac spine of the lateral femoral circumflex vessel's ascending branch was 5.3 ± 1.0 cm, the outer diameter of the origin was 1.2 ± 0.3 mm, and the range of the vascularized periosteal flap harvested in the antero-inferior iliac spine was 2.0×2.0 cm. This surgery is characterized by a complete arterial and venous vascularization system, constant anatomical location, easy dissection, simple surgery and little damage. Combining it with a periosteal flap in the ascending iliac crest branch, the bone flap was grafted to the femoral head epiphyseal plate in children, which is an effective method for treating Perthes disease. When 11 patients with Perthes disease were clinically treated and followed up for 1.0-3.5 years, the rate of excellent results reached 82%.

According to studies carried out by Liu *et al* (11,12), involving a vascularized fibula graft with unilateral fibula, the outer diameter of the peroneal artery that supplies the fibula is 1.55 mm. The first arcuate artery gave rise to one fibular nutrient artery 14.8 cm away from the capitulum fibula,

and its outer diameter was 1.67 mm. A unilateral donor can provide free fibula of sufficient length and ensure adequate vascularization, suggesting its safety and feasibility. In addition, the duration of surgery is shortened, surgical trauma and blood loss are reduced, body aesthetics are improved, and the patients are more likely to accept the surgery. When 14 patients with bilateral ONFH at Steinberg stage II-IV were clinically treated and followed up for an average of 24 months, the radiographic results 1 year postoperatively indicated that 23 hips (82.1%) were improved and 5 hips (17.9%) were kept stable. This finding indicates that a vascularized fibula graft with unilateral fibula is an effective treatment for bilateral ONFH due to its short surgery time, reduced damage and blood loss, and good postoperative recovery of hip function.

Surgery involving a vascularized pedicle with an osteoperiosteal flap of deep iliac circumflex vessels combined with a vascular bundle was carried out by Xian *et al* (13). The authors treated 42 patients with ONFH (71 hips) at Ficat stage I-IV using this surgery, and the rates of excellent and good results were up to 94.1% after a follow-up of 13.6 years (10-18 years).

Chen *et al* (14) described the use of iliac bone flaps pedicled with sartorius muscular fascia and intermuscular septum vessel. They observed that the grafted intermuscular fascia comprised the proximal segment of the sartorius, tensor fascia latae, and rectus femoris. The major blood vessels were derived from the ascending branch of the lateral femoral circumflex artery (iliac crest, gluteal muscle and antero-inferior iliac spine branches) and the sartorius segmental vessels from the superficial iliac circumflex artery and lateral circumflex femoral artery. The length of the myofascial pedicle was 6-8 cm, and the size of the bone block was 3×4 cm. The vascularity and route were constant and abundant. The possibility of lateral femoral cutaneous nerve damage was reduced, while the morphology of the anterosuperior iliac spine was retained. Therefore, this is psychologically acceptable to patients and is considered an easy alternative bone graft for the treatment of femoral neck lesions. Liu *et al* (15) treated 56 patients with ONFH at Ficat stage I-II using sartorius iliac bone flaps. The patients were followed up for 8-36 months (mean, 18 months). The HHS was 85.2 ± 6.3 points at 12 months postoperatively. The rate of excellent and good results was up to 92.8%.

In the present study, 35 patients with ONFH at ARCO stage II-III were treated with iliac bone flaps pedicled with sartorius muscular fascia around superficial circumflex iliac vessels. Based on the imaging findings, according to ARCO staging, the preoperative incidence rates of each stage were IIA 32.56%, IIB 18.60%, IIC 20.93%, IIIA 18.60%, IIIB 6.98% and IIIC 2.33% and the postoperative rates were IIA 37.21%, IIB 16.28%, IIC 18.60%, IIIA 20.93%, IIIB 4.65% and IIIC 2.33%. The results revealed that following treatment, the incidence rates of stages IIA and IIB were increased and those of IIB, IIC and IIIB, IIIC were reduced compared with the preoperative rates. No significant staging progression was observed. The average HHSs for stages II and III were 58.94 ± 7.13 and 50.33 ± 5.71 points, respectively prior to treatment 89.55 ± 4.65 and 82.17 ± 5.81 points, respectively, postoperatively. The results showed that the HHS of stage II was higher than that of stage III. The improvements in scores were statistically significant, and treatment in the earlier stages provided better results.

According to etiology, the HHSs for steroid-induced, alcohol-induced and trauma-induced ONFH, and ONFH of unknown etiology were 55.28 ± 6.98 , 58.50 ± 8.26 , 55.75 ± 8.26 and 55.75 ± 8.26 points, respectively, prior to treatment, and 84.56 ± 5.86 , 90.75 ± 3.09 , 82.50 ± 6.35 and 82.50 ± 6.35 points, respectively, postoperatively. The differences in HHSs between prior to surgery and postoperatively were significant ($P < 0.0001$, $P < 0.0001$, $P = 0.002$ and $P = 0.001$, respectively); the P-values for steroid- and alcohol-induced ONFH were lower than those for trauma-induced ONFH and ONFH of unknown etiology. Notably, steroids and alcohol are single factors, unknown etiology is multifactorial while trauma involves damage to the blood supply of the femoral head itself.

In conclusion, in young adults aged 10-65 years with ONFH at ARCO stage II-III, surgery involving iliac bone flaps pedicled with sartorius muscle fascia around superficial circumflex iliac vessels is effective in maintaining the integrity of the femoral head, as it provides abundant blood circulation, good osteogenesis and functioning of the hip. The effects of the surgery on steroid-induced and alcohol-induced ONFH are superior to those on trauma-induced ONFH and ONFH of unknown etiology, and the effects of ARCO stages IIA and IIIA are better than ARCO stages IIB, IIC and IIIB, IIIC.

The results of the present study, based on HHSs, ARCO stages and imaging, revealed that the clinical success rate was 91.43%, similar to the results of other methods, and better than some previously reported (8,10). However, more clinical research and evidence-based medical investigations are required to verify its results at long-term follow-up (>10 years) and application prospects.

Acknowledgements

This study was financially supported by The National Natural Science Foundation of China (No. 81171692).

References

1. Amanatullah DF, Strauss EJ and di Cesare PE: Current management options for osteonecrosis of the femoral head: part 1, diagnosis and nonoperative management. *Am J Orthop (Belle Mead NJ)* 40: E186-E192, 2011.

2. Wang XS, Zhuang QY, Weng XS, *et al*: Etiological and clinical analysis of osteonecrosis of the femoral head in Chinese patients. *Chin Med J (Engl)* 126: 290-295, 2013.
3. Seamon J, Keller T, Saleh J and Cui Q: The pathogenesis of nontraumatic osteonecrosis. *Arthritis* 2012: 601763, 2012.
4. Zhao DW, Xu DC, Ma Y, *et al*: Anatomical study for transposition of the greater trochanter bone flap pedicled with middle gluteal muscle branch of lateral femoral circumflex vessel. *Zhonghua Xian Wei Wai Ke Za Zhi* 27: 129-131, 2004 (In Chinese).
5. Zhao DW, Cui X, Li CX, *et al*: Greater trochanter bone flap pedicled with middle gluteal muscle branch of lateral femoral circumflex vessel for the treatment of ischemic necrosis of femoral head. *Zhongguo Gu Yu Guan Jie Sun Shang Za Zhi* 19: 4-6, 2004 (In Chinese).
6. Zhao DW, Bao SZ, Wang TN, *et al*: Applied anatomy of periosteal flap of up-middle femoral pedicled with descending branch of lateral femoral circumflex artery. *Zhongguo Lin Chuang Jie Pou Xue Za Zhi* 18: 126-127, 2000 (In Chinese).
7. Zhao DW, Zhang Y and Xu CD: Applied anatomy of greater trochanter bone-periosteum flap pedicled with transversal and middle gluteal muscle branches of lateral femoral circumflex artery. *Zhongguo Lin Chuang Jie Pou Za Zhi* 23: 234-236, 244, 2005 (In Chinese).
8. Zhao DW, Wang WN, Wang BJ, *et al*: Treatment of osteonecrosis of the femoral head by using greater trochanteric bone flap pedicled with double blood vessels. *Zhonghua Xian Wei Wai Ke Za Zhi* 29: 167-169, 2006 (In Chinese).
9. Zhao DW, Wang WM, Chen YW, *et al*: Applied anatomy for transposition of two periosteal flaps pedicled with iliac crest and anterior inferior iliac branches of ascending rarus of lateral femoral circumflex vessel. *Zhongguo Lin Chuang Jie Pou Za Zhi* 21: 211-213, 2003 (In Chinese).
10. Zhao DW, Cui X, Sun Q, *et al*: Two periosteal flap pedicled with anterior superior iliac and anterior inferior iliac branches of lateral femoral circumflex vessel transposition for the treatment of Perthes disease. *Zhonghua Xian Wei Wai Ke Za Zhi* 26: 259-261, 2003 (In Chinese).
11. Liu XL, Sheng JG and Zhang CQ: Applied anatomic study on vascularized fibula graft with unilateral fibula as the donor for bilateral femoral head necrosis. *Guo Ji Gu Ke Xue Za Zhi* 32: 189-191, 201, 2011 (In Chinese).
12. Liu XL, Sheng JH, Zhang CG, *et al*: Treatment of bilateral avascular necrosis of femoral head by free vascularized fibula grafting with unilateral fibula as donor. *Zhongguo Xiu Fu Chong Jian Wai Ke Za Zhi* 25: 641-645, 2011 (In Chinese).
13. Xian BS, Sun Y and Xian RL: Treatment of osteonecrosis of the femoral head using vascular pedicle bone graft. *Shi Yong Gu Ke Za Zhi* 15: 750-753, 2009 (In Chinese).
14. Chen SL, Wang YK, Zheng ZC, *et al*: Applied anatomy for transposition of iliac bone flaps pedicled with sartorius muscular fascia and intermuscular septum vessel and its clinical application. *Zhonghua Xian Wei Wai Ke Za Zhi* 22: 555-557, 2004 (In Chinese).
15. Liu C, Peng H, Yin D, *et al*: Observation of curative effect of treating early avascular necrosis of femoral head by grafting sartorius muscle iliac bone flap. *Zhongguo Linchuang Xin Yixue* 5: 207-209, 2012 (In Chinese).