

Positron Emission Tomography in the Differential Diagnosis of Parkinsonism

Juha O Rinne

Turku PET Centre, University of
Turku and Turku University Hospital,
Turku, Republic of Finland

Positron emission tomography (PET) studies on presynaptic dopaminergic function can reveal hypofunction in early Parkinson's disease (PD) which may help in the early diagnosis especially in patients with mild symptoms. This hypofunction can be detected with fluorodopa (reflecting mainly aromatic amino acid decarboxylase activity of nigrostriatal terminals) or dopamine transporter ligands. These studies can also help to distinguish PD from essential tremor. However, investigations of presynaptic dopaminergic function are not useful in the differential diagnosis of parkinsonian syndromes. PET ligands, such as fluorodeoxyglucose (reflecting glucose metabolism) and dopamine receptor ligands, reflecting striatal neuronal function are better in this respect. Cardiac sympathetic function studies represent a new and interesting approach to improve differential diagnosis of parkinsonian syndromes but more studies are needed in larger patient populations with longer follow-up to evaluate the usefulness of these investigations. Multitracer approach combining ligands reflecting different aspects of dopaminergic neurotransmission and other physiological function will increase differential diagnostic accuracy. **Journal of Movement Disorders 2009;2:53-57**

Key Words: Parkinsonism, PET.

Positron emission tomography (PET) is a technique which employs short-lived radioactive isotopes and by which it is possible to study different physiological brain functions in living humans. PET allows versatile investigation of cerebral blood flow, oxygen consumption, metabolism and the function of various neurotransmitter systems.

In Parkinson's disease (PD), because of the key biochemical deficit being impairment of the nigrostriatal dopaminergic system, most of PET imaging has been concentrated on examining dopaminergic function. In PD PET can be used a) to study pathophysiology, b) in diagnostics / differential diagnostics, c) in follow-up, d) in detection of asymptomatic cases, e) in development of treatment and in f) monitoring of treatment effects (drugs, stimulations, lesions, transplantation, etc.).

Typical PET Findings in Parkinson's Disease

The typical PET findings in PD are listed in Table 1. The most commonly used PET tracer (radiopharmaceutical) to investigate brain dopaminergic function in PD is 3, 4-dihydroxy-6-¹⁸F fluoro-L-phenylalanine (¹⁸F-FDOPA). The uptake of FDOPA mainly reflects the uptake of FDOPA into presynaptic nigrostriatal terminals and its conversion by aromatic amino acid decarboxylase to [¹⁸F]dopamine and storage in vesicles in the presynaptic terminals nigrostriatal dopa-minergic neurons.

When compared to healthy controls FDOPA uptake is reduced in early unmedicated PD patients to 30-40% in the putamen.¹⁻⁴ The reduction shows topographical organization, since the posterior part of the putamen (receiving its projections from ventrolateral substantia nigra) is most severely affected. In the caudate nucleus the decline is smaller, the uptake values being 60-70% of control mean.¹⁻⁴ During disease progression there is further decline in FDO-PA uptake, but the reduction seems to be exponential, or at least non-linear^{5,6} being faster in the beginning of the disease and the slowing down. However, even during progression

Received September 18, 2008

Accepted September 20, 2008

Corresponding author

Juha O Rinne, MD, PhD

Turku PET Centre, University of

Turku and Turku University Hospital,

Kiinamylynkatu 4-8, FIN-20520 Turku,

Republic of Finland

Tel +358-2-3131866

Fax +358-2-2318191

E-mail juha.rinne@tyks.fi

dopaminergic function in the putamen is more severely affected than in the caudate nucleus. The severity motor symptoms, especially bradykinesia and rigidity are related to the degree of striatal dopaminergic hypofunction striatal as indicated by an association between FDOPA uptake and “off” stage unified Parkinson disease rating scale (UPDRS) motor score ($r=-0.50--0.68$).⁷⁻⁹

There are also other dopaminergic PET tracers. By choosing different radioligand it is possible to study presynaptic dopaminergic function (metabolism and storage by FDOPA), reuptake back to presynaptic terminals by membrane transporter [dopamine transporter (DAT) ligands, e.g. [¹⁸F]CFT, [¹¹C] RTI 32, [¹²³I]-beta-CIT-FP], vesicular monoamine transport [vesicular monoamine transporter (VMAT) ligands, e.g. [¹¹C] dihydrotetrabenazine].

Membrane dopamine transporter ligand uptake is reduced usually to 20-30% of the control in the putamen early PD.^{4,10,11} When compared in same patients, DAT binding seems to

be more severely affected than FDOPA uptake.^{4,12} This may be partially due to compensatory mechanism since by down regulating DAT and enhancing the activity of aromatic L-amino acid decarboxylase (AADC) enzyme nigrostriatal system tries to compensate for reduction in dopamine levels.¹³ Vesicular monoamine transporter was reported to be reduced in caudate nucleus (-44%), anterior putamen (-68%), and posterior putamen (-77%) from mean control value.¹⁴

Dopamine D2 receptors are initially upregulated in early PD, and are relatively preserved also in the more advanced stages of the disease^{15,16} whereas dopamine D1 receptors are preserved.^{17,18}

PET in the Differential Diagnosis of Parkinsonism

The possibilities to use PET in the differential diagnostics of parkinsonism are listed in Table 2.

Essential tremor may be a differential diagnostic problem with PD. Patients with pure essential tremor generally have normal striatal dopaminergic function in imaging.¹⁹⁻²¹ However, patients with isolated resting tremor or essential tremor combined with resting tremor may show impairment in striatal dopaminergic function suggesting underlying nigrostriatal pathology and possible “forme fruste” of PD.²¹

Although patients with PD show typical findings in FDOPA-PET, its ability to differentiate between PD and multiple system atrophy (MSA) or progressive supranuclear palsy (PSP) is relatively poor.^{1,22} This is understandable if one considers nigral pathology in these disorders. The degree and to some extent also topography of nigral neuronal loss is quite similar in these disorders, especially in PD and MSA (Figure 1).

In the striatum dopamine receptors are mainly situated on postsynaptic striatal neurons and thus dopamine receptor binding indirectly reflects the state of striatal neurons. In PD

Table 1. Typical PET changes in brain dopaminergic function and metabolism in patients with early Parkinson's disease

- Asymmetry
- Impaired dopaminergic function especially in the (posterior) putamen
- Relative preservation of the caudate nucleus
- Increased caudate / putamen-ratio
- Striatal postsynaptic receptor number and metabolism preserved in the early phase

PET: positron emission tomography.

Table 2. Possibilities to use PET in the differential diagnostics in parkinsonism

- With PET it is possible to detect
- Impairment of nigrostriatal dopaminergic function
 - The state of striatal neurons
 - Changes in cortical and subcortical energy metabolism
 - Changes in cardiac sympathetic function

PET: positron emission tomography.

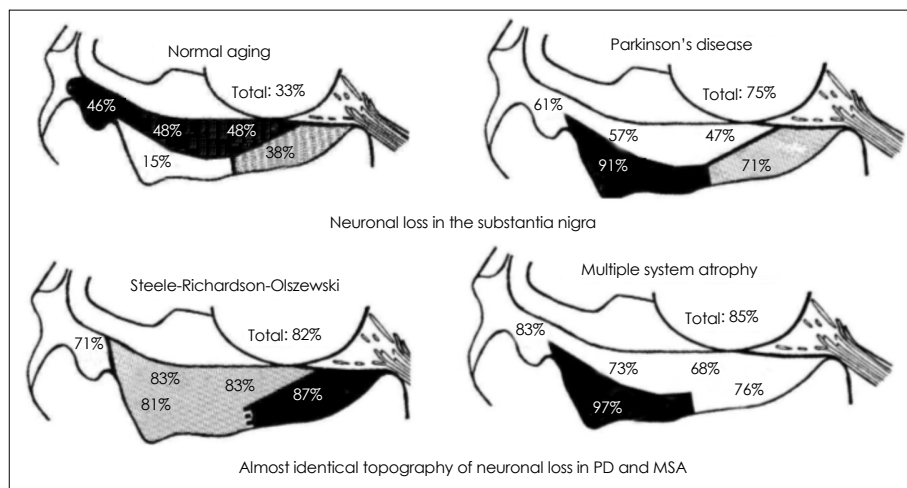


Figure 1. Neuronal loss (percentage from control mean) in post mortem samples of the substantia nigra in normal ageing, Parkinson's disease, Steele-Richardson-Olszewski syndrome (progressive supranuclear palsy), multiple system atrophy.⁴² PD: Parkinson's disease, MSA: multiple system atrophy.

the striatum is relatively well preserved whereas in MSA, PSP and corticobasal degeneration (CBD) there is striatal degeneration. Therefore, in PD D2 binding is generally normal (or even shows initial upregulation) but is reduced in MSA and PSP.^{1,23} In CBD the impairment of dopaminergic system is asymmetrical, usually also affecting the caudate nucleus in addition to the putamen, as can be seen as reduced FDOPA uptake whereas D2 receptor binding is less consistently affected.²⁴⁻²⁶

Fluorodeoxyglucose (FDG) is a glucose analogue the uptake of which indirectly reflects neuronal and synaptic activity. Striatal FDG uptake in PD is normal (or even hypermetabolism at early stage may be seen). In contrast, in MSA, already at early stage of the disease striatal FDG uptake is reduced indicating striatal neuronal dysfunction and degeneration.^{23,27,28} Similarly in PSP and CBD striatal hypometabolism is seen, which is usually asymmetrical in CBD and affects especially caudate in PSP.²⁷

In addition to changes in FDG uptake in the striatum, also cortical changes in glucose metabolism can be detected in different parkinsonian syndromes. In PD in non-demented patients cortical metabolism is relatively preserved, but some reduction can be seen in cortical motor areas and parietal cortex.²⁷ In PSP frontal and brainstem, and sometimes caudate and parietal cortex hypometabolism has been reported.²⁷ In CBD impairment in glucose metabolism is asymmetrical (worse on the hemisphere contralateral to predominant symptoms) and is reduced in caudate nucleus, putamen, thalamus and parietal and insular cortex.^{25,27}

PD is associated with several autonomic manifestations, including orthostatic hypotension, gastrointestinal and genitourinary dysfunction. Multiple studies in PD employing different PET (such as [¹¹C]meta-Hydroxyephedrine) or single photon emission computed tomography (SPECT) ligands (such as [¹²³I]-metaiodobenzylguanidine ([¹²³I]-MIBG) have shown striking reductions in uptake of the ligand in myocardium indicating cardiac sympathetic denervation.²⁸⁻³¹ Some investigators have found cardiac sympathetic denervation in the early stages of PD,^{32,33} others reported it only in patients at later stages of the disease.³⁴ The neuropathologic basis of the denervation has been thought to be neurodegenerative, with Lewy body deposition in the cardiac plexus.³⁵ Imaging of cardiac sympathetic function has been suggested to be helpful in separating patients with PD from those with MSA, since impairment is found in PD whereas the uptake is generally normal in MSA.^{29,33,36,37} However, the separation is not perfect since reduced uptake in both of these disorders has been reported, although the reductions were smaller than those in PD.³⁸ A study comparing cardiac and sympathetic denervation found that a) cardiac sympathetic denervation was found to occur not only in PD but also in other parkinsonian syndromes, such as

MSA and PSP, b) cardiac sympathetic denervation was not correlated with striatal denervation, suggesting that the pathophysiologic processes underlying cardiac and striatal denervation occur independently in patients with parkinsonian syndromes.³⁹

The problem of the PET studies in the relatively small number of patients in each study. Often the studies are cross-sectional without longitudinal follow-up. The clinical diagnosis of parkinsonian syndromes is not always correct and the diagnosis may become apparent during longer follow-up. In neuropathologically confirmed series of 100 clinically diagnosed patients the misdiagnosis of PD was 10%.⁴⁰ In a study investigating dopamine transporter function with [¹²³I]-2-beta-carbomethoxy-3-beta-(4-iodophenyl)-tropane ([¹²³I]-beta-CIT) in different parkinsonian syndromes and using the diagnosis at 6 month clinical follow-up as a “golden standard” found that baseline [¹²³I]-beta-CIT scan result was in disagreement with the final diagnosis in less than 10% of cases whereas the initial clinical diagnosis was in disagreement with the final diagnosis in 20% of cases.⁴¹ Of course, it would be desirable to have even longer follow-up with post mortem confirmation of the diagnosis.

Conclusions and Future Directions

PET studies on presynaptic dopaminergic function can reveal hypofunction in early PD which may help in the early diagnosis especially in patients with mild symptoms. These studies can also help to distinguish PD from essential tremor. However, investigations of presynaptic dopaminergic function are not useful in the differential diagnosis of parkinsonian syndromes. PET ligands reflecting striatal neuronal function are better in this respect. Cardiac sympathetic function studies represent a new and interesting approach to improve differential diagnosis of parkinsonian syndromes but more studies are needed in larger patient populations with longer follow-up to evaluate the usefulness of these investigations. In the future new ligands targeted for different protein aggregations seen in these disorders will probably increase specificity. Also new automated region-of-interest and voxel-based analysis methods may be helpful as suggested by initial experience. Multi-tracer approach combining information from different neurotransmitter or other physiological functions may further increase differential diagnostic accuracy. Furthermore, comparison and evaluation of the relative usefulness of different imaging modalities (e.g. PET vs. new MRI techniques) needs to be done to be able to choose the best imaging investigations to help in the clinical differential diagnosis of parkinsonism.

Acknowledgments

This study was financially supported by the Academy of Finland [pro-

ject #111879, Turku University Hospital clinical grants (EVO), Sigrid Juselius Foundation].

REFERENCES

- Brooks DJ, Ibanez V, Sawle GV, Quinn N, Lees AJ, Mathias CJ, et al. Differing patterns of striatal 18F-dopa uptake in Parkinson's disease, multiple system atrophy, and progressive supranuclear palsy. *Ann Neurol* 1990;28:547-555.
- Sawle GV, Playford ED, Burn DJ, Cunningham VJ, Brooks DJ. Separating Parkinson's disease from normality. Discriminant function analysis of fluorodopa F 18 positron emission tomography data. *Arch Neurol* 1994;51:237-243.
- Ishikawa T, Dhawan V, Kazumata K, Chaly T, Mandel F, Neumeier J, et al. Comparative nigrostriatal dopaminergic imaging with iodine-123-beta CIT-FP/SPECT and fluorine-18-FDOPA/PET. *J Nucl Med* 1996;37:1760-1765.
- Rinne OJ, Nurmi E, Ruottinen HM, Bergman J, Eskola O, Solin O. [(18F)FDOPA and [(18F)CFT are both sensitive PET markers to detect presynaptic dopaminergic hypofunction in early Parkinson's disease. *Synapse* 2001;40:193-200.
- Hilker R, Schweitzer K, Coburger S, Ghaemi M, Weisenbach S, Jacobs AH, et al. Nonlinear progression of Parkinson disease as determined by serial positron emission tomographic imaging of striatal fluorodopa F 18 activity. *Arch Neurol* 2005;62:378-382.
- Brück A, Aalto S, Rauhala E, Bergman J, Marttila R, Rinne JO. A follow-up study on 6-[18F]fluoro-L-dopa uptake in early Parkinson's disease shows nonlinear progression in the putamen. *Mov Disord* 2009;24:1009-1015.
- Brooks DJ. Morphological and functional imaging studies on the diagnosis and progression of Parkinson's disease. *J Neurol* 2000;247 Suppl 2:III1-III18.
- Dhawan V, Ma Y, Pillai V, Spetsieris P, Chaly T, Belakhlef A, et al. Comparative analysis of striatal FDOPA uptake in Parkinson's disease: ratio method versus graphical approach. *J Nucl Med* 2002;43:1324-1330.
- Whone AL, Watts RL, Stoessl AJ, Davis M, Reske S, Nahmias C, et al. Slower progression of Parkinson's disease with ropinirole versus levodopa: the REAL-PET study. *Ann Neurol* 2003;54:93-101.
- Frost JJ, Rosier AJ, Reich SG, Smith JS, Ehlers MD, Snyder SH, et al. Positron emission tomographic imaging of the dopamine transporter with 11C-WIN 35,428 reveals marked declines in mild Parkinson's disease. *Ann Neurol* 1993;34:423-431.
- Rinne JO, Laihininen A, Nägren K, Ruottinen H, Ruotsalainen U, Rinne UK. PET examination of the monoamine transporter with [11C]beta-CIT and [11C]beta-CFT in early Parkinson's disease. *Synapse* 1995;21:97-103.
- Ishikawa T, Dhawan V, Kazumata K, Chaly T, Mandel F, Neumeier J, et al. Comparative nigrostriatal dopaminergic imaging with iodine-123-beta CIT-FP/SPECT and fluorine-18-FDOPA/PET. *J Nucl Med* 1996;37:1760-1765.
- Lee CS, Samii A, Sossi V, Ruth TJ, Schulzer M, Holden JE, et al. In vivo positron emission tomographic evidence for compensatory changes in presynaptic dopaminergic nerve terminals in Parkinson's disease. *Ann Neurol* 2000;47:493-503.
- Bohnen NI, Albin RL, Koeppe RA, Wernette KA, Kilbourn MR, Minoshima S, et al. Positron emission tomography of monoaminergic vesicular binding in aging and Parkinson disease. *J Cereb Blood Flow Metab* 2006;26:1198-1212.
- Brooks DJ, Ibanez V, Sawle GV, Playford ED, Quinn N, Mathias CJ, et al. Striatal D2 receptor status in patients with Parkinson's disease, striatonigral degeneration, and progressive supranuclear palsy, measured with 11C-raclopride and positron emission tomography. *Ann Neurol* 1992;31:184-192.
- Rinne JO, Laihininen A, Ruottinen H, Ruotsalainen U, Nägren K, Lehtinen P, et al. Increased density of dopamine D2 receptors in the putamen, but not in the caudate nucleus in early Parkinson's disease: a PET study with [11C]raclopride. *J Neurol Sci* 1995;132:156-161.
- Rinne JO, Laihininen A, Nägren K, Bergman J, Solin O, Haaparanta M, et al. PET demonstrates different behaviour of striatal dopamine D-1 and D-2 receptors in early Parkinson's disease. *J Neurosci Res* 1990;27:494-499.
- Turjanski N, Lees AJ, Brooks DJ. In vivo studies on striatal dopamine D1 and D2 site binding in L-dopa-treated Parkinson's disease patients with and without dyskinesias. *Neurology* 1997;49:717-723.
- Lee MS, Kim YD, Im JH, Kim HJ, Rinne JO, Bhatia KP. 123I-IPT brain SPECT study in essential tremor and Parkinson's disease. *Neurology* 1999;52:1422-1426.
- Antonini A, Moresco RM, Gobbo C, De Notaris R, Panzacchi A, Barone P, et al. The status of dopamine nerve terminals in Parkinson's disease and essential tremor: a PET study with the tracer [11-C]FE-CIT. *Neurol Sci* 2001;22:47-48.
- Brooks DJ, Playford ED, Ibanez V, Sawle GV, Thompson PD, Findley LJ, et al. Isolated tremor and disruption of the nigrostriatal dopaminergic system: an 18F-dopa PET study. *Neurology* 1992;42:1554-1560.
- Burn DJ, Sawle GV, Brooks DJ. Differential diagnosis of Parkinson's disease, multiple system atrophy, and Steele-Richardson-Olszewski syndrome: discriminant analysis of striatal 18F-dopa PET data. *J Neurol Neurosurg Psychiatry* 1994;57:278-284.
- Ghaemi M, Hilker R, Rudolf J, Sobesky J, Heiss WD. Differentiating multiple system atrophy from Parkinson's disease: contribution of striatal and midbrain MRI volumetry and multi-tracer PET imaging. *J Neurol Neurosurg Psychiatry* 2002;73:517-523.
- Sawle GV, Brooks DJ, Marsden CD, Frackowiak RS. Corticobasal degeneration. A unique pattern of regional cortical oxygen hypometabolism and striatal fluorodopa uptake demonstrated by positron emission tomography. *Brain* 1991;114:541-556.
- Nagasawa H, Tanji H, Nomura H, Saito H, Itoyama Y, Kimura I, et al. PET study of cerebral glucose metabolism and fluorodopa uptake in patients with corticobasal degeneration. *J Neurol Sci* 1996;139:210-217.
- Klafke S, Kuhn AA, Plotkin M, Amthauer H, Harnack D, Felix R, et al. Dopamine transporters, D2 receptors, and glucose metabolism in corticobasal degeneration. *Mov Disord* 2006;21:1724-1727.
- Eckert T, Barnes A, Dhawan V, Frucht S, Gordon MF, Feigin AS, et al. FDG PET in the differential diagnosis of parkinsonian disorders. *Neuroimage* 2005;26:912-921.
- Kwon KY, Choi CG, Kim JS, Lee MC, Chung SJ. Diagnostic value of brain MRI and 18F-FDG PET in the differentiation of Parkinsonian-type multiple system atrophy from Parkinson's disease. *Eur J Neurol* 2008;15:1043-1049.
- Yoshita M, Hayashi M, Hirai S. Decreased myocardial accumulation of 123I-meta-iodobenzyl guanidine in Parkinson's disease. *Nucl Med Commun* 1998;19:137-142.
- Satoh A, Serita T, Seto M, Tomita I, Satoh H, Iwanaga K, et al. Loss of 123I-MIBG uptake by the heart in Parkinson's disease: assessment of cardiac sympathetic denervation and diagnostic value. *J Nucl Med* 1999;40:371-375.
- Braune S, Reinhardt M, Schnitzer R, Riedel A, Lücking CH. Cardiac uptake of [123I]MIBG separates Parkinson's disease from multiple system atrophy. *Neurology* 1999;53:1020-1025.
- Taki J, Nakajima K, Hwang EH, Matsunari I, Komai K, Yoshita M, et al. Peripheral sympathetic dysfunction in patients with Parkinson's disease without autonomic failure is heart selective and disease specific. taki@med.kanawa-u.ac.jp. *Eur J Nucl Med* 2000;27:566-573.
- Takatsu H, Nagashima K, Murase M, Fujiwara H, Nishida H, Matsuo H, et al. Differentiating Parkinson disease from multiple-system atrophy by measuring cardiac iodine-123 metaiodobenzylguanidine accumulation. *JAMA* 2000;284:44-45.
- Berding G, Schrader CH, Peschel T, van den Hoff J, Kolbe H, Meyer GJ, et al. [N-methyl 11C]meta-Hydroxyephedrine positron emission

- tomography in Parkinson's disease and multiple system atrophy. *Eur J Nucl Med Mol Imaging* 2003;30:127-131.
35. Wakabayashi K, Takahashi H. Neuropathology of autonomic nervous system in Parkinson's disease. *Eur Neurol* 1997;38 Suppl 2:2-7.
 36. Taki J, Yoshita M, Yamada M, Tonami N. Significance of 123I-MIBG scintigraphy as a pathophysiological indicator in the assessment of Parkinson's disease and related disorders: it can be a specific marker for Lewy body disease. *Ann Nucl Med* 2004;18:453-461.
 37. Goldstein DS, Holmes C, Li ST, Bruce S, Metman LV, Cannon RO 3rd. Cardiac sympathetic denervation in Parkinson disease. *Ann Intern Med* 2000;133:338-347.
 38. Nagayama H, Hamamoto M, Ueda M, Nagashima J, Katayama Y. Reliability of MIBG myocardial scintigraphy in the diagnosis of Parkinson's disease. *J Neurol Neurosurg Psychiatry* 2005;76:249-251.
 39. Raffel DM, Koeppe RA, Little R, Wang CN, Liu S, Junck L, et al. PET measurement of cardiac and nigrostriatal denervation in Parkinsonian syndromes. *J Nucl Med* 2006;47:1769-1777.
 40. Hughes AJ, Daniel SE, Lees AJ. Improved accuracy of clinical diagnosis of Lewy body Parkinson's disease. *Neurology* 2001;57:1497-1499.
 41. Jennings DL, Seibyl JP, Oakes D, Eberly S, Murphy J, Marek K. (123I) beta-CIT and single-photon emission computed tomographic imaging vs clinical evaluation in Parkinsonian syndrome: unmasking an early diagnosis. *Arch Neurol* 2004;61:1224-1229.
 42. Fearnley JM, Lees AJ. Ageing and Parkinson's disease: substantia nigra regional selectivity. *Brain* 1991;114:2283-2301.