

# The use of the posterior interosseous artery flap and anterolateral thigh flap for post-traumatic soft tissue reconstruction of the hand

Jinyan Ren, MD<sup>a</sup>, Lajin Lu, PhD, MD<sup>b</sup>, Fei Gao, MD<sup>c,\*</sup> 

## Abstract

The purpose of this study was to examine the differences between the use of a posterior interosseous artery (PIA) flap and an anterolateral thigh (ALT) flap for post-traumatic, medium-sized soft tissue reconstruction of the hand based on flap characteristics, postoperative complications, and aesthetic outcomes.

From October, 2010 to March, 2016, 62 patients undergoing soft tissue reconstruction of the hand with 30 PIA flaps and 32 ALT flaps were included in this study. The 62 patients were divided into the PIA flap group and the ALT flap group. The differences between the 2 groups were analyzed.

The 62 patients included 52 males and 10 females, and the mean age at the time of surgery was 41 years. The flap failure rate was 13.3% (4/30) in the PIA flap group and 9.4% (3/32) in the ALT flap group. No significant differences in flap failure rate, recipient site complication rate, or donor site complication rate were observed between the 2 groups. However, the operative time (136 min vs 229 min) and aesthetic outcomes (flap bulk swelling, 0 cases vs 31 cases) were statistically significantly different.

Both the pedicled PIA flap and the free ALT flap were comparable for the reconstruction of post-traumatic, medium-sized soft tissue defects of the hand according to the evaluated outcomes of postoperative complications. Based on the surgical characteristics of the flap and the evaluation of aesthetic outcomes, the pedicled PIA flap was significantly superior to the free ALT flap.

**Abbreviations:** ALT = anterolateral thigh, LCFA = lateral circumflex femoral artery, PIA = posterior interosseous artery.

**Keywords:** anterolateral thigh flap, complication, hand, posterior interosseous artery flap

## 1. Introduction

Complex soft tissue defects of the hand caused by various traumas are the most common defects repaired using hand surgery. Because of the anatomical characteristics and unique functions of the hand,<sup>[1]</sup> complex soft tissue reconstruction poses

a serious challenge to the reconstructive surgeon. As the knowledge of vascular anatomy of the integument increases,<sup>[2]</sup> various skin flaps, including pedicled flaps and free flaps, have been widely used to reconstruct complex soft tissue defects of the hand.<sup>[3,4]</sup> However, to date, the posterior interosseous artery (PIA) flap still plays a pivotal role in the reconstruction of complex soft tissue defects of the hand because of its reliability and simple dissection technique.<sup>[5–12]</sup> Similarly, due to the long vascular pedicle, large flap area, and versatility, the anterolateral thigh (ALT) free flap remain the workhorse flap in the reconstruction of complex soft tissue defects of the hand at many institutions.<sup>[13–20]</sup>

However, increasing numbers of hand surgeons subjectively consider that the pedicled PIA flap failure rate is very high in the reconstruction of complex soft tissue defects of the hand and prefer to use the free ALT flap.<sup>[14,21]</sup> Currently, no published studies have compared the reliability and configuration of the pedicled PIA flap and the free ALT flap used to reconstruct complex soft tissue defects of the hand. A randomized comparison of the pedicled PIA flap and the free ALT flap for reconstruction of post-traumatic, medium-sized soft tissue of the hand was performed to improve the use of the 2 flaps in the reconstruction of post-traumatic, medium-sized soft tissue defects of the hand and to better understand the aesthetic outcomes after soft tissue reconstruction.

The purpose of this study was to examine the differences between the use of a PIA flap and an ALT flap for post-traumatic, medium-sized soft tissue reconstruction of the hand based on flap characteristics, postoperative complications, and aesthetic outcomes.

Editor: Bo Liu.

The authors have no funding and conflicts of interest to disclose.

The datasets generated during and/or analyzed during the present study are publicly available.

<sup>a</sup> Department of Health Management Center, The Affiliated Hospital of Qingdao University, No. 1677 Wutaishan Road, Qingdao, Shandong, China, <sup>b</sup> Department of Hand and Foot Surgery, The First Hospital of Jilin University, No. 76 Xinmin Street, Changchun, Jilin, China, <sup>c</sup> Department of Hand and Foot Surgery, The Affiliated Hospital of Qingdao University, No. 1677 Wutaishan Road, Qingdao, Shandong, China.

\* Correspondence: Fei Gao, Department of Hand and Foot Surgery, The Affiliated Hospital of Qingdao University, No. 1677 Wutaishan Road, Qingdao 266000, Shandong, China (e-mail: gaofei1982424@163.com).

Copyright © 2021 the Author(s). Published by Wolters Kluwer Health, Inc. This is an open access article distributed under the terms of the Creative Commons Attribution-Non Commercial License 4.0 (CCBY-NC), where it is permissible to download, share, remix, transform, and buildup the work provided it is properly cited. The work cannot be used commercially without permission from the journal.

How to cite this article: Ren J, Lu L, Gao F. The use of the posterior interosseous artery flap and anterolateral thigh flap for post-traumatic soft tissue reconstruction of the hand. *Medicine* 2021;100:26(e26517).

Received: 29 October 2020 / Received in final form: 15 April 2021 / Accepted: 11 June 2021

<http://dx.doi.org/10.1097/MD.00000000000026517>

## 2. Patients and methods

### 2.1. Inclusion criteria and study design

This clinical retrospective study was approved by the Institutional Review Board of our hospital. The inclusion criteria for patients were medium-sized soft tissue defects of the hand caused by trauma that were reconstructed using a free ALT flap or a pedicled PIA flap. All patients randomly selected a free ALT flap or a pedicled PIA flap for transplant at the preoperative consultation. Accordingly, we carefully reviewed hospital records and found that 30 pedicled PIA flaps and 32 free ALT flaps had been used to reconstruct post-traumatic, medium-sized soft tissue defects of the hand between October, 2010 and March, 2016. The 62 patients were divided into the pedicled PIA flap group and the free ALT flap group.

A comprehensive chart review was conducted to collect data for preoperative assessments (age, sex, smoking history, comorbidities, preoperative contamination of the wound, and soft tissue defect sites), intraoperative records (interval from injury to flap transfer, operative time, flap width, flap area, and primary closure of the donor site), and postoperative records (perioperative complications and flap bulk swelling). Data on perioperative complications (less than 30 days after surgery) were collected, including flap failure, vascular compromise, postoperative wound infection, subcutaneous hematoma, and wound dehiscence. Flap failure<sup>[22]</sup> was defined as flap primary necrosis of >25% or necrosis that required a second reconstructive surgery for flap survival. Other forms of necrosis were recorded as partial necrosis.

### 2.2. Surgical technique and postoperative management

After thorough and complete debridement, a free ALT flap or a pedicled PIA flap was designed based on the dimension and shape of the soft tissue defects of the hand. Regarding the harvest of the flap, the subfascial dissection technique was utilized to facilitate the identification of optimal cutaneous perforators, and the vascular pedicle was then meticulously dissected. Skin grafting was performed when the donor site was not primarily closed (self-closing).

Standardized and normalized postoperative monitoring and care were performed within 4 days after surgery. An anticoagulant (heparin) was administered during the intraoperative period until the fourth postoperative day. Skin sutures were removed 2 weeks after surgery.

### 2.3. Statistical analysis

The Gaussian distribution of continuous variables was verified using the Shapiro–Wilk test at a significance level of  $P > .05$ . The differences between the ALT flap and the PIA flap groups were analyzed using Student *t* test or the Mann–Whitney *U* test for continuous variables and the chi-square test or Fisher exact test for categorical variables. A *P* value < .05 was defined as statistically significant. IBM SPSS 21.0 software (IBM Corp., Armonk, NY, USA) was used for all statistical analyses.

## 3. Results

The 62 patients included 52 males and 10 females, and the mean age at the time of surgery was 41 years (range, 13–70 years). The basic characteristics of patients who underwent medium-sized

**Table 1**

**Basic characteristics of the 62 patients.**

	Flap type		<i>P</i> value
	Free ALT flap	Pedicled PIA flap	
No. of patients	32	30	
Mean age (range), years*	40 (18–59)	42 (13–70)	.605
Sex <sup>†</sup>			
Male/female	27/5	25/5	1.000
Cigarette smoking <sup>†</sup>	9	7	.667
Hypertension <sup>‡</sup>	3	3	1.000
Diabetes mellitus <sup>‡</sup>	1	0	1.000
Preoperative contamination of the wound <sup>†</sup>	17	12	.301
Laterality <sup>†</sup>			
Left/right hand	9/23	17/13	<b>.023</b>
Soft tissue defect site <sup>†</sup>			
Dorsum of hand	12	23	<b>.006</b>
Palm of hand	8	4	
Palm and back of hand	12	3	

ALT=anterolateral thigh, PIA=posterior interosseous artery.

Bold and italic values indicates  $P < 0.05$ .

\* Student *t* test.

<sup>†</sup> Chi-square test.

<sup>‡</sup> Fisher exact test.

soft tissue reconstruction of the hand using a pedicled PIA flap or a free ALT flap are shown in Table 1. The mean age of the patients in the pedicled PIA flap group was 42 years (range, 13–70 years). The average age of the patients in the free ALT flap group was 40 years (range, 15–59 years). No significant differences in age, sex, cigarette smoking, hypertension, diabetes mellitus, or preoperative contamination of the wound were observed between the 2 groups (Table 1). However, statistically significant differences were detected in the soft tissue defect site ( $P = .006$ ) and laterality ( $P = .023$ ), and the most common site of soft tissue defects was the dorsum of the hand (56.5%, 35/62) (Table 1).

The surgical characteristics of 62 skin flaps are summarized in Table 2. The mean interval from injury to flap transfer was 13 days in the pedicled PIA flap group and 14 days in the free ALT flap group. The mean flap areas of the ALT flap group and the PIA flap group were 126 and 116 cm<sup>2</sup>, respectively. In addition, the interval from injury to flap transfer ( $P = .549$ ) and the flap

**Table 2**

**Surgical characteristics of the 62 skin flaps.**

	Flap type		<i>P</i> value
	Free ALT flap	Pedicled PIA flap	
No. of patients	32	30	
Interval from injury to flap transfer (days)*			
Mean (range)	14 (1–124)	13 (0–48)	.549
Flap area (cm <sup>2</sup> )*			
Mean (range)	126 (56–162)	116 (72–207)	<b>.099</b>
Flap width (cm)*			
Mean (range)	8.8 (7–11)	7.7 (5–10)	<b>.004</b>
Operative time (min)*			
Mean (range)	229 (145–396)	136 (80–205)	<b>&lt;.001</b>
Donor site primary closure (No.) <sup>†</sup>	30	5	<b>&lt;.001</b>

ALT=anterolateral thigh, PIA=posterior interosseous artery.

Bold and italic values indicates  $P < 0.05$ .

\* Mann–Whitney *U* test.

<sup>†</sup> Chi-square test.

**Table 3**  
**Perioperative complications and outcomes of the 62 patients.**

	Flap type		P value
	Free ALT flap	Pedicled PIA flap	
No. of patients	32	30	
Flap failure rate, %, (no.) <sup>*</sup>	9.4% (3)	13.3% (4)	.703
Recipient-site complication rate, %, (no.) <sup>†</sup>	28.1% (9)	40.0% (12)	.323
Postoperative wound infection <sup>†</sup>	6	11	.114
Vascular compromise <sup>†</sup>	4	7	.264
Subcutaneous hematoma <sup>*</sup>	2	1	1.000
Donor-site complication rate, %, (no.) <sup>*</sup>	12.5% (4)	0 (0)	.114
Aesthetic outcomes			
Flap bulk swelling <sup>†</sup>	31	0	<.001

Donor site complications included postoperative wound infection and wound dehiscence.

ALT=anterolateral thigh, PIA=posterior interosseous artery.

<sup>\*</sup> Fisher exact test.

<sup>†</sup> Chi-square test.

area ( $P=.099$ ) were not statistically significantly different between the 2 groups (Table 2). However, the average flap width was 8.8 cm (range, 7–11 cm) in the free ALT flap group and 7.7 cm (range, 5–10 cm) in the pedicled PIA flap group; this difference was statistically significant ( $P=.004$ ). The mean operative time in the free ALT flap group and the pedicled PIA flap group was 229 min (range, 145–396 min) and 136 min (range, 80–205 min), respectively. Self-closing of the donor site was performed in 30 patients in the free ALT flap group and in 5 patients in the pedicled PIA flap group. Statistically significant differences in the operative time and donor site self-closing rate were observed between the 2 groups (Table 2).

Perioperative complications and outcomes are shown in Table 3. Of the 62 skin flaps, the flap failure rate was 11.3% (7/62). The complications of the recipient site were the same in both groups, including flap failure, postoperative wound infection, vascular compromise, subcutaneous hematoma, and wound dehiscence. The flap failure rate was 9.4% (3/32) in the free ALT flap group and 13.3% (4/30) in the pedicled PIA flap group. In the free ALT flap group, 4 flaps required re-exploration within the first 24 to 48 hours after flap transfer because of vascular compromise (arterial thrombosis); 1 free ALT flap was successfully salvaged, whereas 3 free ALT flaps with arterial thrombosis exhibited complete necrosis. In the pedicled PIA flap group, 7 PIA flaps experienced vascular compromise (venous congestion), resulting in partial necrosis (margin necrosis) in 3 cases and flap failure in 4 cases. Postoperative wound infection was the most common complication at the recipient site in the free ALT flap group ( $n=6$ ) and the pedicled PIA flap group ( $n=11$ ). Donor-site complications only occurred in the free ALT flap

group, including postoperative wound infection ( $n=1$ ) and wound dehiscence ( $n=4$ ). As shown in Table 3, the flap failure rate, recipient-site complication rate (postoperative wound infection, vascular compromise, and subcutaneous hematoma), and donor-site complication rate were not statistically significantly different between the 2 groups. In the pedicled PIA flap group, no patient presented flap bulk swelling compared with the free ALT flap group (Fig. 1). In addition, in the free ALT flap group, 31 patients exhibited flap bulk swelling (Fig. 2). This difference was statistically significant ( $P<.001$ ) (Table 3).

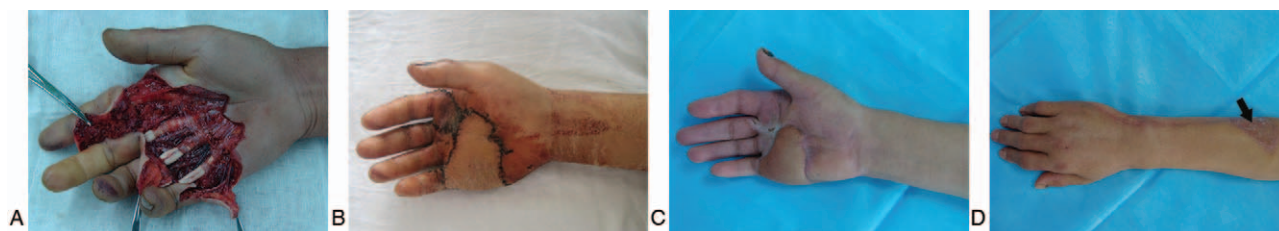
Of the 62 patients, 37 patients continued to be followed, including 20 patients in the free ALT flap group and 17 patients in the pedicled PIA flap group. The mean follow-up period was 10 months (range, 5–38 months). During the follow-up period, no patients experienced pain, cold intolerance, or scar contracture. Functional impairments at the donor sites were not observed. Flap bulk swelling was much more severe in the free ALT flap group than in the PIA flap group (Fig. 3). Compared to the free ALT flap, the PIA flap was more pliable and exhibited a satisfactory skin color and texture (Fig. 3).

**Case 1.** Use of the pedicled PIA flap to repair soft tissue defects of the palm (Fig. 1).

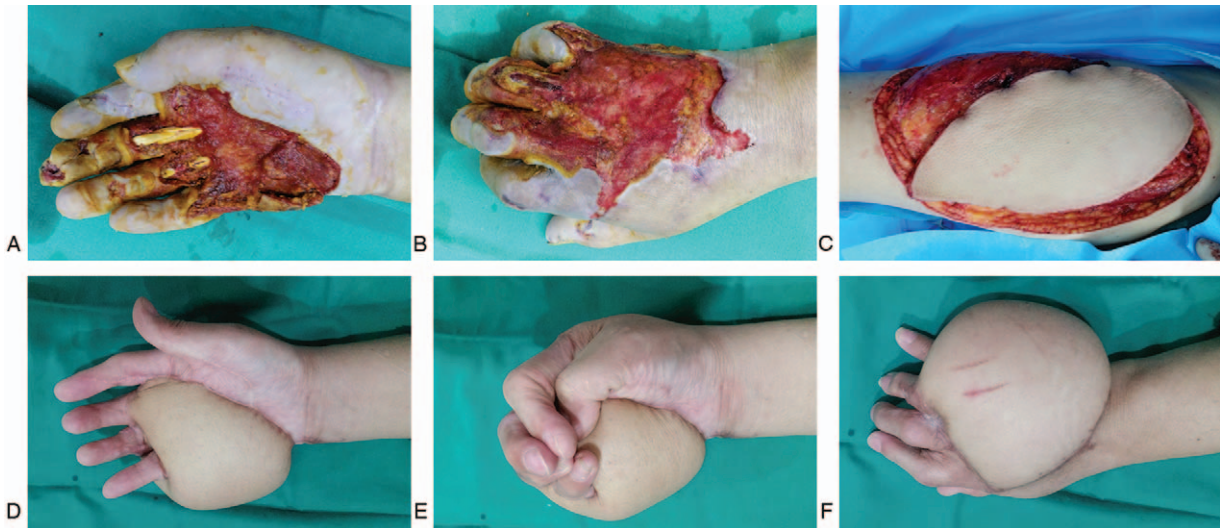
**Case 2.** Soft tissue reconstruction of the palm and back of the hand using the free ALT flap (Fig. 2).

#### 4. Discussion

Of the common conventional skin flaps, the pedicled PIA flap and the free ALT flap have become the workhorse flaps for the reconstruction of complex soft tissue defects of the hand at many



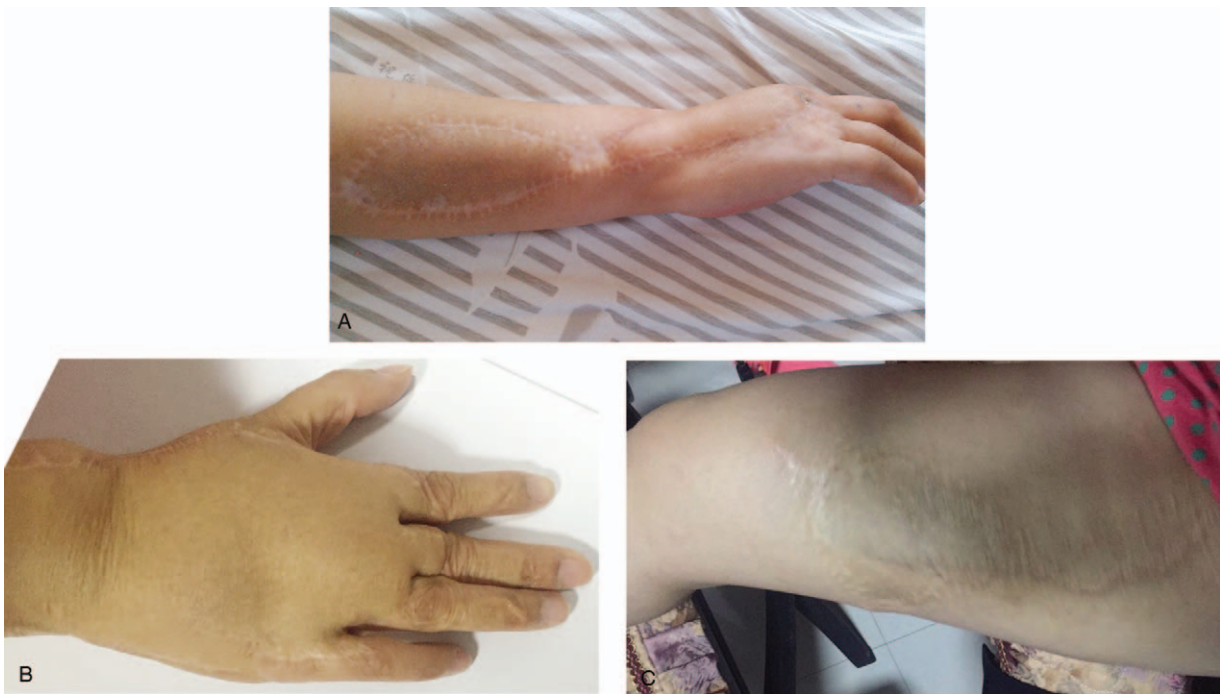**Figure 1.** A pedicled PIA flap was used to reconstruct soft tissue defects of the palm. (A) Soft tissue defect of the palm. (B) The pedicled PIA flap covered the soft-tissue defect of the palm. (C) The result of the recipient site after 2 months. (D) The result of the donor site after 2 months. PIA=posterior interosseous artery.



**Figure 2.** A free ALT flap was used to reconstruct soft tissue defects of the palm and back of the hand. (A) and (B) Soft tissue defects of the palm and back of the hand. (C) Harvest of the free ALT flap. (D) to (F) Results obtained after 8 months. ALT=anterolateral thigh.

institutions.<sup>[3,19]</sup> Currently, no published studies have examined the differences between the pedicled PIA flap and the free ALT flap in the reconstruction of complex soft tissue defects of the hand. In our series, both types of flaps were successfully utilized for the reconstruction of post-traumatic, medium-sized soft tissue defects of the hand, without significant differences in the flap failure rate, recipient site complication rate, and donor site complication rate.

The difference in operative time between the PIA flap group and the ALT flap group was statistically significant (136 vs 229 min). The reason for this difference is that the ALT flap requires complex intramuscular dissection procedures and microvascular anastomoses techniques<sup>[2,3]</sup> compared with the pedicled PIA flap. In addition, the primary closure of the donor site of the flap was determined by the flap width. The maximal flap width required for primary closure was 10 cm in the ALT flap group<sup>[24]</sup> and 6 cm



**Figure 3.** Aesthetic outcomes after reconstruction of soft tissue defects of the dorsal hand. (A) (upper) Result observed 13 months after the pedicled PIA flap transfer. (B) and (C) (lower) Results observed 38 months after the ALT flap transfer; during this period, patients underwent many revision surgical procedures (B: the recipient site of the free ALT flap; C: the donor site of the free ALT flap; and D: a full-thickness skin graft was performed at the donor site of the ALT flap). ALT=anterolateral thigh, PIA=posterior interosseous artery.

**Table 4****Comparison of the use of the pedicled PIA flap and the free ALT flap for post-traumatic, medium-sized soft tissue reconstruction of the hand.**

	Pedicled PIA flap	Free ALT flap
Dominant vascular pedicle	Posterior interosseous flap	Branches of the descending branch of the LCFA
Characteristic of the vascular pedicle	Relatively consistent	Relatively consistent
Maximal flap width required for primary closure (cm)	6 <sup>[29]</sup>	10 <sup>[28]</sup>
Skin paddle thickness	Much thinner than the ALT flap	Much thicker than the PIA flap
Operative time	Short (approximately 2 h)	Long (approximately 4 h)
Flap dissection	Simple	Complex intramuscular dissection procedures
Microvascular anastomoses technique	Not required	Required
Flap bulk swelling	No	Yes
Revision surgery	No	Yes
Aesthetic outcomes after reconstruction (hand)	Superior	Inferior

ALT = anterolateral thigh, LCFA = lateral circumflex femoral artery, PIA = posterior interosseous artery.

in the PIA flap group.<sup>[25]</sup> In our series, the difference in flap width between the PIA flap group and the ALT flap group was significant (7.7 vs 8.8 cm). Additionally, the primary closure rate of the donor site in the PIA flap group was significantly inferior to the primary closure rate in the ALT flap group.

Although research on the PIA flap and the ALT flap has exhibited great progress, complications of the pedicled PIA flap and the free ALT flap, particularly skin flap failure, are not uncommon. The complication rate in the pedicled PIA flap group was 8.5% to 27.5%,<sup>[12,26,27]</sup> and the free ALT flap failure rate was 4.32%.<sup>[28]</sup> In addition, the aesthetic outcomes obtained in the pedicled PIA flap group after the reconstruction of the medium-sized soft tissue defects were significantly superior to outcomes obtained in the free ALT flap group, because the thickness of the skin paddle provided by the PIA flap is much thinner than that provided by the ALT flap. The thickness of the skin paddle provided by the ALT flap was 1 to 3 cm.<sup>[29]</sup> The ALT flap used to reconstruct the soft tissue defects of the hand required multiple revision surgical procedures to achieve the desired aesthetic outcomes, which may increase the suffering of and financial burden on the patients. In addition, although a thinning technique has been reported to make this flap suitable for hand reconstruction, the technique may increase the difficulty of the operation and the risk of partial flap necrosis.<sup>[29]</sup> Table 4 illustrates the comparison of the results obtained with the pedicled PIA flap and the free ALT flap for post-traumatic, medium-sized soft tissue reconstruction of the hand.

In this study, the data of 2 groups are comparable. Firstly, the age at the time of surgery, sex, cigarette smoking, hypertension, diabetes mellitus, and preoperative contamination of the wounds were not significantly different between the 2 groups (Table 1). In addition, the flap areas of the PIA flap group and the ALT flap group should be analogous to reduce the extent of the differences caused by the flap area. In this study, the mean flap areas of the ALT flap group and the PIA flap group were 126 and 116 cm<sup>2</sup>, respectively, and statistically significant differences were not observed between the 2 groups (Table 2).

This study had several limitations. First, the population of patients in our series was heterogeneous. The small sample population may have increased the standard errors, and confounding variables may also have affected the outcomes of our study. Second, the flap transfer procedures were performed by multiple hand surgeons, and thus we recognize that the measurement of the flap area may have some variation. Finally, postoperative complications detected during the perioperative

period were determined in a subjective manner that relied on the experience of the hand surgeons, and this bias may also have increased the sampling error.

## 5. Conclusions

Both the pedicled PIA flap and the free ALT flap were comparable for the reconstruction of post-traumatic, medium-sized soft tissue defects of the hand, according to the evaluated outcomes of postoperative complications. Based on the surgical characteristics of the flap and the evaluation of aesthetic outcomes, the pedicled PIA flap was significantly superior to the free ALT flap.

## Author contributions

**Conceptualization:** Fei Gao.

**Data curation:** Jinyan Ren, Fei Gao.

**Formal analysis:** Jinyan Ren.

**Investigation:** Laijin Lu.

**Methodology:** Laijin Lu, Fei Gao.

**Resources:** Laijin Lu.

**Software:** Jinyan Ren.

**Supervision:** Laijin Lu, Fei Gao.

**Writing – original draft:** Fei Gao.

**Writing – review & editing:** Jinyan Ren, Fei Gao.

## References

- Rehim SA, Kowalski E, Chung KC. Enhancing aesthetic outcomes of soft-tissue coverage of the hand. *Plast Reconstr Surg* 2015;135:413e–28e.
- Morris SF, Tang M, Almutari K, Geddes C, Yang D. The anatomic basis of perforator flaps. *Clin Plast Surg* 2010;37:553–70. xi.
- Yannascoli SM, Thibaudeau S, Levin LS. Management of soft tissue defects of the hand. *J Hand Surg Am* 2015;40:1237–44. quiz 1245.
- Miller EA, Friedrich J. Soft tissue coverage of the hand and upper extremity: the reconstructive elevator. *J Hand Surg Am* 2016;41:782–92.
- Zaidenberg EE, Farias-Cisneros E, Pastrana MJ, Zaidenberg CR. Extended posterior interosseous artery flap: anatomical and clinical study. *J Hand Surg Am* 2017;42:182–9.
- Fong PL, Chew WY. Posterior interosseous artery flap: our experience and review of modifications done. *Hand Surg* 2014;19:181–7.
- Wang JQ, Cai QQ, Yao WT, Gao ST, Wang X, Zhang P. Reverse posterior interosseous artery flap for reconstruction of the wrist and hand after sarcoma resection. *Orthop Surg* 2013;5:250–4.
- Acharya AM, Bhat AK, Bhaskaranand K. The reverse posterior interosseous artery flap: technical considerations in raising an easier and more reliable flap. *J Hand Surg Am* 2012;37:575–82.

- [9] El-Sabbagh AH, Zeina AA, El-Hadidy AM, El-Din AB. Reversed posterior interosseous flap: safe and easy method for hand reconstruction. *J Hand Microsurg* 2011;3:66–72.
- [10] Gong X, Lu LJ. Reconstruction of severe contracture of the first web space using the reverse posterior interosseous artery flap. *J Trauma* 2011;71:1745–9.
- [11] Gavaskar AS. Posterior interosseous artery flap for resurfacing posttraumatic soft tissue defects of the hand. *Hand (N Y)* 2010;5:397–402.
- [12] Lu LJ, Gong X, Lu XM, Wang KL. The reverse posterior interosseous flap and its composite flap: experience with 201 flaps. *J Plast Reconstr Aesthet Surg* 2007;60:876–82.
- [13] Wang HT, Erdmann D, Fletcher JW, Levin LS. Anterolateral thigh flap technique in hand and upper extremity reconstruction. *Tech Hand Up Extrem Surg* 2004;8:257–61.
- [14] Javaid M, Cormack GC. Anterolateral thigh free flap for complex soft tissue hand reconstructions. *J Hand Surg Br* 2003;28:21–7.
- [15] Tang L, Pafitanis G, Yang P, et al. Combined multi-lobed flaps: a series of 39 extensive hand and multi-digit injuries one-staged reconstructions using modified designs of ALT, DPA and chimeric linking flaps. *Injury* 2017;48:1527–35.
- [16] Meky M, Safoury Y. Composite anterolateral thigh perforator flaps in the management of complex hand injuries. *J Hand Surg Eur Vol* 2013;38:366–70.
- [17] Adani R, Tarallo L, Marcoccio I, Fregni U. First web-space reconstruction by the anterolateral thigh flap. *J Hand Surg Am* 2006;31:640–6.
- [18] Adani R, Tarallo L, Marcoccio I, Cipriani R, Gelati C, Innocenti M. Hand reconstruction using the thin anterolateral thigh flap. *Plast Reconstr Surg* 2005;116:467–73. discussion 474–7.
- [19] Friedrich JB, Pederson WC, Bishop AT, Galaviz P, Chang J. New workhorse flaps in hand reconstruction. *Hand (N Y)* 2012;7:45–54.
- [20] Yazar S, Gideroglu K, Kilic B, Gokkaya A. Use of composite anterolateral thigh flap as double-vascularised layers for reconstruction of complex hand dorsum defect. *J Plast Reconstr Aesthet Surg* 2008;61:1549–50.
- [21] Ali RS, Bluebond-Langner R, Rodriguez ED, Cheng MH. The versatility of the anterolateral thigh flap. *Plast Reconstr Surg* 2009;124:e395–395e407.
- [22] Tajsic N, Winkel R, Husum H. Distally based perforator flaps for reconstruction of post-traumatic defects of the lower leg and foot. A review of the anatomy and clinical outcomes. *Injury* 2014;45:469–77.
- [23] Kayano S, Sakuraba M, Miyamoto S, et al. Comparison of pedicled and free anterolateral thigh flaps for reconstruction of complex defects of the abdominal wall: review of 20 consecutive cases. *J Plast Reconstr Aesthet Surg* 2012;65:1525–9.
- [24] Boca R, Kuo YR, Hsieh CH, Huang EY, Jeng SF. A reliable parameter for primary closure of the free anterolateral thigh flap donor site. *Plast Reconstr Surg* 2010;126:1558–62.
- [25] Costa H, Pinto A, Zenha H. The posterior interosseous flap – a prime technique in hand reconstruction. The experience of 100 anatomical dissections and 102 clinical cases. *J Plast Reconstr Aesthet Surg* 2007;60:740–7.
- [26] Cheema TA, Lakshman S, Cheema MA, Durrani SF. Reverse-flow posterior interosseous flap – a review of 68 cases. *Hand (N Y)* 2007;2:112–6.
- [27] Neuwirth M, Hubmer M, Koch H. The posterior interosseous artery flap: clinical results with special emphasis on donor site morbidity. *J Plast Reconstr Aesthet Surg* 2013;66:623–8.
- [28] Wei FC, Jain V, Celik N, Chen HC, Chuang DC, Lin CH. Have we found an ideal soft-tissue flap? An experience with 672 anterolateral thigh flaps. *Plast Reconstr Surg* 2002;109:2219–26. discussion 2227–30.
- [29] Agostini T, Lazzeri D, Spinelli G. Anterolateral thigh flap thinning: techniques and complications. *Ann Plast Surg* 2014;72:246–52.