

## CASE REPORT

# High-density mapping to guide ablation of a right bundle branch morphology premature ventricular contraction from the right outflow tract

Antonio De Simone<sup>1</sup>, Vincenzo La Rocca<sup>1</sup>, Alfonso Panella<sup>1</sup>, Valter Bianchi<sup>2</sup>, Francesco Maddaluno<sup>3</sup>, Giuseppe Stabile<sup>4</sup>  & Ignacio Garcia Bolao<sup>5</sup>

<sup>1</sup>Clinica San Michele, Maddaloni, Italy

<sup>2</sup>Ospedale Monaldi, Naples, Italy

<sup>3</sup>Boston Scientific Italia, Milan, Italy

<sup>4</sup>Clinica Mediterranea, Naples, Italy

<sup>5</sup>Clinica Universidad de Navarra, Pamplona, Spain

### Correspondence

Giuseppe Stabile, Laboratorio di Elettrofisiologia, Clinica Mediterranea, Via Orazio 2, 80100 Napoli, Italy. Tel: +390817259641; Fax: +390817259777; E-mail: gmrstabile@tin.it

### Funding Information

No sources of funding were declared for this study.

Received: 5 October 2017; Revised: 6 December 2017; Accepted: 10 December 2017

*Clinical Case Reports* 2018; 6(6): 1060–1065

doi: 10.1002/ccr3.1370

## Introduction

Most premature ventricular contractions (PVCs) with precordial transition  $\geq V4$  are eliminated ablating in the right ventricular outflow tract RVOT, and those transitioning  $\leq V2$  are eliminated with lesions at the left ventricular outflow tract (LVOT) [1]. The complete abolition of a right bundle branch morphology PVC (precordial transition  $\geq V1$ ) from the RVOT has been very rarely described [2]. We report the use of an automated high-density 3D mapping system to map the dominant RBBB morphology PVC in a patient presenting with multiple PVCs.

## Case Report

A 35-year-old woman implanted with a subcutaneous implantable cardioverter defibrillator for a life-threatening ventricular tachycardia (VT) was referred to our institution

### Key Clinical Message

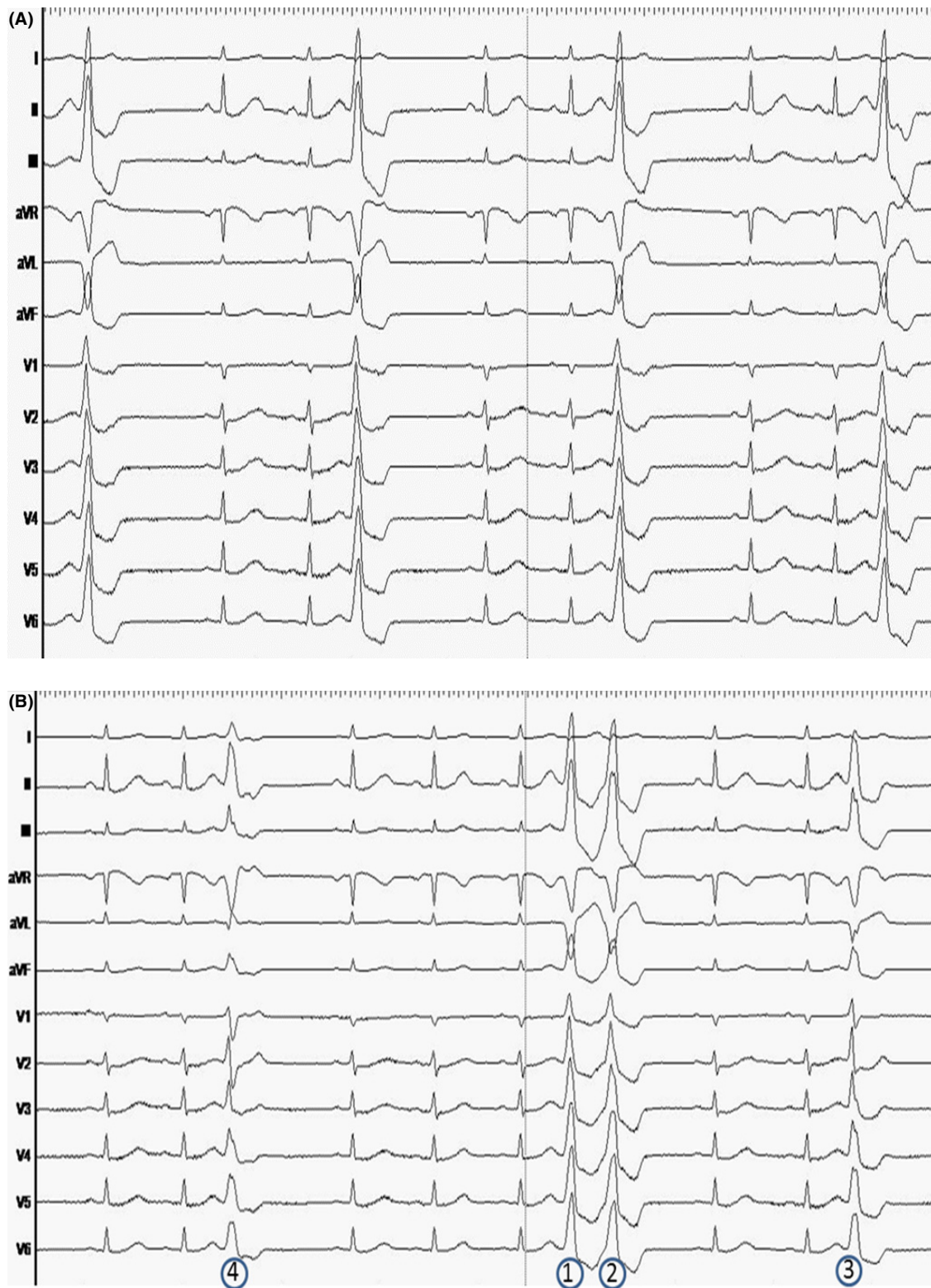The Rhythmia ultrahigh-density mapping system with a specific algorithm seems to be helpful in identifying the target area to successfully treat multiple morphologies by catheter ablation in the right ventricular outflow tract RVOT. Interestingly, the acquisition process seemed to be extremely faster than a standard manual point-by-point premature ventricular contraction (PVC) mapping.

### Keywords

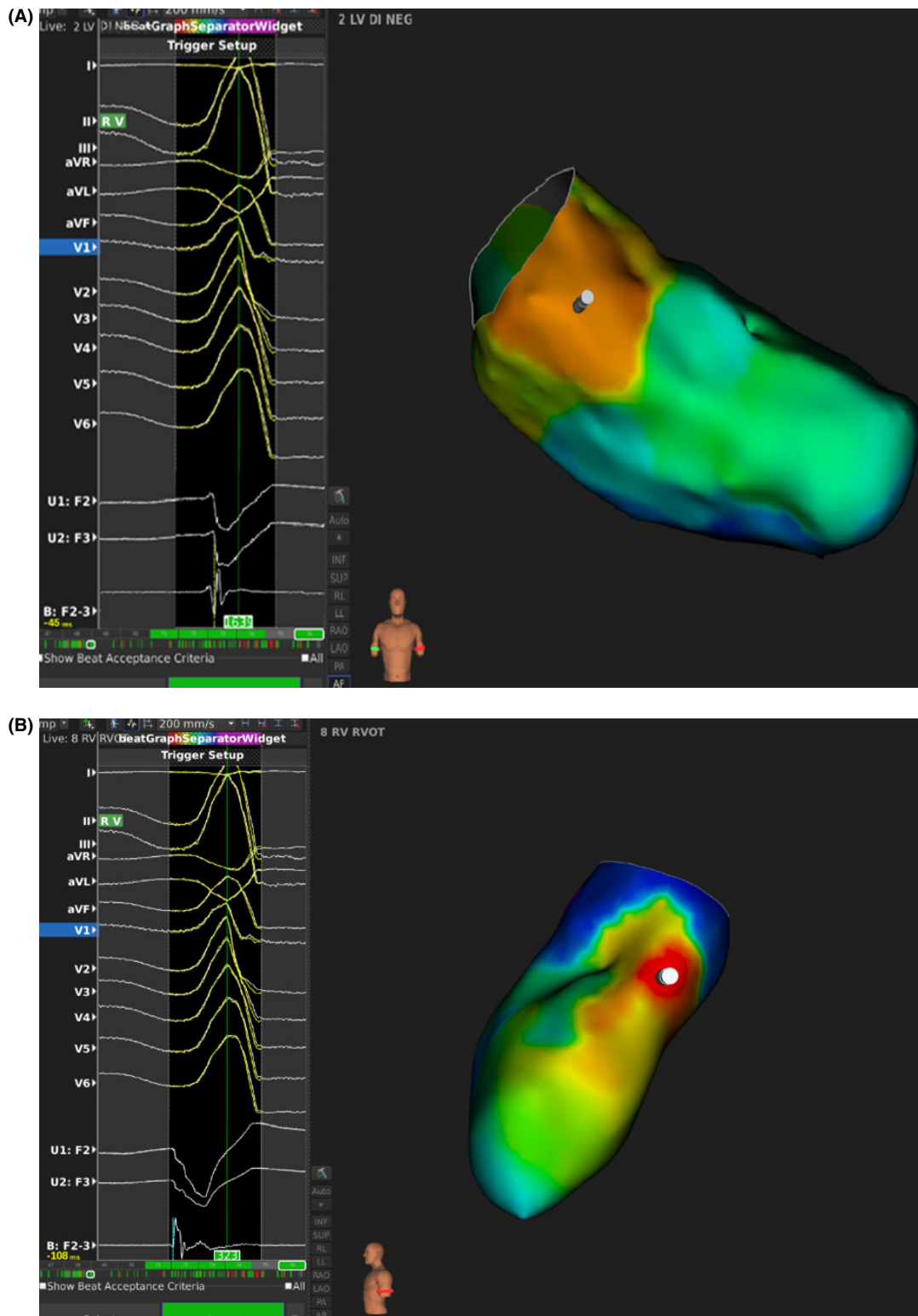
Catheter ablation, high-density mapping, premature ventricular contractions, Rhythmia.

for PVC ablation. Her electrocardiogram (ECG) showed sinus rhythm with frequent ventricular premature depolarizations. The dominant PVC showed RBBB morphology pattern with high amplitude R wave in DII and DIII and slightly negative complex in DI (Fig. 1A). Other PVCs were also observed, and some of them presented very subtle changes compared to the dominant one (Fig. 1B) posing additional challenges to the mapping process.

The dominant PVC was mapped with the Rhythmia mapping system (Boston Scientific, Inc, Cambridge, MA) using the Orion<sup>TM</sup> multipolar basket catheter (64 electrodes of 0.4 mm<sup>2</sup> area; 2.5 mm spacing) (Boston Scientific, Inc, Cambridge, MA) The system automatically collected chamber geometry and electrograms (EGMs) using the operator-defined beat acceptance criteria as follows: (1) respiration gating, (2) stable catheter location, (3) electrocardiographic (ECG) QRS morphology (ECG metric), (4) tracking quality.



**Figure 1.** (Panel A) Dominant PVC with RBBB morphology and high amplitude R wave in DII and DIII ( $1.8 \pm 0.3$  mV). (Panel B) PVC number 1 was the dominant one and was targeted for ablation. PVC number 2 was very similar to the clinical one but was slightly different (note the larger QRS width) and so needed to be rejected in the activation map. PVC number 3 and 4 were two additional PVCs that were observed in this patient.



**Figure 2.** (Panel A) Activation map of the LVOT in the anteroposterior projection. A representative EGM of the broad orange area that had earliest activation time was shown in the lower left corner. (Panel B) Activation map of the RVOT in the left lateral projection. The EGM found at the earliest point in the most leftward aspect of the septal RVOT was shown in the left lower corner.

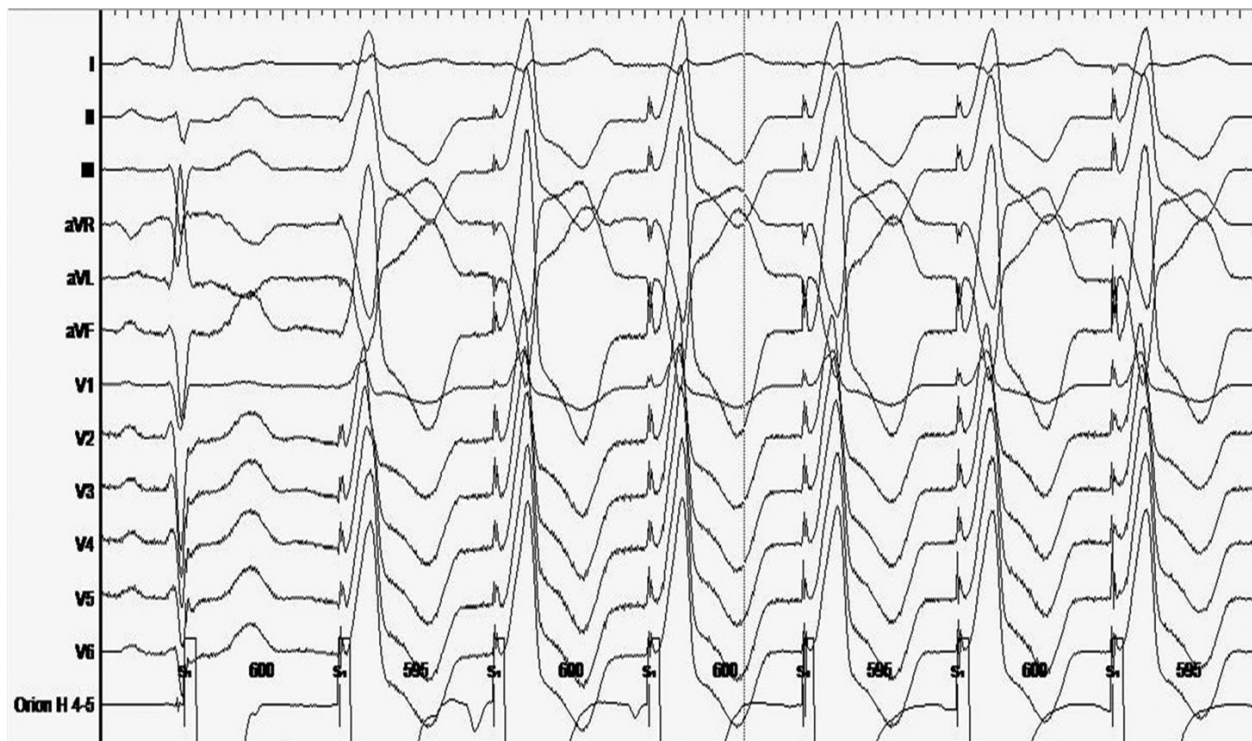
For annotation of the local activation time of each acquired bipolar EGM, the system combines unipolar (maximum negative  $dV/dt$ ) and bipolar (maximum amplitude) EGMs. For multiple potentials and fractionated EGMs, the system annotates timing using a proprietary algorithm which considers the timing of surrounding EGMs. The mapping window can be adjusted (to focus on clinically relevant parts of the tachycardia cycle) at any time without loss of information, and all points are re-annotated near instantaneously. Scar setting may be finely tuned with the confidence mask tool (points in the immediate surrounding area with EGM bipolar amplitude below the confidence mask have no color code and are displayed in gray color).

The LVOT was mapped first using both a trans-septal and a retrograde approach. In particular, the aortic cusps, the mitral annulus, and the endocardial LVOT were mapped. The earliest activating area we found was a broad anteroseptal region whose activation was never before the QRS complex (Fig. 2A). Considering the RBBB morphology and the lack of any early ventricular EGM in the left ventricle, we suspected an epicardial origin of the PVC. For this reason, we tried to advance the coronary sinus (CS) diagnostic 6F catheter (Dynamic XT; Boston Scientific, Inc, Cambridge, MA) in the great cardiac vein

(GCV) and then into the anterior interventricular vein (AIV). Because of difficult CS anatomy, we could only map the proximal part of the GCV where the ventricular EGM was slightly in advance with respect to the QRS onset during the clinical PVC. So, we decided to map the right ventricle. In the most leftward aspect of the septal RVOT, just beneath the pulmonary valve, we found a very early activation (30 msec before QRS onset) (Fig. 2B) where we delivered radiofrequency ablation (40 Watts for 3 min) by means of an irrigated 4-mm tip catheter (Intella NAV OI; Boston Scientific, Inc, Cambridge, MA) and observed suppression of all PVCs. The pacemapping performed at high current from the site of successful ablation is shown in Figure 3. A 24-h ECG Holter monitoring, performed after 3 months, showed only 22 PVCs.

## Discussion

The ECG is the basic tool to predict the site of origin of a PVC and plan the ablation strategy. Then, activation mapping is used to precisely and accurately localize the earliest site of activation where radiofrequency ablation is delivered. In our case, the patient presented with different PVC morphologies, but the RBBB morphology pattern of



**Figure 3.** The pacemapping performed at high current from the site of successful ablation shows a very similar ECG morphology to the dominant PVC.

the dominant one, was strongly suggestive of a left origin [1]. Nonetheless, endocardial mapping found the earliest site of activation on the septal RVOT.

The findings of this case can be explained by an epicardial focus anatomically close to the most leftward aspect of the septal RVOT with different exit sites that gave rise to multiple PVC morphologies. The deep penetration of the radiofrequency energy from the earliest ventricular activation site, in the septal RVOT to the epicardial focus, led to the abolition of all PVCs.

The most leftward aspect of the septal RVOT is in close anatomical relationship with an epicardial region of the left ventricle named left ventricular summit (LVS) that has been reported to be a major source of origin of idiopathic ventricular arrhythmias. The LVS is a triangular portion of the epicardial LVOT bounded by the bifurcation between the left anterior descending and the left circumflex coronary arteries and transected laterally by the GCV at its junction with the AIV [3]. The most leftward septal RVOT is in close proximity to the AIV and the left anterior descending artery and can extend more anteriorly and leftward to the sinuses of Valsalva.

Some authors have reported that VTs originating from one focus in the LVS can present with multiple morphologies due to different exit sites [4–6]. PVCs from this area are often targeted from the CS system (AIV/GCV) but can also be accessed directly via pericardial puncture. Both approaches can be limited by inability to advance the catheter to the site of interest, inadequate power delivery, and proximity to coronary arteries. For these reasons, ablation from the endocardium can be preferred and some authors reported successful abolition of LVS PVCs from adjacent endocardial structures including the septal RVOT [7].

Our case is in line with the findings of these authors and confirms the usefulness of mapping the septal RVOT in patients presenting with dominant RBBB morphology PVCs and no early activations in the LVOT.

The use of an automated high-density mapping system was extremely useful in this complex case both for automatically rejecting nonclinical PVC morphologies and for speeding up the acquisition of multiple activation maps.

When mapping premature ventricular depolarization, extreme care is needed to ensure that only the relevant PVC morphology is being mapped and to exclude fused beats, different morphology, or catheter ectopy in order to avoid “multiple” early points in the activation map. Using the Rhythmia system, this is automatically accomplished by a correlation-based criteria (the ECG metric), aimed at computing the similarity between the 12-lead ECG from a given beat and a user-defined “favorite beat.” In our case, the favorite beat was strictly adjusted to target the clinical PVC and was the only tool we used to rule

out the other PVCs from the activation map. In this case, the application of this automatic tool accurately rejected nonclinical PVCs, even if they presented with very subtle changes compared to the dominant PVC.

In addition to that, the high-density of points acquired for each accepted clinical PVC morphology beat led to a very fast acquisition of the activation maps despite the rejection of multiple beats (nonclinical PVCs and sinus beats). The acquisition process seemed to be extremely faster than a standard manual point-by-point PVC mapping.

## Conclusion

This case report suggested that RBBB morphology PVC in patients presenting with multiple morphologies can be successfully treated by catheter ablation in the RVOT. A high-density mapping with a specific algorithm seems to be helpful in identifying the target area of RF ablation.

## Conflict of Interest

F. Maddaluno is a Boston Scientific employee, no other conflicts of interest exist.

## Authorship

AD: performed the procedure, interpreted the data, and drafted the manuscript. AP: performed the procedure, assisted in signals acquisition and interpretation, and helped to draft the manuscript. VL and VB: planned the procedure, assisted in signals acquisition and interpretation, and helped to draft the manuscript. FM: provided technical support during the procedure, reviewed the literature, and critically reviewed the manuscript. GS and GB: reviewed the literature, provided additional supervision, and critically reviewed the manuscript.

## References

1. Hutchinson, M. D., and F. C. Garcia. 2013. An organized approach to the localization, mapping, and ablation of outflow tract ventricular arrhythmias. *J. Cardiovasc. Electrophysiol.* 24:1189–1197.
2. Frankel, D. S., S. E. Mountantonakis, M. I. Dahu, and F. E. Marchlinski. 2014. Elimination of ventricular arrhythmias originating from the anterior interventricular vein with ablation in the right ventricular outflow tract. *Circ. Arrhythm. Electrophysiol.* 7:984–985.
3. Santangeli, P., F. E. Marchlinski, E. S. Zado, D. Benhayon, M. D. Hutchinson, D. Lin, et al. 2015. Percutaneous epicardial ablation of ventricular arrhythmias arising from the left ventricular summit: outcomes and electrocardiogram correlates of success. *Circ. Arrhythm. Electrophysiol.* 8:337–343.

4. Wang, Y. B., J. Ma, J. Z. Dong, R. Bai, J. Wang, S. N. Li, et al. 2015. Catheter ablation of premature ventricular contractions originating from the aortic cusps or great cardiac vein: two QRS morphologies with one origin. *Pacing Clin. Electrophysiol.* 38:1029–1038.
5. Ma, J., K. X. Wu, Y. B. Wang, C. S. Ma, and J. M. Chu. 2016. Premature ventricular contractions with two QRS morphologies originate from one focus in great cardiac vein. *Heart Rhythm Case Rep.* 2:204–207.
6. Dan Do, V. B., S. L. Chang, Y. J. Lin, and S. A. Chen. 2015. Shift of exit site during ablation of ventricular tachycardia originating from the vicinity of left ventricular summit. *J. Cardiovasc. Electrophysiol.* 26:90–92.
7. Enriquez, A., F. Malavassi, L. C. Saenz, G. Supple, P. Santangeli, F. E. Marchlinski, et al. 2017. How to map and ablate left ventricular summit arrhythmias. *Heart Rhythm* 14:141–148.