

## ORIGINAL RESEARCH

# Change in chorda tympani nerve function after two-stage tympanoplasty for cholesteatoma

Riu Nishimura MD<sup>1</sup>  | Shinya Miuchi MD, PhD<sup>1</sup> | Miki Ikehata MD, PhD<sup>2</sup> | Masafumi Sakagami MD, PhD<sup>1</sup> | Kenzo Tsuzuki MD, PhD<sup>1</sup>

<sup>1</sup>Department of Otorhinolaryngology – Head and Neck Surgery, Hyogo Medical University, Hyogo, Japan

<sup>2</sup>Department of Otolaryngology, Amagasaki Chuo Hospital, Hyogo, Japan

**Correspondence**

Riu Nishimura, Department of Otorhinolaryngology – Head and Neck Surgery, Hyogo Medical University, 1-1 Mukogawa, Nishinomiya, Hyogo 663-8501, Japan.  
Email: [ri-nishimura@hyo-med.ac.jp](mailto:ri-nishimura@hyo-med.ac.jp)

**Abstract**

**Objectives:** Chorda tympani nerve (CTN) function may be damaged more by two-stage than by one-stage surgery for middle ear cholesteatoma. However, few studies have reported the relationship between two-stage cholesteatoma surgery and CTN function. This study aimed to investigate CTN function after two-stage surgery for cholesteatoma.

**Methods:** In this prospective study, 35 patients underwent two-stage canal wall up tympanoplasty (CWUT). Perioperative CTN function was assessed using questionnaires and electrogustometry (EGM). Participants were categorized into minor, major, and section groups, based on the degree of CTN manipulation during surgery.

**Results:** In the first-stage surgery, posterior tympanotomy with an intact canal wall reduced the degree of CTN manipulation. The incidence of taste disorder after the first-stage surgery was 71.4%. Postoperative taste disorder and the EGM threshold improved early in the minor manipulation group. In the second-stage surgery, no new CTN damage occurred, even if this surgery involved removal of residual cholesteatoma. The incidence of taste disorder after second-stage surgery was less than that after first-stage surgery, independent of CTN preservation. However, the recovery rate of the EGM threshold after second-stage surgery was significantly lower in the section group than in those with CTN preservation.

**Conclusion:** CTN function, including symptoms and EGM threshold, can be preserved during two-stage cholesteatoma surgery if care is taken to preserve the CTN in both the first- and second-stage surgeries. A two-stage CWUT, ensuring an intact bony annulus, may be effective to facilitate CTN preservation.

**Level of Evidence:** 2b.

**KEYWORDS**

canal wall up tympanoplasty, chorda tympani nerve, middle ear cholesteatoma, taste disorder, two-stage surgery

This is an open access article under the terms of the [Creative Commons Attribution-NonCommercial-NoDerivs](https://creativecommons.org/licenses/by-nc-nd/4.0/) License, which permits use and distribution in any medium, provided the original work is properly cited, the use is non-commercial and no modifications or adaptations are made.

© 2022 The Authors. *Laryngoscope Investigative Otolaryngology* published by Wiley Periodicals LLC on behalf of The Triological Society.

## 1 | INTRODUCTION

Middle ear cholesteatoma is caused by multiple factors, such as eustachian tube dysfunction, ventilatory failure of the mastoid air cells, and prolonged otitis media.<sup>1,2</sup> Thus, a case-specific surgery is required.<sup>3,4</sup> Canal wall up tympanoplasty (CWUT) allows removal of cholesteatoma while retaining the canal wall intact. It has the advantages of a short postoperative period for ear dryness and placing a small burden on patients. In contrast, residual rates of 26.0%–43.4% have been reported with two-stage CWUT.<sup>5–8</sup> Therefore, we planned a two-stage surgery in case the cholesteatoma might be residual.

Generally, cholesteatoma surgery aims to eradicate cholesteatoma, produce a dry ear, and restore hearing. Therefore, most previous studies on cholesteatoma surgery have focused on recidivism, as well as hearing outcomes.<sup>5–9</sup> However, taste disorder after middle ear surgery is a well-recognized complication. The chorda tympani nerve (CTN) branches from the facial nerve, runs close to the tympanic annulus, crosses the tympanic cavity, and finally reaches the tongue; it innervates the taste buds in the anterior two-thirds of the tongue on each side. Due to the complicated structure around the CTN, removal of cholesteatoma without CTN manipulation is difficult.<sup>10</sup> The CTN may be sacrificed for some reasons during middle ear surgery, including removal of the cholesteatoma or the adhesive eardrum, drilling the bony annulus of the tympanic membrane, and performing posterior tympanotomy. Even if the CTN is not sectioned, damage by touching, stretching, and desiccation can cause postoperative taste disorder.<sup>10–13</sup> According to previous reports, the incidence of taste disorder after cholesteatoma surgery ranged from 23.8% to 71.4% when the CTN was preserved.<sup>14,15</sup>

The risk of postoperative CTN dysfunction was predicted to be higher after two-stage surgery than after one-stage surgery. However, to the best of our knowledge, no previous study has investigated the relationship between two-stage surgery for cholesteatoma and CTN function. This study attempted to assess CTN function after two-stage CWUT for cholesteatoma and discuss the procedure for preserving the CTN function.

## 2 | MATERIALS AND METHODS

### 2.1 | Ethical approval

This study strictly followed the revised version of the Declaration of Helsinki (2013). The study design was approved by the Ethics Committee of Hyogo Medical University (No. 3212). Written informed consent was obtained from all participants.

### 2.2 | Patients

This study was conducted at the Department of Otolaryngology–Head and Neck Surgery, Hyogo Medical University (Hyogo, Japan), between April 2019 and April 2022. Thirty-five patients (24 men, 11 women) who underwent planned two-stage CWUT for otitis media

cholesteatoma were analyzed. Their ages ranged from 14 to 74 years (mean age: 44.1 years). Of these, 28 had pars flaccida cholesteatoma, six had pars tensa cholesteatoma, and one had cholesteatoma secondary to eardrum perforation. Patients who had undergone previous ear surgeries were excluded. Thirty patients completed the second-stage surgery and had stable taste symptoms. Five patients had completed the first-stage surgery and were awaiting the second-stage surgery. The status of the contralateral ear was a retraction pocket in sixteen ears, normal findings in seven ears, cholesteatoma in six ears, postoperative ear in five ears, and eardrum perforation in one ear.

### 2.3 | Surgical procedure

In the first-stage surgery, cholesteatoma and inflammatory granulation were removed with canal wall up mastoidectomy and posterior tympanotomy (Figure 1A–C). Lesions around the stapes were removed using a posterior tympanotomy whenever possible (Figure 2A). If the ossicles were difficult to identify with posterior tympanotomy because of severe granulation or cholesteatoma, the lesions were approached using a transcanal approach (Figure 2B). When the transcanal approach was used, the bony annulus of the tympanic membrane was partially removed in most cases. After removing the cholesteatoma, the bone defect of the tympanic scutum or bony annulus was reconstructed using a strip of sliced auricular cartilage. CTN palpation was unavoidable in all surgeries, and it was preserved whenever possible, although it was sacrificed if the lesion was severe.

Participants were categorized into the preservation and section groups based on their CTN status. The preservation group was divided into minor and major manipulation groups based on the degree of CTN manipulation. The CTN was only touched in the minor manipulation group without significant stretching, and the CTN was significantly stretched in the major manipulation group without severing.

Second-stage surgery was performed 1 year after the first-stage surgery. Residual cholesteatoma was explored with endoscopic assistance. Any residual cholesteatoma was removed, and ossiculoplasty was performed (Figure 1D,E).

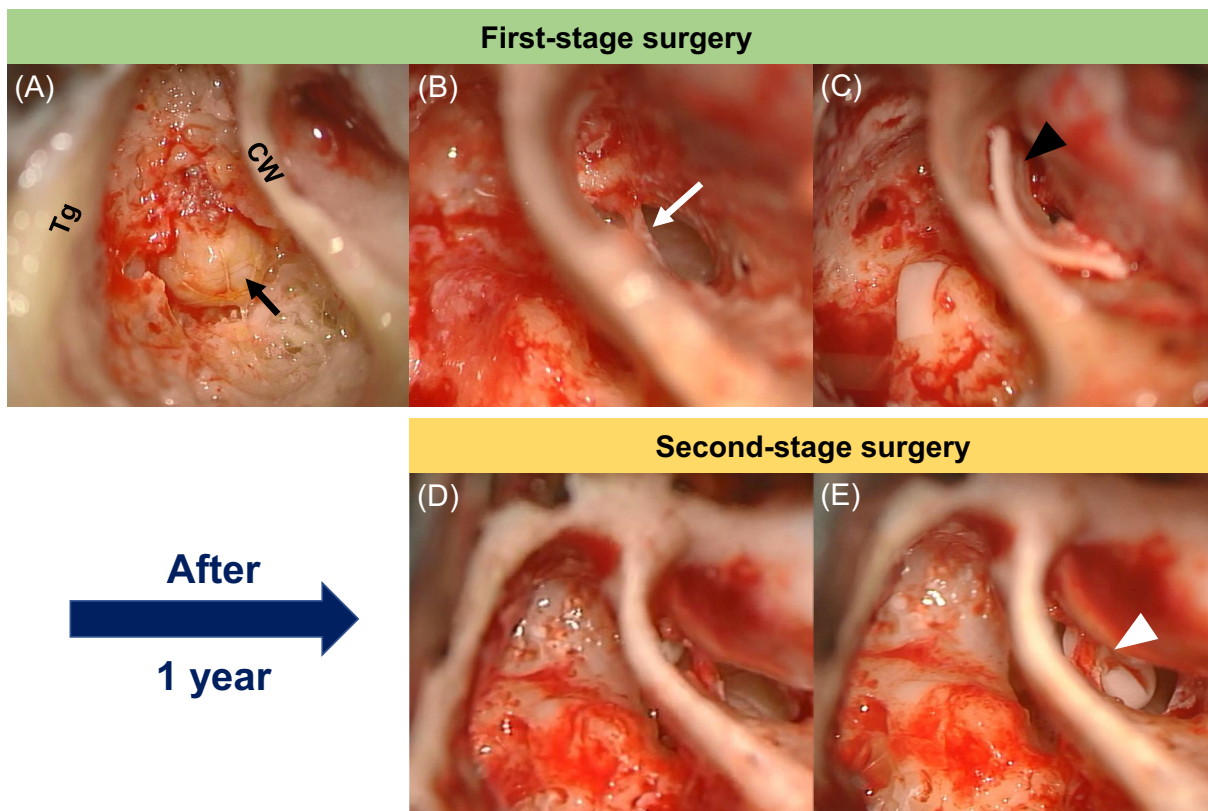
### 2.4 | Surgical findings

This study investigated whether the type of cholesteatoma and surgical management around the CTN during the first-stage surgery affected CTN status. The relationship between residual cholesteatoma and CTN status during the second-stage surgery was also analyzed.

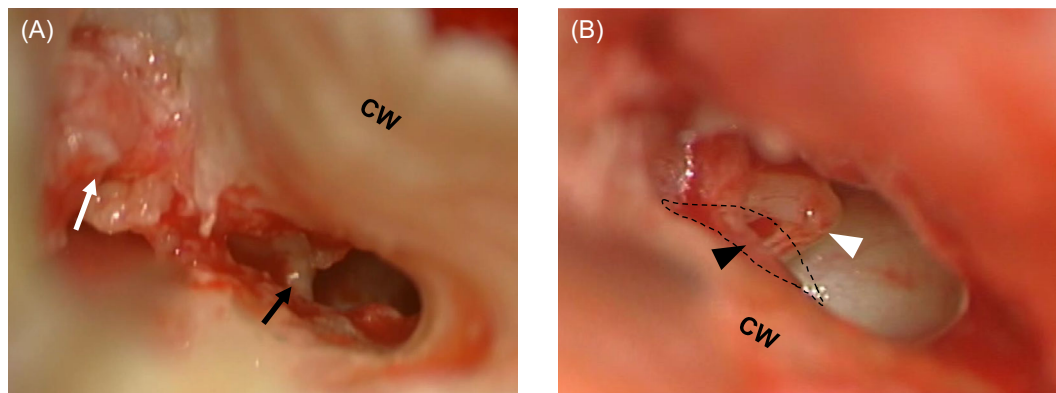
### 2.5 | Assessment of perioperative CTN function

#### 2.5.1 | Questionnaire

All patients were asked about taste symptoms before surgery and again at 2 days, 2 weeks, 1 month, 3 months, 6 months, and 1 year after the



**FIGURE 1** Surgical images of two-stage canal wall up tympanoplasty for right ear cholesteatoma. Tg, Tegmen; CW, Canal wall. (A) Cholesteatoma (black arrow) was removed with combined canal wall up mastoidectomy in the first-stage surgery. (B) The chorda tympani nerve was preserved in its original position (white arrow). (C) Bone defect of the tympanic scutum was reconstructed with a sliver of sliced auricular cartilage (black arrowhead). (D) The mastoid cavity and tympanic cavity were carefully observed in the second-stage surgery. (E) Ossiculoplasty was performed with hydroxyapatite prosthesis. The chorda tympani nerve was preserved in the original position (white arrowhead)

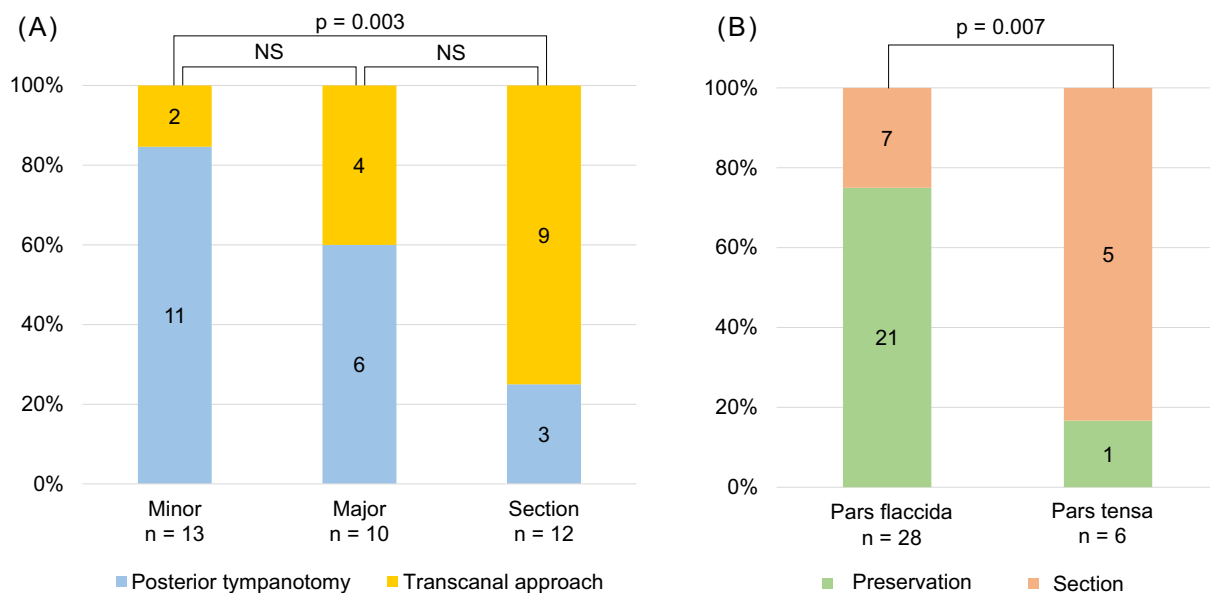


**FIGURE 2** Difference in the approach to the stapes. CW, canal wall. (A) Right middle ear cholesteatoma (white arrow) around the stapes (black arrow) was removed by posterior tympanotomy via mastoid cavity. (B) The incus-stapes joint (white arrowhead) was cut with a transcanal approach. The bony annulus of tympanic membrane was partially removed by drilling (dashed line). The chorda tympani nerve (black arrowhead) was exposed and manipulated

first- and second-stage surgery. The incidence of taste disorder after the first- and second-stage surgery was analyzed based on the status of the CTN. Taste disorder was defined as the patient's subjective abnormal taste perception, including hypogeusia or taste alteration revealed by face-to-face interviews conducted by the first author. Taste alteration was described as bitter, metallic, salty, sweet, or unpleasant taste.

### 2.5.2 | Electrogustometry

The electrogustometry (EGM) threshold was analyzed using a Rion TR-06 electrogustometer (RION Co., Tokyo, Japan) to assess CTN function and was measured according to Tomita et al.<sup>16</sup> The magnitude of the electrical stimulation varied continuously on a logarithmic



**FIGURE 3** (A) Relationship between the approach to the incus–stapes joint and the degree of chorda tympani nerve manipulation. (B) Preservation rate of the chorda tympani nerve in cases with the pars flaccida type and with the pars tensa type cholesteatoma

scale. The lowest current level was  $-6$  decibel (dB), and the highest was 34 dB, increasing in 2-dB steps. The scale-out score was 36 dB. The normal range was  $\leq 8$  dB. The point at which the EGM threshold was measured was the ridge 2 cm behind the tip of the tongue. The EGM threshold was measured before surgery and again at 2 days, 2 weeks, 1 month, 3 months, 6 months, and 1 year after surgery. A postoperative EGM threshold within 8 dB was defined as recovery. All tests were performed by the first author, who was skilled in the procedure.

## 2.6 | Data analysis

Statistical analysis was performed using Stat Mate 4 software (ATMS Co., Ltd., Tokyo, Japan). A paired *t*-test was used to compare the EGM thresholds. Statistical analyses of CTN status, perioperative symptoms, and recovery rate of the EGM threshold were performed using Fisher's exact test. The alpha level was set at .05.

## 3 | RESULTS

### 3.1 | CTN status during the first-stage surgery

Of the 35 patients who underwent first-stage surgery, 13 (37.1%), 10 (28.6%), and 12 (34.3%) were in the minor manipulation, major manipulation, and section groups, respectively.

The relationship between the surgical approach around the stapes and the degree of CTN manipulation was analyzed. The selection rate for posterior tympanotomy was 84.6% (11/13), 60.0% (6/10), and 25.0% (3/12) in minor manipulation, major manipulation, and section groups, respectively (Figure 3A). Posterior tympanotomy was

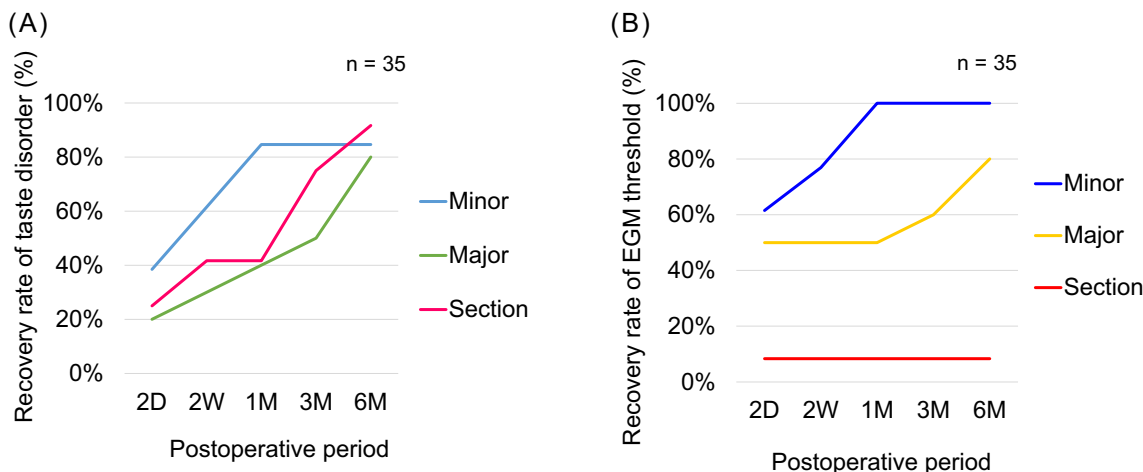
selected significantly more frequently in the minor manipulation group than in the sectioning group ( $p = .003$ ).

The CTN was preserved in 75.0% (21/28) of patients with pars flaccid cholesteatoma and 16.7% (1/6) of patients with pars tensa cholesteatoma during the first-stage surgery (Figure 3B). In cases of cholesteatoma with pars tensa retraction, the rate of preservation of the CTN decreased significantly ( $p = .007$ ).

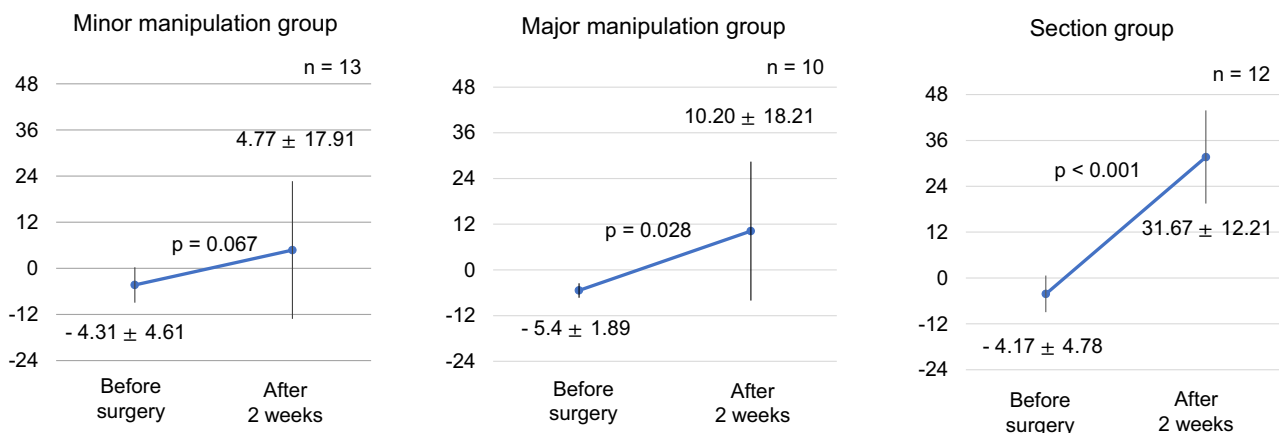
### 3.2 | CTN function after first-stage surgery

In this study, 71.4% (25/35) of patients complained of taste disorder in the early postoperative period. Hypogeusia was the most frequent symptom (22/35, 62.9%), followed by taste alteration (10/35, 28.6%). The incidence of taste disorder at 2 days after surgery was 61.5% (8/13) in the minor manipulation group, 80.0% (8/10) in the major manipulation group, and 75.0% (9/12) in the section group. A month after the first-stage surgery, the incidence was 15.3% (2/13) in the minor manipulation group, 50.0% (5/10) in the major manipulation group, and 58.3% (7/12) in the section group. Improvement in taste disorder occurred earlier in the minor group than in the other two groups. Six months after the first-stage surgery, the incidence of taste disorder was 15.3% (2/13) in the minor manipulation group, 20.0% (2/10) in the major manipulation group, and 8.3% (1/12) in the section group (Figure 4A). Thus, in all three groups, taste disorder recovered within 6 months in many of the patients.

The recovery rate of the EGM threshold within 2 weeks after surgery was 76.9% (10/13) in the minor manipulation group, 50.0% (5/10) in the major manipulation group, and 8.3% (1/12) in the section group. Six months after surgery, the EGM threshold had recovered to 100% (13/13) in the minor manipulation group, 80.0%



**FIGURE 4** (A) Taste disorder after the first-stage surgery. (B) Recovery of the electrogustometry (EGM) threshold by the degree of the CTN manipulation after the first-stage surgery



**FIGURE 5** The mean electrogustometry (EGM) threshold between before and after the first-stage surgery, based on the degree of chorda tympani nerve manipulation. Error bars indicate standard deviation in EGM thresholds

(8/10) in the major manipulation group, and 8.3% (1/12) in the section group (Figure 4B). The recovery of the EGM threshold occurred earlier in the minor manipulation group than it did in the other two groups, and it had not recovered in most of the participants in the section group by 6 months after surgery.

The mean EGM threshold was compared before and after the first-stage surgery according to the degree of CTN manipulation (Figure 5). Two weeks after the first-stage surgery, the EGM threshold was only slightly elevated in the minor manipulation group. In contrast, it was significantly increased in the major manipulation ( $p = .028$ ) and section groups ( $p < .001$ ). The increase in the EGM threshold was smaller in the minor manipulation group than in the other two groups.

### 3.3 | CTN status during second-stage surgery

In the 30 patients who underwent second-stage surgery, CTN preservation was achieved in 18 patients during first-stage surgery. CTN

was preserved in 94.4% (17/18) during the second-stage surgery. Of the 17 patients in whom the CTN was preserved during the second-stage surgery, 16 patients (94.1%) underwent minor manipulation of the CTN, and one patient (5.9%) underwent major manipulation. Residual cholesteatoma was observed in eight of the 30 (26.7%) patients during the second-stage surgery. Among these patients, the CTN was preserved in four patients during the first-stage surgery. Their CTN was still preserved in the second-stage surgery, even when the residual cholesteatoma was removed (Table 1).

### 3.4 | CTN function after second-stage surgery

Taste symptoms were followed up for 3 months after the second-stage surgery (Figure 6). Two days after the second-stage surgery, the rate of complaints of taste disorder was only 17.6% (3/17) in the preservation group and 15.4% (2/13) in the section group. Three months after the second-stage surgery, taste disorder improved in 94.1%



(16/17) of the patients in the preservation group, and it did not change in the section group.

Changes in the mean EGM threshold 2 weeks after the second-stage surgery were analyzed (Figure 7). The mean postoperative EGM threshold in the preservation group was within the normal range. In contrast, the mean postoperative EGM threshold in the section group was outside the normal range. The mean EGM threshold was not significantly increased in both the preservation group ( $p = .198$ ) and the section group ( $p = .269$ ).

We investigated the difference in the incidence of taste disorder between after the first-stage surgery and after the second-stage surgery (Figure 8). In the CTN preservation group, the incidence of taste disorder at 2 weeks after the first-stage surgery was 69.6% (16/23), while that after the second-stage surgery was 11.8% (2/17). In the CTN section group, the incidence of taste disorder at 2 weeks after the first-stage surgery was 59.3% (7/12), while that after the second-stage surgery was 15.4% (2/13). The incidence of taste disorder after second-stage surgery was thus significantly lower than that after first-

stage surgery in both the preservation group ( $p = .0004$ ) and the section group ( $p = .0414$ ).

#### 4 | DISCUSSION

Most previous reports on cholesteatoma surgery have focused on recidivism or hearing outcomes.<sup>5-9</sup> However, CTN function after cholesteatoma surgery has not received marked attention. The present study investigated perioperative taste dysfunction after two-stage CWUT for cholesteatoma.

Michael et al.<sup>17</sup> reported the prevalence of taste disorder after cholesteatoma surgery was low because of the chronic nature of cholesteatoma. However, 71.4% of the patients complained of taste disorder after the first-stage surgery in our study. This result demonstrates that taste disorder after cholesteatoma surgery is a crucial complication.

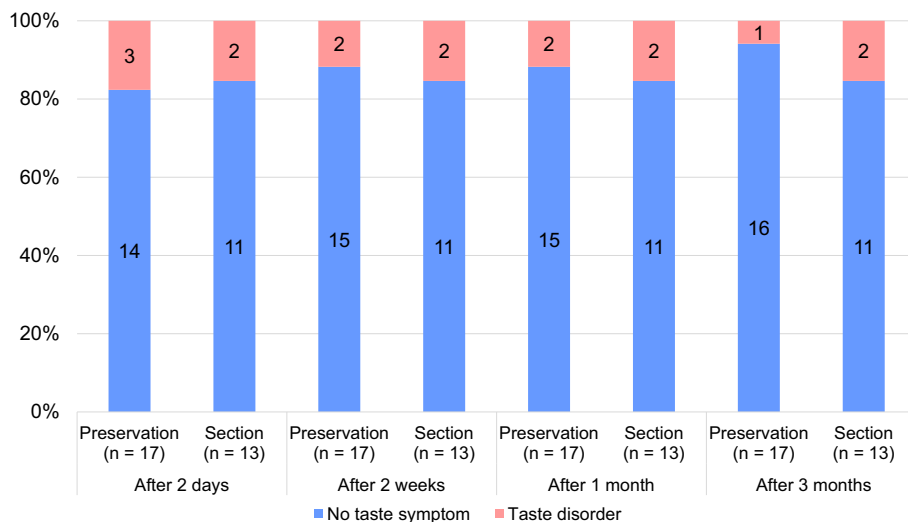
The CTN preservation rate during surgery for cholesteatoma was investigated in two studies. Sone et al.<sup>11</sup> reported that CTN was preserved in 27.7% of patients with cholesteatoma, and they did not address individual surgical procedures. Clerks et al.<sup>14</sup> reported that the CTN was preserved in 23.8% of patients with cholesteatoma, and their surgical procedures included canal wall up or down mastoidectomy and attico-antrotomy. Choi et al.<sup>18</sup> reported that the preservation rate of CTN in chronic otitis media with or without cholesteatoma was significantly higher in canal wall up mastoidectomy than in canal wall down mastoidectomy. In this study, the preservation rate was 62.9% after two-stage surgery. The CTN preservation rate seems higher than that reported in other studies. The reasons for these results may be the following: (1) The majority (80.0%) of patients included in the present study had pars flaccida type cholesteatoma. (2) Posterior tympanotomy was performed as the approach to the stapes whenever possible. (3) The canal wall down technique was not used in this study.

An anatomical study of the temporal bone specimens by McMillan et al.<sup>19</sup> reported that the mean distance between the CTN and the

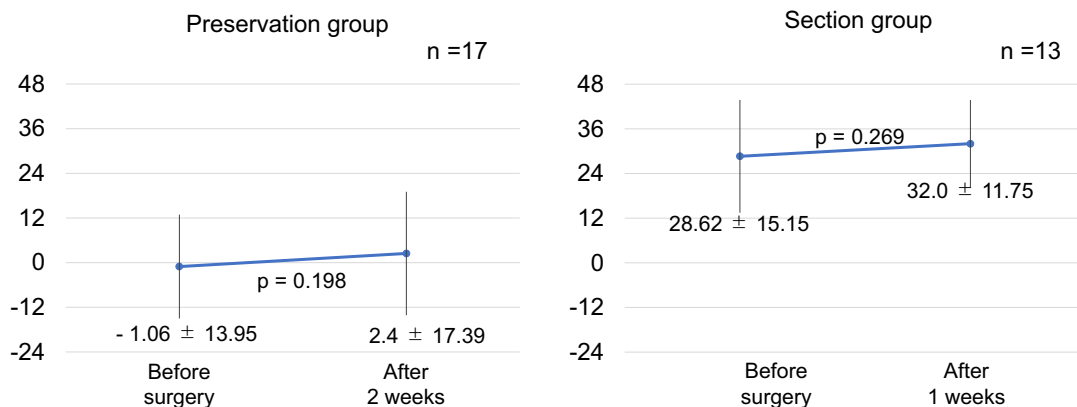
**TABLE 1** Findings of the second-stage surgery

No residual cholesteatoma		n = 22
Preservation		12
Minor manipulation		12
Major manipulation		0
Section in 1st-stage surgery		9
Section in 2nd-stage surgery		1
Residual cholesteatoma		n = 8
Preservation		4
Minor manipulation		3
Major manipulation		1
Section in 1st-stage surgery		4
Section in 2nd-stage surgery		0

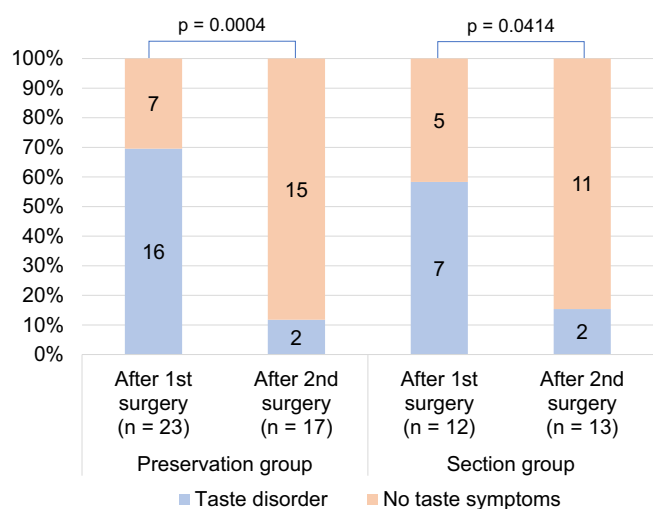
Note: The relationship between the chorda tympani nerve status and residual cholesteatoma during the second-stage surgery is demonstrated.



**FIGURE 6** Incidence of taste disorder after the second-stage surgery



**FIGURE 7** Changes in the mean electrogoniometry (EGM) threshold in the preservation and section groups after the second-stage surgery. Error bars indicate standard deviation in EGM thresholds



**FIGURE 8** Incidence of taste disorder at 2 weeks after the first-stage and the second-stage surgery, according to the chorda tympani nerve status

facial nerve was 3.3 mm at the level of the oval window and 2.4 mm at the level of the round window. Posterior tympanotomy can provide sufficient working space to operate around the I-S joint. Sakagami<sup>20</sup> reported the points at which the CTN is frequently touched. The CTN is more frequently touched or injured when the bony annulus of the tympanic membrane is removed by drilling than when posterior tympanotomy is performed. In this study, for removal of a cholesteatoma around the stapes during the first-stage surgery, significantly more patients in the minor manipulation group underwent posterior tympanotomy rather than transcanal approach, than did patients in the other two groups. In the major manipulation and section groups, many patients underwent drilling of the bony annulus of the tympanic membrane via transcanal approach. Therefore, using a technique without drilling the bony tympanic annulus, may be an effective method for CTN preservation.

The CTN was not sectioned in 94.4% of the patients in the second-stage surgery, and in most of these cases, the CTN was only slightly

manipulated. These results indicate that the second-stage surgery did not cause severe injury to the CTN in cases with CTN preservation during the first-stage surgery. Of the eight patients with residual cholesteatoma in the second-stage surgery, the CTN had been preserved in four patients during the first-stage surgery. These residual cholesteatomas can be removed without damaging the CTN. In general, cholesteatoma surgery aims to eradicate cholesteatoma and improve hearing. Thus, many otosurgeons do not pay much attention to preserving the CTN during cholesteatoma surgery. In this study, we showed that, if the CTN was preserved in the first-stage surgery, residual cholesteatoma could be removed with a high probability of CTN preservation in the second-stage surgery. Thus, in cases where second-stage surgery is planned, surgeons might not need to focus on eradicating cholesteatoma around the CTN in the first-stage surgery.

In the CTN preservation group, many patients complained of postoperative taste disorder in the early phase after the first-stage surgery. In contrast, taste symptoms after the second-stage surgery were mild even in the early postoperative period. The EGM threshold was significantly elevated after the first-stage surgery, but not after the second-stage surgery. If the CTN was preserved during the first-stage surgery, CTN function was unlikely to be damaged by manipulation during the second-stage surgery. The possible explanation for these findings is as follows: (1) Endoscopic assistance in the second-stage surgery visualized the running of the CTN on the underside of the malleus and minimized the elevation of the tympano-meatal flap. The CTN may, therefore, not have been stretched. (2) Mucosal thickness around the sheath of the CTN during recovery from injury by the first-stage surgery may have reduced the damage to the CTN during the second-stage surgery. (3) Because of the shorter operating time of the second-stage surgery than the first-stage surgery, the CTN may have been less manipulated. In most of the CTN section group, taste disorder improved within 1 year after the first-stage surgery, and they did not frequently complain of taste symptoms after the second-stage surgery. However, in most cases, the EGM threshold did not recover. The CTN function of the section group was severely impaired during the first-stage surgery, and it was estimated that no new taste symptoms occurred after the second-stage surgery.

In this study, most patients maintained at least a unilateral CTN. Guinand et al.<sup>21</sup> reported that bilateral CTN injury causes severe symptoms, such as persistent xerostomia. The absence of patients with bilateral CTN impairment in the present study may have contributed to the mild symptoms of patients in the CTN section group. Eighty percent of the patients had some problems with the contralateral ear containing cholesteatoma and may require middle ear surgery in future. Since the rate of CTN preservation decreases as the retraction pocket in the pars tensa progresses, surgeons can recommend surgery before the disease advances too far, to avoid bilateral CTN injury.

This prospective study has several limitations. Due to the small sample size and the short postoperative follow-up period, our results may not be generalizable. Further studies with large sample sizes and long-term follow-up are required in the future. However, our results that the rate of CTN dysfunction after the second-stage surgery was less than after the first-stage surgery may help explain the patients before the two-stage CWUT for cholesteatoma.

## 5 | CONCLUSION

We showed that CTN function, including taste symptoms and EGM threshold, could be preserved in two-stage CWUT for cholesteatoma if care was taken to preserve the CTN during both surgeries. The residual cholesteatoma could be removed in the second-stage surgery without severely damaging the CTN. This study suggests that two-stage CWUT, retaining the bony annulus intact, is effective for preserving CTN function.

### ACKNOWLEDGMENTS

We would like to thank Editage ([www.Editage.com](http://www.Editage.com)) for English language editing.

### FUNDING INFORMATION

This study received no funding.

### CONFLICT OF INTEREST

The authors declare that they have no conflicts of interest to disclose.

### ORCID

Riu Nishimura  <https://orcid.org/0000-0001-8337-7425>

### REFERENCES

- Kuo CL. Etiopathogenesis of acquired cholesteatoma: prominent theories and recent advances in biomolecular research. *Laryngoscope*. 2015;125(1):234-240.
- Jackler RK, Santa Maria PL, Varsak YK, Nguyen A, Blevins NH. A new theory on the pathogenesis of acquired cholesteatoma: mucosal traction. *Laryngoscope*. 2015;125(Suppl 4):S1-S14.
- Karmarkar S, Bhatia S, Saleh E, et al. Cholesteatoma surgery: the individualized technique. *Ann Otol Rhinol Laryngol*. 1995;104(8):591-595.
- Lailach S, Kemper M, Lasurashvili N, Beleites T, Zahnert T, Neudert M. Health-related quality of life measurement after cholesteatoma surgery: comparison of three different surgical techniques. *Eur Arch Otorhinolaryngol*. 2015;272(11):3177-3185.
- Mishiro Y, Sakagami M, Kitahara T, Kondoh K, Okumura S. The investigation of the recurrence rate of cholesteatoma using Kaplan-Meier survival analysis. *Otol Neurotol*. 2008;29(6):803-806.
- Wilson KF, Hoggan RN, Shelton C. Tympanoplasty with intact canal wall mastoidectomy for cholesteatoma: long-term surgical outcomes. *Otolaryngol Head Neck Surg*. 2013;149(2):292-295.
- Ho SY, Kveton JF. Efficacy of the 2-staged procedure in the management of cholesteatoma. *Arch Otolaryngol Head Neck Surg*. 2003;129(5):541-545.
- Crowson MG, Ramprasad VH, Chapurin N, Cunningham CD 3rd, Kaylie DM. Cost analysis and outcomes of a second-look tympanoplasty-mastoidectomy strategy for cholesteatoma. *Laryngoscope*. 2016;126(11):2574-2579.
- Mishiro Y, Sakagami M, Kitahara T, Kondoh K, Kubo T. Long-term hearing outcomes after ossiculoplasty in comparison to short-term outcomes. *Otol Neurotol*. 2008;29(3):326-329.
- McManus LJ, Dawes PJ, Stringer MD. Clinical anatomy of the chorda tympani: a systematic review. *J Laryngol Otol*. 2011;125(11):1101-1108.
- Sone M, Sakagami M, Tsuji K, Mishiro Y. Younger patients have a higher rate of recovery of taste function after middle ear surgery. *Arch Otolaryngol Head Neck Surg*. 2001;127(8):967-969.
- Saito T, Manabe Y, Shibamori Y, et al. Long-term follow-up results of electrogustometry and subjective taste disorder after middle ear surgery. *Laryngoscope*. 2001;111(11 Pt 1):2064-2070.
- Mueller CA, Khatib S, Naka A, Temmel AF, Hummel T. Clinical assessment of gustatory function before and after middle ear surgery: a prospective study with a two-year follow-up period. *Ann Otol Rhinol Laryngol*. 2008;117(10):769-773.
- Clark MP, O'Malley S. Chorda tympani nerve function after middle ear surgery. *Otol Neurotol*. 2007;28(3):335-340.
- Sakagami M, Sone M, Tsuji K, Fukazawa K, Mishiro Y. Rate of recovery of taste function after preservation of chorda tympani nerve in middle ear surgery with special reference to type of disease. *Ann Otol Rhinol Laryngol*. 2003;112(1):52-56.
- Tomita H, Ikeda M, Okuda Y. Basis and practice of clinical taste examinations. *Auris Nasus Larynx*. 1986;13(Suppl 1):S1-S15.
- Michael P, Raut V. Chorda tympani injury: operative findings and postoperative symptoms. *Otolaryngol Head Neck Surg*. 2007;136(6):978-981.
- Choi N, Ahn J, Cho YS. Taste changes in patients with middle ear surgery by intraoperative manipulation of chorda tympani nerve. *Otol Neurotol*. 2018;39(5):591-596.
- McMillan RA, Nassiri AM, Leonel LC, et al. The posterior ligament of the incus ("white dot"): a reliable surgical landmark for the facial recess. *Am J Otolaryngol*. 2022;43(2):103304.
- Sakagami M. Taste disorder after middle ear surgery. *J Int Adv Otol*. 2009;5(3):382-390.
- Guinand N, Just T, Stow NW, Van HC, Landis BN. Cutting the chorda tympani: not just a matter of taste. *J Laryngol Otol*. 2010;124(9):999-1002.

**How to cite this article:** Nishimura R, Miuchi S, Ikehata M, Sakagami M, Tsuzuki K. Change in chorda tympani nerve function after two-stage tympanoplasty for cholesteatoma. *Laryngoscope Investigative Otolaryngology*. 2022;7(6):2035-2042. doi:10.1002/lio2.939