

Case Report

Meningitis complicated by mycotic aneurysms

Ciro Ramos-Estebanez^{1,*} and Dileep Yavagal²

¹Department of Neurology, Neurocritical Care Division, Cleveland, OH 44106-1716, USA and ²Department of Neurology, Miller School of Medicine, University of Miami, Miami, FL 33136, USA

*Correspondence address. Department of Neurology, Neurocritical Care Division, Case Western Reserve University, 11100 Euclid Avenue, Hanna Building, 5040, Cleveland, OH 44106-1716, USA. Tel: +1-216-844-1000; Fax: +1-216-844-4785; E-mail: ciro.ramosestebanez@uHospitals.org

Received 26 February 2014; revised 18 April 2014; accepted 30 April 2014

Mycotic aneurysms complicated by vasospasm and strokes represent a rare manifestation of bacterial meningitis. We describe a healthy woman diagnosed with bacterial meningitis and mycotic aneurysms, who received both antibiotic and corticosteroid therapy. This approach fostered a significant radiologic improvement in her mycotic aneurysms as evidenced by serial angiographic examinations. During her course, she developed vasospasm and strokes and required intra-arterial verapamil. More importantly and as a result of these combined therapies, the patient experienced a substantial clinical improvement. This case allows the description of mycotic aneurysms epidemiology, clinical presentation and complications. In addition, our vignette bestows the relevance of serial neurologic examinations and radiologic testing during the acute vasculopathy period. Current conservative and interventional therapeutic options are briefly discussed.

INTRODUCTION

Mycotic aneurysms occur in the context of bacterial embolization to the intracranial arterial *vasa vasorum*. These aneurysms are typically the consequence of bacteremia in the setting of bacterial endocarditis, intravenous drug use, endovascular procedures or a suppressed immune response (immunosuppressive therapy, HIV, diabetes mellitus, malignancy) [1]. Bacterial meningitis is occasionally complicated by mycotic aneurysms [2]. From the etiologic perspective, *Staphylococcus aureus* and *Streptococcus* species represent the most prevalent microorganisms [3]. Nevertheless, aneurysm development may occur in the mist of sterile blood cultures in 18–50% of cases [4].

Mycotic aneurysms typically become symptomatic in the context of a subarachnoid hemorrhage or intraparenchymal bleeding [1]. It is noteworthy that infective intracranial aneurysms more commonly cause intraparenchymal hemorrhage than do non-infectious aneurysms [1]. More rarely, symptoms develop in the setting of strokes due to septic embolism or vasospasm. We present an unusual case of meningitis complicated by mycotic aneurysms and vasospasm in an immunocompetent patient.

CASE REPORT

A 63-year-old right-handed woman with no previous medical history presented with fever and meningism for 6 days. Her mental status had progressively declined and she was obtunded at admission. Urine toxicology was negative. Complete blood count showed leukocytosis (16 000) with a neutrophilic predominance (86%) and a left shift. Lumbar puncture supported a diagnosis of meningitis (pleocytosis with neutrophilic predominance, mild hypoglycorrhachia and elevated protein). She was started on empirical antibiotic therapy. Her blood cultures, Cerebrospinal fluid microbiologic markers and HIV status were negative. A transesophageal echocardiogram ruled out endocarditis. Her autoimmune panel results were within normal limits. The initial brain computerized tomography (CT) was unremarkable for hemorrhage or early signs of stroke. A 24-h electroencephalogram confirmed diffuse slowing without epileptic activity. Two days after admission, she developed focal neurologic deficits [the motor responses to noxious stimuli were bilaterally impaired, with her left limbs weakly retreating (3+), while the right limbs barely moved (2)]. Her Glasgow Coma Score (GCS) was 7 (eye 1, verbal 1, motor 5). MRI demonstrated mild

subarachnoid hemorrhage and numerous bilateral strokes in anterior and posterior circulation distributions with no significant lesions on MR angiogram. An initial angiographic evaluation evidenced multiple fusiform aneurysms (Fig. 1a). Seven days later, the severity of her right-sided motor deficits increased. Repeated angiographic evaluation demonstrated focal vasospasm in the superior division of the left medium cerebral artery territory, which was reversed angiographically and clinically with intra-arterial verapamil. In addition, a generalized improvement in the quantity and severity of her infective aneurysms was evident after a week on antibiotic and corticosteroid therapy (Fig. 1b). Her GCS improved to 12 (eye 4, verbal 3, motor 5). Eventually, after 2 weeks of admission, her GCS reached 14 points (eye 4, verbal 4, motor 6), and she was transferred to a rehabilitation facility. Her modified Rankin score was 2 at the 3-month outpatient clinic visit.

DISCUSSION

Our case depicts an aggressive clinical course in an immunocompetent patient with meningitis complicated by infective

aneurysms. Typical acute complications in this setting may occur in the form of ischemic infarction, parenchymal hemorrhage or aneurysm rupture [5]. Therefore, once diagnostic suspicion is raised imaging is warranted. Although CT angiogram and MR angiogram are less invasive, angiography remains the diagnostic gold standard for aneurysms <3 mm. Indeed, our patient's angiogram featured classical lesions in cases with a hematogenous spread (fusiform, multiple, more frequent in the anterior circulation, localizing peripherally, thereby sparing the circle of Willis; see Fig. 1a) [6, 7]. This is an interesting finding that illustrates the severity of this meningitis given that a direct extravascular infection typically triggers aneurysms in those proximal areas where vessels penetrate into the infected meningeal layers [2].

Although there are no specific guidelines to this effect, angiography is not routinely repeated for it conveys a risk for stroke and other procedurally related complications [8]. However, this approach may soon change as there is a growing body of literature supporting angiographic monitoring [2]. In our case, repeat deficits localizing to a vascular territory suggest the possibility of vasospasm in the context of a

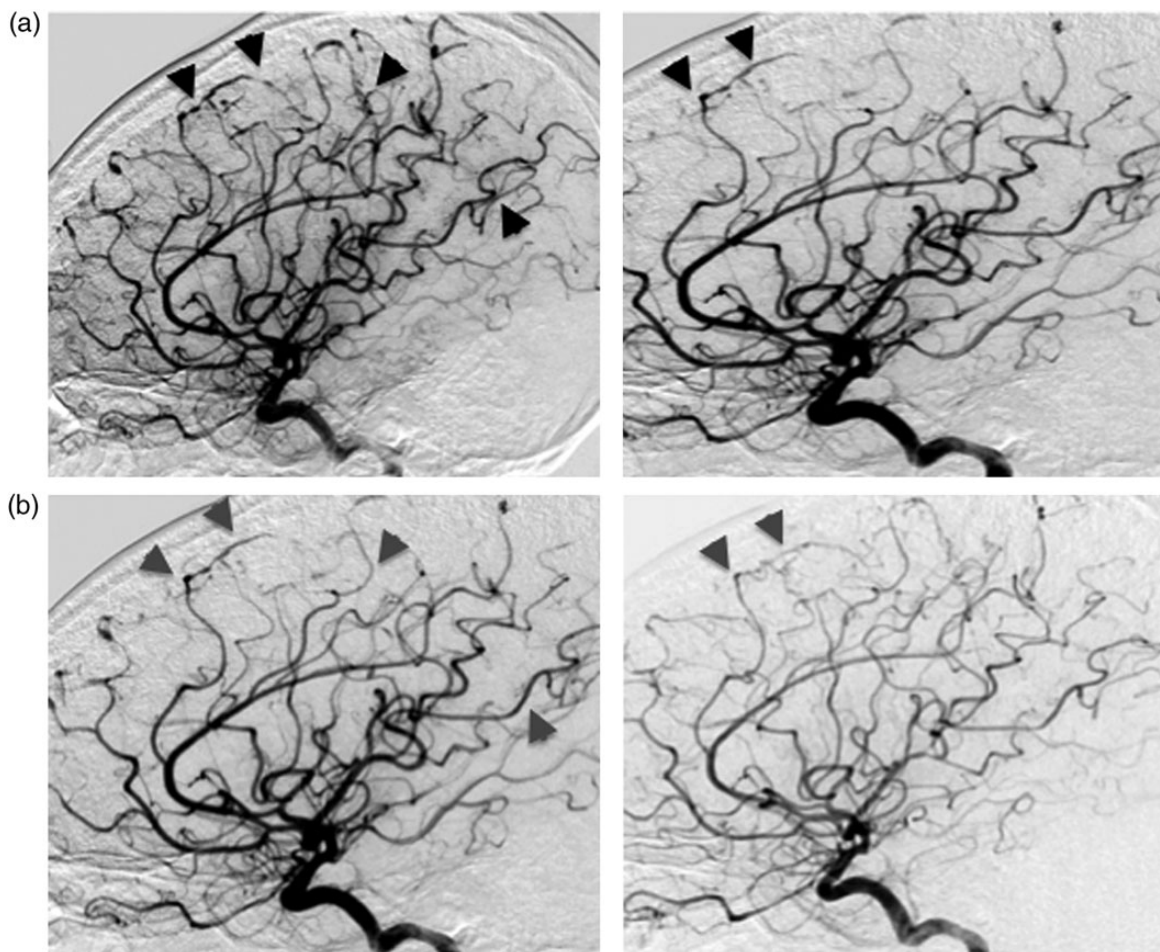


Figure 1: Angiographic studies at presentation (a) and after week receiving corticosteroids and antibiotics (b). (a) Black arrows denote mycotic aneurysms and areas with dilatation and narrowing (string of beads). (b) The aforementioned lesions are resolving as depicted in gray arrows.

subarachnoid hemorrhage. Vasospasm is a differential diagnosis that should always be considered because it is a treatable entity. Transcranial duplex ultrasound suggested this possibility and a new angiogram confirmed the suspicion of vasospasm, which resolved with intra-arterial verapamil.

Antibiotic therapy, alone or combined with endovascular and/or microsurgical approaches, remains the mainstay of management [1, 2]. There are no randomized controlled trials or prospective cohort studies evaluating the various treatment options. Similarly to our case, patients with a high surgical risk due to circumferential aneurysmal vessel involvement, or a proximal aneurysmal location and/or eloquent vascular territory may receive antimicrobial therapy [2]. Young symptomatic patients may undergo surgical clipping in accessible aneurysms [2]. Conversely, individuals with comorbidities that compromise the surgical outcome, or multiple aneurysms, or surgically inaccessible lesions may receive endovascular therapy [2]. Lastly, there is no evidence that steroid therapy would improve outcomes in patients with mycotic aneurysms. However, we feel it is a sensible practice to prescribe corticosteroids in the context of bacterial meningitis as its mortality and disability improve [9, 10]. The second angiogram illustrates a diminished severity of the lesions in the setting of antibiotic and steroid therapy (see Fig. 1), which correlates with an improvement in our patient's clinical examination [6, 7].

CONFLICT OF INTEREST

None declared.

REFERENCES

1. Chun JY, Smith W, Halbach VV, Higashida RT, Wilson CB, Lawton MT. Current multimodality management of infectious intracranial aneurysms. *Neurosurgery* 2001;**48**:1203–13; discussion 1213–4.
2. Ducruet AF, Hickman ZL, Zacharia BE, Narula R, Grobelny BT, Gorski J. Intracranial infectious aneurysms: a comprehensive review. *Neurosurg Rev* 2010;**33**:37–46.
3. Patra P, Ricco JB, Costargent A, Goueffic Y, Pillet JC, Chaillou P. Infected aneurysms of neck and limb arteries: a retrospective multicenter study. *Ann Vasc Surg* 2001;**15**:197–205.
4. Brown SL, Busuttill RW, Baker JD, Machleder HI, Moore WS, Barker WF. Bacteriologic and surgical determinants of survival in patients with mycotic aneurysms. *J Vasc Surg* 1984;**1**:541–47.
5. Hart RG, Kagan-Hallet K, Joerns SE. Mechanisms of intracranial hemorrhage in infective endocarditis. *Stroke* 1987;**18**:1048–56.
6. Brust JCM, Dickinson PCT, Hughes JEO, Holtzman RNN. The diagnosis and treatment of cerebral mycotic aneurysms. *Ann Neurol* 1990;**27**:238–46.
7. Moskowitz MA, Rosenbaum AE, Tyler HR. Angiographically monitored resolution of cerebral mycotic aneurysms. *Neurology* 1974;**24**:1103–8.
8. Dawkins AA, Evans AL, Wattam J, Romanowski CA, Connolly DJ, Hodgson TJ, Coley SC. Complications of cerebral angiography: a prospective analysis of 2,924 consecutive procedures. *Neuroradiology* 2007;**49**:753–9.
9. de Gans J, van de Beek D. Dexamethasone in adults with bacterial meningitis. *N Engl J Med* 2002;**347**:1549–56.
10. van de Beek D, de Gans J, McIntyre P, Prasad K. Corticosteroids in acute bacterial meningitis. *Cochrane Database Syst Rev* 2007. Issue 1. Art. No. CD004405. doi:10.1002/14651858.CD004405.pub2.