

Tentorial dural arteriovenous fistula with perimedullary venous drainage–associated cervical myelopathy: illustrative case

Sergi Cobos Codina, MD,¹ Luis Miguel Bernal García, MD,¹ José Antonio Rodríguez Sánchez, MD,¹ Tania Gavilán Iglesias, MD,² and Luis Fernández de Alarcón, MD³

Departments of ¹Neurosurgery and ³Interventional Radiology, Hospital Universitario Badajoz, Badajoz, Spain; and ²Department of Neurology, Hospital de Mérida, Mérida, Spain

BACKGROUND Tentorial dural arteriovenous fistulas (DAVFs) with perimedullary venous drainage causing cervical myelopathy are very uncommon conditions with an extremely aggressive behavior. When the characteristic radiological clues are missing, the unspecific clinical picture may cause delay and make the diagnosis challenging.

OBSERVATIONS Here the authors report a case of a 58-year-old man who developed progressive spastic tetraparesis and dyspnea with an extensive mild enhancing cervical cord lesion initially oriented as a neurosyphilis-associated transverse myelitis. Acute worsening after steroid administration redirected the diagnosis, and a tentorial Cognard type V DAVF was elicited. The microsurgical disconnection process is described, and previously documented cases in the literature are reviewed.

LESSONS If a DAVF is highly suspected, it is important to consider the possibility of its intracranial origin, and spinal as well as cerebral arteriography must be performed.

<https://thejns.org/doi/abs/10.3171/CASE22148>

KEYWORDS tentorial dural arteriovenous fistula; perimedullary drainage; cervical myelopathy

Dural arteriovenous fistulas (DAVFs) consist of anomalous connections between dural arteries and venous sinuses or leptomeningeal veins, accounting for 10%–15% of all intracranial vascular malformations.¹ Tentorial DAVFs are a rare and dangerous subtype of fistula that should be treated when diagnosed in order to avoid progressive focal neurological deficits or hemorrhage.² Despite its bizarreness, when an arteriovenous shunt occurs to spinal medullary veins, tentorial DAVFs can cause cervical myelopathy with radiological findings resembling tumors or inflammatory or infectious disorders.^{3,4} We present a case exemplifying the vital importance of early recognition and subsequent treatment.

Illustrative Case

A 58-year-old man was hospitalized in the neurology department for complaints of a 3-month history of painless, fluctuating, and

progressive lower limb weakness with sensory deficits. One year earlier, he had experienced a 4-m-high fall onto his back.

Physical examination revealed left leg reduced strength (4+/5), spastic gait, bilateral ankle clonus, and extensor plantar reflexes. Cervical magnetic resonance imaging (MRI) showed no compression but edema and spinal cord thickening from the craniocervical level down to C6 with mild gadolinium peripheral enhancement (Fig. 1A and B).

Subsequently, the detection of a positive cerebrospinal fluid (CSF) *Treponema pallidum* antibody index and motor improvement after penicillin G sodium treatment oriented the diagnosis toward a neurosyphilis-associated transverse myelitis, and the patient was discharged.

Eight months later, spastic tetraparesis, bladder dysfunction, and a T5 sensory level were established. Findings for tumor and infectious and autoimmunity markers were negative, and new cervical MRI revealed increased cord edema (Fig. 1C).

ABBREVIATIONS CSF = cerebrospinal fluid; CT = computed tomography; CTA = computed tomography angiography; DAVF = dural arteriovenous fistula; ICA = internal carotid artery; MHT = meningohipophyseal trunk; MRA = magnetic resonance angiography; MRI = magnetic resonance imaging.

INCLUDE WHEN CITING Published August 8, 2022; DOI: 10.3171/CASE22148.

SUBMITTED March 25, 2022. **ACCEPTED** June 22, 2022.

© 2022 The authors, CC BY-NC-ND 4.0 (<http://creativecommons.org/licenses/by-nc-nd/4.0/>).

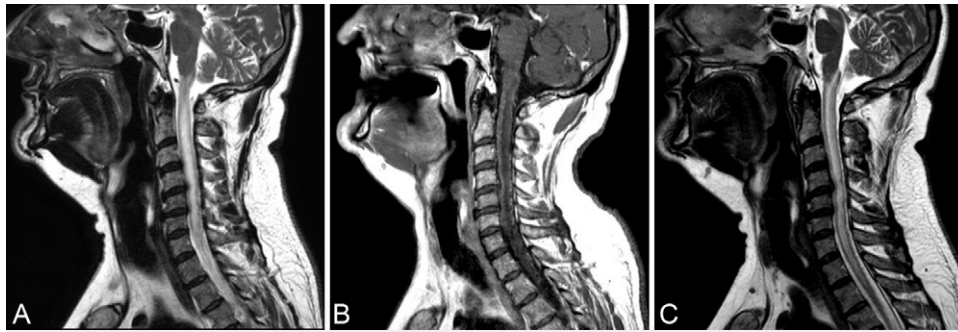


FIG. 1. A: T2-weighted MRI sequence showing edema and spinal cord thickening from the craniocervical level down to C6, with no signal voids appreciated. **B:** Mild peripheral enhancement was demonstrated after gadolinium administration. **C:** Increased spinal cord edema up to the T2 level after 8 months.

The fluctuating progressive clinical course and strength worsening after an empirical corticosteroid dose for the first episode raised suspicion about a vascular etiology. Whole spinal cord angiography and craniocervical magnetic resonance angiography (MRA) showed no vascular abnormalities.

The patient's condition kept worsening. Proximal (1/5) lower limb paresis, major spasticity in the arms, and shortness of breath with speech developed. Despite the negative spinal cord angiography result, cerebral arteriography was programmed. After left internal carotid artery (ICA) catheterization, a tentorial Cognard⁵ type V DAVF was elicited, being identified as a tentorial branch of the meningohypophyseal trunk (MHT) as the feeding artery (Fig. 2).

The tortuosity of the vessels made an endovascular approach difficult, so the patient was referred to us for surgical treatment.

A left retromastoid craniectomy was performed with exposure of the transverse–sigmoid junction. After durotomy, throughout the supra-cerebellar–infratentorial corridor, an arterialized vein was identified hanging from the lateral inferior side of the tentorium. Pre- and post-clipping indocyanine green video angiography showed the correct DAVF interruption (Fig. 3).

Postoperative computed tomography (CT) and cranial arteriography revealed no complications and total DAVF closure (Fig. 3A–E). Shortly after surgery, the patient started to recover from the disturbed respiratory mechanics and slightly from the tetraparesis. He was discharged early to an integrated neurological rehabilitation center. Eight months later, his condition had improved to the point that he could ambulate with a walker, notwithstanding residual hyperreflexia. Control MRI showed important T2 sequence hyperintensity reduction (Fig. 3F).

Discussion

Observations

Tentorial DAVFs account for only 4%–8% of all intracranial DAVFs, but their clinical behavior is the most life threatening, with 97% resulting in hemorrhage or progressive focal neurological deficits. This could be partially explained by the retrograde leptomeningeal venous pattern of drainage, because in large series, all the tentorial DAVFs have been classified as Borden type III.^{2,6,7}

In 1982, Woimant et al.⁸ made the first report of an intracranial DAVF with spinal perimedullary venous drainage presenting with myelopathy, constituting since then a rare entity. However, until Wrobel et al.⁹ 1988, no cervical myelopathy secondary to a tentorial DAVF had been documented.

On the basis of our thorough PubMed database review, to our knowledge and including our case, only 20 cases with this bizarre clinical manifestation have been registered (Table 1).^{1–29} All the patients were male (55.1 years mean age), and the onset of symptoms was 2–48 months before the diagnosis, with an average delay of approximately 12 months. The vast majority of arterial feeders were tentorial branches of the left MHT. It is known that, when identifiable, the meningohypophyseal artery arises from the left ICA in greater proportion.¹⁰ Most often, the treatment option is microsurgery.^{1,9,19–21,24–26} When embolization was attempted (8 of 20 cases), the procedure had to be repeated in 1 case, and in 4 others, microsurgery was the final treatment.^{9,18,22,23,27–29}

The initial trigger of DAVFs is unknown. Nevertheless, in some cases such as ours, previous head trauma is reported. Prior cranial

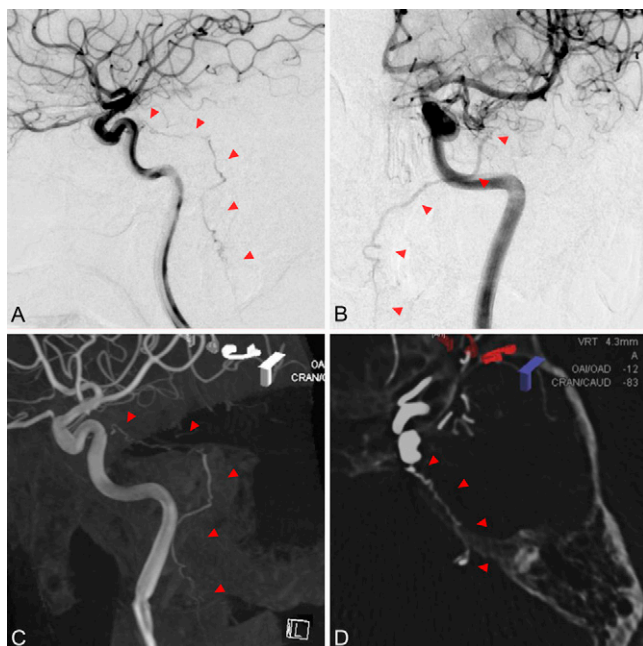


FIG. 2. Left ICA angiography revealing a tentorial branch of the MHT as the feeding artery of the DAVF. Red arrowheads highlight the fistula in lateral (A) and posteroanterior (B) projections, as well as in the lateral (C) and axial (D) reconstructions, where bony landmarks can be appreciated. Note the DAVF trajectory following the petrous ridge (D).

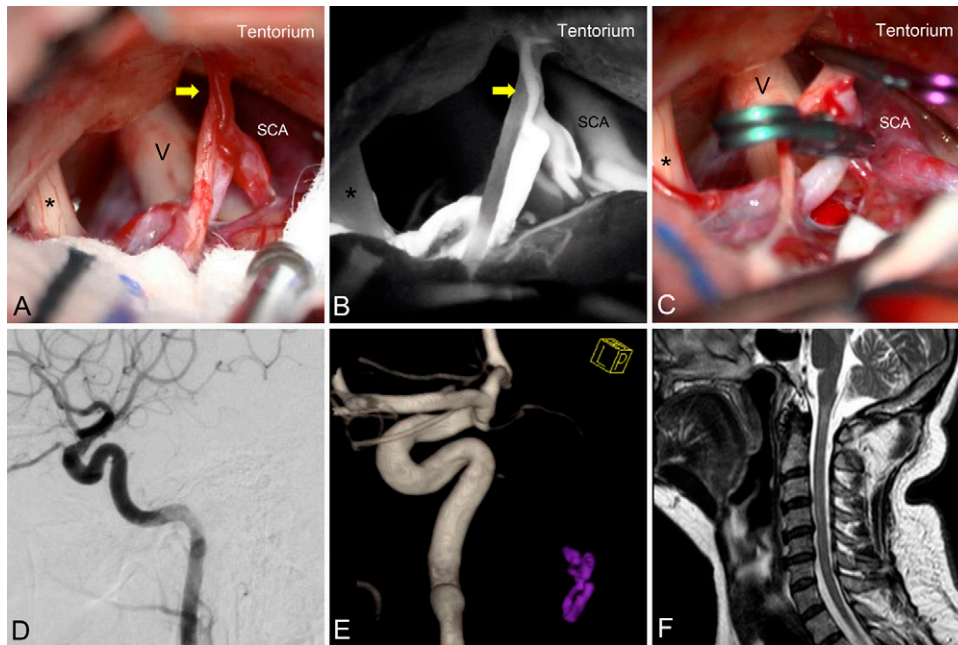


FIG. 3. Intraoperative images (A–C) obtained after performing a left retromastoid craniectomy and durotomy below the transverse–sigmoid junction. Yellow arrows point to the arterialized vein hanging from the lateral inferior side of the tentorium. The trigeminal nerve (V), facial and vestibulocochlear nerves (*), and the superior cerebellar artery (SCA) are visible in the picture. Early indocyanine green video angiography (B) showed the DAVF tentorial arterial supply and its filling. Two straight aneurysm clips (C) were applied to disconnect the fistula. Postoperative left internal carotid arteriography (D and E) proving total DAVF closure. Postoperative MRI (F) showing a minimum residual amount of hyperintensity on a T2 sequence, with neither enlargement nor enhancement.

surgeries, venous system anomalies, and cortical veins or venous sinus multifactorial thrombosis have also been involved.⁵

The suspected physiopathology of the spinal cord damage would be explained by the venous hypertension arising from the shunted arterial flow directly into the petrosal vein and transmitted to the anterior spinal vein through the well-described anastomotic venous channels. The anterior spinal vein communicates superiorly with the anterior medullary vein, which continues with the anterior pontomesencephalic vein and subsequently with the petrosal vein.^{9,11} However, some intracranial DAVFs with perimedullary drainage do not course with myelopathy. It seems that this group has in common a cervical medulloradicular vein that drains into epidural spaces, thereby preventing spinal venous hypertension and myelopathy.^{12,13}

Myelopathy is known to be the heterogeneous clinical manifestation of an extensive sort of etiology. In a prospective survey of 585 patients, the main causes of nontraumatic spastic paraparesis and tetraparesis were cervical spondylotic myelopathy (24%), followed by multiple sclerosis (18%), tumor (16%), and motor neuron disease (4%). Only 1.7% accounted for the vascular disease group. Diagnosis was uncertain, even after MRI, in 18.6% of the cases.¹⁴

Lessons

As these data support, it is difficult per se to establish a vascular origin of the myelopathy. Recognition of diffuse cervical spinal cord edema and/or engorged vessels with serpentine signal void appearance on T2-weighted MRI could orientate the diagnosis toward both spinal and intracranial DAVF. Enhancement of the tortuous veins after gadolinium may also be observed on T1-weighted MRI.¹⁵

Nonetheless, as well as the case we present, these radiological clues can be missing. Additional evaluation with dynamic CT angiography (CTA), MRA, or digital subtraction angiography may also be performed. CTA and MRA have a sensitivity for the detection of DAVF of 15.4% and 50%, respectively, with an inadequate negative predictive value of the former to exclude DAVFs.¹⁶ Furthermore, if only a spinal DAVF is pursued, even with the gold standard whole-spine arteriogram, an intracranial DAVF with perimedullary venous drainage cannot be diagnosed.

Cognard type V tentorial DAVFs are extremely aggressive. They should be disconnected when diagnosed; partial obliteration does not protect against hemorrhage. As in the present case, venous drainage into perimedullary veins prevents a transvenous approach. Also, the embolization of meningeal ICA feeders is difficult; risky; and, as detailed in Table 1, when attempted, the number of cases requiring additional treatment, predominantly microsurgery, was not negligible.^{9,23,24,27,29} For this reason, given the feasibility and in order to avoid further risk or delay in a very fragile patient, we directly opted for the open procedure. Therefore, although endovascular treatment has become the leading therapy for intracranial DAVFs, tentorial DAVFs may require microsurgical discontinuation.^{3,12} Following the classification proposed by Lawton et al. for tentorial DAVFs,² the one we have documented would be classified as a superior petrosal sinus DAVF (type V) with its corresponding infra-tentorial drainage. Nevertheless, none of their type V cases debuted with myelopathy.

Tentorial DAVFs with perimedullary venous drainage causing cervical myelopathy are rare and life threatening. In our case, the unspecific clinical and radiological picture and the plausible

TABLE 1. Summary of reported cases

Authors & Year	Age (yrs)	Sex	Sxs & Signs	Diagnosis Delay	Feeders	Shunt	Treatment	Outcome
Wrobel et al., 1988 ⁹	68	M	Myelopathy	6 mos	MHT (l)/OA	Tentorium	Microsurgery	Paraplegia imp, paraparesis
	42	M	Myelopathy	8 mos	MHT (l)/OA/ECA	Tentorium	Microsurgery	UE recovery, paraparesis
	43	M	Myelopathy	36 mos	MHT (r)/OA (r)	Tentorium	Embolization microsurgery (x2)	UE recovery, paraparesis.
Gobin et al., 1992 ¹⁸	53	M	Myelopathy	5 mos	MHT (l)	Tentorium	Embolization (x2)	UE recovery, paraparesis.
Versari et al., 1993 ¹⁹	50	M	Myelopathy	>6 mos	MHT (l)/OA	Tentorium	Microsurgery	Tetraparesis imp, assisted amb
Bret et al., 1994 ²⁰	31	M	Myelopathy	4 mos	MHT (r)	Tentorium	Microsurgery	Tetraparesis recovery, mild spasticity
Brunereau et al., 1996 ¹³	53	M	Myelopathy	Unknown	MHT (l)	Tentorium	Unknown	Unknown
	69	M	Myelopathy	Unknown	MHT (l)	Tentorium	Unknown	Unknown
Ernst et al., 1997 ²¹	71	M	Myelopathy	Unknown	MHT (r)	Tentorium	Microsurgery	Paraparesis imp
Bousson et al., 1999 ²²	36	M	Myelopathy	12 mos	OA (l)	Tentorium	Embolization	Tetraparesis imp
Ricolfi et al., 1999 ²³	69	M	Myelopathy	36 mos	MHT (l)/ECA	Tentorium	Embolization	Strength worsening, exitus
	53	M	Myelopathy	>8 mos	MHT (l)/ECA (l)	Tentorium	Embolization microsurgery	Paraplegia imp, sensory deficit
Kalamangalam et al., 2002 ²⁴	68	M	Myelopathy	4 mos	MHT (l)	Tentorium	Microsurgery	Paraparesis imp, assisted amb
Renner et al., 2006 ²⁵	58	M	Myelopathy	Several mos	MHT (r)	Tentorium	Microsurgery	Paraparesis recovery, mild sensory deficit
Kim et al., 2011 ²⁶	45	M	Myelopathy	6 mos	MHT (l)	Tentorium	Microsurgery	Tetraparesis imp, assisted amb
Vivekananda et al., 2013 ²⁷	72	M	Myelopathy	3 mos	MHT (r)/ECA (r)	Tentorium	Embolization microsurgery	UE imp, unchanged paraplegia
Zhang et al., 2018 ²⁸	33	M	Myelopathy	2 mos	MHT (l)	Tentorium	Embolization	Paraparesis imp
Peethambar et al., 2019 ²⁹	64	M	Myelopathy	3.5 mos	MHT (l)	Tentorium	Embolization microsurgery	Paraparesis imp, sensory deficit

CONTINUED ON PAGE 5 »

TABLE 1. Summary of reported cases

Authors & Year	Age (yrs)	Sex	Sxs & Signs	Diagnosis Delay	Feeders	Shunt	Treatment	Outcome
Kwon et al., 2019 ¹	66	M	Myelopathy	48 mos	MHT (r)	Tentorium	Microsurgery	Tetraplegia imp, independent amb, urinary incontinence
Cobos Codina et al., 2022 (present case)	58	M	Myelopathy	11 mos	MHT (l)	Tentorium	Microsurgery	Tetraparesis imp, assisted amb, hyperreflexia

amb = ambulation; ECA = external carotid artery branches; Imp = improvement; MHT = meningohypophyseal trunk; OA = occipital artery; Sxs = symptoms; UE = upper extremity.

hypothesis of neurosyphilis-associated transverse myelitis contributed to a significant diagnostic delay that is slightly shorter than the average (12 months) of the reviewed cases. The well-reported association between intravenous corticosteroid administration and acute worsening of spinal DAVFs¹⁷ prompted us to persevere in searching for the DAVF in spite of the inconclusive spinal arteriography.

Thus, when the search for a highly suspected vascular source of myelopathy is unsuccessful, it is mandatory to keep in mind the possibility of its intracranial origin. DAVFs must not be ruled out if a complete intracranial angiography is not performed. If not, as illustrated with some degree of post-treatment residual motor or sensory deficit in all the reported cases (Table 1), the potential reversibility of the symptoms related to medullary venous congestion could be dangerously put at risk.

References

1. Kwon O, Shin DA, Chung J. Long-standing tentorial dural arteriovenous fistula presenting as progressively worsening cervical myelopathy by degenerative cervical intervertebral disc: a case report. *Acta Neurochir (Wien)*. 2019;161(8):1523–1527.
2. Lawton MT, Sanchez-Mejia RO, Pham D, Tan J, Halbach VV. Tentorial dural arteriovenous fistulae: operative strategies and microsurgical results for six types. *Neurosurgery*. 2008;62(3 suppl 1):110–125.
3. Bernard F, Lemée JM, Faguer R, Fournier HD. Lessons to be remembered from a dural arteriovenous fistula mimicking medulla and high cervical cord glioma. *World Neurosurg*. 2018;113:312–315.
4. Kim HJ, Choi IS. Serious myelopathy due to magnetic resonance imaging-occult arteriovenous fistula: case report of petrous ridge dural arteriovenous fistula. *Interv Neuroradiol*. 2015;21(5):609–612.
5. Elhammady MS, Ambekar S, Heros RC. *Epidemiology, Clinical Presentation, Diagnostic Evaluation, and Prognosis of Cerebral Dural Arteriovenous Fistulas*. Vol. 143. 1st ed. Elsevier; 2017.
6. Zhou LF, Chen L, Song DL, Gu YX, Leng B. Tentorial dural arteriovenous fistulas. *Surg Neurol*. 2007;67(5):472–482.
7. Tomak PR, Cloft HJ, Kaga A, Cawley CM, Dion J, Barrow DL. Evolution of the management of tentorial dural arteriovenous malformations. *Neurosurgery*. 2003;52(4):750–762.
8. Woimant F, Merland JJ, Riché MC, et al. Bulbospinal syndrome related to a meningeal arteriovenous fistula of the lateral sinus draining into spinal cord veins. Article in French. *Rev Neurol (Paris)*. 1982;138(6-7):559–566.
9. Wrobel CJ, Oldfield EH, Di Chiro G, Tarlov EC, Baker RA, Doppman JL. Myelopathy due to intracranial dural arteriovenous fistulas draining intrathecally into spinal medullary veins. Report of three cases. *J Neurosurg*. 1988;69(6):934–939.
10. Allen JW, Alastra AJG, Nelson PK. Proximal intracranial internal carotid artery branches: prevalence and importance for balloon occlusion test. *J Neurosurg*. 2005;102(1):45–52.
11. Mitsuhashi Y, Aurboonyawat T, Pereira VM, et al. Dural arteriovenous fistulas draining into the petrosal vein or bridging vein of the medulla: possible homologs of spinal dural arteriovenous fistulas. Clinical article. *J Neurosurg*. 2009;111(5):889–899.
12. Cognard C, Gobin YP, Pierot L, et al. Cerebral dural arteriovenous fistulas: clinical and angiographic correlation with a revised classification of venous drainage. *Radiology*. 1995;194(3):671–680.
13. Brunereau L, Gobin YP, Meder JF, Cognard C, Tubiana JM, Merland JJ. Intracranial dural arteriovenous fistulas with spinal venous drainage: relation between clinical presentation and angiographic findings. *AJNR Am J Neuroradiol*. 1996;17(8):1549–1554.
14. Moore AP, Blumhardt LD. A prospective survey of the causes of non-traumatic spastic paraparesis and tetraparesis in 585 patients. *Spinal Cord*. 1997;35(6):361–367.

15. Kim WY, Kim JB, Nam TK, Kim YB, Park SW. Cervical myelopathy caused by intracranial dural arteriovenous fistula. *Korean J Spine*. 2016;13(2):67–70.
16. Gandhi D, Chen J, Pearl M, Huang J, Gemmete JJ, Kathuria S. Intracranial dural arteriovenous fistulas: classification, imaging findings, and treatment. *AJNR Am J Neuroradiol*. 2012;33(6):1007–1013.
17. Nasr DM, Brinjikji W, Rabinstein AA, Lanzino G. Clinical outcomes following corticosteroid administration in patients with delayed diagnosis of spinal arteriovenous fistulas. *J Neurointerv Surg*. 2017;9(6):607–610.
18. Gobin YP, Rogopoulos A, Aymard A, et al. Endovascular treatment of intracranial dural arteriovenous fistulas with spinal perimedullary venous drainage. *J Neurosurg*. 1992;77(5):718–723.
19. Versari PP, D'Aliberti G, Talamonti G, Branca V, Boccardi E, Collice M. Progressive myelopathy caused by intracranial dural arteriovenous fistula: report of two cases and review of the literature. *Neurosurgery*. 1993;33(5):914–919.
20. Bret P, Salzmann M, Bascoulergue Y, Guyotat J. Dural arteriovenous fistula of the posterior fossa draining into the spinal medullary veins—an unusual cause of myelopathy: case report. *Neurosurgery*. 1994;35(5):965–969.
21. Ernst RJ, Gaskill-Shiple M, Tomsick TA, Hall LC, Tew JM Jr, Yeh HS. Cervical myelopathy associated with intracranial dural arteriovenous fistula: MR findings before and after treatment. *AJNR Am J Neuroradiol*. 1997;18(7):1330–1334.
22. Bousson V, Brunereau L, Vahedi K, Chapot R. Intracranial dural fistula as a cause of diffuse MR enhancement of the cervical spinal cord. *J Neurol Neurosurg Psychiatry*. 1999;67(2):227–230.
23. Ricolfi F, Manelfe C, Meder JF, et al. Intracranial dural arteriovenous fistulae with perimedullary venous drainage. Anatomical, clinical and therapeutic considerations. *Neuroradiology*. 1999;41(11):803–812.
24. Kalamangalam GP, Bhattacharya J, Teasdale E, Thomas M. Myelopathy from intracranial dural arteriovenous fistula. *J Neurol Neurosurg Psychiatry*. 2002;72(6):816–818.
25. Renner C, Helm J, Roth H, Meixensberger J. Intracranial dural arteriovenous fistula associated with progressive cervical myelopathy and normal venous drainage of the thoracolumbar cord: case report and review of the literature. *Surg Neurol*. 2006;65(5):506–510.
26. Kim NH, Cho KT, Seo HS. Myelopathy due to intracranial dural arteriovenous fistula: a potential diagnostic pitfall. Case report. *J Neurosurg*. 2011;114(3):830–833.
27. Vivekananda U, Lunn MP, Brew S, Miller DH. Cervical transverse myelitis like presentation of cranial dural arteriovenous fistula. *Clin Neurol Neurosurg*. 2013;115(7):1187–1189.
28. Zhang S, Liu H, Li J. Cervical myelopathy caused by intracranial dural arteriovenous fistula with acute worsening after steroid administration. *World Neurosurg*. 2018;120:328–330.
29. Peethambar GA, Whittam DH, Huda S, et al. Intracranial dural arteriovenous fistula mistaken as cervical transverse myelitis. *Pract Neurol*. 2019;19(3):264–267.

Disclosures

The authors report no conflict of interest concerning the materials or methods used in this study or the findings specified in this paper.

Author Contributions

Conception and design: Cobos Codina, Bernal García, Gavilán Iglesias. Acquisition of data: Cobos Codina, Bernal García, Gavilán Iglesias, de Alarcón. Analysis and interpretation of data: Cobos Codina, de Alarcón. Drafting the article: Cobos Codina, Gavilán Iglesias. Critically revising the article: Cobos Codina, Bernal García, Gavilán Iglesias. Reviewed submitted version of manuscript: Cobos Codina, Bernal García, Rodríguez Sánchez. Approved the final version of the manuscript on behalf of all authors: Cobos Codina. Statistical analysis: Cobos Codina. Administrative/technical/material support: Cobos Codina. Study supervision: Cobos Codina, de Alarcón.

Correspondence

Sergi Cobos Codina: Hospital Universitario Badajoz, Spain. sergi_c_c@hotmail.com.