

Factors affecting the reduction rate of odontogenic cysts after decompression based on 3-dimensional volumetric analysis

Sarawut Wongrattanakarn¹, Vorapat Trachoo^{1,*}, Boosana Kaboosaya¹, Pornkawe Charoenlarp², Net-nada Chongruangsri³, Patcharapit Promoppatum⁴

¹Department of Oral and Maxillofacial Surgery, Faculty of Dentistry, Chulalongkorn University, Bangkok, Thailand

²Department of Radiology, Faculty of Dentistry, Chulalongkorn University, Bangkok, Thailand

³Somdech Phra Pinklao Hospital, Naval Medical Department, Royal Thai navy, Bangkok, Thailand

⁴Department of Mechanical Engineering, Faculty of Engineering, King Mongkut's University of Technology Thonburi, Bangkok, Thailand

ABSTRACT

Purpose: This study aimed to investigate the potential factors that could affect the reduction rate of odontogenic cysts following decompression using cone-beam computed tomography (CBCT) for 3-dimensional volumetric analysis.

Materials and Methods: The study sample consisted of CBCT images of 41 individuals who underwent decompression of odontogenic cysts at the Department of Oral and Maxillofacial Surgery, Faculty of Dentistry, Chulalongkorn University, between 2010 and 2022. Preoperative and postoperative CBCT results were collected, and a volumetric analysis was conducted to evaluate the differences in the reduction rate and the percentage of volume reduction of cystic lesions based on different parameters. Correlations between these parameters were analyzed to determine associations.

Results: In this study, the average time of decompression for odontogenic cysts was 316 days. Males demonstrated a higher reduction rate than females ($P < 0.05$). The reduction rate was directly proportional to initial cyst volume, with higher reduction rates for cysts with large initial volume than those with small initial volume ($P < 0.05$). Spearman's rank correlation coefficient indicated a weak positive correlation between the initial cyst volume and the duration of decompression. Additionally, a strong positive correlation was observed between the initial volume and the reduction rate.

Conclusion: Knowledge of the reduction rate of odontogenic cysts is vital for surgeons to evaluate the duration of decompression before enucleation and to determine a definitive treatment plan. Sex and initial lesion volume had significant effects on the reduction rate. (*Imaging Sci Dent* 2023; 53: 313-23)

KEY WORDS: Decompression; Odontogenic Cysts; Imaging, Three Dimensional; Cone-Beam Computed Tomography

Introduction

Odontogenic cysts are the most common intraosseous jaw lesions.¹ Several types of cystic lesions such as odontogenic keratocysts, dentigerous cysts, and radicular cysts can present with large dimensions, which leads to the involvement of anatomical structures, such as the inferior

alveolar nerve, nasal cavity, and maxillary sinus due to increasing intra-cystic pressure, tooth displacement, and root resorption.²⁻⁴ Enucleation is the first-line treatment. However, for large cysts, this could present an increased risk of damage to vital structures. Thus, the treatment goal is to first reduce intracystic pressure using decompression techniques, such as decompression with a drain or marsupialization, which should be considered to prevent potential damage.⁵⁻⁸

Decompression is an effective treatment, involving low morbidity, for large cystic lesions of the jaw.^{6,9,10} By reducing the lesion size, either partially or completely, the risk

Received April 12, 2023; Revised July 14, 2023; Accepted July 21, 2023

Published online September 4, 2023

*Correspondence to : Dr. Vorapat Trachoo

Department of Oral and Maxillofacial Surgery, Faculty of Dentistry, Chulalongkorn University, 34 Henri Dunant Road, Pathumwan, Bangkok 10330, Thailand
(Tel) 66-2-218-8581, E-mail) vorapat.t@chula.ac.th

Copyright © 2023 by Korean Academy of Oral and Maxillofacial Radiology

This is an Open Access article distributed under the terms of the Creative Commons Attribution Non-Commercial License (<http://creativecommons.org/licenses/by-nc/3.0>) which permits unrestricted non-commercial use, distribution, and reproduction in any medium, provided the original work is properly cited.

Imaging Science in Dentistry · pISSN 2233-7822 eISSN 2233-7830

of surgical damage to important anatomical structures can be minimized; in some cases, a second operation might not be required.^{11,12} Both marsupialization and decompression with a drain technique have the same primary principle. The marsupialization technique involves opening the cavity to the oral environment and suturing the cystic lining to the oral mucosa.¹³ In decompression with a drain, however, a small hole is made in the cystic cavity, and a tube or stent is anchored for drainage and continuous irrigation.¹⁴ Often, a second operation is needed to completely eliminate the cystic lesion after these procedures.¹⁵ After the cyst size is reduced to the extent that it does not damage the adjacent vital structures, the surgeon considers enucleating the cystic lesion. Therefore, knowledge of the reduction rate of odontogenic cysts is important for determining the duration of decompression before enucleation. This helps surgeons determine when to enucleate a cyst following decompression. Several previous studies have described factors that influence the reduction rate of odontogenic cysts using panoramic radiography.^{4,16,17} However, it can be difficult to determine the exact boundaries of cystic lesions using this technique. Cone-beam computed tomography (CBCT) has become widely employed in dentistry due to its many applications, which allow customized settings and provide accurate 3-dimensional (3D) images. These advantages have resulted in reduced scanning time, easy accessibility, and clear images of contrasted structures. CBCT can also be enhanced with other software to generate 3D mathematical models of teeth, enabling convenient, efficient, and accurate calculations of surface area and volume. As a result, CBCT can be utilized to precisely determine the volume of cystic lesions.^{18,19}

The purpose of this study was to investigate the potential factors that could affect the reduction rate of odontogenic cysts following decompression using CBCT for 3D volumetric analysis.

Materials and Methods

Sample

This retrospective study was approved by the Human Research Ethics Committee of the Faculty of Dentistry, Chulalongkorn University (HREC-DCU 2022-012). The sample size was calculated using G*Power version 3.1.9.2, with an alpha, power, and effect size (E) of 0.05, 0.95, and 3.54, respectively, based on a previous study conducted by Consolo et al.²⁰ Based on these assumptions, the minimum required sample size was estimated to be 16 subjects. This

study included 41 patients who underwent decompression of odontogenic cysts at the Department of Oral and Maxillofacial Surgery, Faculty of Dentistry, Chulalongkorn University, between 2010 and 2022. Preoperative and postoperative CBCT images of these patients were collected for analysis. The histopathological diagnoses comprised dentigerous cysts, orthokeratinized odontogenic cysts, parakeratinized odontogenic keratocysts, and radicular cysts. All cases were categorized as unicystic lesions. The exclusion criteria consisted of insufficient clinical and radiological data on patients, the presence of systemic conditions (e.g., metabolic bone diseases), and the current use of certain medications, such as steroids, chemotherapy, antiresorptive drugs, or antianabolic drugs. The patients were categorized based on several factors, including sex, age, initial volume of the lesion, duration of decompression, location of the lesion, decompression technique, and pathological diagnosis.

CBCT image analysis

CBCT imaging was performed using a CBCT device (3D Accuitomo 170 Morita, Osaka, Japan) with a resolution of 0.25 mm and standard mode exposure settings of 90 kVp and 5 mA. The CBCT images were exported as Digital Imaging and Communications in Medicine (DICOM) files and imported into Mimics software. Mimics version 21.0 (Materialise, Leuven, Belgium) was utilized to analyze the cystic area in the axial, coronal, and sagittal planes. Additionally, the use of Hounsfield units (HU) in CBCT can determine bone density to assess its appropriateness.²¹ According to Bridge and Tipper,²² the appropriate HU value for bone is 400. Therefore, in this study, the HU value was set to 400 to establish the margin of cystic lesions. Soft tissue and fluid were assigned an upper threshold of 399 and a lower threshold of 0 (Fig. 1). A crop mark was placed around the area that contained features of interest (Fig. 2). The measurement area was marked as the blue region along the widest portion from the central part of the cystic site to the healthy bone, while the remaining area was marked as the red region (Fig. 3). This study utilized an automatic program to create a stereolithography (STL) file, which was subsequently used in a 3D medical program to generate a 3D model (Fig. 4). The volume of the cystic lesion was calculated in cubic millimeters (mm^3) and measured to determine the reduction rate and the percentage of volume reduction.

The following variables that can affect the impact of decompression were analyzed: sex (male, female); age (≤ 30 years, > 30 years); the initial volume of the lesion ($\leq 10,000 \text{ mm}^3$, $> 10,000 \text{ mm}^3$); the duration of decom-

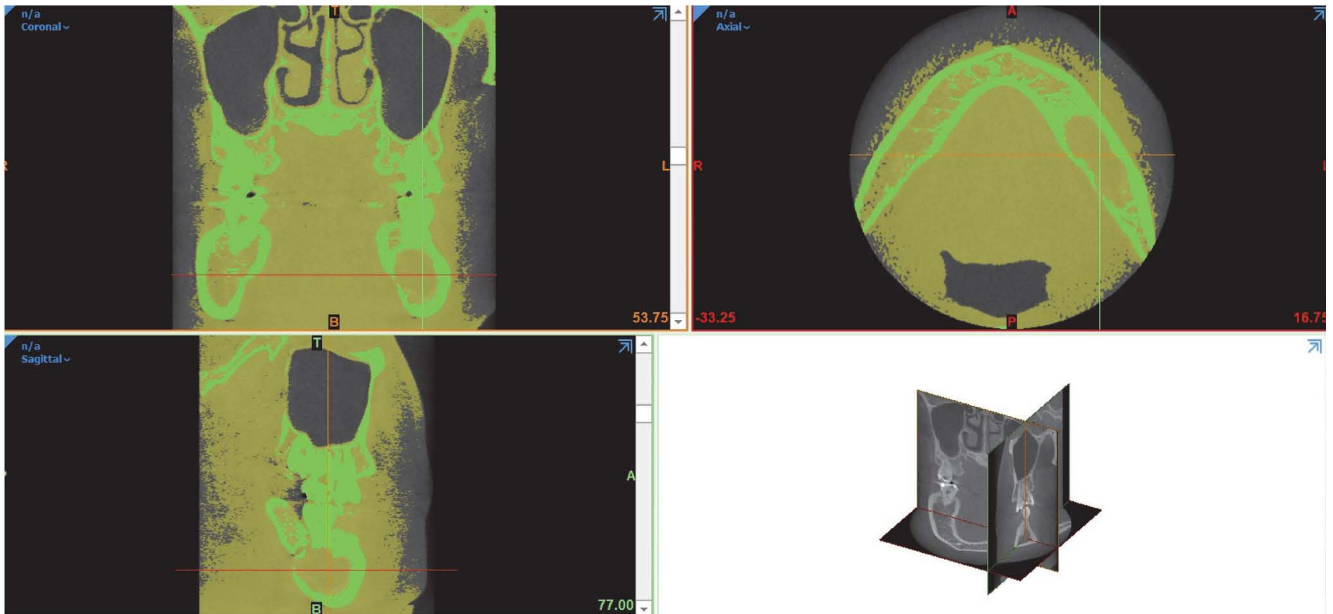


Fig. 1. The cystic lesion margin is designated by a Hounsfield unit (HU) value of 400 for bone density, while a range of 0-399 HU is used for soft tissue and fluid.

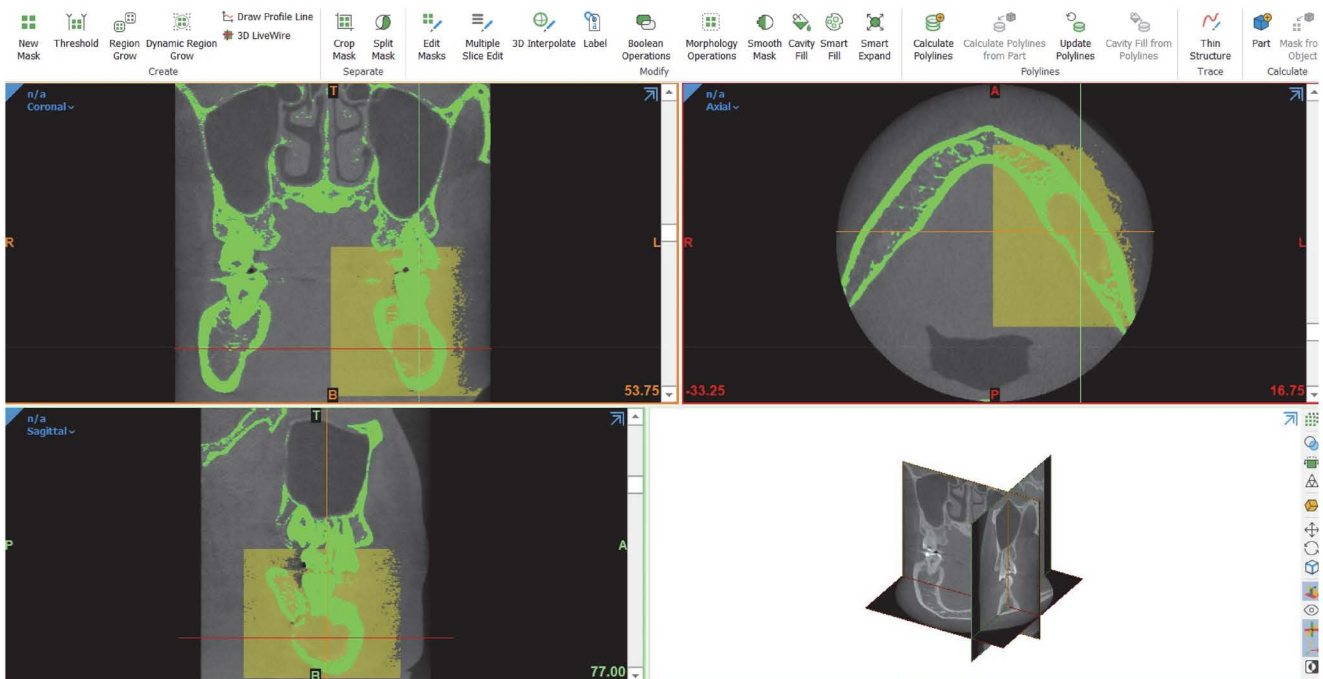


Fig. 2. The crop mask is performed in an area of interest.

pression (120-240 days, 241-360 days, or >360 days); location of the lesion (anterior maxilla, anterior mandible, posterior maxilla, or posterior mandible); decompression technique (tube drain or marsupialization); and pathological diagnosis (dentigerous cyst, orthokeratinized odontogenic cyst, parakeratinized odontogenic keratocyst, or radicular cyst).

togenic cyst, parakeratinized odontogenic keratocyst, or radicular cyst).

The age criterion was determined based on the results of the study conducted by Ihan Hren et al.²³ The initial criterion of 10,000 mm³ for the cystic volume was select-

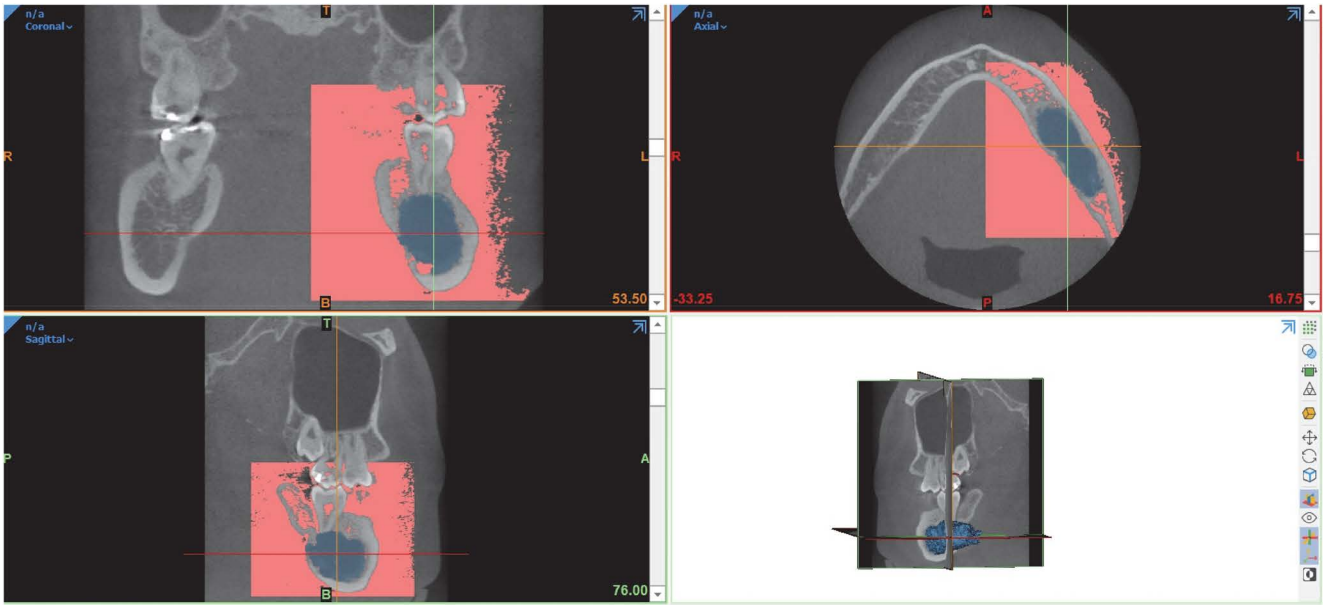


Fig. 3. The analyzed image reveals the cyst lesion area (blue region) and the area not of interest (red region).




Fig. 4. A 3-dimensional (3D) medical program automatically designs the 3D lesion, providing an accurate representation of the affected area.

ed based on the study by Jeong et al.,⁶ which classified the size of the initial lesion as 10 mL. The criterion for the duration of decompression was set based on the study by Bodner and Bar-Ziv.²⁴

To determine the mean value of the descriptive data, the following analysis was performed: the mean value was defined as equal to the total sum of values in a sample divided by the number of values in that sample. To obtain the reduction rate of odontogenic cysts, the reduction rate of

cystic lesions (mm^3/day) was calculated as the total of the cystic volume before decompression (mm^3) minus the cystic volume after decompression (mm^3) divided by time (expressed in days of observation). To obtain the percentage of volume reduction, the cystic volume before decompression (mm^3) minus the cystic volume after decompression (mm^3) was divided by the cystic volume before decompression and multiplied by 100.

Table 1. The reduction rate (mm³/day) according to various parameters

Independent factor	Number	Reduction rate (mm ³ /day)
Sex ^{a*}		
Male	25	27.93 ± 28.11
Female	16	13.91 ± 10.63
Age (y) ^a		
≤ 30	16	19.84 ± 20.15
> 30	25	24.14 ± 26.06
Initial volume of the lesion (mm ³) ^{a*}		
≤ 10,000	21	10.18 ± 5.91
> 10,000	20	35.36 ± 28.45
Duration of decompression (Days) ^b		
120-240	12	29.40 ± 35.22
241-360	15	14.88 ± 10.03
> 360	14	24.64 ± 21.51
Location of the lesion ^b		
Anterior maxilla	5	8.09 ± 5.49
Posterior maxilla	3	20.38 ± 10.91
Posterior mandible	33	24.82 ± 25.61
Decompression technique ^a		
Tube drain	22	22.73 ± 26.72
Marsupialization	19	22.14 ± 20.52
Pathological diagnosis ^b		
Dentigerous cyst	15	17.91 ± 9.89
Orthokeratinized odontogenic cyst	5	52.58 ± 47.15
Parakeratinized odontogenic keratocyst	19	19.76 ± 19.43
Radicular cyst	2	6.96 ± 7.29

*: $P < 0.05$, a: Mann-Whitney U test, b: Kruskal-Wallis test

Statistical analysis

Data on several factors, including sex, age, the initial volume of the lesion, duration of decompression, the location of the lesion, decompression technique, and pathological diagnosis, were collected and presented using descriptive statistics. The normality of the data distribution was examined using the Shapiro-Wilk test. Differences between groups were compared using the Mann-Whitney U test and the Kruskal-Wallis test. After comparing the differences between the associated factors, the Spearman rank correlation coefficient was used to analyze the magnitude of associations between variables. The magnitude of associations was determined with a 95% confidence interval (CI), and the statistical significance was set at $P < 0.05$. All statistical analyses were performed using SPSS version 28.0 (IBM Corp., Armonk, NY, USA).

Results

The present study included 41 subjects, 25 (61%) males

and 16 (39%) females, with a mean age of 37.68 years (range: 10-72 years). The mean initial cyst volume was 12,257.97 mm³ (range: 1,466.21-53,675.73 mm³). The average time of decompression for odontogenic cysts was 316 days (range: 147-740 days). The lesion locations were the anterior maxilla, posterior maxilla, and posterior mandible in 5, 3, and 33 cases, respectively. Decompression techniques using a tube drain and marsupialization were used in 22 and 19 cases, respectively. The pathological diagnoses are shown in Table 1.

There were significant differences in the reduction rate between sexes and based on the initial volume of the lesion ($P < 0.05$). However, there were no statistically significant differences in the reduction rate based on age, duration of decompression, location of the lesion, decompression technique, or pathological diagnosis (Table 1).

No statistically significant differences were found in the percentage of volume reduction based on sex, age, initial volume of the lesion, duration of decompression, location

Table 2. The percentage of volume reduction (according to parameters)

Independent factor	Number	Percentage of volume reduction (%)
Sex^a		
Male	25	53.31 ± 16.85
Female	16	56.06 ± 20.37
Age (y)^a		
≤ 30	16	58.39 ± 14.71
> 30	25	51.82 ± 19.84
Initial volume of the lesion (mm³)^a		
≤ 10000	21	52.78 ± 19.34
> 10000	20	56.07 ± 17.04
Duration of decompression (Days)^b		
120-240	12	48.52 ± 19.91
241-360	15	50.97 ± 19.70
> 360	14	63.07 ± 11.35
Location of the lesion^b		
Anterior maxilla	5	51.57 ± 21.67
Posterior maxilla	3	57.72 ± 7.086
Posterior mandible	33	54.51 ± 18.59
Decompression technique^a		
Tube drain	22	53.45 ± 16.59
Marsupialization	19	55.46 ± 20.13
Pathological diagnosis^b		
Dentigerous cyst	15	56.27 ± 18.84
Orthokeratinized odontogenic cyst	5	48.18 ± 17.00
Parakeratinized odontogenic keratocyst	19	55.43 ± 18.17
Radicular cyst	2	45.73 ± 25.08

a: Mann-Whitney U test, b: Kruskal-Wallis test

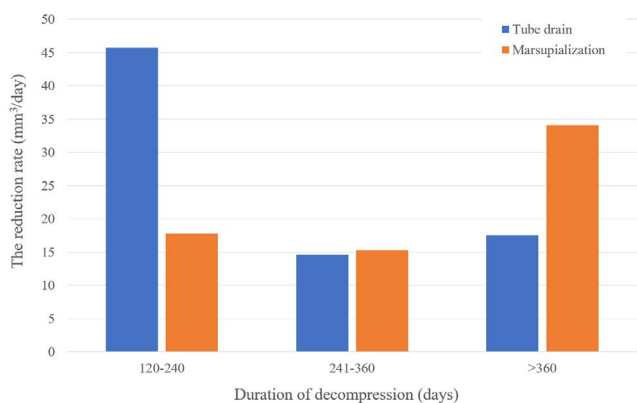


Fig. 5. Chart shows the reduction rate of the decompression technique according to the duration of decompression.

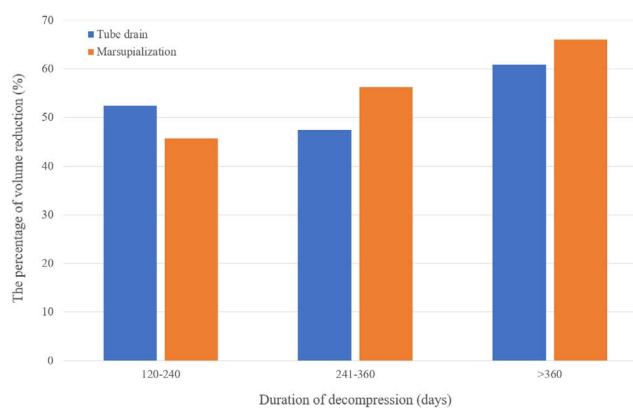


Fig. 6. Chart shows the percentage of volume reduction of the decompression technique according to the duration of decompression.

of the lesion, decompression technique, and pathological diagnosis ($P > 0.05$, Table 2).

The reduction rate for a given duration of decompression

did not show any statistically significant difference between the tube drain and the marsupialization group

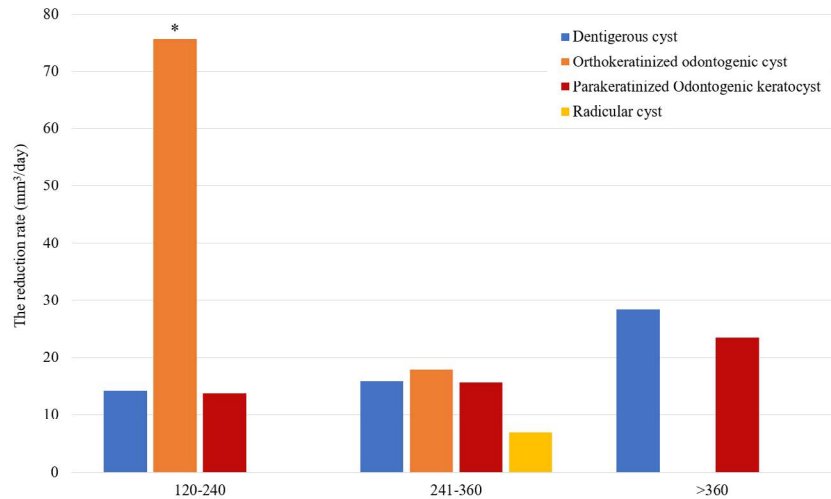


Fig. 7. Chart shows the reduction rate of the pathologic diagnosis corresponding to the duration of decompression (*: $P < 0.05$).

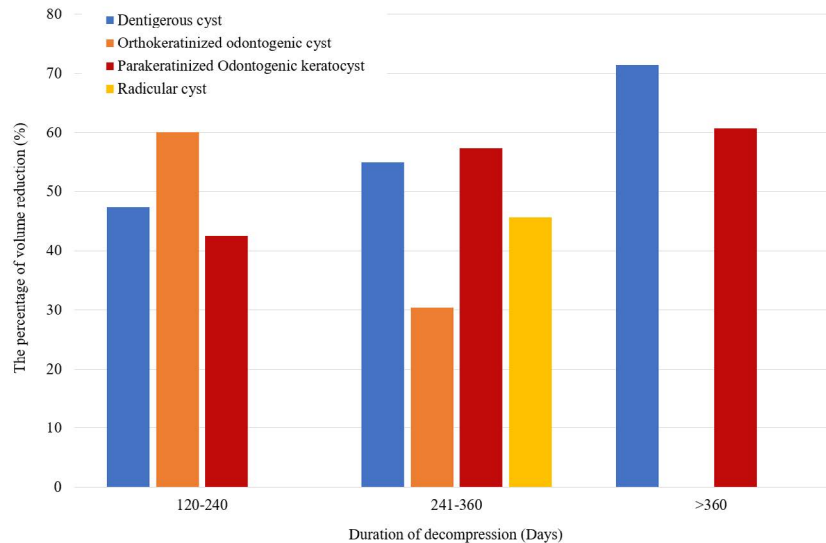


Fig. 8. Chart shows the percentage of volume reduction of the pathologic diagnosis corresponding to the duration of decompression.

($P > 0.05$, Fig. 5). Similarly, the percentage of volume reduction also did not demonstrate a statistically significant difference between the tube drain and marsupialization group ($P > 0.05$, Fig. 6).

The reduction rate for a given duration of decompression did not show any statistically significant difference among different pathological diagnoses, including dentigerous cysts, orthokeratinized odontogenic cysts, and odontogenic keratocysts ($P > 0.05$, Fig. 7). Similarly, the percentage of volume reduction based on the duration of decompression showed no statistically significant difference within each diagnosis group (dentigerous cysts, orthokeratinized odontogenic cysts, and parakeratinized odontogenic keratocysts) ($P > 0.05$, Fig. 8).

Using the Spearman rank correlation coefficient, a weak positive correlation was found between the duration of decompression and the initial cyst volume ($r = 0.320$), which was statistically significant ($P < 0.05$). A strong positive correlation was observed between the reduction rate and the initial volume ($r = 0.855$), which was also statistically significant ($P < 0.05$, Table 3).

Discussion

The conservative treatment of odontogenic cysts often involves decompression, which has been reported to have a high success rate in various studies.^{16,17} As this technique is a long-term treatment, the duration of decompression is an

Table 3. Spearman correlation coefficients for the relationships between the reduction rate and the percentage of volume reduction with age, duration of decompression, and initial volume

		Age	Duration of decompression (days)	Initial volume (mm ³)
Reduction rate	Coefficient	0.12	0.06	0.86*
Percentage of volume reduction	Coefficient	-0.29	0.35*	0.14

*: $P < 0.05$

important consideration, which surgeons will often assess before proceeding with enucleation.²⁵ Therefore, studying the factors that affect the reduction rate of odontogenic cysts can be useful for achieving clinical success. In this study, the authors evaluated the effects of sex, age, initial volume of the lesion, duration of decompression, location of the lesion, decompression technique, and pathological diagnosis on the success of decompression. After a statistical evaluation, it was found that sex and initial volume exhibited statistically significant associations ($P < 0.05$).

This study found that sex was a significant factor influencing the reduction rate of cystic lesion decompression, with males showing a higher reduction rate than females. However, no significant differences in the percentage of volume reduction were observed between males and females. These results are consistent with the study by Jeong et al.,⁶ which reported that males have a higher reduction rate than females, although this difference was not statistically significant in their study. The higher reduction rate observed in males may be attributed to the larger initial volume of odontogenic cysts, such as parakeratinized odontogenic keratocysts, and dentigerous cysts, which are more prevalent in males than females.²⁶ Therefore, the substantial reduction in volume observed in males may be influenced by the large initial cystic volume.

Inconsistent findings have been reported regarding the effects of age on decompression. Kwon et al.²⁵ reported that younger patients demonstrated a significantly higher reduction rate than older patients, while another study^{2,6,7} reported that age was not associated with the reduction rate. In this study, the age criterion was established according to Ihan Hren et al.,²³ who suggested that bone healing is significantly reduced among patients aged over 30 years after large defects. However, the present study found no significant difference in the rate of reduction and the percentage of volume reduction based on age. These findings were consistent with those of Lee et al.,¹⁶ who reported that age did not influence the reduction rate. Therefore, for older patients with large cystic lesions in the jaw, decompression

could be used to reduce the size of the cyst.

According to Jeong et al.,⁶ the rate of decrease in lesion volume was positively associated with the initial volume. Gao et al.²⁷ examined the correlation between relative shrinkage speed and the primary radiolucent area before decompression and discovered that large cystic lesions exhibited a faster rate of shrinkage than smaller lesions after decompression. However, Anavi et al.¹⁷ found that the initial size did not affect the outcome of decompression. In this study, the initial volume of the lesion was categorized based on the criterion ($\leq 10,000 \text{ mm}^3$ and $> 10,000 \text{ mm}^3$) suggested by Jeong et al.⁶ That study indicated that large initial cysts ($> 10 \text{ mL}$) showed a statistically significant greater rate of reduction than that of small initial cysts ($< 10 \text{ mL}$). Likewise, this study revealed a significant difference in the reduction rate based on the initial volume of the cystic lesion, with cysts having a large initial volume demonstrating a higher reduction rate than those with a small initial volume. This suggests that a large initial volume may be attributed to the cyst's ability to absorb fluid from its surroundings and the development of its epithelial cells, leading to increased volumetric pressure within the cystic cavity due to osmotic pressure. Consequently, large cystic lesions tend to shrink more rapidly than small lesions do.

The duration of decompression in this study was categorized as 120-240 days, 241-360 days, or > 360 days, according to the study of Bodner and Bar-Ziv,²⁴ who suggested that bone regeneration could be observed 3-4 months after the marsupialization of odontogenic cysts. This study revealed that the volume reduction rate was higher during the initial duration of decompression (120 to 240 days). However, this result was not statistically significant. This observation is consistent with Zhao et al.,⁹ who suggested that the initial duration of decompression was characterized by a high reduction rate and that enucleation can be conducted 6 to 12 months following marsupialization when enough bone growth has taken place. Additionally, Kwon et al.²⁵ recommended that the ideal duration of decom-

pression should be 3-14 months and that there should be a 50-60% reduction in cyst size before commencing enucleation. They also observed a similar percentage of volume reduction to that in this study. However, no statistically significant differences in the percentage of volume reduction and duration of decompression were found.

Jeong et al.⁶ showed that cystic lesions in the maxilla had higher mean reduction rates than those in the mandible. In contrast, Oliveros-Lopez et al.⁴ obtained statistically significant results that showed a higher reduction rate for odontogenic cysts in the mandible than in the maxilla. However, in this study, no significant differences were observed in reduction rates based on the location of the lesion. These findings are consistent with those of Anavi et al.,¹⁷ who suggested a comparable reduction rate for odontogenic cysts in both the maxilla and the mandible. Additionally, the authors of this study believe that enucleation, including the complete removal of the lesion, is the primary treatment option.

This study did not find any statistically significant impact of the type of decompression technique on reduction rates. However, the initial duration of decompression (120 to 240 days) was associated with a high reduction rate when using the tube drain technique. Conversely, during the later duration of decompression (>360 days), the highest reduction rate was found when the marsupialization technique was utilized. Therefore, the authors suggest the possibility of switching to the marsupialization technique in cases of large cystic lesions that slowly and persistently drain for more than 360 days. Because marsupialization removes the surrounding bone surface tension, which inhibits the proliferation and differentiation of osteogenic precursors, it activates signaling pathways to promote osteogenesis and modifies the expression of osteonectin and collagen type I,²⁰ which help promote bone formation while also relieving cyst pressure. In this study, no statistically significant differences were found in the reduction rates for various pathological diagnoses, thereby aligning with the findings reported by Jeong et al. and Anavi et al.^{6,17} However, the authors observed a higher reduction rate in orthokeratinized odontogenic cysts than in other types, specifically during the initial duration of decompression. This observation may be attributed to the large initial volume of orthokeratinized odontogenic cysts, which can lead to a higher reduction rate than observed for other cyst types.

Most comparative studies on the reduction rates and the percentage of volume reduction in preoperative and postoperative cystic lesions have used panoramic radiographs for the analysis.^{4,16,17} Panoramic radiography has some

advantages over CBCT, as it has a lower radiation exposure requirement and is less expensive. However, due to the limitations of 2-dimensional analysis, it lacks the ability to determine the distinct boundaries of cystic lesions, especially when their positioning overlaps with the spine. In contrast, CBCT allows measurements of the volume of a cystic lesion and exhibits high accuracy in precisely defining the cyst boundaries.^{6,28} The authors of this study utilized CBCT to examine the boundary and shape of cystic lesions in the axial, coronal, and sagittal planes in the form of a DICOM file and created an STL file for cystic volume analysis. The difference between volumetric analysis using a DICOM file and that using an STL file is that volumetric measurement using DICOM files involves a time-consuming process of manually marking images to localize the cyst outline on each CBCT slice. This method is prone to errors, especially when working with numerous slices. Additionally, DICOM measurements have limitations in assessing certain areas, such as the surface areas of tooth roots involved in the cyst and the irregular bone regeneration on the inner walls of the cyst volume after decompression.²⁹ Therefore, this study used STL files, which tend to provide more information about the surface of the volume, in conjunction with the determination of cystic lesion boundaries using HU. This method accurately predicts both the surface and volume of the cyst and is less time-consuming than making measurements with DICOM files.³⁰ The volumetric assessment of the cysts in this study was conducted using Mimics software.

Mimics software is straightforward to use. Martin et al.³¹ suggested that the program's user-friendly interface and the wide range of segmentation capabilities contributed to its high 3D modeling performance. These conclusions were supported by Tuan and Hutmacher,³² who found that Mimics software enabled better image manipulation, visualization, and function. However, a limitation of this retrospective study was the non-normality of the data, which can be attributed to the limited sample size used to determine the effects on the outcome variable. A reason for this small sample size is that only patients who had undergone CBCT were considered in this study. Additionally, there were difficulties in determining certain boundaries of cystic lesions that were in unclear positions.

In conclusion, decompression treatment for cysts was found to be more effective in males and for lesions with large initial volumes. Thereby, the variables of sex and initial volume demonstrated a statistically significant impact on the reduction rate, although no statistically significant impact was observed on the percentage of volume reduc-

tion. Additionally, factors such as age, duration of decompression, location of the lesion, decompression technique, and pathological diagnosis showed no statistically significant impact on the reduction rate or the percentage of volume reduction. Knowledge of the reduction rates of odontogenic cysts is vital for surgeons to evaluate the duration of decompression before enucleation and to determine a definitive treatment plan. Additionally, CBCT was found to be beneficial for measuring changes in cystic volume after decompression.

Conflicts of Interest: None

References

- Núñez-Urrutia S, Figueiredo R, Gay-Escoda C. Retrospective clinicopathological study of 418 odontogenic cysts. *Med Oral Patol Oral Cir Bucal* 2010; 15: e767-73.
- Kubota Y, Yamashiro T, Oka S, Ninomiya T, Ogata S, Shirasuna K. Relation between size of odontogenic jaw cysts and the pressure of fluid within. *Br J Oral Maxillofac Surg* 2004; 42: 391-5.
- Rajendra Santosh AB. Odontogenic cysts. *Dent Clin North Am* 2020; 64: 105-19.
- Oliveros-Lopez L, Fernandez-Olavarría A, Torres-Lagares D, Serrera-Figallo MA, Castillo-Oyagüe R, Segura-Egea JJ, et al. Reduction rate by decompression as a treatment of odontogenic cysts. *Med Oral Patol Oral Cir Bucal* 2017; 22: e643-50.
- Liang YJ, He WJ, Zheng PB, Liao GQ. Inferior alveolar nerve function recovers after decompression of large mandibular cystic lesions. *Oral Dis* 2015; 21: 674-8.
- Jeong HG, Hwang JJ, Lee SH, Nam W. Effect of decompression for patients with various jaw cysts based on a three-dimensional computed tomography analysis. *Oral Surg Oral Med Oral Pathol Oral Radiol* 2017; 123: 445-52.
- Lizio G, Sterrantino AF, Ragazzini S, Marchetti C. Volume reduction of cystic lesions after surgical decompression: a computerised three-dimensional computed tomographic evaluation. *Clin Oral Investig* 2013; 17: 1701-8.
- Muret M, Malthiéry E, Casenave T, Costes-Martineau V, Torres JH. Decompression: a first-intention treatment for “large” non-syndromic odontogenic keratocysts. *J Oral Med Oral Surg* 2021; 27: 29.
- Zhao Y, Liu B, Han QB, Wang SP, Wang YN. Changes in bone density and cyst volume after marsupialization of mandibular odontogenic keratocysts (keratocystic odontogenic tumors). *J Oral Maxillofac Surg* 2011; 69: 1361-6.
- Pogrel MA. Decompression and marsupialization as a treatment for the odontogenic keratocyst. *Oral Maxillofac Surg Clin North Am* 2003; 15: 415-27.
- Lizio G, Ferraioli L, Melini M, Marchetti C. Long-term investigation of decompression as a definitive treatment for mandibular cysts associated with impacted third molars. *J Am Dent Assoc* 2018; 149: 953-9.
- Qian WT, Ma ZG, Xie QY, Cai XY, Zhang Y, Yang C. Marsupialization facilitates eruption of dentigerous cyst-associated mandibular premolars in preadolescent patients. *J Oral Maxillofac Surg* 2013; 71: 1825-32.
- Berretta LM, Melo G, Mello FW, Lizio G, Rivero ER. Effectiveness of marsupialisation and decompression on the reduction of cystic jaw lesions: a systematic review. *Br J Oral Maxillofac Surg* 2021; 59: E17-42.
- Thomas EH. Cysts of the jaws; saving involved vital teeth by tube drainage. *J Oral Surg (Chic)* 1947; 5: 1-9.
- Wakolbinger R, Beck-Mannagetta J. Long-term results after treatment of extensive odontogenic cysts of the jaws: a review. *Clin Oral Investig* 2016; 20: 15-22.
- Lee ST, Kim SG, Moon SY, Oh JS, You JS, Kim JS. The effect of decompression as treatment of the cysts in the jaws: retrospective analysis. *J Korean Assoc Oral Maxillofac Surg* 2017; 43: 83-7.
- Anavi Y, Gal G, Miron H, Calderon S, Allon DM. Decompression of odontogenic cystic lesions: clinical long-term study of 73 cases. *Oral Surg Oral Med Oral Pathol Oral Radiol Endod* 2011; 112: 164-9.
- Gulsahi A, Kulah CK, Bakirarar B, Gulen O, Kamburoglu K. Age estimation based on pulp/tooth volume ratio measured on cone-beam CT images. *Dentomaxillofac Radiol* 2018; 47: 20170239.
- Scarfe WC, Farman AG, Sukovic P. Clinical applications of cone-beam computed tomography in dental practice. *J Can Dent Assoc* 2006; 72: 75-80.
- Consolo U, Bellini P, Melini GM, Ferri A, Lizio G. Analysis of marsupialization of mandibular cysts in improving the healing of related bone defects. *J Oral Maxillofac Surg* 2020; 78: 1355.e1-11.
- Brooks RA. A quantitative theory of the Hounsfield unit and its application to dual energy scanning. *J Comput Assist Tomogr* 1977; 1: 487-93.
- Bridge P, Tipper DJ. *CT anatomy for radiotherapy*. 2nd ed. Cumbria: M&K Pub; 2017.
- Ihan Hren N, Miljavec M. Spontaneous bone healing of the large bone defects in the mandible. *Int J Oral Maxillofac Surg* 2008; 37: 1111-6.
- Bodner L, Bar-Ziv J. Characteristics of bone formation following marsupialization of jaw cysts. *Dentomaxillofac Radiol* 1998; 27: 166-71.
- Kwon YJ, Ko KS, So BK, Kim DH, Jang HS, Kim SH, et al. Effect of decompression on jaw cystic lesions based on three-dimensional volumetric analysis. *Medicina (Kaunas)* 2020; 56: 602.
- Martin L, Speight PM. Odontogenic cysts. *Diagn Histopathol* 2015; 21: 359-69.
- Gao L, Wang XL, Li SM, Liu CY, Chen C, Li JW, et al. Decompression as a treatment for odontogenic cystic lesions of the jaw. *J Oral Maxillofac Surg* 2014; 72: 327-33.
- Asutay F, Atalay Y, Turamanlar O, Horata E, Burdurlu MÇ. Three-dimensional volumetric assessment of the effect of decompression on large mandibular odontogenic cystic lesions. *J Oral Maxillofac Surg* 2016; 74: 1159-66.
- Feher B, Frommlet F, Lettner S, Gruber R, Nemeth LE, Ulm

- C, et al. A volumetric prediction model for postoperative cyst shrinkage. *Clin Oral Investig* 2021; 25: 6093-9.
30. Turkyilmaz I, Wilkins GN, Benli M. Relationship between the data quality of digital scans from intraoral scanners and surface topography of prepared teeth. *J Dent Sci* 2022; 17: 592-4.
31. Martin CM, Roach VA, Nguyen N, Rice CL, Wilson TD. Comparison of 3D reconstructive technologies used for morphometric research and the translation of knowledge using a decision matrix. *Anat Sci Educ* 2013; 6: 393-403.
32. Tuan HS, Hutmacher DW. Application of micro CT and computation modeling in bone tissue engineering. *Comput Aided Des* 2005; 37: 1151-61.