


CLINICAL REVIEW

Ablation therapy for ventricular arrhythmias in patients with LVAD: Multiple faces of an electrophysiological challenge

Nicolò Sisti MD¹  | Amato Santoro MD¹ | Giovanni Carreras MD² |
Serafina Valente MD¹ | Stefano Donzelli MD² | Giulia Elena Mandoli MD¹ |
Carlotta Sciacaluga MD¹ | Matteo Cameli MD, PhD¹

¹Department of Cardiovascular Diseases, University of Siena, Siena, Italy

²Arrhythmology Unit, Cardiology Department, Terni Hospital, Terni, Italy

Correspondence

Nicolò Sisti, MD, Department of Cardiovascular Diseases, University of Siena, Siena, Italy.
Email: nic.sisti@gmail.com

Abstract

Left ventricular assist device implantation is a recognized treatment option for patients with advanced heart failure refractory to medical therapy and can be used both as bridge to transplantation and as destination therapy. The risk of ventricular arrhythmias is common after left ventricular assist device implantation and is influenced by pre-, peri and post-operative determinants. The management of ventricular arrhythmias can be a challenge when they become refractory to medication or to device therapy and their impact on prognosis can be detrimental despite the mechanical support. In this setting, catheter ablation is being increasingly recognized as a feasible option for patients in which standard therapeutic strategies fail, but also with preventive purpose. Catheter ablation is being increasingly considered for the management of ventricular arrhythmias in patients with left ventricular assist device despite complex clinical and technical peculiarities due to the characteristics of the mechanical support. Much conflicting data exist regarding the predictors of success of the procedure and the rate of recurrence. In this review we discuss the latest evidences regarding catheter ablation of ventricular arrhythmias in this subset of patients, focusing on clinical characteristics, arrhythmia etiology, technical aspects and postprocedural features which must be considered by the electrophysiologist.

KEYWORDS

advanced heart failure, catheter ablation, left ventricular assist devices, mechanical circulatory support, ventricular arrhythmias

1 | INTRODUCTION

Ventricular assist devices (VADs) represent a consolidated strategy used either as a bridge to cardiac transplantation or as destination therapy for nontransplant candidates.¹ The incidence of ventricular

arrhythmias (VAs) in patients with advanced heart failure reaches 5% and this burden persists with an upward trend after left ventricular assist device (LVAD) implantation.^{2,3} Around 28%–52% of patients with LVAD experience episodes of sustained VAs after implantation, with some authors considering those as the second most

All authors contributed equally to this work.

This is an open access article under the terms of the Creative Commons Attribution-NonCommercial-NoDerivs License, which permits use and distribution in any medium, provided the original work is properly cited, the use is non-commercial and no modifications or adaptations are made.

© 2021 The Authors. *Journal of Arrhythmia* published by John Wiley & Sons Australia, Ltd on behalf of the Japanese Heart Rhythm Society.

common post-procedural complication.^{4,5} According to the second INTERMACS study, VAs represent the first cause of mortality during the post-implantation period.⁶ Although mechanical circulatory support permits a better hemodynamic tolerance of the arrhythmia, with case reports documenting duration of more than 48 hours without impairment,⁷⁻⁹ right ventricular failure due to arrhythmias can exert detrimental effects on the efficacy of LVAD, especially in the presence of pulmonary hypertension.¹⁰ Antiarrhythmic drugs are often not successful for the treatment of events during post-implantation period but are useful as first-line therapy when the arrhythmia is not refractory. Drug classes Ib and III are the most used, often in association in the long term.^{11,12} Additional therapeutic strategies are represented by electrical cardioversion or implantable cardioverter defibrillator (ICD) implantation. Catheter ablation has been used for more than a decade in LVAD recipients, with Maury et al describing the first case of percutaneous RF ablation procedure for atrial arrhythmias¹³ and others such as Dandamudi et al or Osaki et al reporting the first experiences of VT ablation.^{14,15} Indication exists in case of incessant VAs, recurrent ICD interventions or progressive right ventricular failure, defined as the need of right ventricular support, prolonged use of pulmonary vasodilator or prolonged use of inotropes.¹⁶ This interventional procedure is characterized by specific technical and procedural variables with uncertain impact on outcome. The aim of this review was to summarize the main characteristics of VAs in LVAD patients, focusing on the role of transcatheter ablation in this population, outlining clinical and procedural outcomes.

2 | LVAD STRUCTURE AND MECHANISM

Common elements among the LVADs actually used are the inflow cannula that drains blood from the LV apex to the pump; the outflow cannula that delivers blood to the arterial circulation, typically inserted in the ascending aorta, and an electrical continuous-flow pump consisting in an impeller working at high speeds. LVADs can consist in an axial pump, such as the HeartMate 2 (HM 2) (Abbott Labs, Chicago, IL), or centrifugal pump, such as the HVAD (Medtronic, Inc, Minneapolis, MN) and HeartMate 3 (HM3) (Abbott Labs, Chicago, IL).¹⁷ The first-generation LVADs had pulsatile flow with the purpose of reproducing the cardiac function and were shown to improve the outcome of patients with end-stage HF compared to medical therapy.¹⁸ The second and third generation devices instead (eg HeartMate II, HVAD, HeartMate III) provide continuous flow which can reach 10 L/minute.¹⁹ LVAD flow increases proportionally to the pump speed and is inversely related to the pressure difference across the inflow and outflow. Although the continuous flow pattern, there are phasic changes due to the intrinsic cardiac cycle and its pressure variations.²⁰ It was the "HeartMate II" trial to show that continuous flow led to improved survival compared to pulsatile flow and with a significant reduction of adverse events and hospitalization.²¹ Power source of LVAD is represented by a percutaneous cable connecting the external batteries to the pump.

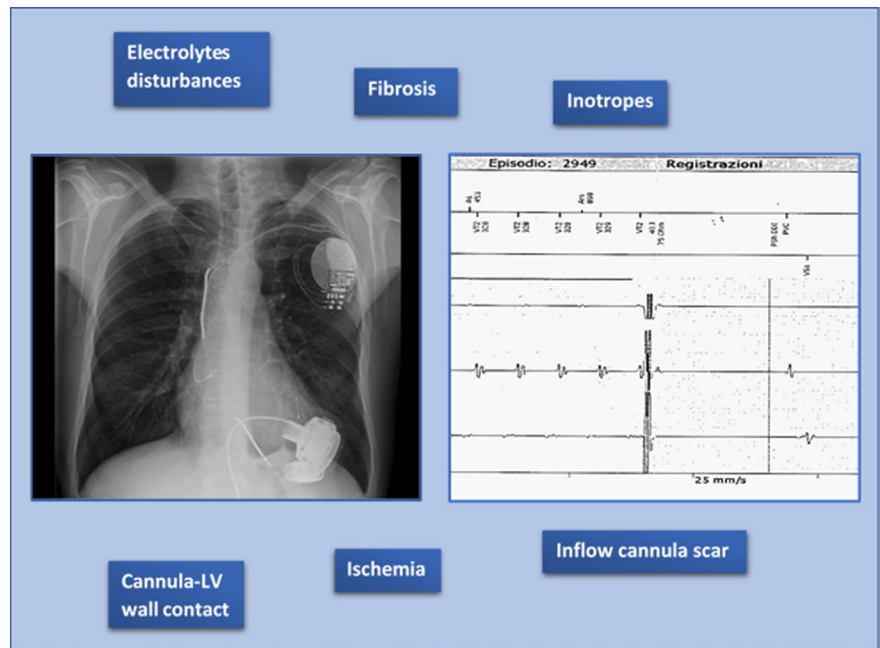
3 | EPIDEMIOLOGY

The results of the ASSIST ICD observational study highlighted that on a population of more than 66 implanted patients, 9% presented an electrical storm (ES) within nine months since implantation (interquartile range [IQR] 2.5-22.1), with the first event registered on the 17th day (IQR 4.0-56.2). Nearly 63% of patients with ES presented the first episode during the first month and 33% of patients had exitus within 2 weeks from ES. Almost 90% of ventricular arrhythmias (sustained and non-sustained) are symptomatic, both in LVAD and Biventricular assist device (BiVAD) patients.^{22,23} Not least, the onset of malignant VAs was associated with a seven-fold increase of mortality during the first post-operative days.²⁴

4 | ETIOLOGY OF VENTRICULAR ARRHYTHMIAS IN LVAD PATIENTS

The mechanisms triggering VAs span from subendocardial ischemia, myocytes remodeling and fibrosis, inotropes, electrolytes disturbances, mechanical contact with the device and inflow cannula-related scar.^{12,25} The analysis of Gordon et al and Enriquez et al points at monomorphic sustained ventricular tachycardia (VT) as the most recurrent arrhythmia (nearly 85% of cases), followed by ventricular fibrillation (VF) (31% of cases).^{3,26} The reported prevalence of inflow cannula related VAs is variable, ranging from 14% to 43%, since the same patients often have an intrinsic apical scar which makes difficult the recognition of the precise origin of the circuit.^{15,27,28} The most common definition of cannula-adjacent arrhythmia is that of an arrhythmia with origin within 2 cm from the inflow cannula.²⁹ Data from 44 inducible VTs among 611 recipients of LVAD, referred for electrophysiological (EP) study, documented a mean cycle length of 339 ± 59 ms and recorded a total number of 40 monomorphic VT (91%) with superior axis, right bundle branch block morphology, and 4 polymorphic VT or VF (8%). Electroanatomical mapping of these VAs demonstrated more frequently a reentrant mechanism related to intrinsic scar (75%) than to the apical inflow cannulation site (14%), focal/microreentry VT (7%) or bundle branch reentry (3.5%).³⁰ Sacher et al showed that cannula related VTs tend to manifest within 38 days from implantation with an increased incidence after 48 hours.³¹ An additional mechanism counting for 3% of cases³ could be linked to the contact between the inflow cannula and the left ventricular wall in case of excessive unloading. Such VTs are predominantly monomorphic, tends to occur in the immediate post-implantation period and are usually well responsive to pump speed reduction (Figure 1).^{32,33} Concerning the molecular mechanism, Refaat et al evidenced that in LVAD patients with VAs there is a down-regulation of proteins such as connexin 43, Na⁺/K⁺-ATPase, and voltage-gated K⁺ channel Kv 4.3, and an increase in the expression of sodium/calcium exchanger and structural genes such as titin, laminin, calsequestrin, skeletal muscle isoform of troponin T, and skeletal muscle isoform of troponin I.²² Finally, electrocardiograms (ECGs) registered in the first 6 hours after implantation

FIGURE 1 Main predisposing factors to ventricular arrhythmias in patients with left ventricular assist device



documented a statistically significant shortening of QRS duration and an increase in both QT and QTc,³⁴ potential additional determinants of arrhythmia.

5 | PREDICTORS OF ARRHYTHMIA IN LVAD PATIENTS

According to literature, the following are the most important predictors of VAs during the 12 months after implantation: history of VAs during pre-LVAD period, pre-implant atrial fibrillation, heart failure lasting more than 12 months, no therapy with ACE inhibitors and betablockers.^{4,24,35-37} In all the reviewed reports, the presence of VAs was associated with a significant increase in all-cause mortality (HR 7.28; 95% CI 3.50-15.15; $P = .001$). The same role of a history of VAs during pre-implantation period was confirmed in a case series of 61 patients treated at the University of North Carolina between 2006 and 2011. In this study, the presence of post-implantation VAs was associated with higher hospitalization rate and with an increased use of antiarrhythmic drugs.¹¹ Corre et al evidenced the following as important risk factors for electrical storm (ES) during post-implantation: high body surface area (BSA), history of VAs, previous ICD implantation, interruption of betablocker therapy, weaning from inotropes after 72 hours, use of extracorporeal membrane oxygenation (ECMO).³⁸ Many predictors of late VAs were recently summarized as the VT-LVAD score in the largest series published so far involving 494 LVAD recipients in 19 centers between 2006 and 2016. After multivariable analysis, predictors were history of VAs (HR 2.320, 95% CI 1.560-3.430, $P < .001$), no ACE inhibitors (HR 2.140, 95% CI 1.420-3.240, $P < .001$), heart failure duration >12 months (HR 2.580, 95% CI 1.470-4.530, $P < .001$) early VAs after implantation (HR 2.050, 95% CI 1.390-3.020, $P < .001$), history of atrial fibrillation (HR

1.720, 95% CI 1.150-2.580, $P = .009$) and non-ischemic cardiomyopathy (HR 1.500, 95% CI 1.010-2.220, $P = .045$).¹⁶ In the study by Bedi et al 22% of 111 patients undergoing LVAD implantation as bridge to transplantation had symptomatic VAs during support, which were more prevalent among patients with ischemic cardiomyopathy (71% in the group with VAs Vs 45% in the group without VAs, $P < .05$). VAs led to a significant increase of mortality rate compared to patients without history of arrhythmias (33% vs 18%, $P < .001$), particularly when the onset was within seven days from implant (54% vs 9%, $P < .001$).³⁹ Also brain natriuretic peptide (BNP) levels, indicators of severity of heart failure, seem to act as significant predictors of VAs in the post-implantation period (Table 1).⁴⁰

6 | TIMING OF VENTRICULAR ARRHYTHMIAS ABLATION IN CANDIDATES TO LVAD

6.1 | Ablation before implantation

The adequate timing of catheter ablation after LVAD implantation basically depends on the onset of the arrhythmia. In the case series by Corre et al the indication to ablation for ES was established in 8 patients on a total of 43 within 30 days from implantation.³⁸ Many authors agree that in patients with history of VAs catheter ablation performed before the implantation with prophylactic purpose could represent an overtreatment. The use of prophylactic epicardial and endocardial cryoablation, guided by visual inspection during surgical ventricular reconstruction in patients with preoperative inducible or spontaneous VTs, has proved to give a significant reduction in the inducibility of arrhythmia during the postoperative period and provided a more

Author	No. of implanted patients	Predictor	% of patients with predictor	P
Efimova et al ¹⁵	98	Pre-LVAD AF	75	,04
		Pre-LVAD VAs	39	,008
		Antiarrhythmic drugs	38	,01
Yoruk et al ⁴	149	Pre-LVAD AF	41	,007
		Pre-LVAD VAs	38	,012
Galand et al ¹⁶	494	Pre-LVAD AF	46	<,001
		Pre-LVAD VAs	33	<,001
		No ACE-i	52	<,001
		Non ischemic CM	28	,007
		Previous ICD	62	,001
Martins et al ²⁸	652	Pre-LVAD VAs	34	<,001
		Prolonged HF	20	<,001
		BBs before implantation	65	,002
		Previous ICD	62	,001
Raasch et al ¹¹	61	Pre-LVAD VAs	34	<,01
Bedi et al ³¹	111	Ischemic heart failure	71	<,05

Abbreviations: ACE-I, Angiotensin converting enzyme inhibitor; AF, atrial fibrillation; CM, cardiomyopathy; HF, heart failure; ICD, implantable cardioverter defibrillator; LVAD, left ventricular assist device; Vas, ventricular arrhythmias.

durable arrhythmia-free survival after the procedure.⁴¹ For this reason, some authors support the use of cryoablation in all LVAD patients with history of recurrent VAs and suggest to perform an EP-programmed electrical stimulation in the remaining patients, considering cryoablation at the time of implantation if inducibility is present.⁴² Snipelisky et al²⁸ considered 9 patients undergoing HeartMate (HM) II implantation and showed that, in those ablated previously to surgery, the burden of arrhythmias, shocks and anti-tachycardia pacing (ATPs), and also the number of EP procedures requested, increased after the ablation and during all the period between ablation and implantation (average time 238 days). This was probably due to the progression of the original cardiopathy.⁴³ LVAD implantation increases the risk of VAs when compared to the burden during the pre-implantation period. It explains why, even though catheter ablation causes a reduction of the arrhythmic burden, this one remains superior to the pre-implantation period. This fact points out that a complete elimination of the substrate is difficult.

6.2 | Ablation during implantation

There are few advantages in performing ablation during implantation. A combined epicardial and endocardial ablation provides a superior result and excellent visualization of the ablation site that cannot be achieved by endovascular techniques.⁴⁴⁻⁴⁶ Endocardial and epicardial ablation during implantation revealed to be safe with a significant reduction in the post-procedural arrhythmic burden,

TABLE 1 Significant predictors of ventricular arrhythmias in patients with left ventricular assist device according to cited studies

in particular when VAs were recurrent during the preoperative period. Mulloy et al suggested a concomitant surgical procedure and ablation through ventriculotomy after localizing the scar with cardiac magnetic resonance (CMR) or computed tomography (CT), performed previously to procedure in order to avoid prolonged extracorporeal circulation. In this report, cryoablation during implantation determined a significant reduction in intensive care unit (ICU) stay (165 vs 441 hours; $P = .01$) and global hospital stay (26 vs 57 days; $P = .03$).⁴² A single report showed an increased risk of thrombosis when endocardial ablation was associated to epicardial ablation during implantation, suggesting that in patients with a high thrombotic risk epicardial cryoablation alone could be safer than when associated with endocardial ablation.^{46,47} Patel et al reported cases of epicardial radiofrequency (RF) ablation performed in the immediate post-implantation period in 5 patients. After implantation, the patients were monitored in ICU, keeping the thoracic cavity covered only with the skin. Once the clinical stability was confirmed, the EP study was performed with substrate and activation mapping with subsequent successful ablation.⁴⁴ Moss et al⁴⁸ reported a case series of 36 patients who underwent open chest epicardial electro-anatomical mapping immediately prior to LVAD implantation. Mapping consisted in high density intraoperative epicardial voltage mapping and required a median of 11.8 minutes per patients. During a median follow-up of 311 post-operative days (IQR 168-469), 4 patients (27%) had sustained VAs and these patients had also showed a significantly higher burden of epicardial low bipolar voltage points: 55.4% vs 24.9% of points with voltage <0.5 mV ($P = .01$) and 88.9% vs 63.7% with voltage <1.5 mV ($P = .004$).

7 | ABLATION IN PATIENTS ALREADY IMPLANTED: TECHNICAL ASPECTS

7.1 | Planning the procedure

There are different technical features to be considered in the periprocedural setting of LVAD patients undergoing catheter ablation. Concerning ICD programming, all anti-tachycardia therapies must be interrupted before the procedure. Post-procedural ICD reprogramming must be performed considering the arrhythmia cycle length and the sensitivity to the overdrive pacing. In the experience of Moss et al, the VT zone was augmented to >190-200 bpm for shock erogation, with longer detection time and multiple ATPs pre shock (between 5 and 10), while the threshold for VF remained >250 bpm.²⁹ On the contrary, according to literature, no LVAD reprogramming is necessary before and after the procedure.¹⁶ A pre-procedural computed tomography (CT) scans can be useful in defining the inflow cannula projection into the ventricle and can aid with expeditious mapping during the procedure.⁴⁹ Epicardial mapping and ablation, which may be necessary in some cases, can be problematic in patients already implanted due to obliteration of the pericardial space following device placement and surrounding adhesions, as well as the potential hazard of damaging mechanical components of the system (cannulae, motor housing) or causing infection. An adequate planning of mapping and ablation at the time of initial LVAD placement can be helpful in these situations.⁴⁹

7.2 | Access to ventricular cavities

Ultrasound guidance for vascular access may be helpful due to reduced or absent pulses that would ordinarily mark the puncture sites. Peripheral arterial puncture can be challenging as well as the LV cavity access because of the reduced opening of the aortic valve and the encumbrance represented by the outflow cannula. Concerning the access to left ventricle (LV), the trans-septal puncture should be considered the first choice since the retrograde aortic access is usually limited by low peripheral arterial flow. Moreover the reduced opening of the aortic cusps represents a source of thromboembolism even in patients under anticoagulation therapy, making trans-esophageal echocardiography (TOE) very useful previously to the retrograde access.^{31,50} This step can also be facilitated by intracardiac echocardiography (ICE) through visualization of LV outflow tract and the aortic valve. Some operators suggest the use of a long sheath (deployed in the LV over a guidewire) to preserve LV access and prevent catheter dislodgement into the aortic root. Decreasing LVAD flow temporarily may allow LV ejection to open the aortic valve enough to allow catheter entrance. Retrograde aortic access may be the first choice if transseptal access cannot provide adequate reach, despite use of deflectable sheaths, to areas of importance, most often the basal septum and basal inferior LV segments.⁴⁹ Trans-septal access may be slightly favored given the avoidance of the outflow cannula and output graft in the aorta. Lowering the LVAD pump speed can

yield an increased left atrial (LA) and LV volume that may be beneficial in transseptal puncture and aid in maneuverability with the LV during mapping: LA volume is reduced due to the suction effect from the LVAD and adjustments of the LVAD settings may be needed before atrial septal puncture for accessing the LV.⁴⁹ A relevant issue to be considered is the inter-atrial shunt following the transseptal puncture, which usually resolves during the following 3 months.⁵¹ Atrial septal defect is a contraindication for LVAD placement given the risk of hypoxemia due to creation or exacerbation of right-to-left shunt following the left ventricular unloading which occurs during left ventricular support.⁵² Transoesophageal echocardiography should be routinely performed after procedure to exclude significant iatrogenic inter-atrial shunting also with different pump speed, since a high rate of long-term persistent atrial septal defect after transseptal puncture has been described.⁵³

7.3 | Troubleshooting and precautions

The reported risk of catheter entrapment in the inflow cannula and related suction is low, but the reduction of LV volume due to LVAD activity is a modification to be considered by the operator since can impede maneuverability.²⁸ In some case reports, the risk of catheter suction was controlled by reduction of pump speed during the procedure.⁵⁴ The main limiting factors, when ablation must be performed near the inflow cannula, are the power of RF, often inadequate nearby sutures, interferences with the mapping system and difficulty to reach the peri-cannula epicardial region.⁵⁵ The operator should carefully consider that in centrifugal LVAD pumps the inflow cannula accesses the rotating impeller directly with no turns, as with HVAD and HeartMate 3. In these settings, intracardiac echocardiography (ICE) can be very useful because modification of LV geometry secondary to LVAD placement can alter standard fluoroscopic views.⁵⁶ ICE, complementary to fluoroscopy, has a relevant role in avoiding that the catheter enters the impeller in particular using the representation of the inflow cannula in the anatomical map. This point must be mapped and eventually ablated with caution when the procedure is performed in the immediate post-implantation period given the fresh sutures (Figure 2).

Cases of refractory VAs were also reported in patients with LVAD and mechanical mitral prosthesis. In these cases, a trans-septal access was performed, and the valve was crossed through the peripheral ring, outer inferior orifice of the bi-leaflet tilting disk. No hemodynamic impairment or troubles of the valve were reported.⁵⁷

When surgical ablation is performed a history of coronary bypass surgery should be considered, in order to preserve bypass grafts and graft touchdowns. Moreover selective lung ventilation may be useful since deflation of the left lung permits optimal exposure of the anterior and lateral walls of the heart.⁵⁶

Anticoagulation should not be interrupted during ablation given the high risk of thromboembolism. In the case series reported in literature INR was kept between 2 and 3 or when UFH was preferred an ACT >250-300 s was maintained.³¹

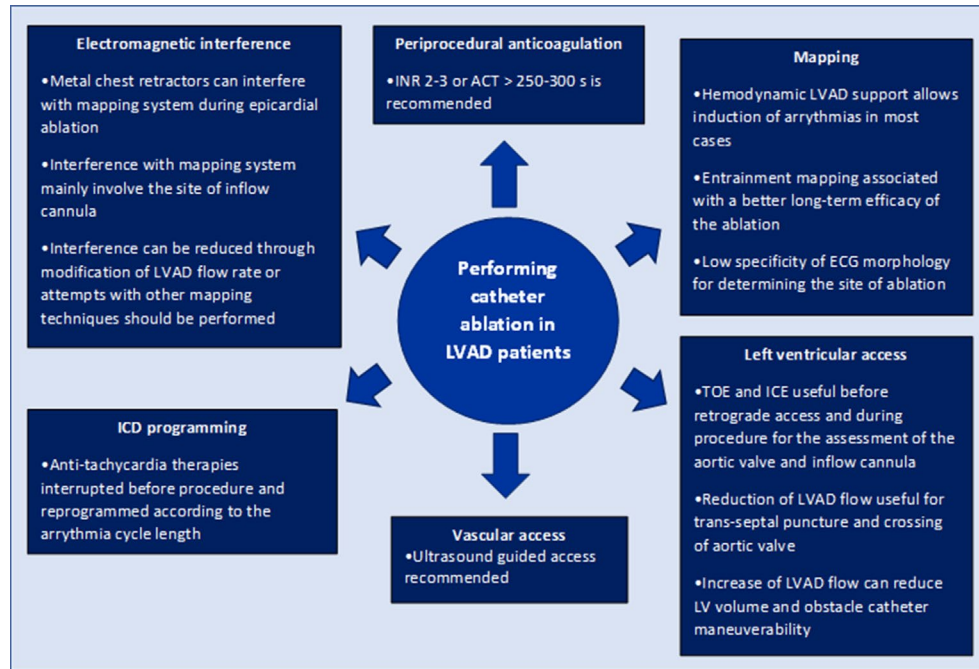


FIGURE 2 Schematic representation of the main technical aspects faced by operators during catheter ablation of LVAD patients. LVAD, left ventricular assist device; INR, international nationalized ratio; ACT, activated clotting time; TOE, trans-oesophageal echocardiography; ICE, intracardiac echocardiography; LV, left ventricle

8 | MAPPING: OVERVIEW

The hemodynamic stability given by LVAD permits to perform the induction of the arrhythmia in most of cases. In the largest cohort of patients with LVAD undergoing ablation, 75% of VAs were related to intrinsic scar, while only 14% were related to the cannulation site.³⁰ The same proportion was confirmed by Sacher et al using entrainment mapping and activation mapping in a population of 34 patients with LVAD undergoing ablation, showing that on a total of 110 VTs, 95% were dependent on macro-reentrants, 5% on micro-reentrants or focal activity, 9% related to scar of the inflow cannula.³¹ In the case series by Anderson et al the activation mapping and the entrainment mapping were used in 60% of cases, the substrate mapping in 20% of cases (<1.5 mV) and in the remaining 20% a combination of both was used. These proportion are different from non LVAD patients in whom the VAs ablation is predominantly guided by substrate mapping.⁵⁰

8.1 | Entrainment mapping

The use of entrainment mapping has been associated with a reduced incidence of arrhythmic relapses in the long term.²⁹ Entrainment mapping is a versatile tool that can help differentiate excellent ablation sites from bystanders and other poor ablation targets. In addition, entrainment mapping is more feasible in LVAD patients than in those without LVADs, as VTs in the former group are well tolerated.⁴⁹ Patients with RV failure may not tolerate sustained VT episodes even in the presence of a VAD and then care should be taken

to limit the total duration of VT during mapping to prevent severe RV decompensation.¹⁵

8.2 | Substrate and pace mapping

The substrate mapping is generally performed with the acquisition of voltage in unipolar and bipolar, during RV pacing or during sinus rhythm. Pace mapping may be used in concert with other mapping modalities as a mean of localizing possible exit sites of VT. When sites with matching to clinical VT are detected, particularly when longer stimuli to QRS are noted, these sites should be tagged and further investigated as sites that may be important to the VT circuits.⁵⁸ The ECG morphology has been correlated to the site of ablation only in 45% of cases in LVAD patients due to several factors such as intrinsic scar, anatomic distortion due to the device, LV decompression.⁴⁹ In particular, the typical ECG morphology of cannula related arrhythmias is right bundle branch block with superior axis, with precordial transition in V3-V5.²⁹ In case of periprocedural ablation, due to open chest exposure, ECG precordial leads are not available and only limb leads are reliable for determining the location of the VT origin or comparing the induced and clinical VTs. Mapping through a small incision impedes to map the entire chamber, and the lack of electroanatomic correlation may be challenging. In addition, the metal chest retractors can interfere with the mapping systems or prohibits mapping in certain areas of the heart.⁵⁶

Acceptable procedural endpoints, as with other VT ablations, include termination and non-inducibility of the clinical VT; whenever

possible, additional substrate modification and targeting of non-clinical VT can be done.⁴⁹

8.3 | Electromagnetic interference

Concerning electromagnetic interference (EMI), this can impede the localization of the mapping catheter and the interpretation of the ECG or EGM but does not seem to compromise the global outcome, being faced no more than in 1.8% of procedures.⁵⁰ Specifically, mapping systems that are reliant on magnetic fields (eg Carto, Biosense Webster, Diamond Bar, California and Rhythmia, Boston Scientific, Cambridge, Massachusetts) to create precise 3D shells, encounter multiple LVAD interactions including loss of catheter visualization, electro-anatomical point acquisition inhibition, loss of vector orientation, and loss of contact force readings, and thus accurate 3D mapping is inhibited when the patient is being supported with a partially or fully magnetic LVAD.⁵⁹ EMI seems to involve predominantly the LV apex, at the level of the inflow cannula. Solutions to EMI in these systems could be represented by positioning the patches away from the inflow cannula and reducing the speed of the device. Systems relying on impedance mapping (eg EnSite NavX, St. Jude Medical, St. Paul, Minnesota) have been successfully used in some reports without being disabled by EMI.^{31,60} The HM 3 causes high-frequency noise on the surface ECG that compromises morphology discrimination or pace mapping; noise seems to disappear with higher revolutions/minute during the delivery of pulse by the device every 2 seconds.^{50,56,61} In the case of HM 2, electromagnetic interference was rarely reported which troubled the catheter visualisation and substrate mapping at the level of the inferior or septal apical segments around the cannula and facing the turbine. This was avoided with the use of conventional mapping but also with impedance mapping.^{31,61}

9 | POST-PROCEDURAL FEATURES

9.1 | Recurrences and prognosis

A recent statement of the American Heart Association (AHA), based on literature revision, highlighted that the short term success of VAs ablation is around 77%–86%, with relapses in the long term spanning from 15% to 85%.⁵⁶ The study by Cantillon et al on patients undergoing LVAD implantation with symptomatic refractory VT referred for EP study and catheter ablation from 1991 to 2010 showed that the overall net mean survival of the cohort was 38 ± 4 months and 120 ± 90 days while on mechanical support. VT recurrence was in 7 of 21 patients (33%) at a mean of 133 ± 98 days, including 1 patient (5%) with recurrence of the previously ablated tachycardia. A repeat procedure was required in 6 patients (29%) with subsequent VT recurrence in 4 of 21 patients (19%).³⁰ Concerning medical therapy after the procedure, in the meta-analysis by Cantillon et al adjunctive medical therapy excluding beta-blockers was used in 7 of 21 patients (in detail 33% was treated with amiodarone: n 6; lidocaine/mexiletine: n 4; sotalol: n 1).³⁰

9.2 | Complications

In 8 case series comprehensive of 100 patients, pooled incidence of acute procedural complications was 9.4% (95% CI: 5.0% to 17.2%). 4.4% patients manifested minor complications, all with groin hematomas, and major complications occurred in 5.5%, with 2 cases of groin pseudoaneurysm requiring surgical repair, 2 cerebrovascular events, and cardiogenic shock in 1 patient.⁵⁰ Since the arterial puncture is often challenging the risk of groin hematoma is increased when compared to normal population. Moreover the risk of bleeding tends to be higher in case of epicardial ablation.⁶¹ Among complications, Moss et al showed that there is an increased incidence of pump thrombosis following ablation in LVAD patients, especially when it is performed next to the inflow cannula. The first recorded event occurred at 148 days and the median time to diagnosis was 273 days.⁴⁸ Thrombosis after endocardial ablation has a theoretical basis that deserves additional attention. As a general rule, ablation of a substrate determines a proinflammatory and thrombogenic state. Additionally, it is also possible that the LV endocardial surface is more inclined to be site of thrombus formation due to inflammation and injury that results from the ablation itself. There are alterations in blood flow within the LV related to flow into the LVAD cannula that can result in stasis within certain portions of the LV cavity (eg due to the inflow cannula position, the LV apex cannot contract causing blood stasis).^{46,47}

10 | CONCLUSION

Catheter ablation is an effective procedure in the management of VAs post LVAD implantation, often enough representing a treatment of last resort when ICD and drug therapy have failed. In this setting, ablation can improve the arrhythmogenic burden, being particularly effective in ES termination, and can promote the reduction of defibrillator shocks. The most known technical troubles such as catheter entrapment are infrequent and have showed no impact on procedural outcome. Scar related re-entry within pre-existing regions is the predominant mechanism of VT, while inflow cannula-related VT is responsible for a minority. Rates of transplantation and mortality are high, confirming that ablation is performed in a high risk population. Despite acute success of this procedure, VA frequently recurs and for this reason a first ablation strategy should be planned taking into account the evolution of the cardiomyopathy, the predisposing conditions to arrhythmias and the electrophysiologists' technical skills.

DISCLOSURE

All authors declare that they have no conflict of interest.

ORCID

Nicolò Sisti  <https://orcid.org/0000-0003-1795-855X>

REFERENCES

1. Cameli M, Loiacono F, Sparla S, Solari M, Iardino E, Mandoli GE, et al. Systematic left ventricular assist device implant eligibility

- with non-invasive assessment: the SIENA protocol. *J Cardiovasc Ultrasound*. 2017;25(2):39–46.
2. Nakahara S, Chien C, Gelow J, Dalouk K, Henrikson CA, Mudd J, et al. Ventricular arrhythmias after left ventricular assist device. *Circ Arrhythmia Electrophysiol*. 2013;6(3):648–54.
 3. Gordon JS, Maynes EJ, Choi JH, Wood CT, Weber MP, Morris RJ, et al. Ventricular arrhythmias following continuous-flow left ventricular assist device implantation: a systematic review. *Artif Organs*. 2020;44(8):E313–E325. <https://doi.org/10.1111/aor.13665>
 4. Yoruk A, Sherazi S, Massey HT, Kutiyfa V, McNitt S, Hallinan W, et al. Predictors and clinical relevance of ventricular tachyarrhythmias in ambulatory patients with a continuous flow left ventricular assist device. *Hear Rhythm*. 2016;13(5):1052–6.
 5. Yuan N, Arnaoutakis GJ, George TJ, Allen JG, Ju DG, Schaffer JM, et al. The spectrum of complications following left ventricular assist device placement. *J Card Surg*. 2012;27(5):630–8.
 6. Kirklin JK, Naftel DC, Kormos RL, Stevenson LW, Pagani FD, Miller MA, et al. Second INTERMACS annual report: more than 1,000 primary left ventricular assist device implants. *J Hear Lung Transplant*. 2010;29(1):1–10.
 7. Salzberg SP, Lachat ML, Zünd G, Turina MI. Left ventricular assist device (LVAD) enables survival during 7 h of sustained ventricular fibrillation. *Eur J Cardiothorac Surg*. 2004;26(2):444–6. <https://doi.org/10.1016/j.ejcts.2004.05.010>
 8. Sims DB, Rosner G, Uriel N, González-Costello J, Ehlert FA, Jorde UP. Twelve hours of sustained ventricular fibrillation supported by a continuous-flow left ventricular assist device. *Pacing Clin Electrophysiol*. 2012;35(5):e144–e148. <https://doi.org/10.1111/j.1540-8159.2011.03159.x>
 9. Butterfield M, Derr C, Keffeler J, Jelic T. Organized cardiac activity in an awake LVAD patient during ventricular fibrillation. *Am J Emerg Med*. 2017;35:1041.e1–1041.e3. <https://doi.org/10.1016/j.ajem.2017.03.001>
 10. Oz MC, Rose EA, Slater J, Kuiper JJ, Catanese KA, Levin HR. Malignant ventricular arrhythmias are well tolerated in patients receiving long-term left ventricular assist devices. *J Am Coll Cardiol*. 1994;24(7):1688–91.
 11. Raasch H, Jensen BC, Chang PP, Mounsey JP, Gehi AK, Chung EH, et al. Epidemiology, management, and outcomes of sustained ventricular arrhythmias after continuous-flow left ventricular assist device implantation. *Am Heart J*. 2011;164(3):373–8.
 12. Kadado AJ, Akar JG, Hummel JP. Arrhythmias after left ventricular assist device implantation: incidence and management. *Trends Cardiovasc Med*. 2018;28(1):41–50. <https://doi.org/10.1016/j.tcm.2017.07.002>
 13. Maury P, Delmas C, Trouillet C, Slaughter MS, Lairez O, Galinier M, et al. First experience of percutaneous radio-frequency ablation for atrial flutter and atrial fibrillation in a patient with HeartMate II left ventricular assist device. *J Interv Card Electrophysiol*. 2010;29(1):63–7. <https://doi.org/10.1007/s10840-010-9476-6>
 14. Osaki S, Alberte C, Murray MA, Brahmhatt RD, Johnson MR, Edwards NM, et al. Successful radiofrequency ablation therapy for intractable ventricular tachycardia with a ventricular assist device. *J Heart Lung Transplant*. 2008;27(3):353–6. <https://doi.org/10.1016/j.healun.2007.11.572>
 15. Dandamudi G, Ghuman WS, Das MK, Miller JM. Endocardial catheter ablation of ventricular tachycardia in patients with ventricular assist devices. *Heart Rhythm*. 2007;4(9):1165–9. <https://doi.org/10.1016/j.hrthm.2007.05.029>
 16. Garan AR, Iyer V, Whang W, Mody KP, Yuzefpolskaya M, Colombo PC, et al. Catheter ablation for ventricular tachyarrhythmias in patients supported by continuous-flow left ventricular assist devices. *ASAIO J*. 2014;60(3):311–6. <https://doi.org/10.1097/MAT.000000000000061>
 17. Moazami N, Fukamachi K, Kobayashi M, Smedira NG, Hoercher KJ, Massiello A, et al. Axial and centrifugal continuous-flow rotary pumps: a translation from pump mechanics to clinical practice. *J Heart Lung Transplant*. 2013;32:1–11. <https://doi.org/10.1016/j.healun.2012.10.001>
 18. Rose EA, Gelijns AC, Moskowitz AJ, Heitjan DF, Stevenson LW, Dembitsky W, et al. Long-term use of a left ventricular assist device for end-stage heart failure. *N Engl J Med*. 2001;345:1435–43.
 19. Sayer G, Naka Y, Jorde UP. Ventricular assist device therapy. *Cardiovasc Ther*. 2009;27:140–50.
 20. Pagani FD. Continuous-flow rotary left ventricular assist devices with “3rd generation” design. *Semin Thorac Cardiovasc Surg*. 2008;20:255–63. <https://doi.org/10.1053/j.semthor.2008.08.002>
 21. Slaughter MS, Rogers JG, Milano CA, Russell SD, Conte JV, Feldman D, et al. Advanced heart failure treated with continuous-flow left ventricular assist device. *N Engl J Med*. 2009;361:2241–51.
 22. Refaat M, Chemaly E, Lebeche D, Gwathmey JK, Hajjar RJ. Ventricular arrhythmias after left ventricular assist device implantation. *Pacing Clin Electrophysiol*. 2008;31(10):1246–52. <https://doi.org/10.1111/j.1540-8159.2008.01173.x>
 23. Mulukutla V, Lam W, Simpson L, Mathuria N. Successful catheter ablation of hemodynamically significant ventricular tachycardia in a patient with biventricular assist device support. *Hear Case Rep*. 2015;1(4):209–12.
 24. Galand V, Flécher E, Auffret V, Boulé S, Vincentelli A, Dambrin C, et al.; ASSIST-ICD Investigators. Predictors and clinical impact of late ventricular arrhythmias in patients with continuous-flow left ventricular assist devices. *JACC Clin Electrophysiol*. 2018;4(9):1166–75. <https://doi.org/10.1016/j.jacep.2018.05.006>
 25. Ziv O, Dizon J, Thosani A, Naka Y, Magnano AR, Garan H. Effects of left ventricular assist device therapy on ventricular arrhythmias. *J Am Coll Cardiol*. 2005;45(9):1428–34.
 26. Enriquez AD, Calenda B, Miller MA, Anyanwu AC, Pinney SP. The role of implantable cardioverter-defibrillators in patients with continuous flow left ventricular assist devices. *Circ Arrhythmia Electrophysiol*. 2013;6(4):668–74.
 27. Herweg B, Ilcil A, Kristof-Kuteyeva O, Rinde-Hoffman D, Caldeira C, Mangar D, et al. Clinical observations and outcome of ventricular tachycardia ablation in patients with left ventricular assist devices. *Pacing Clin Electrophysiol*. 2012;35(11):1377–83. <https://doi.org/10.1111/j.1540-8159.2012.03509.x>
 28. Snipelisky D, Reddy YN, Manocha K, Patel A, Dunlay SM, Friedman PA, et al. Effect of ventricular arrhythmia ablation in patients with heart mate II left ventricular assist devices: an evaluation of ablation therapy. *J Cardiovasc Electrophysiol*. 2017;28(1):68–77. <https://doi.org/10.1111/jce.13114>
 29. Nayak HM, Upadhyay GA, Burke MC, Jeevanandam V. Characterization of ventricular tachycardia after left ventricular assist device implantation as destination therapy. *JACC Clin Electrophysiol*. 2017;3(12):1412–24. <https://doi.org/10.1016/j.jacep.2017.05.012>
 30. Cantillon DJ, Bianco C, Wazni OM, Kanj M, Smedira NG, Wilkoff BL, et al. Electrophysiologic characteristics and catheter ablation of ventricular tachyarrhythmias among patients with heart failure on ventricular assist device support. *Hear Rhythm*. 2012;9(6):859–64.
 31. Sacher F, Reichlin T, Zado ES, Field ME, Viles-Gonzalez JF, Peichl P, et al. Characteristics of ventricular tachycardia ablation in patients with continuous flow left ventricular assist devices. *Circ Arrhythm Electrophysiol*. 2015;8(3):592–7. <https://doi.org/10.1161/CIRCEP.114.002394>
 32. Griffin JM, Katz JN. The burden of ventricular arrhythmias following left ventricular assist device implantation. *Arrhythmia Electrophysiol Rev*. 2014;3(3):145.
 33. Vollkron M, Voitl P, Ta J, Wieselthaler G, Schima H. Suction events during left ventricular support and ventricular arrhythmias. *J Hear Lung Transplant*. 2007;26(8):819–25.

34. Harding JD, Piacentino V, Gaughan JP, Houser SR, Margulies KB. Electrophysiological alterations after mechanical circulatory support in patients with advanced cardiac failure. *Circulation*. 2001;104(11):1241–7.
35. Efimova E, Fischer J, Bertagnolli L, Dinov B, Kircher S, Rolf S, et al. Predictors of ventricular arrhythmia after left ventricular assist device implantation: a large single-center observational study. *Heart Rhythm*. 2017;14(12):1812–9. <https://doi.org/10.1016/j.hrthm.2017.07.027>
36. Martins RP, Leclercq C, Bourenane H, Auffret V, Boulé S, Loobuyck V, et al. Incidence, predictors, and clinical impact of electrical storm in patients with left ventricular assist devices: new insights from the ASSIST-ICD study. *Heart Rhythm*. 2019;16(10):1506–12.
37. Sisti N, Mandoli GE, Sciacaluga C, Valente S, Mondillo S, Cameli M. Insight into atrial fibrillation in LVAD patients: from clinical implications to prognosis. *Pulse*. 2020;8(1-2):2–14.
38. Corre J, Picard F, Garcia R, Zemmoura A, Derval N, Denis A, et al. Electrical storm in the early phase of HeartMate® II device implantation: incidence, risk factors and prognosis. *Arch. Cardiovasc. Dis*. 2018;111(5):332–9.
39. Bedi M, Kormos R, Winowich S, McNamara DM, Mathier MA, Murali S. Ventricular arrhythmias during left ventricular assist device support. *Am J Cardiol*. 2007;99(8):1151–3. <https://doi.org/10.1016/j.amjcard.2006.11.051>
40. Hellman Y, Malik AS, Lin H, Shen C, Wang IW, Wozniak TC, et al. B-type natriuretic peptide levels predict ventricular arrhythmia post left ventricular assist device implantation. *Artif Organs*. 2015;39(12):1051–5. <https://doi.org/10.1111/aor.12486>
41. Dor V, Sabatier M, Montiglio F, Rossi P, Toso A, Di Donato M. Results of nonguided subtotal endocardectomy associated with left ventricular reconstruction in patients with ischemic ventricular arrhythmias. *J Thorac Cardiovasc Surg*. 1994;107:1301–7.
42. Mulloy DP, Bhamidipati CM, Stone ML, Ailawadi G, Bergin JD, Mahapatra S, et al. Cryoablation during left ventricular assist device implantation reduces postoperative ventricular tachyarrhythmias. *J Thorac Cardiovasc Surg*. 2013;145(5):1207–13.
43. Cameli M, Sparla S, Focardi M, Righini FM, Solari M, Alvino F, et al. Evaluation of right ventricular function in the management of patients referred for left ventricular assist device therapy. *Transplant Proc*. 2015;47(7):2166–8.
44. Patel M, Rojas F, Shabari FR, Simpson L, Cohn W, Frazier OH, et al. Safety and feasibility of open chest epicardial mapping and ablation of ventricular tachycardia during the period of left ventricular assist device implantation. *J Cardiovasc Electrophysiol*. 2016;27(1):95–101. <https://doi.org/10.1111/jce.12839>
45. Emaminia A, Nagji AS, Ailawadi G, Bergin JD, Kern JA. Concomitant left ventricular assist device placement and cryoablation for treatment of ventricular tachyarrhythmias associated with heart failure. *Ann Thorac Surg*. 2011;92(1):334–6.
46. McIlvennan CK, Babu AN, Brieky A, Ambardekar AV. Concomitant surgical cryoablation for refractory ventricular tachycardia and left ventricular assist device placement: a dual remedy but a recipe for thrombosis? *J Cardiothorac Surg*. 2016;11(1):53.
47. Casida JM, Combs P, Pavol MK, Hickey KT. Ready, set, go: how patients and caregivers are prepared for self-management of an implantable ventricular assist device. *ASAIO J*. 2018;64(6):e151–e155.
48. Moss JD, Oesterle A, Raiman M, Flatley EE, Beaser AD, Jeevanandam V, et al. Feasibility and utility of intraoperative epicardial scar characterization during left ventricular assist device implantation. *J Cardiovasc Electrophysiol*. 2019;30(2):183–92. <https://doi.org/10.1111/jce.13803>
49. Devabhaktuni SR, Shirazi JT, Miller JM. Mapping and ablation of ventricle arrhythmia in patients with left ventricular assist devices
50. Anderson RD, Lee G, Virk S, Bennett RG, Hayward CS, Muthiah K, et al. Catheter ablation of ventricular tachycardia in patients with a ventricular assist device: a systematic review of procedural characteristics and outcomes. *JACC Clin Electrophysiol*. 2019;5(1):39–51.
51. Rillig A, Meyerfeldt U, Birkemeyer R, Treusch F, Kunze M, Jung W. Persistent iatrogenic atrial septal defect after pulmonary vein isolation: incidence and clinical implications. *J Interv Card Electrophysiol*. 2008;22:177–81.
52. Baker JE, Stratmann G, Hoopes C, Donatello R, Tseng E, Russell IA. Profound hypoxemia resulting from shunting across an inadvertent atrial septal tear after left ventricular assist device placement. *Anesth Analg*. 2004;98:937–40.
53. Hammerstingl C, Lickfett L, Jeong KM, Troatz C, Wedekind JA, Tiemann K, et al. Persistence of iatrogenic atrial septal defect after pulmonary vein isolation—an underestimated risk? *Am Heart J*. 2006;152:362.e1–5.
54. Sipahi NF, Mehdiani A, Saeed D, Boeken U, Makimoto H, Lichtenberg A, et al. Successful treatment of ventricular arrhythmic storm with percutaneous coronary intervention and catheter ablation in a patient with left ventricular assist device. *Int J Artif Organs*. 2018;41(6):333–6. <https://doi.org/10.1177/0391398818768118>
55. Whang W, Patel MR, Iyer V, Gambhir A, Biviano AB, Garan AR, et al. Epicardial catheter ablation through subxiphoid surgical approach in a patient with implanted left ventricular assist device and cannula-related ventricular tachycardia. *Circ Hear Fail*. 2014;7(5):868–9.
56. Gopinathannair R, Cornwell WK, Dukes JW, Ellis CR, Hickey KT, Joglar JA, et al. Device therapy and arrhythmia management in left ventricular assist device recipients: a scientific statement from the American Heart Association. *Circulation*. 2019;139(20):E967–E989.
57. Herweg B, Ilercil A, Sheffield CD, Caldeira CC, Rinde-Hoffman D, Barold SS. Ablation of left ventricular tachycardia via transeptal approach and crossing of a mechanical mitral valve prosthesis. *Pacing Clin Electrophysiol*. 2010;33(7):900–3. <https://doi.org/10.1111/j.1540-8159.2009.02678.x>
58. Stevenson WG, Sager PT, Natterson PD, Saxon LA, Middlekauff HR, Wiener I. Relation of pace mapping QRS configuration and conduction delay to ventricular tachycardia reentry circuits in human infarct scars. *J Am Coll Cardiol*. 1995;26(2):481–8.
59. Andersen M, Videbæk R, Boesgaard S, Sander K, Hansen PB, Gustafsson F. Incidence of ventricular arrhythmias in patients on long-term support with a continuous-flow assist device (HeartMate II). *J Hear Lung Transplant*. 2009;28(7):733–5.
60. Trevisi N, Frontera A, Calore F, Okubo K, Della BP. Fast and safe mapping of ventricular tachycardia in patient with left ventricular assist device. *Clin Case Rep*. 2019;7(4):630–1. <https://doi.org/10.1002/ccr3.2004>
61. Schade A, Nentwich K, Deneke T. Catheter ablation of electrical storm in a patient with left ventricular assist device. *Herzschr Elektrophys*. 2014;25:102–4. <https://doi.org/10.1007/s00399-014-0311-0>

How to cite this article: Sisti N, Santoro A, Carreras G, et al. Ablation therapy for ventricular arrhythmias in patients with LVAD: Multiple faces of an electrophysiological challenge. *J Arrhythmia*. 2021;37:535–543. <https://doi.org/10.1002/joa3.12542>