

Case Report

Delayed Brain Infarction due to Bilateral Vertebral Artery Occlusion Which Occurred 5 Days after Cervical Trauma

Donghwan Jang, M.D., Choonghyo Kim, M.D., Seung Jin Lee, M.D., Jiha Kim, M.D.

Department of Neurosurgery, Kangwon National University Hospital, Chuncheon, Korea

Vertebral artery (VA) injuries usually accompany cervical trauma. Although these injuries are commonly asymptomatic, some result in vertebrobasilar infarction. The symptoms of VA occlusion have been reported to usually manifest within 24 hours after trauma. The symptoms of bilateral VA occlusions seem to be more severe and seem to occur with shorter latencies than those of unilateral occlusions. A 48-year-old man had a C3–4 fracture-dislocation with spinal cord compression that resulted from a traffic accident. After surgery, his initial quadriplegia gradually improved. However, he complained of sudden headache and dizziness on the 5th postoperative day. His motor weakness was abruptly aggravated. Radiologic evaluation revealed an infarction in the occipital lobe and cerebellum. Cerebral angiography revealed complete bilateral VA occlusion. We administered anticoagulation therapy. After 6 months, his weakness had only partially improved. This case demonstrates that delayed infarction due to bilateral VA occlusion can occur at latencies as long as 5 days. Thus, we recommend that patients with cervical traumas that may be accompanied by bilateral VA occlusion should be closely observed for longer than 5 days.

Key Words : Cervical trauma · Delayed infarction · Vertebral artery injury.

INTRODUCTION

Vertebral artery (VA) injuries commonly accompany blunt cervical trauma^{4,11,15,24}. Across articles, the reported incidences of VA injuries after cervical trauma range from 13% to 46%^{2,4,12,14,15}, and bilateral VA injuries are estimated to occur at approximately 10% of the frequency of unilateral VA injuries¹². However, bilateral VA injury was previously considered to be rare because of inadequate imaging modalities^{4,6,14}, or the clinical silence of this condition^{2,16,24}. The prompt diagnosis of VA injury requires a high index of suspicion, because the majority of patients exhibit no neurological symptom^{4,7,13,20,24}. Although the majority of VA injuries are asymptomatic, these injuries can potentially result in devastating outcomes that include cerebral, brain stem, and spinal cord ischemia^{2,4,6,10-13,15,17}.

Unilateral VA occlusion rarely results in neurological deficits because of the collateral blood supplies delivered by the contralateral VA and the posterior inferior cerebellar artery (PICA)^{8,18,24}. Whereas unilateral injuries are generally well tolerated, bilateral VA injuries can lead to vertebrobasilar insufficiencies or death¹⁸. Moreover, the neurologic symptoms due to VA occlusion usually manifest within 24 hours after cervical trauma²⁴.

Here, we present a case of a 48-year-old man who was involved in a motor vehicle accident from which he sustained cervical trauma that demanded operative stabilization. On the 5th postoperative day, he presented with delayed brain infarction due to bilateral VA occlusion. To our knowledge, this 5-day interlude between the trauma and symptom onset is exceptionally longer than those of most published cases of bilateral VA occlusion. Thus, our case is unique among previously reported cases wherein symptoms of bilateral VA occlusion were more immediately evident.

CASE REPORT

A 48-year-old man presented to the emergency department with cervical trauma. He had been involved in a motor vehicle accident while driving his car. On arrival at our hospital (3 hours after the trauma), the patient's vital signs were stable, and he was alert and fully oriented, but he complained of neck pain and quadriplegia. His bilateral upper extremity weakness was rated as grade 3/5 and grade 0/5 in the right and left biceps, respectively. His lower extremity weakness was rated as grade 4/5 and grade 3/5 in the right and left quadriceps, respectively. He also complained of a tingling sensation in left upper extremity. Neu-

• Received : April 8, 2014 • Revised : June 26, 2014 • Accepted : August 16, 2014

• Address for reprints : Jiha Kim, M.D.

Department of Neurosurgery, Kangwon National University Hospital, 156 Baengnyeong-ro, Chuncheon 200-722, Korea
Tel : +82-33-258-2410, Fax : +82-33-251-0374, E-mail : dopaa@naver.com

• This is an Open Access article distributed under the terms of the Creative Commons Attribution Non-Commercial License (<http://creativecommons.org/licenses/by-nc/3.0>) which permits unrestricted non-commercial use, distribution, and reproduction in any medium, provided the original work is properly cited.

rologic examination of the cranial nerves produced normal findings. An initial computed tomography (CT) scan of the brain was normal; however, plain X-ray and CT scan of the cervical spine revealed a cervical fracture-dislocation at the C3–4 level. Magnetic resonance imaging (MRI) demonstrated spinal cord compression and bilateral VA occlusion at the same level (Fig. 1).

We performed an operation immediately after ensuring the absence of associated organ injury. The operation was performed in two stages (i.e., via anterior and posterior approach) without the removal of general anesthesia. In the supine position, we performed C3–4 discectomy and fusion using the anterior cervical plate. After moving him to the prone position, we performed a C3–4 decompressive laminectomy and C3–4 fixation using lateral mass screws and bone chips (Fig. 2).

After the operation, his upper extremity weakness improved (i.e., from grade 3/5 to 4/5 in right biceps, from grade 0/5 to 2/5 in left biceps). However, on the 5th postoperative day, he suddenly presented with dizziness and headache. His right biceps motor strength also deteriorated abruptly from grade 4/5 to 2/5. MRI revealed an acute infarction in the left posterior cerebral artery (PCA) territory and the left cerebellar hemisphere (Fig. 3). CT

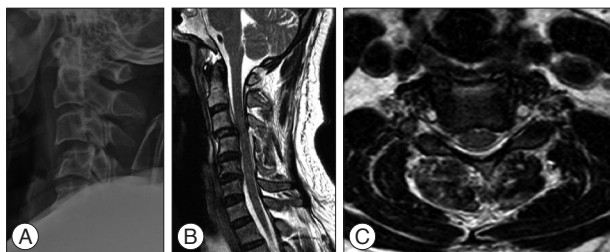


Fig. 1. Lateral plain X-ray on the first day showing cervical fracture-dislocation at the C3–4 level (A). T2-weighted MRI on the first day showing spinal cord compression in the sagittal view (B) and bilateral vertebral artery occlusion at the C4 level in the axial view (C).

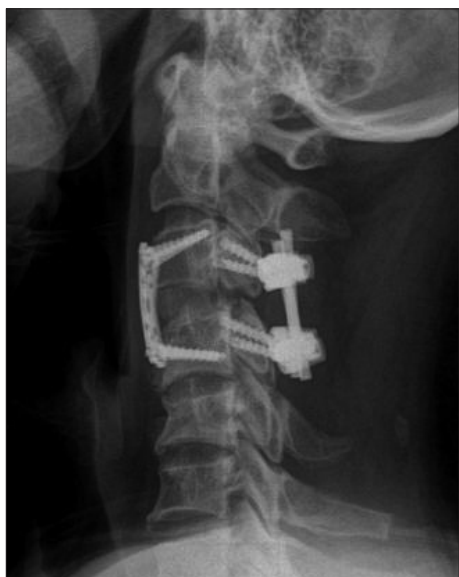

Fig. 2. Postoperative plain X-ray showing anterior and posterior fixation of the cervical spine at the C3–4 level in the lateral view.

angiography showed bilateral VA occlusion near the C3–4 level (Fig. 4). Cerebral angiography demonstrated complete occlusions of the bilateral VA and left PICA. However, collateral flows from the bilateral external carotid artery (ECA) via the occipital artery and ascending cervical artery were present (Fig. 5).

We promptly initiated anticoagulation therapy and increased the volume of intravenous fluid delivered. Thereafter, his motor weakness did not progress and his dizziness gradually improved. He was subsequently transferred to the rehabilitation department, where his weakness gradually improved. Six months later, follow-up visits revealed normal strength in both upper extremities, and he was able to walk with a cane at this time.

DISCUSSION

VA injuries after blunt cervical trauma have previously been considered to be rare; however, advancements in imaging modalities have greatly increased the rate of VA injury diagnoses^{4,14,23}. These diagnoses are difficult because the majority of patients do not present with neurological symptoms^{13,16,24}. VA occlusion is rarely symptomatic because of collateral blood supply from the contralateral VA and the circle of Willis^{2,13,22}. Moreover, injuries

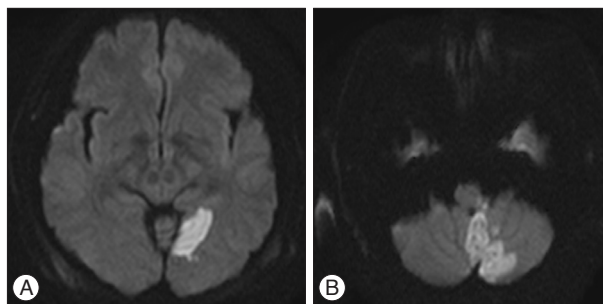


Fig. 3. Diffusion-weighted MRI on the 5th postoperative day showing infarctions in the left occipital lobe (A) and the left cerebellar hemisphere (B).

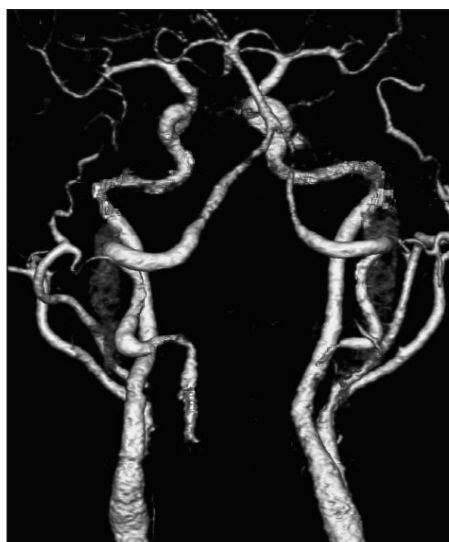

Fig. 4. CT angiography on the 5th postoperative day showing bilateral vertebral artery occlusion.

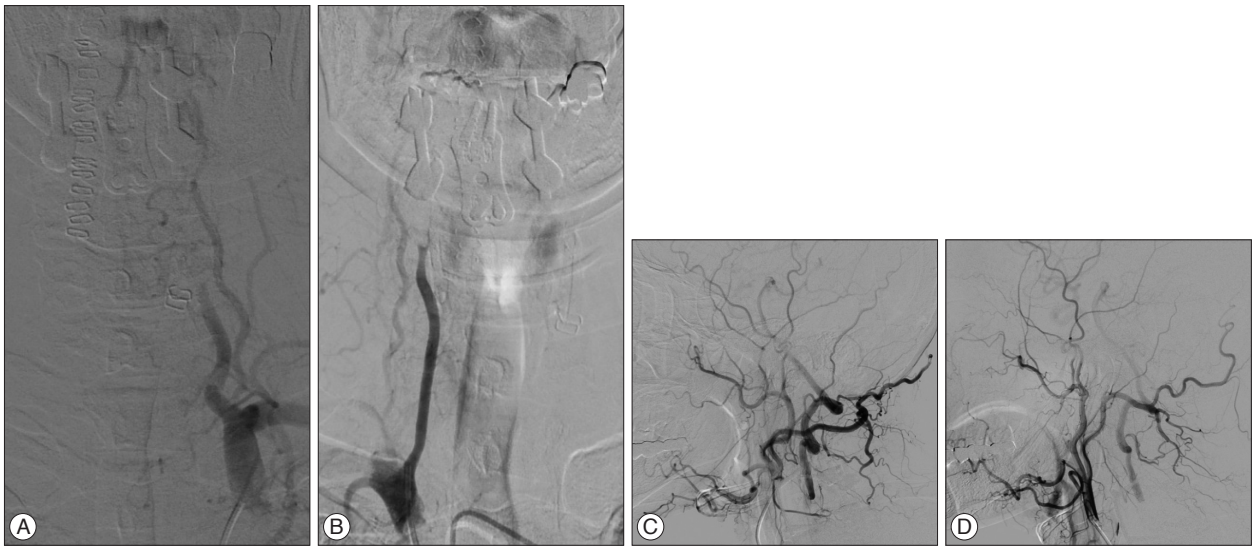

Fig. 5. Cerebral angiography on the 5th postoperative day showing complete occlusion of the bilateral vertebral artery, left (A) and right (B); collateral flows via the occipital arteries, left (C) and right (D).

to the non-dominant VA are not likely to be symptomatic². However, unlike unilateral VA occlusion, in which only 20% of patients are symptomatic^{4,24}, most patients with bilateral VA occlusion are symptomatic²⁴. Bilateral or dominant VA occlusion may cause rapid and fatal ischemic damage to the cerebellum and brain stem¹⁶.

Interlude

VA occlusions do not always cause ischemic symptoms immediately after the trauma. Many reported cases of posttraumatic VA occlusion have demonstrated asymptomatic interludes of a few hours between the trauma and the onset of neurologic symptoms^{17,24}. It has been suggested that intimal tears can lead to the aggregation of platelets on the exposed subintimal tissue and subsequent thrombosis, clot propagation and/or embolization to the cerebellum^{11,17,18}. It is likely that our case went through same process after traumatic VA dissection, causing progressive thromboembolic event. VA dissection usually arises from an intimal tear, which allows blood under arterial pressure to enter between the layers of the wall of the artery, forming an intramural hematoma, the so-called false lumen⁷. The interludes are likely due to the slow progression of thrombosis or the gradual swelling of the vessel^{18,24}. Woolsey and Chung²³ described an autopsy finding from a patient with a left VA occlusion that was followed by fatal basilar artery occlusion. The autopsy revealed an organized thrombus in the left VA and a fresh thrombus that occluded the entire basilar artery²³. The fresh thrombus in the basilar artery, which caused the brain stem infarction, seems to have gradually progressed from the left VA occlusion site after the initial insult.

We believe that the interludes in these cases represent the time period of thrombus propagation after which the infarction develops. Although some cases with longer interludes of up to several weeks or months have been reported, these cases are predominately cases of either unilateral or incomplete occlusion^{1,20}. In

many cases of bilateral VA occlusion, the interlude between the injury and the onset of ischemic symptoms occurs within hours^{3,19,24}.

The 5-day interlude observed in our case was exceptionally long and represents an extremely rare occurrence in cases of bilateral posttraumatic VA occlusion.

Collaterals

Fink et al.⁵ reported no significant difference in the incidence of stroke between patients with occlusive VA injuries and non-occlusive injuries. We believe this finding suggests that VA occlusion itself is not the sole factor that determines vertebrobasilar insufficiency or infarction. The size of the contralateral VA, the completeness of the circle of Willis, and the robustness of the native pial collateral seem to be important factors affecting the development of infarction after VA occlusion⁵.

Six et al.²¹ reported a case of asymptomatic bilateral posttraumatic VA occlusion. Although both VAs were occluded in this case, angiography demonstrated reconstitution by the intramuscular collateral vessels of the thyrocervical trunk and the collaterals from the superficial occipital artery. Collateral circulation may derive from the anterior circulation via the posterior communicating artery or from anastomoses via the branches of the ECA, the thyrocervical trunk, the costocervical trunk or the muscular and spinal branches of more proximal VAs⁴.

We believe that these abundant collateral channels resulted in the delayed symptom onset observed in our case. Our patient showed collateral flows from the bilateral ECA via the muscular branch of the occipital artery and the ascending cervical artery on cerebral angiography (Fig. 5). Although our patient's collateral blood supplies were able to meet posterior circulation demands to some extent, these demands could not be met over the course of several days due to bilateral VA occlusion.

Aspects of patients' premorbid state, such as atherosclerosis and VA dominance, should also be considered⁴. Bilateral VA occlu-

sion secondary to atherosclerosis is usually well tolerated, as this atherosclerosis is a slow process that allows for the development of collateral circulation¹⁸. Although our patient had diabetes mellitus, there was no evidence of cerebrovascular problems.

Infarction

Our patient had infarctions in the left occipital lobe and the left cerebellar hemisphere. We suggest that the infarctions in the cerebellar hemisphere and the occipital lobe were mediated by different mechanisms. Our patient's left PICA was completely occluded, which explains why the infarction involved only the left hemisphere; whereas both PCAs were patent on cerebral angiography.

The cerebellar infarction due to PICA occlusion was likely the result of the direct progression of thrombus from the VA injury site, which blocked the blood supply to the left cerebellar hemisphere. However, the left occipital lobe infarction was likely the result of an embolus, rather than thrombus formation. Emboli in the basilar territory do not commonly cause extensive brain stem infarction because an embolus of sufficient size to traverse the VA would be unlikely to occlude the larger diameter basilar artery²³. Such embolic fragments usually lodge in one or both PCAs²³. We propose that the left occipital lobe lesion was likely due to an embolus from the VA occlusion site because there was no infarction in the brain stem.

Screening and treatment

Screening for VA injury is warranted for certain high-risk patients at the time of presentation due to the potentials for both acute and delayed development of neurological sequelae^{12,15,17}. However, VA injury is not always accompanied by bone or spinal cord injury¹⁴. Neck manipulations by chiropractors and physiotherapists have also been reported to be associated with VA injury without cervical fracture^{4,20}. The mechanism responsible for VA injury has been suggested to be stretching, tearing of the intima and media, or compression of the vessels^{18,20}. Motor vehicle accidents are the leading cause of VA injury due to the major rotational component^{4,7}. Rotational forces applied to the mobile portions of the cervicocephalic arteries are responsible for intimal tears²⁰. Although bilateral VA dissection or occlusion is rare and found in only 0.1% of the patients with blunt trauma with angiography, its mechanism is likely to be same as unilateral one¹³. Galtés et al.⁷ described an autopsy finding from a patient with bilateral VA dissection after rotational neck injury, which is similar to unilateral one. Medhkour and Chan¹³ also mentioned chiropractic manipulation, motor vehicle crashes, or falls as the cause of bilateral VA injury. Chung et al.² stated that VAs that are located on the lateral aspect of the cervical spine are more susceptible to rotational injuries, whereas the spinal cord is more likely to be injured by sagittal plane insults such as compression and hyperflexion.

The presence of cervical spine injuries requiring operative stabilizations has not been found to be an independent risk factor

for VA injury¹². In the current study, the severity of the spinal cord injury, as indicated by the neurologic deficits, was not associated with VA injury². Because the severity of injury to the bone and/or spinal cord is not linearly correlated with the severity of VA injury, it is difficult to predict or screen for VA injury at the initial examination.

There are some controversies surrounding screening for VA injuries in patients with cervical trauma^{10,15}, that stem from the uncertainties regarding improved outcomes and the benefits of treatment¹⁵. The guidelines of the American Association of Neurological Surgeons state that "there is insufficient evidence to recommend anticoagulation in asymptomatic patients", and the risk of adverse effects of anticoagulation therapy may be as high as 14%¹². Although clinicians support either anticoagulation or antiplatelet therapy in symptomatic patients, the medical evidence surrounding this issue is inconclusive⁹. At present, there seems to be no consensus about the principles of treatment for VA injury, with the exception of individualization based on the specifics of the patient's VA injury, associated injuries, and risk of bleeding⁹.

CONCLUSION

Our case is unique in that a 5-day delay occurred between bilateral VA occlusion and symptom onset. Our patient experienced symptomatic brain infarction due to bilateral VA occlusion 5 days after cervical trauma. We recommend that close observation of patients with cervical traumas that may induce bilateral VA occlusion should continue for 5 days or longer.

References

1. Beletsky V, Nadareishvili Z, Lynch J, Shuaib A, Woolfenden A, Norris JW, et al. : Cervical arterial dissection : time for a therapeutic trial? *Stroke* 34 : 2856-2860, 2003
2. Chung D, Sung JK, Cho DC, Kang DH : Vertebral artery injury in destabilized midcervical spine trauma; predisposing factors and proposed mechanism. *Acta Neurochir (Wien)* 154 : 2091-2098; discussion 2098, 2012
3. Deen HG Jr, McGirr SJ : Vertebral artery injury associated with cervical spine fracture. Report of two cases. *Spine (Phila Pa 1976)* 17 : 230-234, 1992
4. Desouza RM, Crocker MJ, Haliasos N, Rennie A, Saxena A : Blunt traumatic vertebral artery injury : a clinical review. *Eur Spine J* 20 : 1405-1416, 2011
5. Fink KR, Fink JR, Cohen WA : Cervical collaterals may protect against stroke after blunt vertebral artery injury. *Emerg Radiol* 18 : 545-549, 2011
6. Friedman D, Flanders A, Thomas C, Millar W : Vertebral artery injury after acute cervical spine trauma : rate of occurrence as detected by MR angiography and assessment of clinical consequences. *AJR Am J Roentgenol* 164 : 443-447; discussion 448-449, 1995
7. Galtés I, Borondo JC, Cos M, Subirana M, Martin-Fumadó C, Castellà J, et al. : Traumatic bilateral vertebral artery dissection. *Forensic Sci Int* 214 : e12-e15, 2012
8. Golueke P, Sclafani S, Phillips T, Goldstein A, Scalea T, Duncan A : Vertebral artery injury--diagnosis and management. *J Trauma* 27 : 856-865, 1987

9. Harrigan MR, Hadley MN, Dhall SS, Walters BC, Aarabi B, Gelb DE, et al. : Management of vertebral artery injuries following non-penetrating cervical trauma. *Neurosurgery* 72 Suppl 2 : 234-243, 2013
10. Hart DJ : To screen or not to screen : vertebral artery injuries in blunt cervical spine trauma. *World Neurosurg* 80 : 309-310, 2013
11. Kim CH, Cho KT, Chung CK : Vertebral artery injury following blunt trauma to the cervical spine case report and literature review. *J Korean Neurosurg Soc* 35 : 625-627, 2004
12. Lebl DR, Bono CM, Velmahos G, Metkar U, Nguyen J, Harris MB : Vertebral artery injury associated with blunt cervical spine trauma : a multivariate regression analysis. *Spine (Phila Pa 1976)* 38 : 1352-1361, 2013
13. Medhkour A, Chan M : An unusually favorable outcome of bilateral vertebral arterial dissections : case report and review of the literature. *J Trauma* 58 : 1285-1289, 2005
14. Mimata Y, Murakami H, Sato K, Suzuki Y : Bilateral cerebellar and brain stem infarction resulting from vertebral artery injury following cervical trauma without radiographic damage of the spinal column : a case report. *Skeletal Radiol* 43 : 99-105, 2014
15. Mitha AP, Kalb S, Ribas-Nijkerk JC, Solano J, McDougall CG, Albuquerque FC, et al. : Clinical outcome after vertebral artery injury following blunt cervical spine trauma. *World Neurosurg* 80 : 399-404, 2013
16. Miyachi S, Okamura K, Watanabe M, Inoue N, Nagatani T, Takagi T : Cerebellar stroke due to vertebral artery occlusion after cervical spine trauma. Two case reports. *Spine (Phila Pa 1976)* 19 : 83-88, 1994
17. Mueller CA, Peters I, Podlogar M, Kovacs A, Urbach H, Schaller K, et al. : Vertebral artery injuries following cervical spine trauma : a prospective observational study. *Eur Spine J* 20 : 2202-2209, 2011
18. Muratsu H, Doita M, Yanagi T, Sekiguchi K, Nishida K, Tomioka M, et al. : Cerebellar infarction resulting from vertebral artery occlusion associated with a Jefferson fracture. *J Spinal Disord Tech* 18 : 293-296, 2005
19. Parent AD, Harkey HL, Touchstone DA, Smith EE, Smith RR : Lateral cervical spine dislocation and vertebral artery injury. *Neurosurgery* 31 : 501-509, 1992
20. Schneck M, Simionescu M, Bijari A : Bilateral vertebral artery dissection possibly precipitated in delayed fashion as a result of roller coaster rides. *J Stroke Cerebrovasc Dis* 17 : 39-41, 2008
21. Six EG, Stringer WL, Cowley AR, Davis CH Jr : Posttraumatic bilateral vertebral artery occlusion : case report. *J Neurosurg* 54 : 814-817, 1981
22. Taneichi H, Suda K, Kajino T, Kaneda K : Traumatically induced vertebral artery occlusion associated with cervical spine injuries : prospective study using magnetic resonance angiography. *Spine (Phila Pa 1976)* 30 : 1955-1962, 2005
23. Woolsey RM, Chung HD : Fatal basilar artery occlusion following cervical spine injury. *Paraplegia* 17 : 280-283, 1979
24. Yoshihara H, Vanderheiden TF, Harasaki Y, Beauchamp KM, Stahel PF : Fatal outcome after brain stem infarction related to bilateral vertebral artery occlusion - case report of a detrimental complication of cervical spine trauma. *Patient Saf Surg* 5 : 18, 2011