

## Testicular masses in a man with a plausible sarcoidosis

Om Albanin Paknejad, Mohammad Ali Sadighi Gilani<sup>1</sup>, Mahdi Khoshchereh<sup>2</sup>

Department of Pulmonology, Shariati Hospital, <sup>1</sup>Department of Infertility Genetics, Royan Institute, Infertility Clinic & Reproductive Biomedicine Research Center, <sup>2</sup>Evidence based medicine group, The Endocrine and Metabolism Research Center, Shariati Hospital, Tehran, Iran

### ABSTRACT

Genitourinary involvement with sarcoidosis is very rare. The objective of this report was to present a case of a patient with testicular swelling. The patient was an infertile 42-year-old man with bilateral testicular swelling. Semen analysis in the past 10 years revealed no abnormality; however, gradually he became azoospermic in 3 years. A diagnosis of sarcoidosis made on the basis of hilar and mediastinal lymphadenopathy in chest CT scan was confirmed through testicular and epididymal biopsy. Testicular masses vanished after administering steroids, and azoospermia recovered. To conclude, although genitourinary sarcoidosis is rare, it must be kept in mind in patients with confirmed sarcoidosis.

**Key words:** Granulomatosis, sarcoidosis, testicular mass

### INTRODUCTION

Sarcoidosis is a multisystem granulomatous disease of unknown etiology that affects individuals worldwide, usually involving the lungs and lymph nodes, and is characterized pathologically by the presence of noncaseating granulomas in the affected organs. Although almost any organ can be involved, genitourinary involvement with sarcoidosis is very rare. Up to now, less than 60 cases of sarcoidosis of the male genitourinary tract, with histological confirmation, have been reported in the English literature.<sup>[1]</sup> Because of its uncommon nature, the treatment of male reproductive tract sarcoidosis is controversial. Here, we present a case of testicular involvement of sarcoidosis.

### CASE REPORT

A 42-year-old man presented with intermittent,

**For correspondence:** Dr. Khoshchereh Mahdi, Evidence based medicine group, The Endocrine and Metabolism Research Center, Shariati Hospital, Tehran, Iran.  
E-mail: mahdi.kh@gmail.com

#### Access this article online

Quick Response Code:



Website:

www.indianjurol.com

DOI:

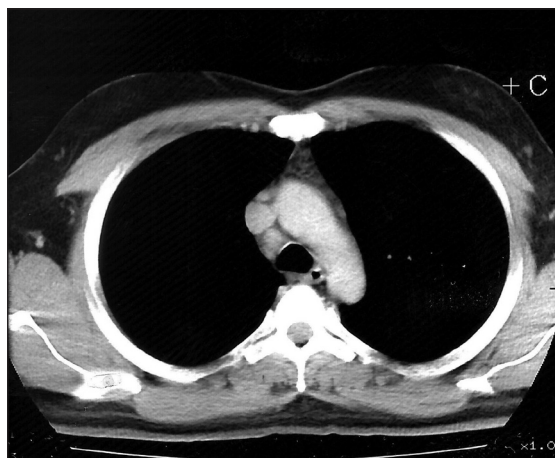
10.4103/0970-1591.82848

bilateral testicular pain and swelling of 1 month's duration, associated with a dry cough for 1 week. Dry cough and weight loss had begun 2 years before he visited our clinic, and he had been treated with a high-dose steroid for presumptive diagnosis of sarcoidosis at another hospital for less than a year. The diagnosis had been based on hilar and mediastinal lymphadenopathy found in chest computed tomography (CT), and chronic granulomatous inflammatory reaction in a bronchial mucosal biopsy.

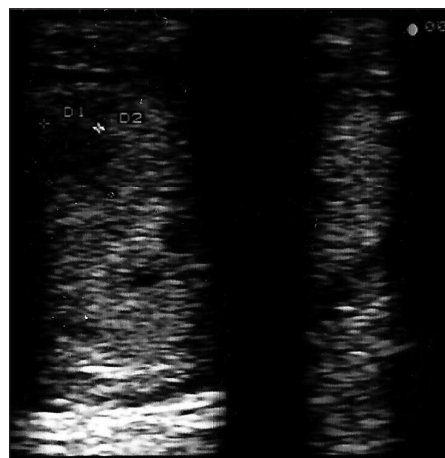
He had no complaints ever since, and he was under treatment with a low-dose steroid during this interval. He reported absence of symptoms such as dyspnea, chest discomfort, sputum production, night sweats, weight loss, skin rashes and dysuria, as well as other symptoms. He had a noncontributory family history. Additionally, he was infertile for more than 10 years, and *in vitro* fertilization (IVF) attempts were not successful.

His temperature was 37.3°C; heart rate, 80 to 90 beats/min; blood pressure, 140/92 mm Hg; and respiratory rate, 18 to 20 breaths/min. Physical examination revealed no lymphadenopathy; examination of head and neck, respiratory, cardiovascular systems and abdomen revealed no abnormality as well. The genitourinary examination was significant for firm and nontender testicular masses, especially on the right side, and a firm enlarged epididymis.

Laboratory investigations for CBC differential count, erythrocyte sedimentation rate, C-reactive protein, electrolytes, serum calcium and phosphorus levels, liver function, renal function, arterial blood gases, urine studies, urine calcium and urine protein, rheumatoid



**Figure 1:** CT scan of the chest prior to visiting our clinic, showing small mediastinal (right paratracheal and hilar) lymph nodes



**Figure 2:** Ultrasonography of the right testis, showing two hypoechoic testicular masses

factor, antinuclear antibodies, anti-neutrophil cytoplasmic antibodies (C.ANCA and P.ANCA), complement levels (C3, C4, CH50), adenosine deaminase, and serological studies for brucellosis all revealed results that were negative or within normal limits. Serum angiotensin converting enzyme (ACE) levels determined on several occasions in the past 3 years were on the higher side of the normal range. Tuberculosis skin test, tests for HIV, and serology findings with regard to hepatitis C and B were negative. Serum alpha fetoprotein and beta-human chorionic gonadotropin levels were also within normal limits. Semen analysis in the past 10 years revealed no abnormality; however, he gradually became azoospermic during the last 3 years.

The chest roentgenogram revealed no abnormalities. Chest computed tomography (CT) demonstrated small mediastinal (right paratracheal and hilar) lymph nodes [Figure 1]. The abdominal CT was normal.

Abdominopelvic and scrotal ultrasonography revealed scrotal thickening, a large epididymis with heterogeneous echo, and several hypoechoic testicular masses (3-4 mm) [Figure 2] but was otherwise normal.

Pulmonary function tests disclosed a normal pattern, without any reduction in the diffusing capacity for carbon monoxide.

Bronchoalveolar lavage (BAL) demonstrated a reduced number of CD8 cells, as well as an elevated CD4-to-CD8 ratio. Direct smear and culture of bronchial washing samples was negative for acid-fast bacilli, fungi or any pathogenic bacteria. There was no evidence of lymphoma or malignancy.

Findings of the bronchial mucosal biopsy were compatible with chronic granulomatous inflammatory reaction.

## DISCUSSION

The etiology of sarcoidosis remains undetermined.

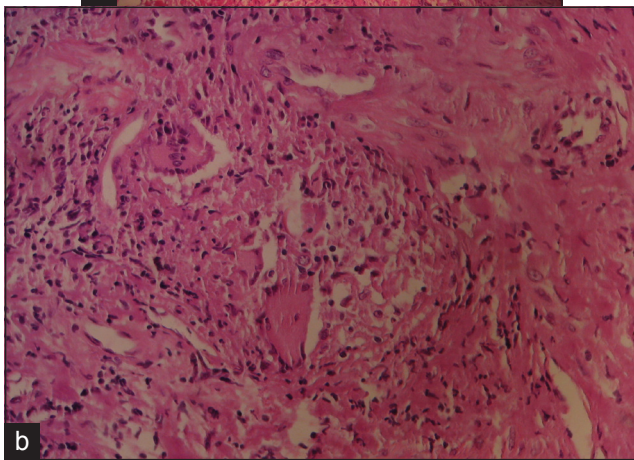
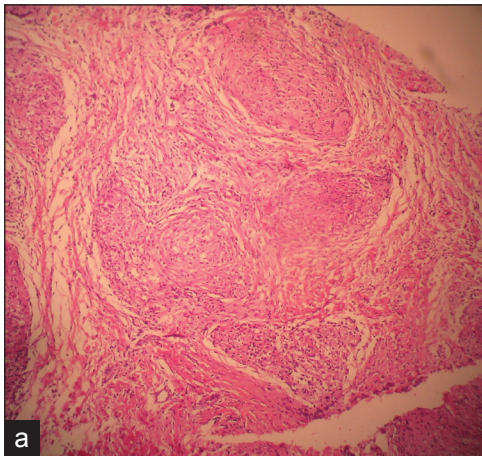
Sarcoidosis presents in a variety of ways, but the disease usually localizes to the chest in 80% to 90% of patients, characterized by bilateral, hilar lymphadenopathy on chest radiographs, which are precise, evocative findings for the diagnosis. Although noncaseating granulomas on biopsy are very suggestive, the diagnosis is ultimately one of ruling out other conditions.

The genitourinary tract is involved in sarcoidosis in 0.2% of the clinically diagnosed cases and in 5% of the cases found at autopsy.<sup>[2]</sup> It is 10 times more frequent in black men and has a greater prevalence in the southeastern United States.<sup>[3]</sup> Manifestations of genitourinary sarcoidosis include usually painless, unilateral, nodular and diffuse testicular masses; acute epididymo-orchitis, and renal disorders with nephrocalcinosis.<sup>[4]</sup> Following the identification of a scrotal mass, differential diagnosis includes tuberculosis, sperm granulomas, cysts, fungal diseases and, the most notable, testicular cancer.

Testicular involvement of sarcoidosis is extremely rare. In order of decreasing incidence of genital sarcoidosis, however, it is placed between epididymal and prostate gland sarcoidosis.

Some reports consider an association between testicular cancer and sarcoidosis. An excessively high incidence of testicular cancer (generally seminoma) in a number of patients with simultaneous sarcoidosis has been reported.<sup>[5]</sup> However, metastatic lesions that are radiographically and pathologically identical to sarcoidosis have been reported in patients with resected testicular cancer after a disease-free interval of 8 years, as well as the absence of recurrence at the primary site.

Even though fertility-related sequels of genitourinary sarcoidosis have not been studied so far, azoospermia and hypogonadism may be caused by fibrosis and occlusion of



**Figure 3:** (a-b) Intraoperative ultrasound-guided biopsy; showing fibrotic tissue with a non-necrotizing granuloma made up of epithelioid and giant cells and focal lymphatic infiltration (Magnification:  $\times 40$  and  $\times 100$  respectively)

the epididymal duct. Steroid therapy has been reported recently to be beneficial in raising sperm counts (and to some extent, ductal occlusion).

Two main approaches to genitourinary sarcoidosis have been proposed. Based on the marked relationship between testicular cancer and sarcoidosis, orchiectomy is recommended, even if evidence of sarcoidosis in other organs is present. By contrast, others consider immediate orchiectomy as being quite aggressive because of several factors associated with a benign diagnosis, as well as the involvement of the epididymis or vas deferens and bilateral testicular involvement. If the malignant diagnosis is established by exploration and intraoperative ultrasound-guided biopsy, orchiectomy is performed in cases of diffuse involvement of a testis. Spontaneous resolution has been reported in 50% to 70% of patients with active sarcoidosis. If the diagnosis is not established unequivocally, immunosuppressive agents (frequently steroids) will resolve the inflammation in patients who wish to salvage their

fertility; and in those with severely advanced disease, after careful consideration.

A new approach has been proposed recently, based on the absence of evidence for malignant transformation in pathologically confirmed benign diagnosed testicular sarcoidosis, and it involves the open exploration of both testes, with resection of the largest lesion (on the right tunica). In this technique, patient was not given steroids after the operation. Nevertheless, careful follow-up may be preferred to medication or surgery in certain clinical settings.

In our case, because of the patient's desire for maintaining his fertility and the absence of evidence of malignancy, the patient underwent unilateral testicular and epididymal biopsy. The biopsy revealed fibrotic tissue with a non-necrotizing granuloma made up of epithelioid and giant cells and focal lymphatic infiltration [Figures 3 and 4]. The diagnosis was in favor of chronic non-necrotizing granulomatous inflammation. After the administration of steroids (prednisolone, 30 mg/d), testicular masses vanished, and the patient was followed up with ultrasonography. The azoospermia recovered, and zygote intra-fallopian transfer (ZIFT) was performed. The patient has not had a recurrence of any sarcoidosis lesions during the 2-year follow-up period.

In conclusion, although genitourinary sarcoidosis is rare, it must be taken into consideration, in patients with confirmed sarcoidosis, since the diagnosis can prevent unnecessary orchiectomies.

## REFERENCES

1. Kodama K, Hasegawa T, Egawa M, Tomosugi N, Mukai A, Namiki M. Bilateral epididymal sarcoidosis presenting without radiographic evidence of intrathoracic lesion: Review of sarcoidosis involving the male reproductive tract. *Int J Urol* 2004;11:345-8.
2. Turk CO, Schacht M, Ross L. Diagnosis and management of testicular sarcoidosis. *J Urol* 1986;135:380-1.
3. Heffner JE, Milam MG. Sarcoid-like hilar and mediastinal lymphadenopathy in a patient with metastatic testicular cancer. *Cancer* 1987;60:1545-7.
4. Rees DA, Dodds AL, Rathbone N, Davies JS, Scanlon MF. Azoospermia in testicular sarcoidosis is an indication for corticosteroid therapy. *Fertil Steril* 2004;82:1672-4.
5. Massarweh NN, Bhalani VK, Shaw KK, Crawford B, Lang E, Davis R. Testicular presentation of sarcoidosis and organ preservation: Case report and review of management strategies. *Urology* 2006;67:200.

**How to cite this article:** Paknejad O, Gilani MS, Khoshchreh M. Testicular masses in a man with a plausible sarcoidosis. *Indian J Urol* 2011;27:268-71.

**Source of Support:** Nil, **Conflict of Interest:** None declared.