

## Review Article

# Treatment of Bullous Systemic Lupus Erythematosus

Lihua Duan,<sup>1</sup> Liying Chen,<sup>1</sup> Shan Zhong,<sup>2</sup> Ying Wang,<sup>1</sup> Yan Huang,<sup>1</sup>  
Yan He,<sup>1</sup> Jie Chen,<sup>3</sup> and Guixiu Shi<sup>1</sup>

<sup>1</sup>Department of Rheumatology and Clinical Immunology, The First Hospital of Xiamen University, Xiamen 361003, China

<sup>2</sup>Department of Pathology, The First Hospital of Xiamen University, Xiamen 361003, China

<sup>3</sup>Department of Immunology, College of Medicine, Xiamen University, Xiamen 361102, China

Correspondence should be addressed to Lihua Duan; lh-duan@163.com and Guixiu Shi; guixiu.shi@gmail.com

Received 5 August 2014; Accepted 21 August 2014

Academic Editor: Jianying Zhang

Copyright © 2015 Lihua Duan et al. This is an open access article distributed under the Creative Commons Attribution License, which permits unrestricted use, distribution, and reproduction in any medium, provided the original work is properly cited.

Bullous systemic lupus erythematosus (BSLE) is an autoantibody-mediated vesiculobullous disease in patients with SLE. Autoimmunity in BSLE is characterized by the presence of circulating anti-type VII collagen antibodies. BSLE patients often present with multiple, tense, clear fluid-filled vesicles and bullae overlying erythematous edematous plaques. Skin biopsy from BSLE patients shows subepidermal bullae with numerous neutrophils and only occasional eosinophils. Furthermore, immunofluorescence examination showed linear deposition of IgG, IgA, C3, and C1q along the basement membrane zone. BSLE patients with corticosteroids treatment constantly do not receive a marked improvement, while dapsone generally dramatically improved the skin condition. Recently, it has been reported that quite a few cases of BSLE were successfully treated with other immune suppressive drugs. Therefore, a comprehensive review of the treatment of BSLE would be beneficial to cure the disease.

## 1. Introduction

Bullous systemic lupus erythematosus (BSLE) is a subepidermal blistering disease that occurs in a subset of patients with systemic lupus erythematosus (SLE) [1, 2]. Cutaneous lesions are reported during the course of SLE in 76% of patients; however, it has been reported that BSLE is very rare and occurs in less than 1% of patients with SLE [3–5]. Clinically, in addition to the features of SLE, the BSLE patients especially present with a rapid, widespread development of tense fluid-filled vesicles and bullae. Moreover, this blistering disease may vary from a small group of vesicles to large tense blisters with urticarial eruptions, erosions, itching, and crustations. Histologically, BSLE is characterized by a subepidermal blister, with a predominantly neutrophilic dermal infiltrate and only occasional eosinophils. Furthermore, immunofluorescence examination showed linear deposition of IgG, IgA, C3, and C1q along the basement membrane zone [5, 6]. Because of the particularly clinical and histological presentation of BSLE, Camisa and Sharma proposed diagnostic criteria for BSLE; these include a diagnosis of SLE based on the following criteria of the ACR; vesicles and bullae mainly located on

sun-exposed areas; the histopathology is characterised by subepidermal bullae with microabscesses of neutrophils in the dermal papillae, similar to those found in dermatitis herpetiformis and deposition of IgG, IgM, or both and often IgA in the basement membrane zone [7].

Although BSLE may exhibit any of the symptoms associated with SLE, the onset and course of blistering eruption do not necessarily parallel the activity of the systemic involvement [8]. Furthermore, the therapeutic options for SLE are not usually fit for BSLE [9, 10]. In some cases, the eruption flared after systemic corticosteroid administration for SLE [11, 12]. However, most of the patients have a striking therapeutic response to dapsone [13–16]. A response may be seen with very small doses of dapsone [1]. In the case of the present paper, we report a significantly and clinically meaningful improvement of BSLE following dapsone administration. Other drugs such as cyclophosphamide, azathioprine, and mycophenolate mofetil and biologic drugs may also be effective for BSLE treatment [17]. In the part of literature review, we provide a review of all the available treatment options for BSLE.

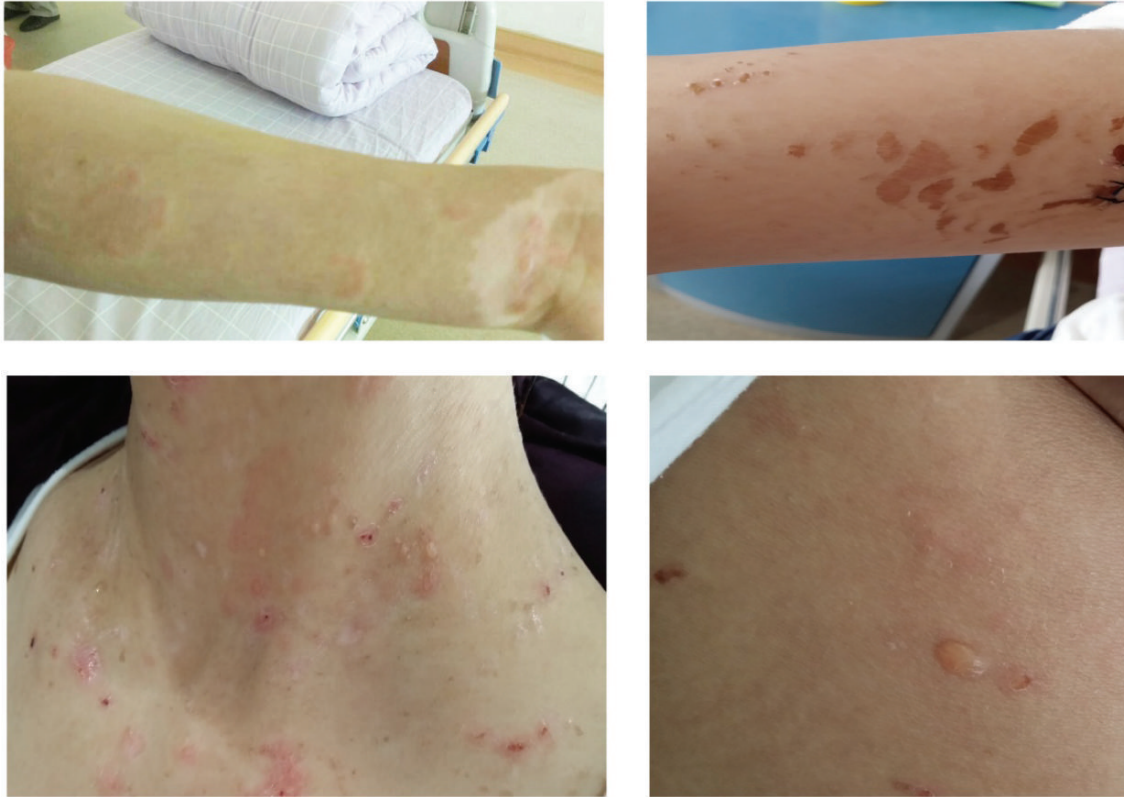

FIGURE 1: Gross view of the skin lesion. Presence of tense vesicles (marked with an arrow) filled with clear fluid on the arm, neck, and back.

## 2. Literature Review

Steroids and antimalarials are the standard treatments for the cutaneous manifestations of SLE. In unresponsive patients, azathioprine and high dose or pulse steroids, cyclosporin, and pulse cyclophosphamide are the most commonly used alternative therapies [18–20]. Dapsone is less used in the control of the SLE rash but has a dramatic improvement in the eruption of BSLE patients [15, 16]. A relatively low dose has also been shown to be an efficacious response. We also found that a 22-year-old woman with BSLE had multiple tense vesiculobullous lesions on the face, trunk, and limb (Figure 1). A biopsy from the upper limb showed a subepidermal blister with a predominantly neutrophilic dermal infiltrate and only occasional eosinophils (Figure 2(a)). Immunofluorescence showed a granular band of C1q, C3, and IgG at the basement membrane; less IgA and IgM were observed (Figures 2(b)–2(f)). The skin condition showed no response in the methylprednisolone, while a considerable improvement after dapsone administration was observed. Regarding the special clinical feature and the discriminative therapies from the SLE treatments, we review all the available treatment for BSLE.

**2.1. Dapsone.** Dapsone is a sulfone that has played a critical role in the eradication of leprosy [21]. Besides, a number of cutaneous eruptions are effectively controlled by dapsone [22]. Due to these eruptions that are largely characterized by the presence of cutaneous neutrophilic dermal infiltrate

[22], such as dermatitis herpetiformis and the inflammatory variant of epidermolysis bullosa acquisita, the mechanism of its anti-inflammatory action mainly relies upon its inhibition of the functions of polymorphonuclearleukocytes and of complement activation via the alternative pathway that has been postulated [15, 23]. Although a new or recurrent rash was considered a factor of SLE disease activity index, the eruption of BSLE was not constantly associated with a flare of SLE [8]. Consequently, because of being unparallel with the disease activity, the eruption of BSLE patients is often unresponsive to corticosteroid therapy. Due to the striking histologic resemblance to dermatitis herpetiformis, the patients who were treated with dapsone (2 mg/kg/day) usually obtained a dramatic improvement in the eruption. Patients tend to have an efficacious response with cessation of new blister formation in 1-2 days and healing of existing lesions within several days. A relatively low dose (25–50 mg) has also been shown to have a response [1, 15, 24]. Interestingly, improvement of the eruption did not correlate with amelioration of the systemic manifestations [25]. The dramatic response to dapsone therapy demonstrated that dapsone is useful in treating bullous lesions of SLE [5, 15, 16, 26]. Notably, the blistering eruption was not improved by dapsone in some cases, and even worsening has been noted after its administration. It has been reported that patients with BSLE, who initially presented with lesions clinically resembling erythema multiforme, experienced exacerbation of their disease with dapsone [27–29]. Furthermore, dapsone

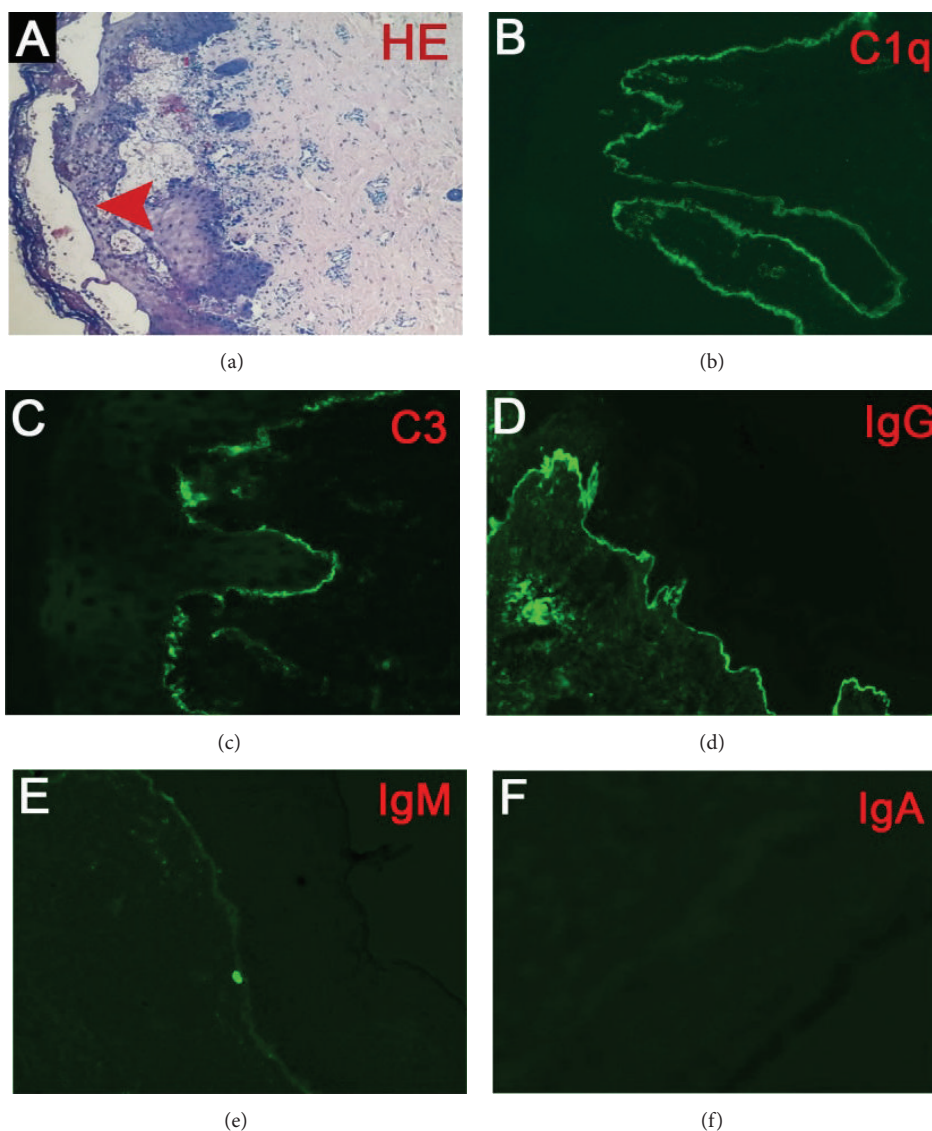


FIGURE 2: Histopathology of the skin lesion. (a) Histopathologic examination of the skin biopsy specimen showed a subepidermal blister (arrow indicated) with abundant neutrophils infiltration and only occasional eosinophils (H&E stain, 100x). (b) Direct immunofluorescence examination showed linear, granular deposition of C1q (b), C3 (c), and IgG (d) at the dermoepidermal junction (400x); less IgM and IgA were detected.

has been assigned to pregnancy category C; BSLE patients with pregnancy might not be fit for administration of this drug [30]. Hemolysis and hepatic and renal toxicity usually accompany administration of the drug in a dose related fashion [31–34]; therefore its clinic use was confined and a careful monitoring of its toxicity is required.

**2.2. Corticosteroids.** Corticosteroids are usually required to improve clinical symptoms and laboratory abnormalities and are still a mainstay for inducing remission in SLE patients [18, 20, 35]. Topical corticosteroids may be helpful in the treatment of cutaneous SLE. Unexpectedly, many bullous SLE patients tend to be unresponsive to systemic corticosteroid therapy that has been described [36]. Furthermore, in some cases of SLE patients, the eruption flared a few

days after systemic corticosteroid administration [11, 12]. Interestingly, some patients responded effectively to corticosteroids, although they required relatively high doses [37]. A patient with SLE who presented with vesiculobullous lesions during the third trimester of pregnancy has been presented. A skin biopsy of this patient was performed, and it showed significant necrosis of keratinocytes in the epidermis and granular, dense, and continuous deposits of moderate IgG positivity in the basement membrane zone. Dapsone has been assigned to pregnancy category C. The pregnant woman treated with high-dose corticosteroids obtained a satisfactory response [30]. As the dapsone administration often causes hepatic and renal toxicity [32, 33, 38–40], prednisone alone or in combination with low doses dapsone might be the treatment of choice for these BSLE patients. These observations

demonstrated that corticosteroids may act as an alternative treatment for BSLE when patients are unresponsive or unfit for other drugs [37].

**2.3. Rituximab.** Biologic agents, such as infliximab, rituximab, and anakinra, have emerged as effective therapies for treating a wide spectrum of diseases which includes various rheumatic, gastrointestinal, and cutaneous diseases [41–44]. The involvement of all of the key components (especially cytokines and immune cells) of the immune system in the pathogenesis of SLE offers many potential targets for therapeutic management of this disease. B cells, a critical immune cell, which can act as antigen-presenting cells, differentiate into plasma cell to produce pathogenic autoantibodies and secrete various cytokines and chemokines in the immune response [45, 46]. These functions of the B cell support the fact that it plays an important role in the development of pathogenesis of SLE. Therefore, use of B cell depletion therapy in SLE has emerged as a novel and promising therapeutic alternative for SLE patients [47–49]. Rituximab which is a chimeric monoclonal antibody that reacts with CD20, an antigen that is present on immature, naive, and memory B cells but not on mature plasma cells, has been approved in the treatment of SLE [50]. Up to now, there is only a case report about rituximab in BSLE. The patient was treated with hydroxychloroquine (HCQ) twice daily, mycophenolate mofetil 1000 mg/d, and varying doses of corticosteroids, while the eruption was not improved. Dapsone and azathioprine were added but had to be stopped because of elevated liver enzymes and leukopenia. Mycophenolate mofetil was increased to 2000 mg/d, but her skin disease remained active. Then the patient was treated with intravenous infusions of rituximab. The skin lesions improved within 10 days after the first dose and cleared by day 15 after the second dose. Furthermore, prednisone was successfully tapered, and the patient has remained free of recurrence of cutaneous and oral blistering lesions [34]. The results of this case suggest a potential role for treatment of refractory BSLE with rituximab.

**2.4. MTX.** Methotrexate (MTX) has been widely proved to be an effective agent in control of the rheumatoid arthritis [51]. It has proved that MTX was beneficial in sporadic cases of SLE refractory to therapy with conventional therapy [52–54], such as antimalarials and corticosteroids. Furthermore, in a randomized and double-blind trial in 41 patients with SLE, MTX reveals a role for controlling the skin lesions in 75% of cases, with a mean reduction of prednisone dose of 44% [55]. These reports demonstrated that MTX could represent a valid therapeutic option in controlling the cutaneous SLE and in sparing the steroid dose. However, BSLE is a subepidermal blistering disease that occurs in a subset of patients with systemic lupus erythematosus (SLE). Cutaneous lesions of BSLE are reported during the course of SLE in less than 1% of patients, while lesions are not in line with the disease activity [9]. Unexpectedly, BSLE is often unresponsive to antimalarials and corticosteroids [56]. In a recent report, a rapid and full resolution of cutaneous lesions was obtained with methotrexate alone. A case of 40-year-old

female with systemic lupus erythematosus (SLE) developed a severe bullous eruption on sun-exposed areas, while the previous manifestations of the disease were quiescent. In consideration of prior intolerance to many drugs, methotrexate was administered. The drug administration was followed by a rapid and full resolution of cutaneous lesions. Therefore, MTX might be an alternative therapeutic choice to dapsone [57].

**2.5. Other Therapies.** HCQ is a commonly used drug for controlling the cutaneous lesions and the disease activity of the SLE [58, 59], while it does not act effectively in the eruption of BSLE [10]. The conventional treatment for SLE only revealed modest improvement in steroids and antimalarials [9]. Although cyclophosphamide has been shown to produce moderate improvement of skin lesions of SLE, the beneficial role in BSLE has not been demonstrated [60]. Mycophenolate mofetil (MMF) has been widely used for suppressing the lupus activity, while it also was not valid for BSLE, even at a high dose [10, 37]. In cases nonresponsive to dapsone, the eruption has been controlled by prednisone or with combination therapy of prednisone and azathioprine [8].

### 3. Conclusions

In the treatment of bullous SLE, dapsone is the effective basic therapy, and it often induces a dramatic response. In some cases, where an adequate response is not achieved with dapsone or the SLE disease activity index is high, other immunosuppressants, such as prednisolone, methotrexate, and azathioprine, can be used for controlling the eruption and suppressing the systemic symptoms. Moreover, in some special case, where dapsone administration or other chemical drugs (MTX, azathioprine, etc.) induce serious side effects, biologic agents might be an alternative choice for BSLE.

### Conflict of Interests

The authors declare that there is no conflict of interests regarding the publication of this paper.

### Authors' Contribution

Lihua Duan and Liying Chen contributed equally to this work.

### Acknowledgments

This work was supported by the National Natural Science Foundation of China 81302564 to L. Duan, 81273285 to G. Shi, and 81301786 to J. Chen and by the National Basic Research Program of China (973 Program) (no. 2014CB541903 to G. Shi).

### References

- [1] A. Yung and A. Oakley, "Bullous systemic lupus erythematosus," *The Australasian Journal of Dermatology*, vol. 41, no. 4, pp. 234–237, 2000.

- [2] N. Rothfield, R. D. Sontheimer, and M. Bernstein, "Lupus erythematosus: systemic and cutaneous manifestations," *Clinics in Dermatology*, vol. 24, no. 5, pp. 348–362, 2006.
- [3] B. Tebbe, "Clinical course and prognosis of cutaneous lupus erythematosus," *Clinics in Dermatology*, vol. 22, no. 2, pp. 121–124, 2004.
- [4] R. P. Hall III, T. J. Lawley, and S. I. Katz, "Bullous eruption of systemic lupus erythematosus," *Journal of the American Academy of Dermatology*, vol. 7, no. 6, pp. 797–799, 1982.
- [5] H. Walling and R. Sontheimer, "Cutaneous lupus erythematosus: issues in diagnosis and treatment," *American Journal of Clinical Dermatology*, vol. 10, no. 6, pp. 365–381, 2009.
- [6] S. Vassileva, "Bullous systemic lupus erythematosus," *Clinics in Dermatology*, vol. 22, no. 2, pp. 129–138, 2004.
- [7] C. Camisa and H. M. Sharma, "Vesiculobullous systemic lupus erythematosus. Report of two cases and a review of the literature," *Journal of the American Academy of Dermatology*, vol. 9, no. 6, pp. 924–933, 1983.
- [8] W. R. Gammon and R. A. Briggaman, "Bullous SLE: A phenotypically distinctive but immunologically heterogeneous bullous disorder," *Journal of Investigative Dermatology*, vol. 100, no. 1, pp. 28S–34S, 1993.
- [9] C. Grover, A. Khurana, S. Sharma, and A. Singal, "Bullous systemic lupus erythematosus," *Indian Journal of Dermatology*, vol. 58, no. 6, p. 492, 2013.
- [10] C. Rassbach, N. Shah, and A. Davis, "A 6-year-old girl with extensive bullous skin lesions," *Pediatric Annals*, vol. 41, no. 6, pp. 229–231, 2012.
- [11] A. Lalova, K. Pramatarov, and S. Vassileva, "Facial bullous systemic lupus erythematosus," *International Journal of Dermatology*, vol. 36, no. 5, pp. 369–371, 1997.
- [12] T. Tsuchida, M. Furue, T. Kashiwado, and Y. Ishibashi, "Bullous systemic lupus erythematosus with cutaneous mucinosis and leukocytoclastic vasculitis," *Journal of the American Academy of Dermatology*, vol. 31, no. 2, part 2, pp. 387–390, 1994.
- [13] R. Neri, M. Mosca, E. Bernacchi, and S. Bombardieri, "A case of SLE with acute, subacute and chronic cutaneous lesions successfully treated with Dapsone," *Lupus*, vol. 8, no. 3, pp. 240–243, 1999.
- [14] K. L. Liu, J. L. Shen, C. S. Yang, and Y. Chen, "Bullous systemic lupus erythematosus in a child responding to dapsone," *Pediatric Dermatology*, vol. 31, no. 4, pp. e104–e106, 2014.
- [15] R. P. Hall, T. J. Lawley, H. R. Smith, and S. I. Katz, "Bullous eruption of systemic lupus erythematosus. Dramatic response to dapsone therapy," *Annals of Internal Medicine*, vol. 97, no. 2, pp. 165–170, 1982.
- [16] M. W. Ludgate and D. E. Greig, "Bullous systemic lupus erythematosus responding to dapsone," *The Australasian Journal of Dermatology*, vol. 49, no. 2, pp. 91–93, 2008.
- [17] P. Patrício, C. Ferreira, M. M. Gomes, and P. Filipe, "Autoimmune bullous dermatoses: a review," *Annals of the New York Academy of Sciences*, vol. 1173, pp. 203–210, 2009.
- [18] "Guidelines for referral and management of systemic lupus erythematosus in adults. American College of Rheumatology Ad Hoc Committee on Systemic Lupus Erythematosus Guidelines," *Arthritis & Rheumatism*, vol. 42, no. 9, pp. 1785–1796, 1999.
- [19] M. A. Dooley, C. Aranow, and E. M. Ginzler, "Review of ACR renal criteria in systemic lupus erythematosus," *Lupus*, vol. 13, no. 11, pp. 857–860, 2004.
- [20] B. H. Hahn, M. A. McMahon, A. Wilkinson et al., "American College of Rheumatology guidelines for screening, treatment, and management of lupus nephritis," *Arthritis Care & Research*, vol. 64, no. 6, pp. 797–808, 2012.
- [21] P. G. Lang Jr., "Sulfones and sulfonamides in dermatology today," *Journal of the American Academy of Dermatology*, vol. 1, no. 6, pp. 479–492, 1979.
- [22] P. Fabbri, C. Cardinali, B. Giomi, and M. Caproni, "Cutaneous lupus erythematosus: diagnosis and management," *The American Journal of Clinical Dermatology*, vol. 4, no. 7, pp. 449–465, 2003.
- [23] J. H. Holtman, D. H. Neustadt, J. Klein, and J. P. Callen, "Dapsone is an effective therapy for the skin lesions of subacute cutaneous lupus erythematosus and urticarial vasculitis in a patient with C2 deficiency," *Journal of Rheumatology*, vol. 17, no. 9, pp. 1222–1225, 1990.
- [24] N. P. Burrows, B. S. Bhogal, M. M. Black et al., "Bullous eruption of systemic lupus erythematosus: a clinicopathological study of four cases," *British Journal of Dermatology*, vol. 128, no. 3, pp. 332–338, 1993.
- [25] R. Harris-Stith, Q. L. Erickson, D. M. Elston, and K. David-Bajar, "Bullous eruption: a manifestation of lupus erythematosus," *Cutis*, vol. 72, no. 1, pp. 31–37, 2003.
- [26] C. S. Sirka, T. Padhi, P. Mohanty, D. K. Patel, P. R. Parida, and C. R. Kar, "Bullous systemic lupus erythematosus: response to dapsone in two patients," *Indian Journal of Dermatology, Venereology and Leprology*, vol. 71, no. 1, pp. 54–56, 2005.
- [27] D. D. Barton, J.-D. Fine, W. R. Gammon, and W. M. Sams Jr., "Bullous systemic lupus erythematosus: an unusual clinical course and detectable circulating autoantibodies to the epidermolysis bullosa acquisita antigen," *Journal of the American Academy of Dermatology*, vol. 15, no. 2, part 2, pp. 369–373, 1986.
- [28] G. S. Alarcón, W. M. Sams Jr., D. D. Barton, and J. Reveille, "Bullous lupus erythematosus rash worsened by Dapsone," *Arthritis & Rheumatism*, vol. 27, no. 9, pp. 1071–1072, 1984.
- [29] A. Kraus, J. Jakez, and A. Palacios, "Dapsone induced sulfone syndrome and systemic lupus exacerbation," *The Journal of Rheumatology*, vol. 19, no. 1, pp. 178–180, 1992.
- [30] C. E. dos Santos, P. H. I. Velho, F. M. Marques, B. Werner, S. C. Aragão, and A. R. Filho, "Bullous systemic lupus erythematosus in a pregnant woman: a case report," *Revista Brasileira de Reumatologia*, vol. 53, no. 5, pp. 438–440, 2013.
- [31] M. Nishina, E. Saito, and M. Kinoshita, "Correction of severe leukocytopenia and thrombocytopenia in systemic lupus erythematosus by treatment with dapsone," *The Journal of Rheumatology*, vol. 24, no. 4, pp. 811–812, 1997.
- [32] M. A. Meyerson and P. R. Cohen, "Dapsone-induced aplastic anemia in a woman with bullous systemic lupus erythematosus," *Mayo Clinic Proceedings*, vol. 69, no. 12, pp. 1159–1162, 1994.
- [33] C. Moss and P. J. Hamilton, "Thrombocytopenia in systemic lupus erythematosus responsive to dapsone," *British Medical Journal*, vol. 297, no. 6643, p. 266, 1988.
- [34] S. Alsanafi, C. Kovarik, A. L. Mermelstein, and V. P. Werth, "Rituximab in the treatment of bullous systemic lupus erythematosus," *Journal of Clinical Rheumatology*, vol. 17, no. 3, pp. 142–144, 2011.
- [35] W. W. Chatham and R. P. Kimberly, "Treatment of lupus with corticosteroids," *Lupus*, vol. 10, no. 3, pp. 140–147, 2001.
- [36] Y. N. Singh, C. M. Adya, K. K. Verma, A. Kumar, and A. N. Malaviya, "Dapsone in cutaneous lesions of SLE: an open study," *The Journal of the Association of Physicians of India*, vol. 40, no. 11, pp. 735–736, 1992.

- [37] M. Tincopa, K. B. Puttgen, S. Sule, B. A. Cohen, and M. R. Gerstenblith, "Bullous lupus: an unusual initial presentation of systemic lupus erythematosus in an adolescent girl," *Pediatric Dermatology*, vol. 27, no. 4, pp. 373–376, 2010.
- [38] C.-C. Mok and C.-S. Lau, "Dapsone syndrome in cutaneous lupus erythematosus," *The Journal of Rheumatology*, vol. 23, no. 4, pp. 766–768, 1996.
- [39] K. Tsutsui, T. Imai, N. Hatta, H. Sakai, M. Takata, and K. Takehara, "Widespread pruritic plaques in a patient with subacute cutaneous lupus erythematosus and hypocomplementemia: response to dapsone therapy," *Journal of the American Academy of Dermatology*, vol. 35, no. 2, pp. 313–315, 1996.
- [40] N. I. Stahl, "Progressive multifocal leukoencephalopathy in a minimally immunosuppressed patient with systemic lupus erythematosus treated with dapsone," *The Journal of Rheumatology*, vol. 35, no. 4, pp. 725–727, 2008.
- [41] S. Ramiro, C. Gaujoux-Viala, J. L. Nam et al., "Safety of synthetic and biological DMARDs: a systematic literature review informing the 2013 update of the EULAR recommendations for management of rheumatoid arthritis," *Annals of the Rheumatic Diseases*, vol. 73, no. 3, pp. 529–535, 2014.
- [42] M.-E. Ariza, M. V. Williams, and H. K. Wong, "Targeting IL-17 in psoriasis: from cutaneous immunobiology to clinical application," *Clinical Immunology*, vol. 146, no. 2, pp. 131–139, 2013.
- [43] A. S. Raut, R. H. Prabhu, and V. B. Patravale, "Psoriasis clinical implications and treatment: a review," *Critical Reviews in Therapeutic Drug Carrier Systems*, vol. 30, no. 3, pp. 183–216, 2013.
- [44] J. P. Terdiman, C. B. Gruss, J. J. Heidelbaugh, S. Sultan, and Y. T. Falck-Ytter, "American gastroenterological association institute guideline on the use of thiopurines, methotrexate, and anti-TNF-alpha biologic drugs for the induction and maintenance of remission in inflammatory Crohn's disease," *Gastroenterology*, vol. 145, no. 6, pp. 1459–1463, 2013.
- [45] Y. He, H. Qian, Y. Liu, L. Duan, Y. Li, and G. Shi, "The roles of regulatory B cells in cancer," *Journal of Immunology Research*, vol. 2014, Article ID 215471, 7 pages, 2014.
- [46] Y. Bao and X. Cao, "The immune potential and immunopathology of cytokine-producing B cell subsets: a comprehensive review," *Journal of Autoimmunity*, vol. 56, pp. 10–23, 2014.
- [47] F. B. Vincent, D. Saulep-Easton, W. A. Figgett, K. A. Fairfax, and F. Mackay, "The BAFF/APRIL system: emerging functions beyond B cell biology and autoimmunity," *Cytokine & Growth Factor Reviews*, vol. 24, no. 3, pp. 203–215, 2013.
- [48] F. B. Vincent, E. F. Morand, P. Schneider, and F. Mackay, "The BAFF/APRIL system in SLE pathogenesis," *Nature Reviews: Rheumatology*, vol. 10, no. 6, pp. 365–373, 2014.
- [49] J. H. Anolik, "B cell biology: implications for treatment of systemic lupus erythematosus," *Lupus*, vol. 22, no. 4, pp. 342–349, 2013.
- [50] T. Cobo-Ibáñez, E. Loza-Santamaría, J. M. Pego-Reigosa et al., "Efficacy and safety of rituximab in the treatment of non-renal systemic lupus erythematosus: a systematic review," *Seminars in Arthritis and Rheumatism*, vol. 44, no. 2, pp. 175–185, 2014.
- [51] P. Emery, A. Sebba, and T. W. J. Huizinga, "Biologic and oral disease-modifying antirheumatic drug monotherapy in rheumatoid arthritis," *Annals of the Rheumatic Diseases*, vol. 72, no. 12, pp. 1897–1904, 2013.
- [52] A. Kuhn, C. Specker, T. Ruzicka, and P. Lehmann, "Methotrexate treatment for refractory subacute cutaneous lupus erythematosus," *Journal of the American Academy of Dermatology*, vol. 46, no. 4, pp. 600–603, 2002.
- [53] I. Bohm, M. Uerlich, and R. Bauer, "Rapid improvement of subacute cutaneous lupus erythematosus with low-dose methotrexate," *Dermatology*, vol. 194, no. 3, pp. 307–308, 1997.
- [54] I. B. Boehm, G. A. Boehm, and R. Bauer, "Management of cutaneous lupus erythematosus with low dose methotrexate: indication for modulation of inflammatory mechanisms," *Rheumatology International*, vol. 18, no. 2, pp. 59–62, 1998.
- [55] E. Sato, "Methotrexate therapy in systemic lupus erythematosus," *Lupus*, vol. 10, no. 3, pp. 162–164, 2001.
- [56] D. F. Sebaratnam and D. F. Murrell, "Bullous systemic lupus erythematosus," *Dermatologic Clinics*, vol. 29, no. 4, pp. 649–653, 2011.
- [57] G. Malcangi, G. Brandozzi, M. Giangiacomini, M. Zampetti, and M. G. Danieli, "Bullous SLE: response to methotrexate and relationship with disease activity," *Lupus*, vol. 12, no. 1, pp. 63–66, 2003.
- [58] V. Bykerk, J. Sampalis, J. M. Esdaile et al., "A randomized study of the effect of withdrawing hydroxychloroquine sulfate in systemic lupus erythematosus," *The New England Journal of Medicine*, vol. 324, no. 3, pp. 150–154, 1991.
- [59] G. J. Pons-Estel, G. S. Alarcón, G. McGwin Jr. et al., "Protective effect of hydroxychloroquine on renal damage in patients with lupus nephritis: LXV, data from a multiethnic US cohort," *Arthritis Care and Research*, vol. 61, no. 6, pp. 830–839, 2009.
- [60] J. P. Callen and J. Klein, "Subacute cutaneous lupus erythematosus. Clinical, serologic, immunogenetic, and therapeutic considerations in seventy-two patients," *Arthritis and Rheumatism*, vol. 31, no. 8, pp. 1007–1013, 1988.