

## CASE REPORT

# Quadri-lineage disease involving nodal B-cell marginal zone lymphoma, high-grade B-cell lymphoma, Kaposi's syndrome, and acute myeloid leukemia

Kamel Laribi<sup>1</sup>, Habib Ghnaya<sup>1</sup>, Pierre-Jean Mention<sup>1</sup>, Hoel Rousset<sup>1</sup>, Alix Baugier de Materre<sup>2</sup>, Fabienne Pineau-Vincent<sup>3</sup>, Catherine Truong<sup>4</sup> & Delphine Bolle<sup>5</sup>

<sup>1</sup>Department of Hematology, Centre Hospitalier, Le Mans, France

<sup>2</sup>Department of Medicine, Pôle Sante Sud, Le Mans, France

<sup>3</sup>Laboratory of Haematology, Centre Hospitalier, Le Mans, France

<sup>4</sup>Clinical Research Center, Centre Hospitalier, Le Mans, France

<sup>5</sup>Department of pharmacy, Centre Hospitalier, Le Mans, France

### Correspondence

Kamel Laribi, Centre Hospitalier, 194 Avenue Rubillard, 72000 Le Mans, France.  
Tel: 33 (0)2 43 43 43 61;  
Fax: 33 (0)2 43 43 25 18;  
E-mail: klaribi@ch-lemans.fr

### Funding Information

No sources of funding were declared for this study.

Received: 20 March 2015; Revised: 30 June 2015; Accepted: 11 August 2015

*Clinical Case Reports* 2016; 4(1): 39–42

doi: 10.1002/ccr3.393

## Introduction

Marginal zone lymphomas are usually indolent and respond well to treatment [1, 2], but the nodal form is often more severe and is associated with poor response rates and shorter survival times [3–5]. Progression to high-grade B-cell lymphoma may occur, and has long been known [1, 6, 7].

The occurrence of acute leukemia after a high-grade B-cell lymphoma has also been described in various studies [8–10]. The use of alkylating agents based chemotherapy and the intensification of therapy with autologous stem cell transplantation are risk factors for leukemia or myelodysplasia [11–13].

Kaposi's sarcoma after autologous bone marrow transplantation for non-Hodgkin's lymphoma is rare, but cases have been published [14].

The occurrence in the same patient of nodal B-cell marginal zone lymphoma, high-grade B-cell lymphoma, Kaposi's syndrome, and acute myeloid leukemia in quick succession has never been described.

### Key Clinical Message

A patient with a marginal zone lymphoma received RCHOP and obtained PR. He received RDHAP, autograft, and obtained CR. Three months later, he developed Kaposi's sarcoma with spontaneous regression. Two months later, he developed DLBCL treated with R-MIV with CR. Thereafter, he developed AML and died a few days later.

### Keywords

Acute myeloid leukemia, diffuse large B-cell lymphoma, Kaposi's syndrome, marginal zone lymphoma.

## Case Report

We report an exceptional case of diseases of four lineages in a 61-year-old man with a history of type 2 diabetes, deep vein thrombosis of the lower limbs, syphilis, hypertension, and glaucoma. He developed a marginal zone lymphoma, revealed by alteration of his general condition, weight loss of 8 kg over the previous 3 months, and detected as a left pelvic nodal mass with a diameter of 8.5 cm. A chest and abdominal CT revealed left axillary, mediastinal, retroperitoneal, and pelvic involvement. A pelvic lymph node biopsy showed proliferation in the marginal zone with a moderate contingent of large cells and a mitotic index (Ki 67) of 40%. Blood tests showed anemia with low hemoglobin levels (9 g/dL). Lactate dehydrogenase levels were high (2 N) and the ECOG PS was 2. Up to 30% of the bone marrow was infiltrated by lymphoma cells. A PET scan was not performed. The patient was diagnosed with a high tumor burden lymphoma (FLIPI = 4, IPI adjusted to age 3).

The nodal and medullary karyotypes were normal. Bone marrow and blood cells tested positive for BCL2 by PCR.

Pretreatment assessment identified a syphilis infection, which was cured with penicillin. Hypogammaglobulinemia or lymphopenia were not detected during the assessment. Serological tests for hepatitis B, hepatitis C, HIV, CMV, and HTLV were negative.

The patient was treated with the standard protocol for the RCHOP regimen (rituximab–cyclophosphamide–doxorubicin–vincristin). After three courses of chemotherapy, the response was evaluated to be 50% by physical examination and tomography scans of the chest and abdomen. Bone marrow was not analyzed. The patient then received three courses of RDHAP (rituximab–cisplatin–cytosine arabinoside–dexamethasone) and obtained a complete response (chest and abdominal CT, and bone marrow biopsies were negative), and an autologous stem cell transplant conditioned by the BEAM regimen (carmustine–cytosine arabinoside–etoposid–melphalan). This treatment was followed by complete remission.

Three months after the autograft, the patient developed multiple nodular lesions of the legs and the right and left forearms, the largest of which was 2-cm long and on the left forearm. Skin biopsy revealed a typical Kaposi's sarcoma, and HHV8 serological tests were positive (Figs. 1 and 2).

Concomitantly, the patient became severely immunosuppressed; the absolute CD4+ cell count was  $220 \times 10^6/L$ ,

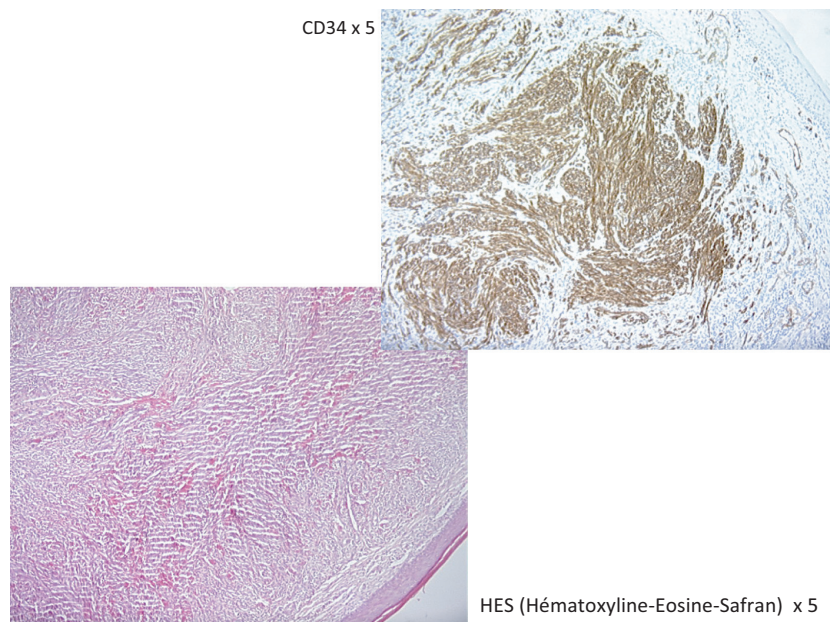
with  $1048 \times 10^6/L$  CD8+ cells, and thus a CD4/CD8 ratio of 0.2.

It was decided not to treat. The lesions spontaneously regressed 3 months after their appearance, and had completely disappeared 6 months later; the CD4/CD8 ratio rose to 0.8, and immunity returned to normal.

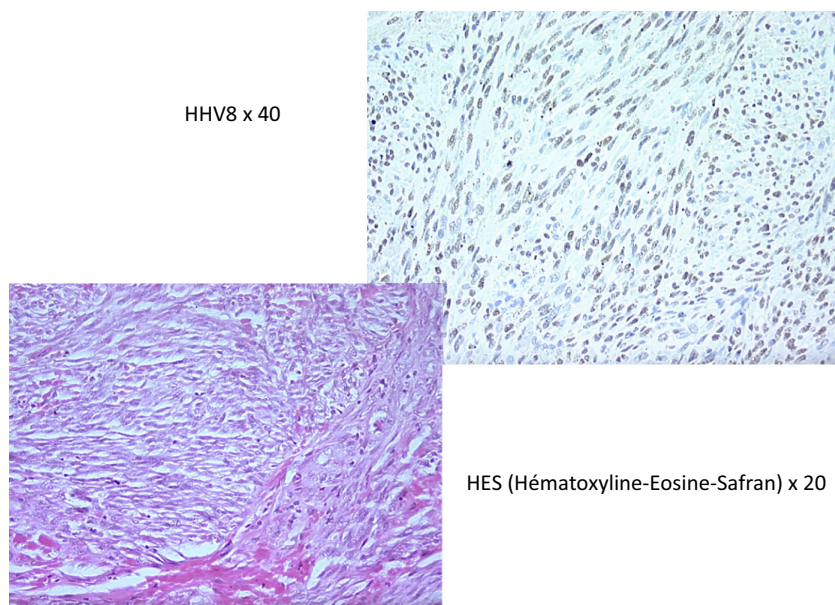
Two months later, the patient developed a bilateral cervical lymphadenopathy 3 cm in diameter. Nodal biopsy showed a typical diffuse large B-cell lymphoma. Extended assessment found Ann Arbor stage III, IPI adjusted to age 3. Bone marrow biopsy, medullary karyotype, and FISH were normal.

No sibling donor was available; given the age of the patient, the nature of the lymphoma, and the severity of the comorbidity no volunteer donor was sought. The patient was administered six sequences of the R-MIV regimen (rituximab–ifosfamide–mitoxantone–etoposide). Physical examination, tomography scan of the chest and the abdomen, and PET scan indicated that complete remission was obtained.

Six months later, the patient developed pancytopenia (PN  $0.3 \times 10^6/L$ , platelets  $26 \times 10^6/L$ , hemoglobin 83 g/L). The myelogram showed bone marrow infiltration, 90% AML type 1. Karyotyping by FISH revealed a translocation  $t(9, 11)$  with an MLL rearrangement. It was decided not to treat because of mounting concerns about the poor general condition of the patient, who had developed cellulitis of the right arm. The patient died from multiple sepsis a few days later.



**Figure 1.** Vascular-type CD34+ spindle cell tumor within the dermis.



**Figure 2.** Vascular tumor with atypical cytonuclear HHV8+ staining indicating Kaposi's sarcoma.

## Discussion

Several studies have analyzed the prognostic factors affecting the survival of patients with marginal zone lymphoma. Some identified no prognostic factors [5] and others found that age (>60 years) [15] or a high follicular lymphoma international prognostic index [16] score were associated with shorter survival [17]. In another study, patients expressing Ki 67 in less than 5% of tumor cells had a better prognosis [18]. Recently, in a large retrospective series of 197 patients with marginal zone lymphoma, Meyer *et al.* [19] found that age (>60 years), elevated serum LDH, lower than normal hemoglobin, high IPI [20], high FLIPI, and a lack of PR or CR after initial therapy were independent risk factors for shorter survival.

In addition, nodal marginal zone lymphomas (NMZL) are more aggressive than extranodal marginal zone lymphomas, with lower PFS and overall survival [3–5, 21].

Furthermore, several groups have reported that the risk of developing a second cancer is high in patients with marginal zone lymphoma [19, 22, 23], resulting in shorter survival rates among such patients [19].

These findings are consistent with the clinical presentation of our patient: he was older than 60, had high LDH levels, a high FLIPI score, a high IPI score, did not respond to initial treatment with RCHOP, and relapsed with an aggressive cancer within 5 months of the autograft.

Kaposi's sarcoma after autologous bone marrow transplantation for non-Hodgkin's lymphoma is rare, but cases have been reported in relation to immunosuppression induced by chemotherapy [14].

Although the use of alkylating and autologous stem cells may have influenced the onset of acute leukemia, it is surprising that the nodal karyotype appeared normal at diagnosis. No cytogenetic abnormalities were detected by *in situ* hybridization at the time of the occurrence of acute leukemia besides the MLL rearrangement [9, 11], which is usually associated with alkylating agents (full or partial deletions of chromosomes 5 and 7, trisomy 8). These observations, and the succession of four diseases in a short time (21 months after the diagnosis of nodal marginal zone lymphoma and 15 months after autograft), makes this a rather unusual case.

Although standard cytogenetic analyses were normal at diagnosis, FISH provided a more detailed information and genomic DNA copy number analysis may have been informative [3, 22, 23].

Although the findings of this particularly severe case cannot be generalized to other patients, it may not be an isolated case. Prospective studies are required to validate the different prognostic factors found in retrospective studies.

## Conflict of Interest

None declared.

## References

- Berger, F., P. Felman, C. Thieblemont, T. Pradier, L. Baseggio, P. A. Bryon, *et al.* 2000. Non-MALT marginal zone B-cell lymphomas: a description of clinical presentation and outcome in 124 patients. *Blood* 95:1950–1956.

2. Thieblemont, C., and B. Coiffier. 2006. Management of marginal zone lymphomas. *Curr. Treat. Options Oncol.* 7:213–222. Review.
3. Traverse-Glehen, A., F. Bertoni, C. Thieblemont, E. Zucca, B. Coiffier, F. Berger, et al. 2012. Nodal marginal zone B-cell lymphoma: a diagnostic and therapeutic dilemma. *Oncology* 26:92–99, 103–104.
4. Armitage, J. O., and D. D. Weisenburger. 1998. New approach to classifying non-Hodgkin's lymphomas: clinical features of the major histologic subtypes. Non-Hodgkin's Lymphoma Classification Project. *J. Clin. Oncol.* 16:2780–2795.
5. Traverse-Glehen, A., P. Felman, E. Callet-Bauchu, S. Gazzo, L. Baseggio, P. A. Bryon, et al. 2006. A clinicopathological study of nodal marginal zone B-cell lymphoma. A report on 21 cases. *Histopathology* 48:162–173.
6. Oh, S. Y., B. Y. Ryoo, W. S. Kim, K. Kim, J. Lee, H. J. Kim, et al. 2006. Nodal marginal zone B-cell lymphoma: analysis of 36 cases. Clinical presentation and treatment outcomes of nodal marginal zone B-cell lymphoma. *Ann. Hematol.* 85:781–786.
7. Coiffier, B., C. Thieblemont, P. Felman, G. Salles, and F. Berger. 1999. Indolent non follicular lymphomas: characteristics, treatment, and outcome. *Semin. Hematol.* 36:198–200.
8. Pirani, M., R. Marcheselli, L. Marcheselli, A. Bari, M. Federico, and S. Sacchi. 2011. Risk for second malignancies in non-Hodgkin's lymphoma survivors: a meta-analysis. *Ann. Oncol.* 22:1845–1858.
9. Mudie, N. Y., A. J. Swerdlow, C. D. Higgins, P. Smith, Z. Qiao, B. W. Hancock, et al. 2006. Risk of second malignancy after non-Hodgkin's lymphoma: a British Cohort Study. *J. Clin. Oncol.* 24:1568–1574.
10. Pedersen-Bjergaard, J., J. Ersbøll, H. M. Sørensen, N. Keiding, S. O. Larsen, P. Philip, et al. 1985. Risk of acute nonlymphocytic leukemia and preleukemia in patients treated with cyclophosphamide for non-Hodgkin's lymphomas. Comparison with results obtained in patients treated for Hodgkin's disease and ovarian carcinoma with other alkylating agents. *Ann. Intern. Med.* 103:195–200.
11. Travis, L. B., R. E. Curtis, J. D. Boice Jr, B. F. Hankey, and J. F. Fraumeni Jr. 1991. A Second cancers following non-Hodgkin's lymphoma. *Cancer* 67:2002–2009.
12. André, M., N. Mounier, X. Leleu, A. Sonet, P. Brice, M. Henry-Amar, et al. 2004. Groupe D'Etude Des Lymphomes De L'Adulte. Second cancers and late toxicities after treatment of aggressive non-Hodgkin lymphoma with the ACVBP regimen: a GELA cohort study on 2837 patients. *Blood* 103:1222–1228.
13. Sacchi, S., L. Marcheselli, A. Bari, R. Marcheselli, S. Pozzi, P. G. Gobbi, et al. 2008. Second malignancies after treatment of diffuse large B cell non-Hodgkin's lymphoma: a GISL cohort study. *Haematologica* 93:1335–1342.
14. Porta, F., M. Bongiorno, F. Locatelli, A. Gibardi, A. Lanfranchi, R. Rosso, et al. 1991. Kaposi's sarcoma in child after autologous bone marrow transplantation for non-Hodgkin's lymphoma. *Cancer* 68:1361–1364.
15. Camacho, F. I., P. Algara, M. Mollejo, J. F. García, C. Montalbán, N. Martínez, et al. 2003. Nodal marginal zone lymphoma: a heterogeneous tumor: a comprehensive analysis of a series of 27 cases. *Am. J. Surg. Pathol.* 27:762–771.
16. Solal-Céligny, P., P. Roy, P. Colombat, J. White, J. O. Armitage, R. Arranz-Saez, et al. 2004. Follicular lymphoma international prognostic index. *Blood* 104:1258–1265.
17. Arcaini, L., M. Paulli, S. Burcheri, A. Rossi, M. Spina, F. Passamonti, et al. 2007. Intergruppo Italiano Linfomi. Primary nodal marginal zone B-cell lymphoma: clinical features and prognostic assessment of a rare disease. *Br. J. Haematol.* 136:301–304.
18. Petit, B., M. P. Chaury, C. Le Clorennec, A. Jaccard, N. Gachard, S. Moalic-Judge, et al. 2005. Indolent lymphoplasmacytic and marginal zone B-cell lymphomas: absence of both IRF4 and Ki67 expression identifies a better prognosis subgroup. *Haematologica* 90:200–206.
19. Meyer, A. H., A. Stroux, K. Lerch, J. Eucker, J. Eitle, K. Hohloch, et al. 2014. Transformation and additional malignancies are leading risk factors for an adverse course of disease in marginal zone lymphoma. *Ann. Oncol.* 25:210–215.
20. Shipp, M. A., and P. D. Harrington. 1993. A predictive model for aggressive non-Hodgkin's lymphoma. The International Non-Hodgkin's Lymphoma Prognostic Factors Project. *N. Engl. J. Med.* 329:987–994.
21. Angelopoulou, M. K., C. Kalpadakis, G. A. Pangalis, M. C. Kyrtonis, and T. P. Vassilakopoulos. 2014. Nodal marginal zone lymphoma. *Leuk. Lymphoma* 55:1240–1250.
22. Rinaldi, A., M. Mian, E. Chigrinova, L. Arcaini, G. Bhagat, U. Novak, et al. 2011. Genome-wide DNA profiling of marginal zone lymphomas identifies subtype-specific lesions with an impact on the clinical outcome. *Blood* 117:1595–1604.
23. Novak, U., A. Rinaldi, I. Kwee, S. V. Nandula, P. M. Rancoita, M. Compagno, et al. 2009. The NF- $\kappa$  B negative regulator TNFAIP3 (A20) is inactivated by somatic mutations and genomic deletions in marginal zone lymphomas. *Blood* 113:4918–4921.