

Contents lists available at [ScienceDirect](https://www.sciencedirect.com)

Gynecologic Oncology Reports

journal homepage: www.elsevier.com/locate/gynor

Case report

Acute extraperitoneal spontaneous bladder rupture in cervical cancer patient undergoing chemoradiation: A case report and review of the literature

Annalyn Welp^{a,*}, Emma C. Fields^b, Leslie Randall^c, Florence K. Brown^c, Stephanie A. Sullivan^c^a Virginia Commonwealth University School of Medicine, Richmond, VA 23219, United States^b Department of Radiation Oncology, Virginia Commonwealth University Health System, Richmond, VA 23219, United States^c Division of Gynecologic Oncology, Department of Obstetrics and Gynecology, Virginia Commonwealth University Health System, Richmond, VA 23219, United States

ARTICLE INFO

Keywords:

Cervix
Chemoradiation
Complications
Bladder

ABSTRACT

The standard of care for locally advanced cervical cancer is pelvic radiotherapy with sensitizing cisplatin, and intracavitary brachytherapy. This standard of care treatment paradigm has best survival outcomes, however is associated with genitourinary toxicities. Spontaneous bladder rupture (SBR) is a rare complication of chemoradiation that has only been reported in literature as an intraperitoneal rupture occurring years after the cessation of treatment. We herein present a novel case of extraperitoneal SBR in a 27-year-old female with FIGO Stage IIIC cervical cancer and no prior surgical history who was undergoing chemoradiation with sensitizing cisplatin. During her final planned brachytherapy treatment upon instilling the bladder under ultrasound guidance, an anterior midline extraperitoneal rupture was noted. She was managed conservatively for several weeks and during this time was ultimately able to complete her external beam therapy and last cycle of cisplatin. After approximately ten weeks of conservative management, imaging demonstrated complete resolution of the rupture. A review of the literature suggests this complication tends to occur as an intraperitoneal rupture years after the cessation of therapy. Late genitourinary complications and types of complications are rarely reported in clinical trials, so it is difficult to determine the true incidence of rare complications and identify patients that may be at risk.

1. Background

Cervical cancer remains a relatively rare diagnosis in the United States. However, it is a preventable cancer which accounts for 4,000 deaths a year (Tewari and Monk, 2019). Locally advanced cervical cancer, which includes FIGO Stage IB3 through IVA, is primarily treated with pelvic radiotherapy, sensitizing cisplatin and intracavitary brachytherapy (Rose et al., 1999; Morris et al., 1999). The addition of cisplatin to radiation as well as the advent of modern radiation techniques have shown incremental benefits in survival and pelvic control (Tewari and Monk, 2019; Rose et al., 1999). However, this treatment paradigm is associated with urologic complications due to the anatomic proximity of these organs to the cervix. Typically, urologic toxicities are low-grade, with the majority of patients experiencing minimal or no adverse effects (Tewari and Monk, 2019; Rose et al., 1999). High-grade

toxicities increase over time after completion of treatment, most commonly involving ureteric stricture formation, vesicovaginal fistulas, or hemorrhagic cystitis at rates ranging from 1.8 to 14.5% at 3 years post therapy (Lobo et al., 2018).

Spontaneous bladder rupture (SBR), however, is a rare complication of radiation therapy and has been reported in the literature as an intraperitoneal rupture and late complication (Lobo et al., 2018). Here, we present a unique case of spontaneous extraperitoneal rupture occurring during upfront chemoradiation for stage IIIC1 (previously FIGO 2014 IIB) cervical cancer.

2. Case

We present the case of a 27-year-old G3P3 female with FIGO stage IIIC1 squamous cell carcinoma of the cervix. She was diagnosed in

* Corresponding author at: Division of Gynecologic Oncology, Department of Obstetrics and Gynecology, Virginia Commonwealth University Medical Center, 1250 E. Marshall Street, Richmond, VA 23219, United States.

E-mail address: welpam@mymail.vcu.edu (A. Welp).

<https://doi.org/10.1016/j.gore.2020.100656>

Received 7 August 2020; Received in revised form 22 September 2020; Accepted 30 September 2020

Available online 3 October 2020

2352-5789/© 2020 The Authors.

Published by Elsevier Inc.

This is an open access article under the CC BY-NC-ND license

(<http://creativecommons.org/licenses/by-nc-nd/4.0/>).

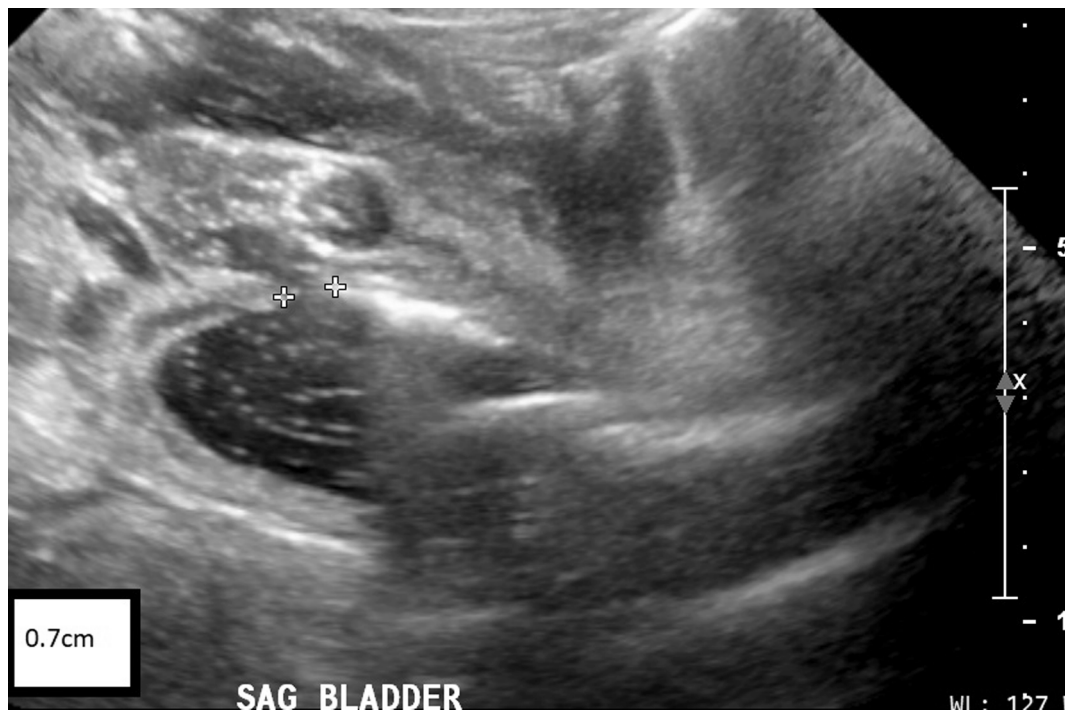


Fig. 1. Ultrasound with bladder rupture. Ultrasound with anterior initial extraperitoneal leak. Diameter of rupture marked with calipers, 0.7 cm.

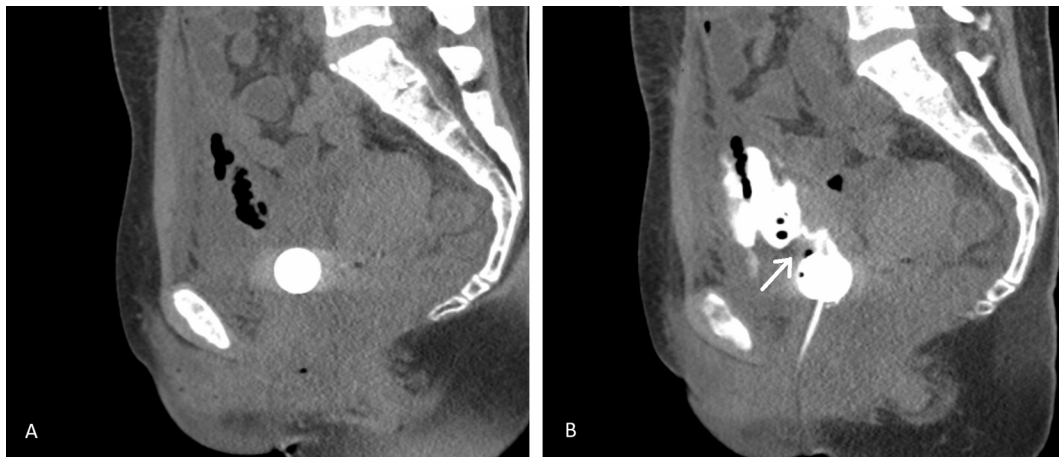


Fig. 2. CT urogram with contrast demonstrating extraperitoneal leak. Anterior extraperitoneal leak demonstrated. Image A taken prior to instillation of contrast with air and fluid appreciated between the anterior peritoneum and fascia. Image B with instillation of contrast demonstrating 0.7 cm anterior, extraperitoneal rupture with contrast extravasation into the extraperitoneal space. Arrow indicating area of rupture from the bladder.

August 2018 after an admission for acute renal injury and a new diagnosis of autoimmune hepatitis. Her medical history included polycystic ovarian syndrome, iron-deficiency anemia, recovered multi-substance abuse, and on-going tobacco use. She had no prior surgical history. Upon diagnosis, she underwent an exam under anesthesia, cystoscopy, and proctoscopy. She was found to have a 4 × 6 cm primary cervical tumor with bilateral parametrial involvement. She had no evidence of vaginal wall, bladder or rectal involvement. Her initial radiation plan included whole pelvic intensity-modulated external beam radiation therapy to 45 Gy over 25 fractions with a left internal iliac boost of 14 Gy over 7 fractions. High-dose brachytherapy with interdigitated tandem and ovoid placement was planned for 30 Gy over 5 fractions; ultimately, she received 24 Gy over 4 fractions after declining the last session. She received 5 cycles of weekly cisplatin complicated by grade 3 thrombocytopenia, completed in October of 2018.

At presentation for her final planned brachytherapy treatment, she

noted abdominal pain, nausea and vomiting since her last treatment. She had no urologic complaints. She was tachycardic but otherwise hemodynamically stable, with diffuse abdominal tenderness. Labs were notable for hyperkalemia to 6.2 mmol/L and stage III acute kidney injury with a creatinine of 2.88 mg/dL. Brachytherapy was suspended, and she was admitted. She resumed her brachytherapy the following day after clinical improvement. After filling the bladder with saline prior to the ultrasound guided placement of the tandem and ovoids by the radiation oncologist, an anterior bladder rupture was noted, measured to be 0.7 cm (Fig. 1). Treatment was aborted, and a foley catheter was placed with subsequent normalization of her labs. A CT cystogram obtained urgently confirmed a midline anterior extraperitoneal bladder leak with no evidence of an intraperitoneal leak (Fig. 2). She was managed conservatively with an indwelling foley. At this time, she declined the last fraction of brachytherapy, however did complete her external beam therapy and cisplatin once renal function improved. A CT

Table 1
Summary of cervical cancer stage, management, and spontaneous bladder rupture (SBR) in reported literature.

Author (Year)	Study	FIGO Stage	Treatment	SBR Location	SBR Interval
Nishimura et al. (2000) ^a	Case Report	IIA	Rad Hyst Radiation therapy	intraperitoneal	3 years
Shin et al. (2014)	Case Report	IIIB ^b	Rad hyst Concurrent CRT	intraperitoneal	13 years

Abbreviations: CRT, chemoradiation; FIGO, International Federation of Gynecology and Obstetrics; Rad hyst, radical hysterectomy; SBR, spontaneous bladder rupture

^a This case report did not disclose whether or not the patient in question underwent chemotherapy at any point during their management.

^b This case report did not document the patient's stage; reporting of this based on personal correspondence with the author.

cytogram 4 weeks later demonstrated an improved but persistent leak. The patient continued with conservative management for 6 additional weeks, at which point imaging demonstrated complete resolution of the rupture.

The patient developed recurrent disease and underwent additional chemotherapy, however she died from her disease in December 2019.

3. Discussion

This is the first case to our knowledge describing an extraperitoneal SBR occurring during upfront chemoradiation treatment for cervical cancer.

Two physiological explanations for SBR have been proposed: an increase in intravesical pressure and decreased strength of the bladder wall (Mitchell et al., 2011). Underlying risk factors include metabolic, inflammatory, neurologic, congenital, obstructive, and malignant etiologies that have been identified as potential contributors to SBR (Lobo et al., 2018; Mitchell et al., 2011). SBR after radiation for cervical cancer has been described in reports as a late complication involving the intraperitoneal bladder (Lobo et al., 2018; Nishimura et al., 2000; Shin et al., 2014). Intraperitoneal SBR is a morbid condition that presents as acute abdomen with peritoneal signs, ascites, acute renal failure, or infection that requires urgent intervention (Fujikawa et al., 1999). Extraperitoneal SBR is associated with prior trauma or surgery. Both types require a high degree of clinical suspicion.

Given our unique presentation, a literature review was performed to identify cases similar to what we have described. A search was performed in PubMed with the terms "spontaneous bladder rupture AND cervical cancer" yielding 14 results through April 2020. In February 1999, the National Cancer Institute (NCI) alerted oncologists that concomitant chemotherapy and radiotherapy should be considered for all patients with invasive cervical cancer (Tewari and Monk, 2019). Therefore, studies were included if they detailed clinical information on individual patients with a history and timeline of treatment after 1999 with SBR. Studies were excluded if they were not available in English, or failed to meet the detailed inclusion criteria. Bibliographies of included studies were reviewed for reports that may have been missed in the initial search.

We identified 2 investigations meeting our criteria (Table 1). Treatment for each patient's cancer was described to the extent of the detail provided in the original source. Both cases involved *intraperitoneal* SBR after radical hysterectomy and pelvic radiation. Neither case described SBR in the setting of definitive or adjuvant treatment, with both instances occurring as a long-term adverse event ranging 3–13 years after completion of radiation. It is worth noting that SBRs after pelvic radiation therapy alone in cervical cancer have been documented in literature published prior to 1999 with a latency period commonly

greater than 10 years (Nishimura et al., 2000).

Graded toxicities are defined by the NCI's Common Terminology Criteria for Adverse Events (CTCAE),¹ the standard classification schema for reporting toxicity in oncologic clinical trials. Extraperitoneal bladder rupture requiring indwelling catheterization is a grade 2 genitourinary toxicity by this classification, while intraperitoneal rupture are grade 3 (NCI, 2020). The granular details are often not specified in large clinical trials or supplementary data beyond generally detailing "genitourinary effects" (Rose et al., 1999). One systematic review and meta-analysis of clinical trials involving concomitant chemoradiation in cervical cancer patients found of the 19 articles included, only 8 trials described acute toxicity and 3 studies reported late toxicity (Green et al., 2001). Clinical trial data is regarded as the highest quality source for toxicity information, however the true incidence of rare complications such as SBR may be challenging to ascertain given the long time to occurrence and low frequency with which it occurs (Lobo et al., 2018; Nishimura et al., 2000). There are no reported extraperitoneal SBP during upfront treatment of cervical cancer, however this toxicity may have been grouped with other grade 2 toxicities and not specifically described as previously mentioned.

There are several aspects of this case worth further discussion. First, there was early concern that the rupture was iatrogenic. During the suspended brachytherapy treatment, 30 cc (out of the total 240 cc) were instilled before the rupture was noted on ultrasound. We hypothesize the rupture occurred near or soon after the fourth brachytherapy treatment, as this would account for the patient's interval signs and symptoms, and the volume instilled was negligible. Additionally, there was no evidence of through-and-through bladder injury, nor uterine perforation noted on exam or imaging studies. Second, our patient had an excellent response to EBRT with reduction in tumor volume allowing for a condensed treatment schedule. She received brachytherapy concurrently with her EBRT in the 4th and 5th weeks. There is no evidence a condensed schedule increases complication rates, although this treatment schedule has less long-term toxicity data and attribution cannot be definitively ruled out.

One notable limitation in our review was 3 articles excluded² from our initial PubMed search were written in Japanese. These cases all involved patients with a history of cervical cancer and bladder rupture. It is possible these papers may have presented similar cases. Additionally, our analysis is limited by studies describing patients treated over 10 years ago. Today, imaging advances, a switch from low-dose to high-dose brachytherapy, and the adaptation of intensity-modulated radiotherapy have changed and improved the precision of the delivered dose and limited radiation damage to surrounding structures (Lobo et al., 2018). Finally, we acknowledge our patient had several complicating factors in her history that have been associated with SBR in literature, namely past alcohol use, history of smoking, pregnancy, and psychiatric conditions. Any attempt at etiologic analysis at this point would be conjecture.

4. Conclusions

This case report and review of the literature describe the novel presentation of an *extraperitoneal* SBR occurring during chemoradiation for a patient with advanced cervical cancer. Prior cases have described *intraperitoneal* ruptures that have occurred years after the end of treatment. While SBRs tend to be morbid conditions, in this case our patient was able to proceed with conservative management with resolution of her rupture, which allowed for completion of her therapy without further delay or morbidity - paramount to survival for this disease. As data is gathered on the acute and late toxicities of modern chemoradiation, patients at increased risk for morbidity may be better

¹ Version 4.0.

² PMID 21817848; PMID 10769806; PMID 12166239.

identified by their providers.

CRediT authorship contribution statement

Annalyn Welp: Investigation, Writing - original draft, Writing - review & editing. **Emma C. Fields:** Writing - review & editing, Supervision. **Leslie Randall:** Writing - review & editing, Supervision. **Florence K. Brown:** Investigation. **Stephanie A. Sullivan:** Investigation, Writing - review & editing, Supervision, Resources.

Declaration of Competing Interest

The authors declare that they have no known competing financial interests or personal relationships that could have appeared to influence the work reported in this paper.

References

- Fujikawa, K., Yamamichi, F., Nonomura, M., Soeda, A., Takeuchi, H., 1999. Spontaneous rupture of the urinary bladder is not a rare complication of radiotherapy for cervical cancer: Report of six cases. *Gynecol. Oncol.* 73 (3), 439–442.
- Green, J.A., Kirwan, J.M., Tierney, J.F., Symonds, P., Fresco, L., Collingwood, M., et al., 2001. Survival and recurrence after concomitant chemotherapy and radiotherapy for cancer of the uterine cervix: A systematic review and meta-analysis. *Lancet* 358 (9284), 781–786.
- Lobo, N., Kulkarni, M., Hughes, S., Nair, R., Shamim Khan, M., Thuraija, R., 2018. Urologic complications following pelvic radiotherapy. *Urology* 122, 1–9. <https://doi.org/10.1016/j.urolgy.2018.07.017> [cited 2020 Feb 3].
- Mitchell, T., Al-Hayek, S., Patel, B., Court, F., Gilbert, H., 2011. Acute abdomen caused by bladder rupture attributable to neurogenic bladder dysfunction following a stroke: A case report. *J. Med. Case Rep.* 5.
- Morris, M., Eifel, P.J., Lu, J., Grigsby, P.W., Levenback, C., Stevens, R.E., et al., 1999. Pelvic radiation with concurrent chemotherapy compared with pelvic and para-aortic radiation for high-risk cervical cancer. Available from [cited 2020 Apr 7] *N. Engl. J. Med.* 340 (15), 1137–1144.
- NCI, 2020. Common Terminology Criteria for Adverse Events (CTCAE) [Internet]. Available from: https://ctep.cancer.gov/protocolDevelopment/electronic_applications/ctc.htm#ctc_40.
- Nishimura, T., Suzuki, K., Iijima, M., Nozue, M., Imai, M., Suzuki, S., et al., 2000. Spontaneous rupture of bladder diverticulum after postoperative radiotherapy for carcinoma of the uterine cervix: a case report. Available from [cited 2020 Apr 6] *Radiat. Med.* 18 (4), 261–265.
- Rose, P.G., Bundy, B.N., Watkins, E.B., Thigpen, J.T., Deppe, G., Maiman, M.A., et al., 1999. Concurrent cisplatin-based radiotherapy and chemotherapy for locally advanced cervical cancer. *N. Engl. J. Med.* 340 (15), 1144–1153.
- Shin, J.Y., Yoon, S.M., Choi, H.J., Lee, S.N., Kim, H.B., Joo, W.C., et al., 2014. A case of post-radiotherapy urethral stricture with spontaneous bladder rupture, mimicking obstructive uropathy due to cancer metastasis. *Electrolyte Blood Press.* 12 (1), 26–29.
- Tewari, K.S., Monk, B.J., 2019. Evidence-based treatment paradigms for management of invasive cervical carcinoma. *J. Clin. Oncol. Am. Soc. Clin. Oncol.* 37, 2472–2482.