

CASE REPORT

Emergency clamshell thoracotomy in blunt trauma resuscitation: Shelling the paradigm-2 cases and review of the literature

Patrick Schober^{1,2} | Marcel A. de Leeuw^{1,2} | Maartje Terra^{2,3} |
Stephan A. Loer^{1,2} | Lothar A. Schwarte^{1,2} 

¹Department of Anesthesiology, VU University Medical Center, Amsterdam, The Netherlands

²Trauma Center with HEMS Lifeline 1, VU University Medical Center, Amsterdam, The Netherlands

³Department of Traumatology, VU University Medical Center, Amsterdam, The Netherlands

Correspondence

Lothar A. Schwarte, Department of Anesthesiology, VU University Medical Center, Amsterdam, The Netherlands.
Email: L.Schwarte@VUmc.NL

Key Clinical Message

Clamshell thoracotomy (CST) may be indicated and life-saving in carefully selected cases of blunt trauma. As such, the current clinical stance of general contraindication of CST in blunt trauma should be reviewed and criteria developed to accommodate select cases, considering the diversity of injuries resulting from blunt trauma.

KEYWORDS

arrest, blunt trauma, clamshell, return of spontaneous circulation, sterno-thoracotomy, thoracotomy

1 | INTRODUCTION

Advances in prehospital emergency medicine allow that treatment options traditionally reserved for in-hospital care are performed increasingly already in the prehospital setting. One example for this development is the transverse sterno-thoracotomy, also coined clamshell thoracotomy (CST).^{1,2} Prehospital CST is generally reserved for penetrating traumas, that is, stab and shot wounds. In contrast, blunt trauma is generally regarded as contraindication for CST.³⁻⁵ This is also the case in the regional guideline of our area of practice, that is, the “clamshell guideline of the Lifeline 1”. This discouragement is based on outcome reports on the overall group of blunt trauma.^{6,7} However, realizing that the mixed population with blunt trauma covers a broad spectrum with diverging pathologies, we suggest that selected subpopulations with blunt trauma might benefit from CST. Therefore, we believe that the dogma of *no CST in blunt trauma* is too simplistic⁵ and should be revised to consider CST also in selected prehospital blunt trauma scenarios. To support this idea, we present 2 cases in which patients in circulatory arrest settings

successfully underwent prehospital CST and were stabilized and transported to the emergency room and subsequently to the operation theater.

2 | THE CASE REPORTS

2.1 | Case #1

An elderly driver of a private car crashed with a truck. Upon arrival of the ambulance, the patient was fully awake, with no apparent head trauma. The ambulance personnel found only a left forearm injury (bleeding, successfully treated with a tourniquet) and suspected a left thoracic injury with diminished breath sounds upon chest auscultation. The patient then deteriorated into circulatory arrest with unmeasurable blood pressure (Figure 1). From an immediate left thoracic puncture (with an IV cannula) and a subsequently placed pleural drain, it was suspected that the patient had severe intrathoracic hemorrhage. The HEMS team on scene decided to perform a prehospital CST, which demonstrated ongoing intrathoracic hemorrhage, which could then be controlled

(Figure 2A,B). The patient was stabilized and transported to a Level I trauma center for further treatment (Figure 1) with restored vital parameters (blood pressure 115/79 mm Hg; heart rate 103/min; pulseoxymetric oxygen saturation 93%; end-tidal CO₂ 32 mm Hg).

2.2 | Case #2

A teenager crashed with his scooter against a truck. During initial treatment in the ambulance vehicle, the patient deteriorated into circulatory arrest with asystole. There was a high suspicion of an intrathoracic pathology and as such, an

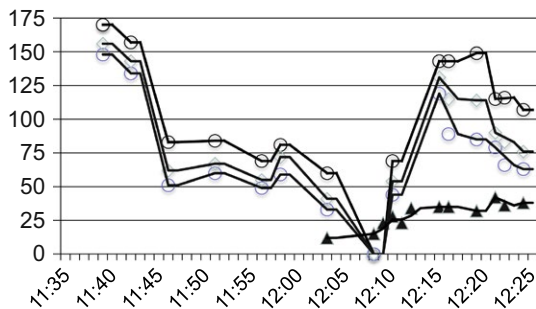


FIGURE 1 Vital parameters in the peri-arrest setting of case #1, with circulatory arrest and the clamshell thoracotomy at about 12:05–12:10. Systolic, mean, and diastolic blood pressure (open symbols, given in [mm Hg]); end-tidal CO₂ (filled symbol, also given in [mm Hg])

immediate CST was performed by the HEMS team in the ambulance, eg, to allow for bimanual open cardiac compressions. A cardiac contusion was suspected as trigger for arrest, with no apparent other major pathology. Within 1 minute of bimanual open cardiac massage, cardiac activity restarted and a return of spontaneous circulation (ROSC) was achieved, with adequate blood pressure and capnographic CO₂ output. No further episode of relevant arrhythmias or arrest occurred thereafter, and the patient was stabilized and transported for further treatment to a Level I trauma center.

In both patients, our standard technique for CST was applied after endotracheal intubation: using a scalpel, a left-sided axillary thoracotomy (fifth intercostal space) was advanced ventrally to the sternum, thereafter the sternum horizontally dissected with a dressing scissor, and finally the scalpel used to perform a right-sided incision in the fifth intercostal space from sternum into the axilla. This complete transverse thoracic incision was then spread open using a Finochietto rib retractor, allowing visualization of both lungs and the mediastinum with the heart (clamshell aspect, Figure 2B).

Both patients were successfully resuscitated, stabilized, and transported to a Level I trauma center. In the subsequent course of the treatment, both patients however succumbed: in the operation theater, patient #1 developed coagulation disorders (with TEE-confirmed, cardiac thrombus formation), and in patient #2 the therapy was deliberately terminated in consensus because of unexpected intracranial pathologies with

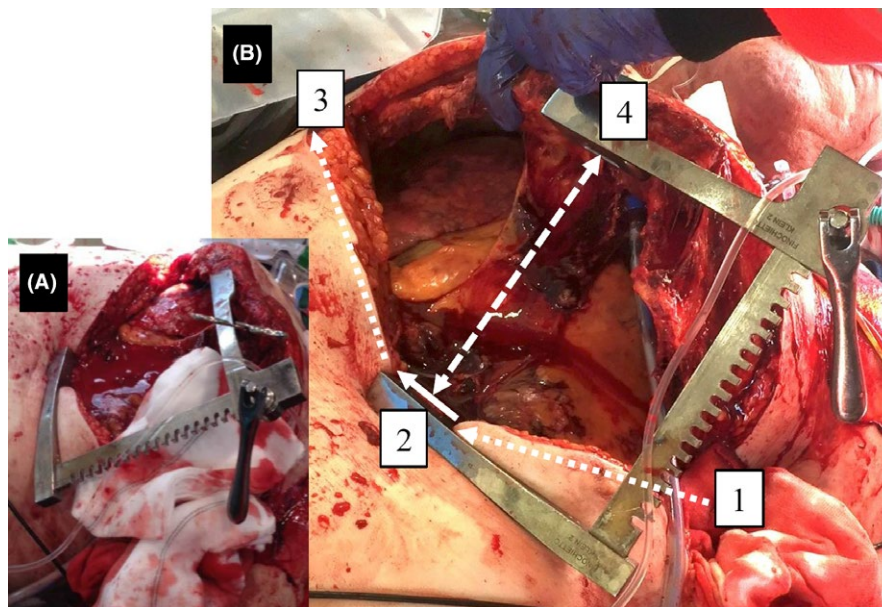


FIGURE 2 (A, B) The clamshell thoracotomy of case #1 (printed with permission, pictures taken in the ambulance vehicle). Inlay A shows the clamshell aspect obscured by the hemorrhage and gauze. Picture B, after hemorrhage control, depicts the steps leading to the clamshell aspect: using a scalpel, a left-sided axillary thoracostomy (fifth intercostal space) was advanced ventrally to the sternum (1, dotted line), thereafter the sternum transversally dissected (2, solid line) with a dressing scissor, and finally the scalpel used to perform a right-sided incision in the fifth intercostal space from sternum into the axilla (3, dotted line). This transversal thorax incision was then spread open with a Finochietto rib retractor (4, dashed line), allowing visualization of both lungs and the mediastinum with the heart

poor neurologic prognosis (such as traumatic arterial tear, resulting in cerebral hypoperfusion).

3 | DISCUSSION

In the presented cases, blunt injury was the obvious mechanism of trauma, generally regarded as contraindication for CST.³⁻⁵ However, both patients were successfully resuscitated from the circulatory arrest setting, stabilized, and transported to the emergency room, and subsequently to the operation theater.

In contrast to other world regions, penetrating thoracic trauma by stabbing and gunshots, where CST is indicated, are a relatively rare cause for traumatic resuscitation in our HEMS area. On the contrary, blunt thoracic trauma requiring resuscitation particularly after traffic accidents (as presented in both cases) is more common in our HEMS area. Therefore, we suggest, that refining the dogma of *no CST for blunt trauma* will allow us to beneficially apply this technique to the population that is more predominant in our HEMS setting.

Indirectly, this refinement may also be supported by more recent literature on emergency thoracotomies in hospitals, however unspecified for CST. Although beneficial outcome after emergency thoracotomy in blunt trauma was traditionally regarded almost nihil,^{8,9} a recent systematic review demonstrates a survival of >25% (49 of 193 patients) after emergency thoracotomy in blunt trauma, even with good neurologic outcome.¹⁰ Specifically for blunt trauma CST, there is at least 1 case report¹¹ encouraging resuscitative in-hospital CST in blunt trauma. CST would allow faster and better access to thoracic organs for diagnosis and intervention,^{12,13} which might support even better outcome, compared to other thoracotomy techniques.^{2,13,14} Herein, rapid thoracic organ access should support a faster reversal of cardiac arrest, protecting cerebral perfusion, and limit hypoxic damage. Searching the scientific literature (via PubMed.org) for *clamshell + prehospital* resulted in only 1 case report,¹⁵ that is, on a penetrating knife injury, suggesting that the topic of prehospital CST in blunt trauma requires further studies.

The CST in both presented cases was performed in our standard technique, however, the subsequent interventions markedly differed: in case #1, the CST allowed identification of an intrathoracic bleeding focus and hemorrhage control, in case #2 it allowed access to the chest and open cardiac massage¹² resulting in a rapid and sustained return of spontaneous circulation (ROSC). In both cases also inspection for cardiac injuries was done, particularly checking for relevant pericardial tamponade, which might be a strong indication for CST. No relevant cardiac tamponades were found, therefore pericardiocentesis was omitted. If other factors contributed to the resuscitation of

these patients (eg, improved decompression¹⁶ of a hemato-/pneumo-thorax by CST) remains speculative.

Our encouragement to deliberate the use of CST in blunt trauma should also address questions on criteria for case selection. A too liberal case selection will lead to CST in patients beyond repair, whereas a too strict selection will withhold lifesaving interventions from certain patients that may have benefitted, and will also reduce the overall exposure and expertise of the team. Although in the 2 presented cases the situation of a physician-witnessed deterioration into a circulatory arrest was observed and a sustained ROSC was achieved, this obviously does not guarantee beneficial long-term outcome. Thus a delicate balance must be achieved between these poles. In addition, CST places a psychological burden to all who witness the procedure.

We are clearly not advocating CST in all blunt trauma patients in (imminent) arrest settings, even if intrathoracic injuries are highly suspected. In the presented cases, we selected patients with rapid clinical deterioration into a cardiovascular arrest situation, that was witnessed by an attending physician, with a CST trained and equipped medical team on site, and in which no major extra-thoracic injuries were apparent. In addition, our HEMS area contains several Level I trauma centers to rapidly receive and treat our patients. These criteria match or even exceed criteria that are suggested by others to support thoracotomies in blunt trauma emergencies. The European Resuscitation Council¹⁷ advocates the 4-E-rule, where adequate expertise, equipment, environment, and an elapsed time <10 minutes after cardiac arrest are prerequisites for emergency thoracotomy. The Western Trauma Association¹⁸ also advocates a cut-off time <10 minutes for blunt trauma without signs of life, or a condition of refractory shock (ie, CPR with signs of life or a systolic blood pressure <60 mm Hg).

In summary, to our knowledge, we present the first 2 cases where prehospital CST in blunt traumas were successfully performed, leading to sustained ROSC. We suggest that the dogma of limiting CST to penetrating trauma should be scrutinized and an extension to selected blunt trauma cases deliberated.^{19,22} Further studies are required to divide the heterogeneous population with blunt trauma into subgroups where CST is futile or beneficial, ultimately leading to an improved outcome.

CONFLICT OF INTEREST

No conflict of interest.

AUTHORSHIP

PS: case MD, manuscript. MAL: manuscript. MT: technique trainer, manuscript. SAL: case discussion, manuscript. LAS: case MD, manuscript.

ORCID

Lothar A. Schwarte  <http://orcid.org/0000-0001-6119-7810>

REFERENCES

- Voiglio EJ, Flaris AN, Simms ER, Prat NJ, Reynard FA, Caillot JL. The clamshell incision can be easily taught to both emergency physicians and surgeons. *Injury*. 2015;46:2084-2085.
- Voiglio EJ, Simms ER, Flaris AN, Franchino X, Thomas MS, Caillot JL. Bilateral anterior thoracotomy (clamshell incision) is the ideal emergency thoracotomy incision: an anatomical study: reply. *World J Surg*. 2014;38:1003-1005.
- Wise D, Davies G, Coats T, Lockety D, Hyde J, Good A. Emergency thoracotomy: "how to do it". *Emerg Med J*. 2005;22:22-24.
- Lorenz HP, Steinmetz B, Lieberman J, Schecoter WP, Macho JR. Emergency thoracotomy: survival correlates with physiologic status. *J Trauma*. 1992;32:780-785. discussion 5-8.
- Roberts K. The role for surgery in prehospital care. *Trauma*. 2016;18:92-100.
- Powell DW, Moore EE, Cothren CC, et al. Is emergency department resuscitative thoracotomy futile care for the critically injured patient requiring prehospital cardiopulmonary resuscitation? *J Am Coll Surg*. 2004;199:211-215.
- Duron V, Burke RV, Bliss D, Ford HR, Upperman JS. Survival of pediatric blunt trauma patients presenting with no signs of life in the field. *J Trauma Acute Care Surg*. 2014;77:422-426.
- Cothren CC, Moore EE. Emergency department thoracotomy for the critically injured patient: objectives, indications, and outcomes. *World J Emerg Surg*. 2006;1:4.
- Mitchell TA, Waldrep KB, Sams VG, Wallum TE, Blackburn LH, White CE. An 8-year review of operation enduring freedom and operation iraqi freedom resuscitative thoracotomies. *Mil Med*. 2015;180:33-36.
- Narvestad JK, Meskinfamfard M, Soreide K. Emergency resuscitative thoracotomy performed in European civilian trauma patients with blunt or penetrating injuries: a systematic review. *Eur J Trauma Emerg Surg*. 2016;42:677-685.
- Goh ES, Cheah YL, Mak KS. The 'clamshell' approach to emergency department thoracotomy. *Singapore Med J*. 2015;56:481.
- Puchwein P, Sommerauer F, Clement HG, et al. Clamshell thoracotomy and open heart massage—A potential life-saving procedure can be taught to emergency physicians: an educational cadaveric pilot study. *Injury*. 2015;46:1738-1742.
- Simms ER, Flaris AN, Franchino X, Thomas MS, Caillot JL, Voiglio EJ. Bilateral anterior thoracotomy (clamshell incision) is the ideal emergency thoracotomy incision: an anatomic study. *World J Surg*. 2013;37:1277-1285.
- Flaris AN, Simms ER, Prat N, Reynard F, Caillot JL, Voiglio EJ. Clamshell incision versus left anterolateral thoracotomy. Which one is faster when performing a resuscitative thoracotomy? The tortoise and the hare revisited. *World J Surg*. 2015;39:1306-1311.
- Rudolph M, Schneider NR, Popp E. Clamshell thoracotomy after thoracic knife wounds. *Unfallchirurg*. 2017;120:344-349.
- Mistry N, Bleetman A, Roberts KJ. Chest decompression during the resuscitation of patients in prehospital traumatic cardiac arrest. *Emerg Med J*. 2009;26:738-740.
- Monsieurs KG, Nolan JP, Bossaert LL, et al. European resuscitation council guidelines for resuscitation 2015: section 1. Executive summary. *Resuscitation*. 2015;95:1-80.
- Burlew CC, Moore EE, Moore FA, et al. Western Trauma Association critical decisions in trauma: resuscitative thoracotomy. *J Trauma Acute Care Surg*. 2012;73:1359-1363.
- Inaba K, Chouliaras K, Zakaluzny S, et al. FAST ultrasound examination as a predictor of outcomes after resuscitative thoracotomy: a prospective evaluation. *Ann Surg*. 2015;262:512-518. discussion 6-8.
- Seamon MJ, Haut ER, Van Arendonk K, et al. An evidence-based approach to patient selection for emergency department thoracotomy: a practice management guideline from the Eastern Association for the Surgery of Trauma. *J Trauma Acute Care Surg*. 2015;79:159-173.
- Miki T. Clamshell thoracotomy for two cases of blunt traumatic cardiac rupture. *Jpn J Cardiovasc Surg*. 2014;43:230-233.
- Kim DH, Chang SW, Yun JH. Emergency department thoracotomy with clamshell incision for traumatic cardiac tamponade. *J Korea Soc Emerg Med*. 2017;28:141-146.

How to cite this article: Schober P, de Leeuw MA, Terra M, Loer SA, Schwarte LA. Emergency clamshell thoracotomy in blunt trauma resuscitation: Shelling the paradigm—2 cases and review of the literature. *Clin Case Rep*. 2018;6:1521–1524. <https://doi.org/10.1002/ccr3.1653>