

Case report

Metastases from lung adenocarcinoma within a leiomyoma: A case report☆☆☆



Shannon K Rush^a, Mirna N Toukatly^b, Mark R Kilgore^b, Renata R Urban^{c,*}

^a University of Washington Medical Center, Department of Obstetrics and Gynecology, Seattle, WA, United States

^b University of Washington Medical Center, Department of Pathology, Seattle, WA, United States

^c University of Washington Medical Center, Division of Gynecologic Oncology, Seattle, WA, United States

ARTICLE INFO

Article history:

Received 6 December 2016

Received in revised form 31 January 2017

Accepted 3 February 2017

Available online 6 February 2017

Keywords:

Leiomyoma
Lung carcinoma
Metastases
PET avid

ABSTRACT

Background: Pulmonary adenocarcinoma rarely spreads to the gynecologic tract, and has not been fully reported to metastasize within a leiomyoma.

Case: A 47 year-old woman with recurrent pulmonary adenocarcinoma was incidentally found to have a positron emission tomography (PET) avid pelvic mass at the time of restaging. She was also noted to be anemic, and reported significant vaginal bleeding. She was taken for an uncomplicated hysterectomy. She was unexpectedly found to have adenocarcinoma within a leiomyoma, consistent with metastasis from her primary pulmonary adenocarcinoma.

Conclusion: We report one of the first cases of pulmonary adenocarcinoma metastatic to a uterine leiomyoma. A personal history of cancer should always be considered in patients presenting with symptomatic leiomyoma.

© 2017 The Authors. Published by Elsevier Inc. This is an open access article under the CC BY-NC-ND license (<http://creativecommons.org/licenses/by-nc-nd/4.0/>).

1. Introduction

We describe one of the first reported cases of a patient with recurrent pulmonary adenocarcinoma, who was incidentally found to have a PET-avid pelvic mass on her PET-CT, and ultimately diagnosed with recurrent pulmonary adenocarcinoma metastatic to a leiomyoma.

2. Case

A 47-year-old G4P4004 non-smoker with a history of recurrent multifocal pulmonary adenocarcinoma was referred for consultation for a suspicious pelvic mass that was incidentally identified on a staging PET-CT. She was initially diagnosed with pulmonary adenocarcinoma outside of the United States (US) in 2012 after presenting with a mass in the left upper lung lobe incidentally identified on chest X-ray. She underwent a thoracotomy, left upper lobectomy, and subsequent chemotherapy. She completed approximately four weeks of treatment, then elected to discontinue due to severe nausea, vomiting, and fatigue.

☆ Precis: We present one of the first cases of a leiomyoma containing metastatic lung carcinoma.

☆☆ The authors have no conflicts of interest. Written informed consent was obtained from the patient for publication of this case report and accompanying images. A copy of the written consent is available for review by the Editor-in-Chief of this journal on request.

* Corresponding author at: Department of Obstetrics & Gynecology, University of Washington Medical Center, 1959 NE Pacific Street, Campus Box 356460, Seattle, WA 98195-6460, United States.

E-mail address: urbanr@u.washington.edu (R.R. Urban).

She underwent cancer surveillance for approximately eighteen months, at which time recurrent disease was discovered in the right lung. She was started on icotinib presumptively, reportedly without Epidermal Growth Factor Receptor (EGFR) testing, given her prior toxicities with chemotherapy. After starting icotinib, she moved to the US and presented to a local hospital for treatment of her pulmonary adenocarcinoma. In the course of establishing care, she was discovered to have profound anemia, requiring transfusion of two units of blood after a syncopal event. A PET-CT was eventually completed, demonstrating multiple PET-avid lung lesions, as well as a multi-lobulated pelvic mass measuring 10.6 × 8.8 cm with a maximum standardized uptake value (SUV) of 3.7. She had a CT-guided biopsy of a right lung nodule notable for adenocarcinoma consistent with recurrent pulmonary adenocarcinoma. There were no EGFR, anaplastic lymphoma kinase (ALK), or ROS proto-oncogene receptor tyrosine kinase 1 (ROS-1) mutations.

At her initial consultation with Gynecologic Oncology, she reported heavy menses lasting about four days and a history of anemia. Her gynecologic history was notable for menarche at age fifteen, four spontaneous vaginal deliveries without complication, and ongoing heavy, regular menstruation. She denied prior sexually transmitted diseases, had never had a Pap smear, and had never taken any form of hormonal treatment. On exam, her uterus was large, smooth, and mobile. There were no visible lesions on the cervix, and a Pap smear was collected, which was negative. A mass separate from the uterus was not palpated. Laboratory studies included a CA-125 elevated at 190, hemoglobin 9.8, hematocrit 31.5, high total iron binding capacity of 379, and low ferritin level of 3.0.

She was consented for and underwent a robotic-assisted laparoscopic total hysterectomy and bilateral salpingectomy. An exam under anesthesia demonstrated a large and mobile pelvic mass that was indistinguishable from the uterus. Intra-abdominally, she had two normal-appearing ovaries. The uterus itself was globular and enlarged with a large posterior leiomyoma. The remainder of the intra-abdominal survey was unremarkable. The estimated blood loss was 200 mL. The patient tolerated the procedure well, with a hematocrit of 32 on postoperative day one. Her postoperative course was unremarkable.

The pathology was reviewed and noted to have a focus of high-grade adenocarcinoma within an otherwise unremarkable leiomyoma (Fig. 1). By immunohistochemistry (IHC), Thyroid Transcription Factor 1 (TTF-1) was expressed strongly and diffusely in the carcinoma cells and not in the smooth muscle or stromal cells, supporting a diagnosis of metastatic pulmonary adenocarcinoma. The pathology findings were communicated to her medical oncologist, and the patient was scheduled for follow-up oncology care.

3. Discussion

When the patient initially presented, the pelvic mass was favored to be a symptomatic leiomyoma, given her exam and history of heavy menstrual bleeding. Leiomyomas are the most common pelvic tumors in women, and are the most common indication for hysterectomy in the US (Styer and Rueda, 2016). Common presenting symptoms include excessive cyclic bleeding, pelvic pain or mass effect including abdominal pain, bloating or constipation (Styer and Rueda, 2016).

A literature search was conducted in PubMed, using the terms “metastasis to fibroid,” “metastasis to leiomyoma,” “cancers metastasize to gynecologic organs,” “cancer metastasis to uterus,” and “extra genital cancer metastases to uterus,” and further references were collected based on works cited by reviewed articles. There were reports of invasive breast cancer (lobular and ductal) (Toyoshima et al., 2015), two cases of stomach and pancreas, gallbladder (Kumar and Hart, 1982), melanoma (Chanthasenont et al., 2015), a gastric adenocarcinoma metastatic to a lipoleiomyoma, and leiomyosarcoma metastasizing to leiomyomata. The most complete of these works included 63 cases of extragenital metastasis to the uterine corpus, with 13 cases involving leiomyomata, and 6 of those 13 solely involving a metastasis to a leiomyoma (Kumar and Hart, 1982). Breast cancer was the most commonly found extragenital neoplasm metastasizing to leiomyomata in that review; invasive lobular over ductal breast carcinoma more commonly spread to the gynecologic organs (Toyoshima et al., 2015).

Malignant neoplasms that metastasize to the gynecologic tract commonly spread to the ovary. The most common extragenital malignancies that metastasize to the gynecologic tract include colon and breast, with other reports finding gastric cancer metastases, especially in one study set in Japan, where the rate of gastric cancer is much higher overall. In those pelvic masses thought to be primary ovarian cancers, between 5 and 20% of these ultimately are found to be metastases (Moore et al., 2004). Common malignant neoplasms that metastasize to the gynecologic tract include colon and breast, with other reports finding gastric cancer metastases, especially in one study set in Japan, where the rate of gastric cancer is much higher overall. In those pelvic masses thought to be primary ovarian cancers, between 5 and 20% of

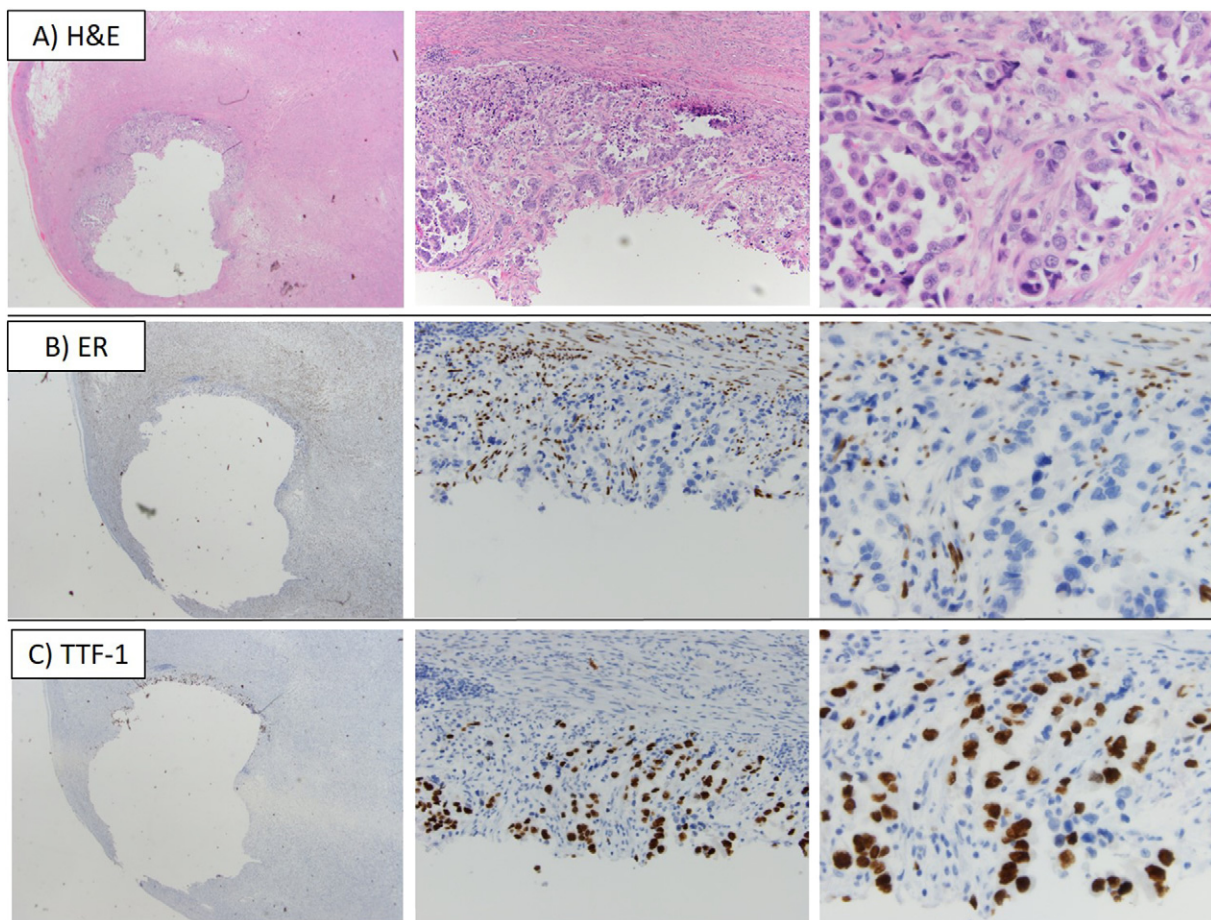


Fig. 1. A) Hematoxylin and Eosin (H&E)-stained slide of leiomyoma involved by high-grade adenocarcinoma. B) Estrogen Receptor (ER) IHC-stained slide; ER is expressed in smooth muscle and stromal cells and is negative for expression in the carcinoma cells. C) TTF-1 IHC-stained slide; TTF-1 is expressed strong and diffusely in the carcinoma cells and is negative for expression in smooth muscle and stromal cells. All photographs are taken at 2 \times , 10 \times , and 40 \times , respectively from left to right, with a 0.55 mm objective and an Olympus DP73 camera.

these ultimately are found to be metastases (Toyoshima et al., 2015). Finding occult uterine malignant neoplasms in presumed benign leiomyomata after surgery is uncommon but controversial. In the recent debate surrounding a diagnosis of leiomyosarcoma following morcellation, a comprehensive literature review that included 134 analyses reported a total of 32 leiomyosarcoma diagnoses in 30,193 women, with a total prevalence of one leiomyosarcoma diagnosis per 2000 surgeries performed for leiomyomata (Kumar and Hart, 1982). A review of occult malignancy found at the time of hysterectomy for benign indications revealed that less than 2% of surgeries for leiomyoma had occult cancers diagnosed following surgery, with such cancers including cervical, endometrial and metastatic cancer (Mahnert et al., 2015).

There are a number of case reports of leiomyomata metastatic to the lung in the setting of benign metastasizing leiomyomas (Miller et al., 2016). In a review of the literature, only case reports are available of pulmonary adenocarcinoma metastasizing to gynecologic organs. Primary pulmonary adenocarcinoma was found in 11 of 32 ovarian metastases from primary pulmonary carcinomas reported in a series by Irving and Young (2005). In addition, there are two English reports and three cases of pulmonary adenocarcinoma metastasizing to the uterine endometrium (Ahmad and Raza, 2015; Tiseo et al., 2011). However, there is only one obscure reference of a lung primary found within and confined to a leiomyoma (Kumar and Hart, 1982). Though rare, metastatic disease in the gynecologic organs should be on the differential when a PET-avid mass is identified in the pelvis, especially when another primary cancer has already been diagnosed.

The pathology assessment of this tissue required IHC to support the diagnosis of metastatic pulmonary adenocarcinoma. TTF-1 is a rather sensitive, but not specific, marker for pulmonary adenocarcinoma. In a database of 3593 cases of primary pulmonary adenocarcinomas and 140 metastatic pulmonary carcinomas, 74% and 73%, respectively, were reported as immunoreactive for TTF-1 (PathIQ® ImmunoQuery®). Adenocarcinoma with this morphology, that is strong and diffusely immunoreactive for TTF-1 in a patient with a history of pulmonary adenocarcinoma and no other evidence of disease, is most consistent with a diagnosis of metastatic pulmonary adenocarcinoma. Negative ER expression in the carcinoma cells in this context is neither sensitive nor specific, however, is in keeping with the aforementioned interpretation.

In approaching this and all clinical cases, the patient's symptoms, differential diagnosis, and possible interventions have to be considered in the context of her medical history and the improvement in quality of life

that possible interventions may afford. Our patient presented with known recurrent pulmonary adenocarcinoma, and thus a possible metastasis should be considered in the differential diagnosis of her pelvic mass. When deciding on surgical intervention, the purpose of resecting the pelvic mass was to provide not only a diagnosis but also to provide resolution of her symptomatic menorrhagia. Furthermore, the identification of metastases from her primary pulmonary adenocarcinoma within her leiomyomas indicates small-volume, but distant disease, which is important information when counseling on further antineoplastic and supportive therapy for her primary malignancy (Mehta et al., 2004). Lastly, a personal history of cancer is key to provide to pathologists in order to comprehensively assess uterine leiomyomas following surgical removal.

References

- Ahmad, Z., Raza, A., 2015 May 18. Endometrial metastasis of lung adenocarcinoma: a report of two cases. *Am. J. Case Rep.* 16, 296–299.
- Chanthasenanont, A., Nantakomon, T., Kintarak, J., Vithisuvanakul, N., Pongrojapaw, D., Suwannarurk, K., 2015 Apr. Incidental finding of metastatic cutaneous malignant melanoma at uterine leiomyoma. A Thai University Hospital experience: a case report. *J. Med. Assoc. Thai.* 98 (Suppl. 3), S126–S131.
- Irving, J.A., Young, R.H., 2005. Lung carcinoma metastatic to the ovary: a clinicopathologic study of 32 cases emphasizing their morphologic spectrum and problems in differential diagnosis. *Am. J. Surg. Pathol.* 29 (8), 997–1006.
- Kumar, N.B., Hart, W.R., 1982 Nov 15. Metastases to the uterine corpus from extragenital cancers. A clinicopathologic study of 63 cases. *Cancer* 50 (10), 2163–2169.
- Mahnert, N., Morgan, D., Campbell, D., Johnston, C., As-Sanie, S., 2015. Unexpected gynecologic malignancy diagnosed after hysterectomy performed for benign indications. *Obstet. Gynecol.* 125 (2), 397–405.
- Mehta, N., Mauer, A.M., Hellman, S., et al., 2004. Analysis of further disease progression in metastatic non-small cell lung cancer: implications for locoregional treatment. *Int. J. Oncol.* 25 (6), 1677–1683.
- Miller, J., Shoni, M., Siegert, C., Lebenthal, A., Godleski, J., McNamee, C., 2016 Jan. Benign metastasizing leiomyomas to the lungs: an institutional case series and a review of the recent literature. *Ann. Thorac. Surg.* 101 (1), 253–258.
- Moore, R.G., Chung, M., Granai, C.O., Gajewski, W., Steinhoff, M.M., 2004. Incidence of metastasis to the ovaries from nongenital tract primary tumors. *Gynecol. Oncol.* 93 (1), 87–91.
- PathIQ® ImmunoQuery®. <https://app.immunoquery.com/>. (Antibody panel for TTF-1, <https://app.immunoquery.com/>, accessed 6/27/16).
- Styer, A.K., Rueda, B.R., 2016 Jul. The epidemiology and genetics of uterine leiomyoma. *Best Pract. Res. Clin. Obstet. Gynaecol.* 34, 3–12.
- Tiseo, M., Bersanelli, M., Corradi, D., et al., 2011 May. Endometrial metastasis of lung adenocarcinoma: a case report. *Tumori* 97 (3), 411–414.
- Toyoshima, M., Iwahashi, H., Shima, T., et al., 2015 Feb 14. Solitary uterine metastasis of invasive lobular carcinoma after adjuvant endocrine therapy: a case report. *J. Med. Case Rep.* 9, 47.