

Original Article

Factors affecting results of fluoroscopy-guided facet joint injection: Probable differences in the outcome of treatment between pure facet joint hypertrophy and concomitant diseases

Akif Albayrak, Baris Ozkul, Mehmet Bulent Balioglu, Yunus Atici, Muhammet Zeki Gultekin¹, Merih Dilan Albayrak²

Department of Orthopaedics and Traumatology, MS Baltalimani Bone Disease and Research Hospital Istanbul, ¹Department of Orthopaedics and Traumatology, Sanliurfa State Hospital, Sanliurfa, ²Department of Anesthesiology, Yedikule Chest Disease and Research Hospital, Istanbul, Turkey

Corresponding author: Dr. Akif Albayrak, Kağıthane Merkez Mahallesinde, Ece Sok Gönülevleri Sit C Blok Daire 5, Istanbul, Turkey.
E-mail: albayrakakif@gmail.com

Journal of Craniovertebral Junction and Spine 2016, 7:8

Abstract

Study Design: Retrospective cohort study. **Purpose:** Facet joints are considered a common source of chronic low-back pain. To determine whether pathogens related to the facet joint arthritis have any effect on treatment failure. **Materials and Methods:** Facet joint injection was applied to 94 patients treated at our hospital between 2011 and 2012 (mean age 59.5 years; 80 women and 14 men). For the purpose of analysis, the patients were divided into two groups. Patients who only had facet hypertrophy were placed in group A (47 patients, 41 women and 6 men, mean age 55.3 years) and patients who had any additional major pathology to facet hypertrophy were placed in group B (47 patients, 39 women and 8 men, mean age 58.9 years). Injections were applied around the facet joint under surgical conditions utilizing fluoroscopy device guidance. A mixture of methylprednisolone and lidocaine was used as the injection ingredient. **Results:** In terms of Oswestry Disability Index (ODI) and visual analog scale (VAS) scores, no significant difference was found between preinjection and immediate postinjection values in both groups, and the scores of group A patients were significantly lower ($P < 0.005$) compared with that of group B patients at the end of the third, sixth, and twelfth month. **Conclusion:** For low-back pain caused by facet hypertrophy, steroid injection around the facet joint is an effective treatment, but if there is an existing major pathology, it is not as effective.

Key words: Algology, facet hypertrophy, facet injection

This is an open access article distributed under the terms of the Creative Commons Attribution-NonCommercial-ShareAlike 3.0 License, which allows others to remix, tweak, and build upon the work non-commercially, as long as the author is credited and the new creations are licensed under the identical terms.

For reprints contact: reprints@medknow.com

How to cite this article: Albayrak A, Ozkul B, Balioglu MB, Atici Y, Gultekin MZ, Albayrak MD. Factors affecting results of fluoroscopy-guided facet joint injection: Probable differences in the outcome of treatment between pure facet joint hypertrophy and concomitant diseases. *J Craniovert Jun Spine* 2016;7:38-42.

Access this article online	
Quick Response Code:	Website: www.jcvjs.com
	DOI: 10.4103/0974-8237.176622

INTRODUCTION

In Western societies, two out of three people have low-back pain at some point during their life, and in one out of five of these cases, the pain persists for more than 4 weeks. Cases where symptoms persist for more than 7–12 weeks are diagnosed as chronic low-back pain.^[1]

Prominent structures that are the source of pain in the spine are the vertebral body, intervertebral discs, ligaments, muscles, roots, and facet joints.^[2]

Patients complain about pain caused by standing on their feet for a long time. The pain is generally felt 5 cm laterally to the centerline of the spine in paravertebral muscles on both sides. The application of local pressure increases pain in facet joints that are initially spotted as vulnerable through radiology imaging. The physical examination shows that the pain decreases when the patient leans forward, and it increases when they lean backwards and rotate.

In case of chronic low-back pain, treatment options are divided into nonsurgical and surgical ones. Nonsurgical treatment options include physical exercise; ultrasound; physical therapy modalities such as superficial and deep heat applications; and alternative medical practices such as acupuncture, massage, and traction manipulation. Oral drugs and locally applied drugs can be used as well. Another treatment option that has become popular in recent years is an imaging-assisted local injection and denervation technique.^[3-5]

In recent years, a multitude of randomized studies were performed, and this subject is popular in some branches like algology, physiotherapy, and interventional radiology.^[6-10]

Our aim is to demonstrate that for low-back pain produced by pure facet hypertrophy, steroid injection around the facet joint is an effective treatment. However, if there is an existing major pathology, it is not as effective.

MATERIALS AND METHODS

A total of 94 patients who were admitted to our hospital with complaints of low-back pain were included in the study. The patients were divided into two diagnosis groups according to their physical examination, x-ray, and magnetic resonance imaging (MRI) findings. Group A consisted of 47 patients confirmed to have only facet hypertrophy. Group B also had 47 patients, but these patients had facet hypertrophy in

addition to other condition(s) such as spondylolisthesis grades 1 and 2 (13 patients, 27.6%), retrolisthesis (1 patient, 2.1%), multiple discopathy (33 patients, 70.2%, protrusion or more grade), scoliosis (7 patients, 14.8%, *de novo* scoliosis), and coxarthrosis (2 patients, 14.2% idiopathic coxarthrosis). None of the patients from either group had sagittal and coronal balance defects [>5 cm deviation in central sacral vertical line (CSVL)]. Group A comprised of 41 women and 6 men with mean age of 55.3 years and group B comprised of 39 women and 8 men with mean age of 58.9 years. The age difference and sex difference between the two groups were not significant [Table 1].

Criteria required for patient inclusion:

- Low-back pain not responding to medicinal treatment for more than 3 months.
- A pain locally occurring at or around the lower back, without spreading to the legs.
- Palpation-induced sensitivity on the facet joint upon examination.
- Radiologic confirmation of facet hypertrophy.

Criteria required for patient exclusion:

- Central stenosis patients ($>50\%$ central or foraminal stenosis).
- Patients whose complaints about pain upon spreading to legs and numbing were more prevalent (radiculopathy).
- Patients who had additional pathologies such as infection or neoplasia.
- Patients who had a body mass index greater than 35.
- Patients with uncontrolled diabetes.

Statistical analysis

The normality inside the group was calculated using the Shapiro–Wilk test. The Wilcoxon test was also applied when in-group values were not found to be homogenous. Statistical Package for the Social Sciences (SPSS) version 20.0 software (SPSS-Inc., Chicago, IL) was used for the analysis. Cross-group differences were compared using Mann-Whitney *U*-test, which is a nonparametric two-group test.

Injection technique

The patients were informed about the procedure and signed consent was obtained from them prior to the procedure. Injection levels were decided by using results of MRI analysis and examinations made on the operating table.

Table 1: Patient demographics and sex distribution

		Group A		Group B		p		
		Mean.±s.s./n-%	Med (Min-Max)	Mean.±s.s./n-%	Med (Min-Max)			
Age		55.1±9.7	55	26-71	64.9±13.8	69	32-86	0.000
Sex	Male	6	13%		9	19%		0.398
	Female	41	87%		38	81%		

Mann-whitney u test / Chi square test

The patients were placed on the radiolucent operating table in prone position, and their backs were sterilized by povidone-iodine and were covered locally. In the procedure, first the needle was inserted into the palpated, tender facet joint following anteroposterior (AP) fluoroscopy imaging to confirm the location. After insertion of the needle, a 20° oblique fluoroscopy view was taken for the verification of the needle position [Figure 1].

Initially, the contrast agent was injected using a 22-gauge 10-cm black colored spinal needle. After feeling the contact with the bone and confirming that no bleeding occurred by negative aspiration, 2 mL of 2.5% bupivacaine and a methylprednisolone mixture were periarticularly injected into the medial side of the facet joint.

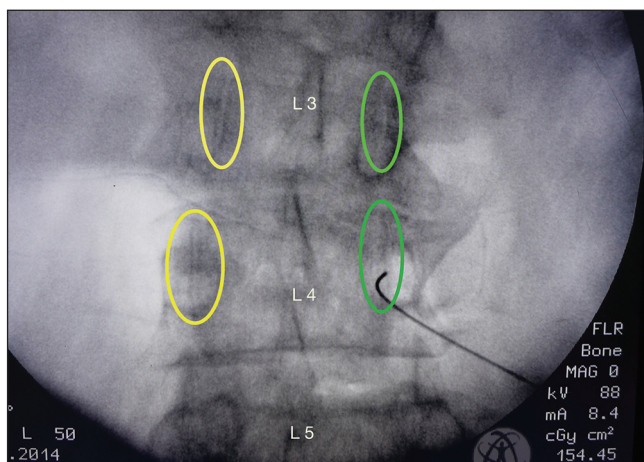


Figure 1: AP fluoroscopy image of L4 vertebra; spinal needle seen over the L4 facet

Soon after the occurrence of the postinjection relaxation at the region, which was a source of pain prior to injection by physical examination, the process was completed.

To eliminate any root irritation caused by the injection that might interfere with our study, the occurrence of any sensation of electric shock or numbing spreading to the leg was questioned, and the patient was kept under observation for an hour in the clinic in case of any allergic reaction.

RESULTS

In the patient evaluation, the lower back specific functional score such as Oswestry Disability Index (ODI) score and the general pain score such as visual analog scale (VAS) score were used.

In Table 2, pre and postinjection distribution of ODI and VAS scores for both groups are displayed. Preinjection ODI and VAS scores were found to be significantly higher ($P < 0.05$) compared with the 3- and 6-month postinjection scores.

Preinjectional VAS scores of patients from groups A and B were found to be significantly higher than the postinjection score at third and sixth months ($P < 0.05$). At the twelfth month, group A patients' scores were still significantly lower than preinjectional but for group B patients it was not still significantly lower than preinjectional VAS scores ($P > 0.05$). When comparing postinjectional change of the VAS scores of two groups, group A has a significantly higher change than group B [Table 2].

There was no significant difference in preinjection ODI scores between groups A and B ($P > 0.05$). Preinjection ODI scores were significantly higher in group A patients than postinjectional

Table 2: VAS and ODI scores comparison of group A and group B in the course of the treatment

		Group A			Group B			p
		Mean.±s.s.	Med (Min-Max)		Mean.±s.s.	Med (Min-Max)		
Visual Analog Scale	Preop	6.6±0.9	7	5-9	7.1±1.0	7	5-9	0.062
	3 Month	3.2±1.3*	3	1-6	6.0±1.6*	6	2-9	0.000
	6 Month	3.8±1.4*	4	2-8	6.6±1.6*	7	2-9	0.000
	12 Month	4.9±1.6*	5	2-7	7.3±1.5	8	3-9	0.000
Comparison with the preop								
	3 Month	-3.4±1.5	-3	-6-0	-1.1±1.5	-1	-5-2	0.000
	6 Month	-2.9±1.6	-3	-6-0	-0.6±1.1	0	-5-1	0.000
	12 Month	-1.6±1.5	-1	-5-0	-0.1±1.3	0	-4-2	0.002
Oswestry Index	Preop	56.3±10.0	56	30-74	59.3±8.1	58	44-82	0.156
	3 Month	28.8±11.3*	26	10-66	51.9±12.5*	52	24-80	0.000
	6 Month	33.8±13.1*	30	12-66	54.7±13.0*	56	26-84	0.000
	12 Month	44.5±18.0*	52	14-68	58.0±9.5	58	40-74	0.039
Comparison with the preop								
	3 Month	-27.5±11.4	-28	-50-0	-7.4±10.6	-4	-38-4	0.000
	6 Month	-21.8±12.7	-22	-49-2	-5.0±9.8	-2	-38-4	0.000
	12 Month	-10.9±14.4	-6	-46-4	-1.4±6.3	1	-22-4	0.023

Mann-whitney u test / Wilcoxon test, *Intra-group comparison $P < 0,05$

scores at third, sixth, and twelfth months ($P < 0.05$). Preinjectional ODI scores of group B were significantly lower at the third and sixth months postinjectionally ($P < 0.05$). At the twelfth month, the difference was not significant ($P > 0.05$) [Table 2].

ODI scores of group A patients were significantly lower compared with the scores of group B patients ($P < 0.05$) at the third, sixth, and twelfth months after applying the injection [Table 2].

The mean facet levels of injection was 2.42 for group A and 2.12 for group B. Nine patients in group A (19.1%) and five patients in group B (10.6%) had sacroiliac injections in addition to facet joint injection.

When group A patients were asked if they were satisfied with the treatment and if they would prefer it again, 91.5% of the patients gave positive response, whereas when group B patients were asked the same question, only 8.5% of the patients gave positive response ($P < 0.05$). This inadequate decrease in scores of group B patients was considered appropriate in light of the lower satisfaction rate.

The patients' preinjection and postinjection needs for analgesic medication were also questioned. The use of medication prior to the treatment for group A patients was 90% and was for group B patients it was 97%. At the third month after applying the injection, these figures dropped to 10% for group A and to 71% for group B. At the sixth month after applying the injection, the figures increased to 31% for group A and 96% for group B [Table 3].

DISCUSSION

Facet joints are the source of low-back pain in 15-52% of back pain patients.^[3] In the treatment of facet joint pain, medical treatment and physiotherapy comprise the first step, and facet injection is involved in the second step of the treatment. The following injection techniques are applied to the facet joint: Injection around the facet joint (medial branch block), intra-articular injection, and neurotomy with radiofrequency are common.^[3,11,12]

The selection of the patients to be included in our study was

Table 3: The need for pain killer medication comparison of group A and group B in the course of the treatment

Pain Killer Needs	Group A		Group B		p	
	n	%	n	%		
Preop	Yes	5	10.6%	1	2.1%	0.091
	No	42	89.4%	46	97.9%	
3 Month	Yes	42	89.4%	13	28.3%	0.000
	No	5	10.6%*	33	71.7%*	
6 Month	Yes	24	61.5%	2	5.0%	0.000
	No	15	38.5%*	38	95.0%	

Chi square test / MC Nemar test, *Intra-group comparison $P < 0,05$

made by experienced spinal surgeons. All patients were given lumbar AP and lateral (LAT) radiography and lumbar MRI. The patients who had scoliosis received stand-up AP and LAT scoliosis radiography.

The patients who had at least one condition such as balance defect in the sagittal and coronal plane (CSVL >5 cm), central stenosis ($>50\%$ central or foraminal stenosis), complaints of pain spreading from the lower back to leg or numbing or more prevalent paraesthesia, body mass index >35 , and uncontrolled diabetes were excluded from the study.

After the exclusion of other diseases that might be the cause of low-back pain, facet joint injection treatment was suggested to the patients who were unresponsive to the medication therapy. The patients were given facet joint injection periarticularly under the control of fluoroscopy device.

Postinjection VAS and ODI scores of group A, at the end of third, sixth, and twelfth month followup, were found to be significantly lower than the preinjection levels. Although the decrease of VAS and ODI scores of group B at the end of the third and sixth months were less than those of group A, but they were still found to be statistically significant from the preinjection levels ($P < 0.05$).

The decline in the need of pain medication and overall affirmative answers for the question of repeating the treatment if the pain reoccurs indicated that the treatment yielded much more successful results in patients without an accompanying condition. When selecting patients, these points must be considered.

There are studies that applied facet injection intra-articularly and pericapsularly, and it was reported that the end results were no different. We applied the pericapsular injection technique because it is technically easier and less time-consuming compared to other methods.^[2,13]

The ultrasound-assisted injection technique was introduced much earlier, and it has the advantage of being radiation free. However, difficulties are involved in imaging due to the acoustical impedance of bones, and the method requires experienced users to achieve a reliable image.^[14] In our study, we used fluoroscopy, which is the most commonly used imaging device by orthopedic surgeons.

It is reported that facet injection was as effective as facet denervation at the first month. However, the effect of the injection treatment decreased at the end of the third month.^[10] Due to the patient satisfaction in group A patients, we reached the conclusion that the facet joint injection has continued effects until the end of the twelfth month.

The reason for the unsuccessful treatment in the patients with multiple conditions is not fully understood^[15] In our study, the patients who comprised the second group did not experience successful results after applying the facet injection unlike the patients who comprised the first group. This leads us to the

conclusion that the presence of major pathologies in addition to facet joint arthritis reduces the affectivity of the treatment.

In our patients, the facet injection sustained its effects up to the twelfth month for group A, whereas for group B its effect was found on a medium level at the third and sixth month, but was not effective at the twelfth month. In our opinion, the difference between two groups in terms of the effectiveness of the injection and patient satisfaction was influenced by comorbidities to the facet joint arthritis.

Finally, we deduced that it is crucial to be more careful about choosing patients to increase the effectiveness of facet injection.

CONCLUSION

Among various types of low-back pains, facet joint-originated pain is quite common. Facet joint hypertrophy might often be accompanied by other pathologies. Our analysis showed that even in these situations, the local anesthetic and steroid injections applied to the facet joint are effective treatment options in the short and medium terms. To maximize the effect of the treatment, the selection of the patient is a crucial step. By repeating the process every 6-12 months under operating room conditions, our opinion is that the patients were spared from risky surgical procedures.

Financial support and sponsorship

Nil.

Conflicts of interest

There are no conflicts of interest.

REFERENCES

- Peh W. Image-guided facet joint injection. *Biomed Imaging Interv J* 2011;7:e4.
- Karavelloğlu E, Kokulu S, Eser O. Lomber faset eklem sendromunda enjeksiyon tedavisinin etkinliği: Klinik çalışma efficacy of injection therapy at lumbar facet joint syndrome: Clinical study. *J Turkish Spinal Surg* 2012;23.
- Ali Haluk Düzkalır, Selçuk Özdoğan 2nd. Radyofrekans termokoagülasyon ile faset eklem denervasyonu. *J Turkish Spinal Surg* 2014;25:33-8.
- Boswell MV, Colson JD, Sehgal N, Dunbar EE, Epter R. A systematic review of therapeutic facet joint interventions in chronic spinal pain. *Pain Physician* 2007;10:429-53.
- Bykowski JL, Wong WH. Role of facet joints in spine pain and image-guided treatment: A review. *AJNR Am J Neuroradiol* 2012;33:1419-26.
- Manchikanti L, Manchikanti KN, Manchukonda R, Cash KA, Damron KS, Pampati V, et al. Evaluation of lumbar facet joint nerve blocks in the management of chronic low back pain: Preliminary report of a randomized, double-blind controlled trial: Clinical Trial NCT00355914. *Pain Physician* 2007;10:425-40.
- Bykowski JL, Wong WH. Role of facet joints in spine pain and image-guided treatment: A review. *AJNR Am J Neuroradiol* 2012;33:1419-26.
- van Tulder MV, Koes B, Seitsalo S, Malmivaara A. Outcome of invasive treatment modalities on back pain and sciatica: An evidence-based review. *Eur spine J* 2006;15(Suppl 1):S82-92.
- Destouet JM, Gilula LA, Murphy WA, Monsees B. Systematic assessment of diagnostic accuracy and therapeutic utility of lumbar facet joint interventions. *Radiology* 1892;145:321-5.
- Selçuk Özdoğan, Ali Haluk Düzkalır 2nd. Kronik bel ağrısı tedavisinde faset eklem denervasyonu ile faset enjeksiyonunun karşılaştırılması. *J Turkish Spinal Surg* 2013;24 219-22.
- Civelek E, Cansever T, Kabatas S, Kircelli A, Yılmaz C, Musluman M, et al. Comparison of effectiveness of facet joint injection and radiofrequency denervation in chronic low back pain. *Turk Neurosurg* 2012;22:200-6.
- Manchikanti L, Abdi S, Atluri S, Benyamin RM, Boswell MV, Buenaventura RM, et al. An update of comprehensive evidence-based guidelines for interventional techniques in chronic spinal pain. Part II: Guidance and recommendations. *Pain Physician* 2013;16(Suppl):S49-283.
- Sehgal N, Dunbar EE, Shah RV, Colson J. Systematic review of diagnostic utility of facet (zygapophysial) joint injections in chronic spinal pain: An update. *Pain Physician* 2007;10:213-28.
- Kim D, Choi D, Kim C, Kim J, Choi Y. Transverse process and needles of medial branch block to facet joint as landmarks for ultrasound-guided selective nerve root block. *Clin Orthop Surg* 2013;5:44-8.
- Van Boxem K, Cahana A, Van Zundert J. Injection therapy and denervation procedures for chronic low back pain: A systematic review — Clinical value? *Eur spine J* 2011;20:820-3.