

## Periventricular leukomalacia in a neonatal calf

Kenji KOYAMA<sup>1</sup>, Riku FUJITA<sup>1</sup>, Masaki MAEZAWA<sup>2</sup>, Natsuko FUKUMOTO<sup>3</sup>, Noriyuki HORIUCHI<sup>1</sup>, Hisashi INOKUMA<sup>2</sup> and Yoshiyasu KOBAYASHI<sup>1</sup>\*

<sup>1</sup>Laboratory of Veterinary Pathology, Department of Basic Veterinary Medicine, Obihiro University of Agriculture and Veterinary Medicine, Nishi 2-11, Inada-cho, Obihiro, Hokkaido 080-8555, Japan

<sup>2</sup>Laboratory of Veterinary Internal Medicine, Department of Clinical Veterinary Medicine, Obihiro University of Agriculture and Veterinary Medicine, Nishi 2-11, Inada-cho, Obihiro, Hokkaido 080-8555, Japan

<sup>3</sup>National Livestock Breeding Center, Tokachi Station, Komabanamiki 8-1, Otofuke, Hokkaido 080-0572, Japan

(Received 21 January 2016/Accepted 2 March 2016/Published online in J-STAGE 24 March 2016)

**ABSTRACT.** A 10-day-old, Japanese Black, female calf had shown astasia since just after birth. Focal symmetrical periventricular malacic lesions of the cerebrum and suppurative arthritis of the left hip joint were observed in macroscopic examination. Histologically, the cerebral lesions were confirmed as periventricular leukomalacia (PVL). The location and histological features of the lesions were similar to PVL in humans, caused by neonatal ischemia/hypovolemia. This is the first report of PVL in a neonatal calf.

**KEY WORDS:** ischemia, neonatal calf, periventricular leukomalacia

doi: 10.1292/jvms.16-0034; *J. Vet. Med. Sci.* 78(7): 1175–1177, 2016

In humans, periventricular leukomalacia (PVL) is a cerebral white matter injury due to ischemia/hypovolemia experienced during the prenatal period and is most often observed in premature infants [5, 6]. Histologically, the lesions are recognized as focal leukomalacia in the periventricular area with bilateral and symmetrical distribution.

PVL has been reported in pups and lambs in the veterinary literature [2, 10, 11]. Therefore, sheep are utilized as an experimental animal model for PVL pathogenesis studies for humans [1, 8, 9, 12]. However, to the best of our knowledge, there has been no reported case of PVL in calves. In the present study, we described the clinical and pathologic characteristics of PVL observed in a calf. Furthermore, in a study of possible etiological factors, congenital bovine viral diarrhoea virus (BVDV) and *Neospora caninum* infections were investigated for their association with PVL.

A 10-day-old, Japanese black, female calf had shown astasia since just after birth. The calf was delivered tail-first with human assistance at 289 gestational days and was the first calf of the dam. Birth weight of the calf was 27 kg, and the value was within the normal range of Japanese black neonatal calves. There was no obvious increase in the number of abortion and stillbirth in the herd. At postnatal day (PD) 8, despite the ability to stand up by herself, the calf showed dysfunction of the left hind limb. At PD 11, the calf was euthanized under deep barbiturate anesthesia due to poor prognosis. The clinical and pathological examination procedures were approved by the Animal Care and Use Committee of

Obihiro University of Agriculture and Veterinary Medicine.

At necropsy, suppurative arthritis of the left hip joint, and ulceration and peri-arthritis of the left knee were the only notable findings. Tissue samples of the central nervous system and representative tissues were collected and fixed in 15% neutral-buffered formalin. At brain cutting, focal bilateral and mostly symmetrically distributed whitish demarcated lesions were detected in the cerebral periventricular area (Fig. 1A). These lesions were prominent in the dorsolateral and rostral areas around the lateral ventricle and were mild in the caudal area (Supplementary Fig. 1).

Fixed samples were trimmed, embedded in paraffin and cut into 3- $\mu$ m thick sections. Paraffin sections were stained with hematoxylin and eosin (HE), and selected sections were stained with Luxol fast blue-HE or subjected to immunohistochemical stainings. The immunohistochemical examinations were performed using a simple stain MAX-PO polymer reagent (Nichirei Bio-science, Tokyo, Japan). The following primary antibodies were used: polyclonal anti-gial fibrillary acidic protein (GFAP) (dilution 1 in 500; Dakocytomation, Tokyo, Japan), monoclonal anti-vimentin (dilution 1 in 200; Dakocytomation), monoclonal anti-Iba1 (dilution 1 in 500; Wako Pure Chemical Industries, Osaka, Japan) and polyclonal anti-*Neospora caninum* (dilution 1 in 2,500; VMRD, Pullman, WA, U.S.A.). For antigen retrieval, microwave antigen retrieval (15 min in 0.01 M citrate buffer, pH 6.0) was performed for staining against vimentin, Iba1 and *Neospora caninum*, and enzymatic predigestion (30 min at 37°C with 0.1% trypsin) was performed for staining against GFAP.

Histologically, the periventricular lesions of the cerebrum were identified as well-demarcated focal leukomalacia (Fig. 1B). In the necrotic foci, there were severe accumulations of gitter cells, vascularization with swelling of vascular endothelial cells. Numerous spheroids were found in and around the necrotic foci. A few spheroids were also seen in

\*CORRESPONDENCE TO: KOBAYASHI, Y., Obihiro University of Agriculture and Veterinary Medicine, Nishi 2-11, Inada-cho, Obihiro, Hokkaido 080-8555, Japan. e-mail: kyoshi@obihiro.ac.jp

©2016 The Japanese Society of Veterinary Science

This is an open-access article distributed under the terms of the Creative Commons Attribution Non-Commercial No Derivatives (by-nc-nd) License <http://creativecommons.org/licenses/by-nc-nd/4.0/>.

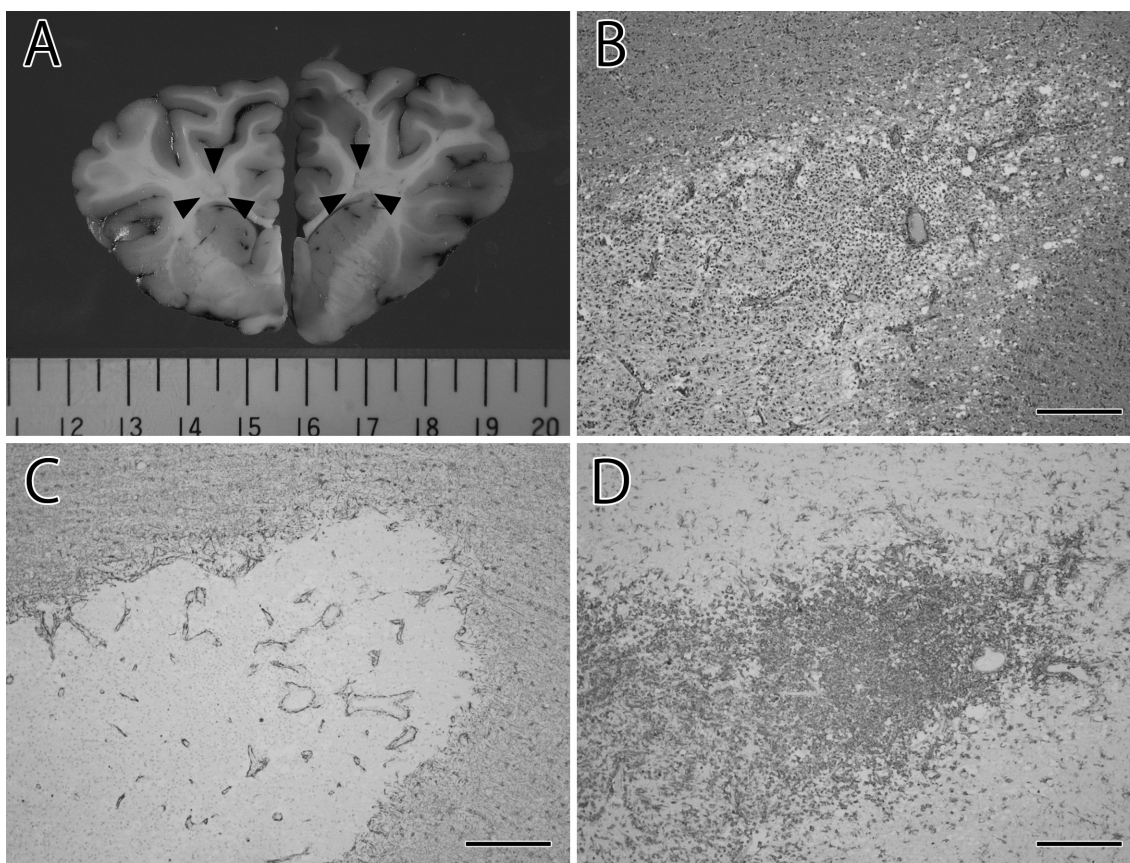


Fig. 1. (A) Focal, symmetric periventricular lesions located in the deep cerebral white matter (surrounded by arrowheads). (B) Photomicrograph of the periventricular white matter lesion at the level of the corpus striatum. Note the well-demarcated necrotic lesion filled with macrophages/microglia, with prominent vascularization. HE. Bar=300  $\mu$ m. (C) Mild proliferation of fibrillary astrocytes around the foci, but few within the foci. IHC. Bar=300  $\mu$ m. (D) Numerous Iba1-positive macrophages/microglia within the necrotic focus. IHC. Bar=300  $\mu$ m.

the internal capsules. Luxol fast blue-HE staining sections revealed marked loss of myelin in the foci (Supplementary Fig. 2). Some myelin debris were found in the cytoplasm of the gitter cells. There was no myelin hypoplasia in any other area of the cerebral white matter. Immunostaining against GFAP and vimentin revealed mild proliferation of fibrillary astrocytes around the foci, but few within the foci (Fig. 1C). Iba1 immunohistochemistry revealed that almost all accumulated cells in the foci were macrophages/microglia. Furthermore, diffuse infiltration of microglia was also widely observed in the cerebral white matter around the foci (Fig. 1D). For investigation of possible etiological factors, *Neospora* immunohistochemistry showed no positive staining structures in the cerebrum.

We also examined whether persistent infection of BVDV was associated with the present disease condition. The single tube RT-PCR method was used to detect BVDV genetic material according to a previous report [14], and the present calf was shown to be free from persistent BVDV infection.

Pathologic characteristics of the present case included the presence of periventricular necrotic foci that were distributed

in a bilateral symmetrical pattern. Focal necrosis within this region has never been reported in calves. The location and histological features of the lesions were similar to those of PVL in humans and lambs [4, 9]. With aggregation of macrophages/microglia and vascularization within the necrotic foci, we believe that the cerebral lesions in the present case were older lesions. Furthermore, the present case did not show astrocytic reactivity, which is known to not be present in premature brain damage [13]. These findings suggest that the brain injury of the present case occurred during the prenatal period.

PVL is a well-studied diseased state in humans and has also been reported in lambs [5, 10]. However, there have been no reports of PVL in calves. The cause of human and ovine PVL is ischemia/hypovolemia [5, 6] due to the following two factors: 1) the periventricular area is distant from the blood supply and is vulnerable due to the premature cerebral arteries of the infant, and 2) insufficient cerebral blood supply to the cerebrum during infancy [4, 5]. In cattle, the main sources of the cerebral blood supply to the periventricular area are the rostral cerebral artery and middle cerebral artery,

similar to humans [3]. In the present case, the lesions were distributed throughout the periventricular area bilaterally, known to be distant from the blood supply in humans, suggesting ischemia/hypovolemia during the prenatal period as the cause.

In lambs, PVL has been reported in association with placentitis due to toxoplasmosis, tick-borne fever and chlamydiosis [2, 10]. In the present case, there were no lesions suggestive of fetal infections of these pathogens. In addition, there was no increase in the number of abortion and stillborn in the herd. Therefore, these infections were thought to be less likely to be involved in the pathogenesis of the present disease condition. However, we could not completely exclude the possibility, because the pathological examination of the placenta was not performed.

Motor impairment, such as cerebral palsy, is the most common clinical sequela of PVL in humans, although patients with PVL on magnetic resonance imaging do not always show motor impairment [5, 15]. Injury of the corticospinal tract within the periventricular white matter may underlie the motor impairment [7]. In the present case, dysfunction of the hind limb was severe on the arthritic side. Thus, the main cause of hind limb dysfunction may have been due to the suppurative arthritis of the hip joint, and PVL may have been associated with no or slight symptoms. The lack of clinical signs may be one reason why there have been no reported cases of PVL in calves.

In conclusion, to the best of our knowledge, this is the first report of PVL in a neonatal calf. To clarify the clinical significance and prevalence of such lesions in calves, further studies are warranted.

**ACKNOWLEDGMENT.** This work was supported in part by a Grant-in-Aid for Scientific Research (no. 25450420) from the Japan Society for the Promotion of Science (JSPS).

## REFERENCES

1. Castaño, P., Fuertes, M., Ferre, I., Fernández, M., Ferreras, M. C., Moreno-Gonzalo, J., González-Lanza, C., Katzer, F., Regidor-Cerrillo, J., Ortega-Mora, L. M., Pérez, V. and Benavides, J. 2014. Placental thrombosis in acute phase abortions during experimental *Toxoplasma gondii* infection in sheep. *Vet. Res.* **45**: 9. [Medline] [CrossRef]
2. Chianini, F., Adams, C. and Buxton, D. 2004. Neuropathological changes in ovine fetuse caused by tickborne fever. *Vet. Rec.* **155**: 805–806. [Medline]
3. Ghoshal, N. G., Nanda, B. S. and Habel, R. E. 1975. Ruminant Heart and Arteries. pp. 960–1023. In: Sisson and Grossman's The Anatomy of the Domestic Animals, 5th ed. (Getty, R. ed.), W. B. Saunders Company, Philadelphia.
4. Khwaja, O. and Volpe, J. J. 2008. Pathogenesis of cerebral white matter injury of prematurity. *Arch. Dis. Child. Fetal Neonatal Ed.* **93**: F153–F161. [Medline] [CrossRef]
5. Kinney, H. C. 2006. The near-term (late preterm) human brain and risk for periventricular leukomalacia: a review. *Semin. Perinatol.* **30**: 81–88. [Medline] [CrossRef]
6. Kuban, K. C. and Leviton, A. 1994. Cerebral palsy. *N. Engl. J. Med.* **330**: 188–195. [Medline] [CrossRef]
7. Lee, J. D., Park, H. J., Park, E. S., Oh, M. K., Park, B., Rha, D. W., Cho, S. R., Kim, E. Y., Park, J. Y., Kim, C. H., Kim, D. G. and Park, C. I. 2011. Motor pathway injury in patients with periventricular leukomalacia and spastic diplegia. *Brain* **134**: 1199–1210. [Medline] [CrossRef]
8. Marumo, G., Kozuma, S., Ohyu, J., Hamai, Y., Machida, Y., Kobayashi, K., Ryo, E., Unno, N., Fujii, T., Baba, K., Okai, T., Takashima, S. and Taketani, Y. 2001. Generation of periventricular leukomalacia by repeated umbilical cord occlusion in near-term fetal sheep and its possible pathogenetical mechanisms. *Biol. Neonate* **79**: 39–45. [Medline] [CrossRef]
9. Matsuda, T., Okuyama, K., Cho, K., Hoshi, N., Matsumoto, Y., Kobayashi, Y. and Fujimoto, S. 1999. Induction of antenatal periventricular leukomalacia by hemorrhagic hypotension in the chronically instrumented fetal sheep. *Am. J. Obstet. Gynecol.* **181**: 725–730. [Medline] [CrossRef]
10. Maxie, M. G. and Youssef, S. 2007. Nervous system. pp. 281–457. In: Pathology of Domestic Animals, Vol. 1, 5th ed. (Maxie, M.G. ed.), Elsevier Saunders, London.
11. Rentmeister, K., Schmidbauer, S., Hewicker-Trautwein, M. and Tipold, A. 2004. Periventricular and subcortical leukoencephalopathy in two dachshund puppies. *J. Vet. Med. Ser. A Physiol. Pathol. Clin. Med.* **51**: 327–331. [Medline] [CrossRef]
12. Saito, M., Matsuda, T., Okuyama, K., Kobayashi, Y., Kitanishi, R., Hanita, T. and Okamura, K. 2009. Effect of intrauterine inflammation on fetal cerebral hemodynamics and white-matter injury in chronically instrumented fetal sheep. *Am. J. Obstet. Gynecol.* **200**: 663.e1–663.e11. [Medline] [CrossRef]
13. Schwartz, E. S. and Barkovich, A. J. 2012. Brain and Spine Injuries in Infancy and Childhood. pp. 240–366. In: Pediatric Neuroimaging, 5th ed. (Barkovich, A.J. and Raybaud, C. eds.), Wolters Kluwer Health/Lippincott Williams and Wilkins, Philadelphia.
14. Weinstock, D., Bhudevi, B. and Castro, A. E. 2001. Single-tube single-enzyme reverse transcriptase PCR assay for detection of bovine viral diarrhea virus in pooled bovine serum. *J. Clin. Microbiol.* **39**: 343–346. [Medline] [CrossRef]
15. Woodward, L. J., Anderson, P. J., Austin, N. C., Howard, K. and Inder, T. E. 2006. Neonatal MRI to predict neurodevelopmental outcomes in preterm infants. *N. Engl. J. Med.* **355**: 685–694. [Medline] [CrossRef]