

# Six-Year Prospective Outcomes of Primary Breast Augmentation With Nano Surface Implants

Manuel Chacón Quirós, MD; Manuel Chacón Bolaños, MD; and Jeffry James Fassero, MD

Aesthetic Surgery Journal  
2019, Vol 39(5) 495–508  
© 2018 The American Society for  
Aesthetic Plastic Surgery, Inc.  
This is an Open Access article  
distributed under the terms of the  
Creative Commons Attribution-  
NonCommercial-NoDerivs licence  
(<http://creativecommons.org/licenses/by-nc-nd/4.0/>), which permits  
non-commercial reproduction and  
distribution of the work, in any  
medium, provided the original  
work is not altered or transformed  
in any way, and that the work is  
properly cited. For commercial  
re-use, please contact journals.  
permissions@oup.com  
DOI: 10.1093/asj/sjy196  
[www.aestheticsurgeryjournal.com](http://www.aestheticsurgeryjournal.com)

OXFORD  
UNIVERSITY PRESS

## Abstract

**Background:** Motiva Implants (Establishment Labs Holdings Inc.) are a novel family of silicone breast implants using cutting-edge technologies engineered to optimize aesthetic and safety outcomes.

**Objectives:** The authors sought to prospectively evaluate the safety and effectiveness of SmoothSilk/SilkSurface Motiva Implants over long-term follow-up.

**Methods:** Surgeons at a single plastic surgery center undertook a 10-year follow-up study of SmoothSilk/SilkSurface Motiva Implants in women who underwent primary breast augmentation. Safety was assessed through identification of complications on follow-up and through magnetic resonance imaging (MRI) in a representative sample. Effectiveness outcomes were assessed by surgeons and patients using Likert scales and a Quality of Life tool.

**Results:** This article reports the 6-year safety and effectiveness outcomes. A total of 35 patients were implanted between September and December 2010, and 71.9% of implants were placed submuscularly using inframammary incision. During the 6-year follow-up, there were no occurrences of capsular contracture, rupture, double capsules, or late seroma. MRI evaluation identified no signs of implant-related complications. Three revision surgeries were performed, all for aesthetic reasons; there were no implant replacements for medical reasons. The level of satisfaction for both patients and surgeons was high at all follow-up visits. Patient quality-of-life scores increased following breast augmentation by an average of 0.89% at 72 months.

**Conclusions:** The results of this prospective long-term follow-up study demonstrate the excellent safety and effectiveness of SmoothSilk/SilkSurface Motiva Implants in primary breast augmentation through 6 years of follow-up.

## Level of Evidence: 4

Editorial Decision date: May 30, 2018; online publish-ahead-of-print November 13, 2018.



More than 310,000 breast augmentation surgeries were performed in the United States in 2016, making it the most commonly performed cosmetic surgical procedure.<sup>1</sup> Silicone breast implants were used in 87% of those augmentation procedures.<sup>1</sup>

Silicone gel-filled breast implants have been commercially available for decades but were not approved by the FDA until 2006 for use in all women over the age of 21. Since their inception, silicone breast implants have evolved significantly to improve safety and aesthetic outcomes. Indeed, the use of breast implants is associated with a variety of potential complications, such as hematoma, seroma,

infection, altered sensation, rupture, leakage, and capsular contracture.<sup>2</sup> Poor aesthetic outcomes, such as asymmetry, rippling, double capsules, rotation, and malposition can also occur and may require reoperation and possibly implant replacement to optimize cosmesis.<sup>3</sup>

Drs Chacón Quirós and Chacón Bolaños are plastic surgeons and Dr Fassero is an anesthesiologist in private practice in San Jose, Costa Rica.

### Corresponding Author:

Dr Manuel Chacón Quirós, European Center of Surgery, 3rd Avenue, Sabana, San José 10108, Costa Rica.

E-mail: [drmanuelchaconquiros@gmail.com](mailto:drmanuelchaconquiros@gmail.com)

Technical developments designed to reduce these risks include procedural and device-related innovations. For example, newer generations of silicone implants often use cohesive or form-stable silicone gels to limit the risk of leakage and surfaces designed to improve biocompatibility. Differences in the design and manufacture of available silicone breast implants can significantly affect safety and aesthetic outcomes.

Motiva Implants (Establishment Labs Holdings Inc., NY) represent a novel family of breast implants that incorporates a variety of cutting-edge technologies engineered to optimize aesthetic and safety outcomes while providing patients and surgeons with a diverse range of implant choices. These implants are form-stable, silicone-filled devices with a unique surface designed to minimize reaction with host tissues. Rheological features of the silicone gels used in Motiva implants provide patients and surgeons with multiple options to promote specific aesthetic outcomes.

To evaluate the safety and effectiveness of SmoothSilk/SilkSurface Motiva Implants, surgeons at a single plastic surgery center undertook a prospective 10-year follow-up study in women who underwent primary breast augmentation. This article reports the 6-year safety and effectiveness outcomes of this ongoing study.

## METHODS

This report presents the 6-year outcomes from an ongoing, prospective, 10-year follow-up study to confirm the safety and effectiveness of Motiva Implants silicone breast implants in patients who underwent breast augmentation surgery between September and December 2010.

Thirty-five patients were operated on for mammary hypotrophy and hypotrophy plus ptosis grade I or II and implanted with SmoothSilk/SilkSurface Motiva Implants.

The study was conducted at a single private plastic surgery center, accredited by the American Association for Accreditation of Surgery Facilities, by board-certified Plastic and Reconstructive Surgeons trained at the University of Paris. Written informed consent was obtained from all subjects following the principles of the Helsinki declaration. All patients were informed about their options to refuse to participate or to choose a different device, and they all accepted to be part of this single arm study.

## Implants Studied

Per protocol, the implants used in this study were Motiva Implants. These devices are gel-filled, form-stable silicone breast implants with a unique surface architecture. The implants used in this study were SmoothSilk/SilkSurface. These implants are available in a range of sizes, base diameters, and projections. The manufacturer also offers

an optional feature consisting of a Radio Frequency Identification Device embedded in the implant that was not available when this study was designed. Therefore, all patients were implanted with devices without the Radio Frequency Identification Device technology.

Unlike textured silicone breast implants, which are produced with a secondary process that uses crystals or polyurethane foam to create surface texture, the surface of Motiva Implants is manufactured using 3-dimensional (3D) inverted negative imprinting technology directly on the mandrel. Another surface that is not manufactured with salt crystals is found in the Siltex textured implants (Mentor Corporation, Santa Barbara, CA) in which the silicone is imprinted in a secondary process by pressing a polyurethane foam prior to curing, creating a negative contact stamp that produces a nodular surface of varying depths and widths and a greater amount of surface area for cellular ingrowth.<sup>4</sup> What makes SmoothSilk/SilkSurface unique is the controlled dimensions of its architecture based on very low statistical roughness and the presence of cell size features in the topography of the implant that reduce the movement and proliferation of ingrowth breast tissue.<sup>5</sup>

This implant has an average of 49,000 contact points per cm<sup>2</sup> with a roughness of 3600 nanometers  $\pm$  400 nm, measured by means of a noncontact profilometer ( $\mu$ surf Mobile profilometer (Nanofocus, Oberhausen, Germany), an instrument that traces the surface topography and quantifies the roughness using the optical light interference principles, defining it as an exceptional surface with roughness at a subcellular level where tissue ingrowth is not possible.<sup>5</sup> According to ISO 14607:2018, SmoothSilk/SilkSurface is considered a smooth surface.<sup>6</sup>

## Patients

Study patients were healthy women aged 18 years or older who presented themselves for aesthetic primary breast augmentation.

## Inclusion Criteria

Females 18 years of age or older with an appropriate health condition for breast augmentation and adequate tissue available to cover the implants, which has been used as an inclusion criterion for other device studies as stated by Bengston et al (2007) in the Style 410 Highly Cohesive Silicone Breast Implant Core Study,<sup>7</sup> were included. These women were asked to complete the screening visits and sign the informed consent form, which gives information about the breast implants and confirms the patient commitment to follow this evaluation's requirements and acceptance of the potential risks involved, according to the Declaration of Helsinki's guidelines.

Patients were requested to have a magnetic resonance imaging (MRI) procedure performed immediately prior to explantation, if medically advisable.

### Exclusion Criteria

Women with advanced fibrocystic disease considered to be premalignant without accompanying subcutaneous mastectomy were excluded from the study. Other conditions such as existing carcinoma of the breast (without mastectomy), abscess or infection at the time of enrollment, pregnancy or currently breast-feeding, having a disease clinically known to impact wound healing ability including uncontrolled diabetes, tissue damage resulting from radiation, compromised vascularity, or ulceration were also considered as exclusion criteria. Any condition or treatment that may constitute an unjustifiable surgical risk (eg, unstable cardiac or pulmonary problems) and manifestation of psychological issues such as inappropriate attitude or motivation (eg, body dysmorphic disorder) was also considered an exclusion criterion.

### Procedures

Per protocol, all patients were primary augmentation cases with no breast reconstruction cases. Indications for augmentation were mammary hypotrophy or hypotrophy plus ptosis grade I or II.

Incision site (inframammary, periareolar, transaxillary, T mastopexy) and site of implant placement (submuscular, subfascial, subglandular, dual plane) were selected by the treating surgeons based on patient characteristics and preferences. In consultation with the treating surgeons, implant size, projection, and base diameter were selected to satisfy the patient's desired aesthetic outcomes.

The day before the procedure the patient received a prophylactic antibiotic. All procedures were performed utilizing general anesthesia. Once on the operatory table, the patient's thorax was prepped with Povidone-iodine solution, which was allowed to dry by itself. The zone where the incision was to be performed was properly marked and infiltrated with 2% lidocaine plus epinephrine to minimize bleeding.

Before placing the implant inside the breast pocket, it was checked and cleaned with saline solution in its original package to remove the static, trying to limit its manipulation as much as possible.

The implant information was written in the study's logbook and the traceability stickers adhered to it. Once the implants were introduced in the surgical pocket, the surgeon checked their position and symmetry and closed the surgical wound in 3 planes: fascia, subcutaneous tissue, and cutaneous plane. In case of submuscular placement of the implants, when the subcutaneous plane was almost closed, a catheter was placed at the distal corner of the incision and bupivacaine hydrochloride (25 mg) was injected periprosthetically to reduce postoperative pain. Immediately before the cutaneous plane was closed, the surgeon excised the contusion strip (about 2 mm) to improve the approximation of the incision borders and enhance the appearance of the future scar.

**Table 1.** Characteristics of Patients, Implants, and Follow-Up in the Treatment Group

Characteristics	Treatment group (N = 35)
Mean age, years (range)	31.5 (21-51)
Mean weight, kg (range)	55.8 (42.5-64)
Mean BMI (range)	21.9 (17.9-25)
Current smoker, N (%)	4 (11.42%)
Implant type	SilkSurface/SmoothSilk (100%)
Incision site (N = 35)	Inframammary (97.15%) Transaxillary (2.85%)
Implant placement (N = 35)	Submuscular (68.59%) Subglandular (14.28%) Subfascial (14.28%) Dual plane (2.85%)
Mean implant volume, cc (range)	326.70 (235-400)
Length of follow-up	6 years

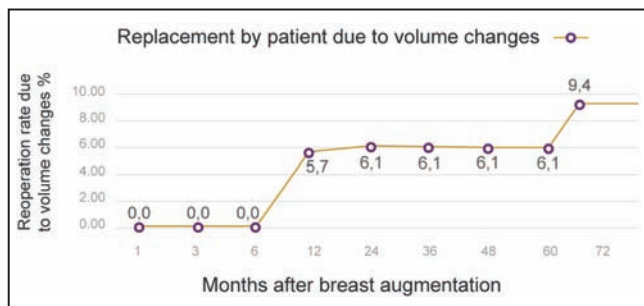
### Assessments

Patient follow-up evaluation was performed postoperatively at 24 hours, 4 days, 2 weeks, and 1, 3, 6, 12, 24, 36, 48, 60, and 72 months and will continue annually through 10 years.

Safety was assessed by the presence of complications, including seroma, infection, hematoma, edema, erythema, inflammatory signs, scarring, calcification, granuloma, stretch marks, pruritus, or suture dehiscence. Assessment for implant-related complications included implant exposure, malposition, rupture, asymmetry, rippling, capsular contracture, or double capsules. Patient-reported breast pain and nipple sensitivity were also assessed. Safety was also assessed through MRI studies performed in a representative sample of the population (62% of patients) with a 1.5 Tesla MR system (Software Philips Achieva: Release 2.1 Level 5 2010-02-20).

The MRI sample was planned to include >50% of participants to acquire important imaging findings. All patients who underwent the procedure were contacted by the treating physician and asked if they were willing to receive an MRI evaluation. Follow-up appointments were scheduled to collect most of the data, and 62.5% was obtained between April 2016 and May 2017 at 5 years after the breast augmentation. Patients who did not want to participate in the MRI study had either a condition that impeded the use of MRI, including pregnancy and claustrophobia, or were unwilling to be subjected to the procedure. It is important to note that the regulatory agencies regularly require MRI studies on a small sample of the study population.

Both surgeon and patient assessed effectiveness outcomes. Satisfaction with aesthetic results was evaluated



**Figure 1.** The Kaplan-Meier risk rate for implant replacement due to volume changes through 6 years (N = 35).

by both surgeon and patient by means of Likert scales as shown in Appendix A and Appendix B, available online at [www.aestheticsurgeryjournal.com](http://www.aestheticsurgeryjournal.com). The surgeon's level of satisfaction with the augmentation procedure was measured on a 5-point Likert scale (1 highest, 5 lowest); the patient's satisfaction was based on 6-point Likert scale (1 highest, 6 lowest). Patient quality of life was assessed using a Quality of Life (QoL) tool shown in Appendix C (available online at [www.aestheticsurgeryjournal.com](http://www.aestheticsurgeryjournal.com)). The QoL measures were a combination of the Rosenberg Self Esteem Scale, the Body Esteem Scale, the Tennessee Self Concept Scale, and the SF-36. Data were collected from the identified patients before implantation and at all scheduled follow-up visits and then included in their medical record.

## Statistical Analysis

Self-esteem/QoL scores were compared between baseline and follow-up time points utilizing simple linear regression. Kaplan-Meier survival rates were calculated for implant-related outcomes, such as implant rupture, capsular contracture, and implant replacement. Satisfaction scores were analyzed using descriptive statistics, and statistical significance was defined as  $P < .05$ .

## RESULTS

The mean age of the 35 patients was 31.5 years old (range, 21-51 years) and mean body mass index was 21.9 kg/m<sup>2</sup> (range, 17.9-25.0 kg/m<sup>2</sup>). Demographic characteristics of study patients and the types and placement of implants are listed in Table 1.

Most patients requested a moderate augmentation, with an average cup size change of one cup. The estimated average implant size calculated by the surgeon through 3-D scanning prior to the surgery was 317 cc (range, 180-450 cc) and the actual average volume used was 326.7 cc. The most frequently used implant profile was the "Full" (3.5-6.1 cm), which is in the midrange projection compared to a market equivalent selected by the surgeon, in 74% of patients. The average implant base diameter was 11 cm.

**Table 2.** Kaplan-Meier Cumulative Complication Rates for 6 Years

Complication	Risk rates, %	95% CI
Breast implant-associated anaplastic large cell lymphoma	0	0
Capsular contracture	0	0
Late seroma	0	0
Loss of nipple sensation	68.6	53.4-83.7
Loss of volume	6.0	0-13.0
Nipple hypersensitivity	54.3	38.0-70.6
Pain	22.9	9.14-36.8
Ptosis	54.3	37.8-70.8
Replacement due to safety reasons	0	0
Replacement due to volume changes	9.4	0-17.7
Rupture	0	0
Twinges	20.0	6.9-33.1

Projections and volumes were chosen by the patient and the surgeon based on the patient's anatomy and desires and the surgeon's professional judgment.

No drains were used and no intraoperative complications were reported. No incidents of infection, hematoma, suture dehiscence, or implant exposure were reported during the perioperative, intraoperative, immediate, and postoperative periods.

Three revision surgeries were performed on 3 patients, one each at 3, 6, and 71 months after the initial augmentation procedure. The Kaplan-Meier risk rate for implant replacement due to volume changes was 9.4% through 6 years (Figure 1). The rate of implant replacement for safety reasons remains 0% through 6 years.

At 6 years, the Kaplan-Meier rate for capsular contracture, rupture, double capsules, and late seroma was 0% for the primary augmentations as well as for the reoperations. Table 2 shows the Kaplan-Meier cumulative complication rates through 6 years.

## Safety Outcomes

The safety outcomes of the 6-year follow-up evaluation are described in Appendix C. Because this is an ongoing study, it is noteworthy that 32 of 35 patients have attended the 72-month follow-up visit; 33 patients attended their 60-month follow-up and all 35 patients completed their 24-month follow-up.

One subject who underwent revision surgery for aesthetic reasons was lost to follow-up after 2 years. Among the 32 patients who did not receive revision surgery (Table 3), no cases of edema, bruising, erythema, inflammatory reaction, delayed wound healing, hematoma,



**Table 3.** Safety Outcomes

Duration of follow-up, years	6
Outcome (N = 32) <sup>a</sup>	Value N (%)
Changes in nipple sensitivity	3 (9.4%)
Implant rupture, capsular contracture, double capsules, late seroma, or ALCL	0 (0%)
Inadequate scarring	0 (0%)
Pain	2 (6.3%)
Pruritus	0 (0%)
Ptosis	17 (53.1%)
Reported loss of volume	0 (0%)
Symmastia	0 (0%)
Twinges	2 (6.3%)

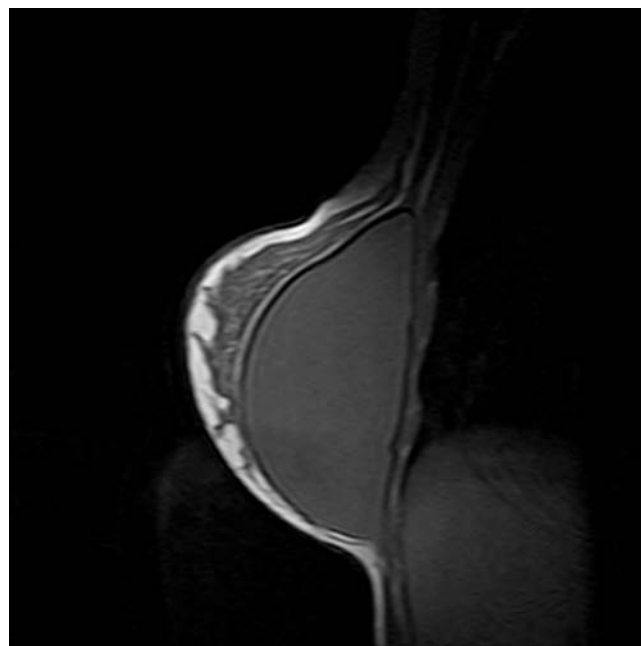
ALCL, anaplastic large cell lymphoma. <sup>a</sup>.

seroma, infection, calcification, granuloma, stretch marks, tightness, extrusion, necrosis, asymmetry, rippling, malposition, or irregular appearance were observed. No cases of rupture, capsular contracture, double capsules, late seromas, or anaplastic large cell lymphoma (ALCL) were reported at 6 years. The 6-year Kaplan-Meier risk rate for implant replacement due to volume changes is illustrated in [Figure 1](#).

### Revision Surgery Cases due to Volume Changes

A total of 3 revision surgeries were performed on 3 subjects. None of the revision surgeries was related to implant safety but rather to preferred aesthetic outcomes. One patient requested reoperation 3 months after the primary surgery to correct an aesthetic dissatisfaction related to larger than desired breast size. At 6 years, no adverse events were observed and the patient's reported level of satisfaction was "very satisfied."

The second reoperation patient was diagnosed with Grade II ptosis, and her satisfaction with the augmentation procedure decreased significantly from "extremely satisfied" at 3 months to "satisfied" at 6 months. A mastopexy with implant replacement was performed 6 months after the primary surgery. The patient reported satisfaction with the outcome at the 1-year and 2-year follow-up visits. Through 2 years, no adverse events were observed. This patient did not attend subsequent follow-up visits (ie, 3, 4, 5, or 6 years) and is the only one lost from the original group.



**Figure 2.** MRI of a 25-year-old female patient's left breast after primary breast augmentation done at 6 years postoperative showing no wrinkles and excellent outcome related with total filling of the implant.

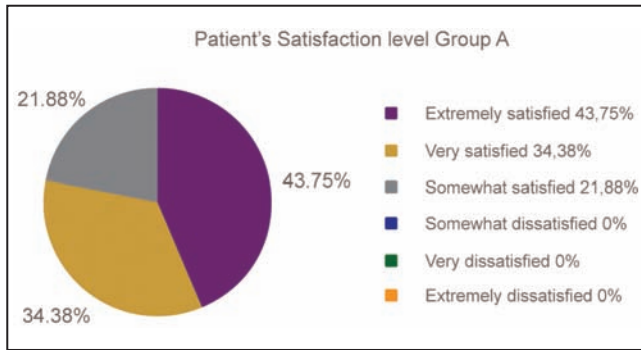
The third patient requested a reoperation 71 months after the primary surgery to replace her implants for a larger size. This patient and the first-mentioned reoperation cases continued to be monitored but were excluded from the study. In the 3 reoperation cases, histological analysis of the removed implants and pseudocapsules did not show signs of contracture or any other anomaly.

At year 6, 62.5% of patients (20 of the 32 who did not undergo revision surgery) included in the prospective, 10-year follow-up study had undergone MRI at 1.5 Tesla to assess the Motiva Implants safety. The MRI cohort showed excellent results ([Figure 2](#)), with no radiological signs suggesting intracapsular or extracapsular ruptures, capsular contractures Baker Grades III or IV, asymmetries, calcifications, hematomas, seromas, or any other implant-related complication. The overall rate of complications found in the MRI cohort was 0% for subjects and implants. By year 6, 100% of MRI cohort subjects still had an original implant in place. Given the size of the MRI group within each indication, pooling the results provides a more accurate estimate of the Motiva Implants safety and effectiveness.

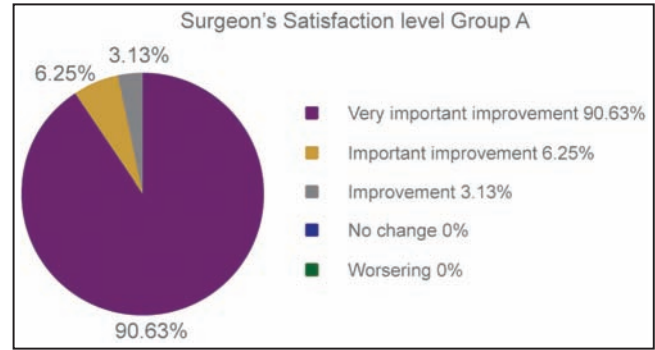
## Effectiveness Outcomes

### Patient and Surgeon Satisfaction

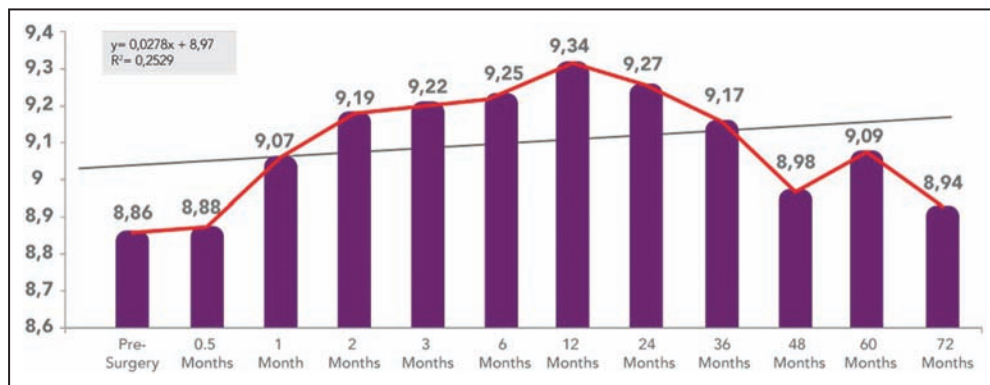
In general, the level of satisfaction for both patients and surgeons was high at all follow-up visits through 6 years. All



**Figure 3.** Patients' satisfaction level, 6 years after primary breast augmentation with Motiva Breast Implants (N = 32).



**Figure 4.** Surgeons' satisfaction level at 6 years after primary breast augmentation with Motiva Breast Implants (N = 32).



**Figure 5.** Average scores on the self-esteem and quality of life scales (from 1 to 10, with 1 lowest and 10 highest) before augmentation surgery and from 2 weeks to 72 months after the augmentation procedure (N = 32).

patients were at least “somewhat satisfied” to “extremely satisfied” with the aesthetic results (Figure 3). The mean patient satisfaction level was  $1.75 \pm 0.18$  with a 95% level of confidence, which means that the average value set of patient satisfaction with the aesthetic results provided by their surgical procedure was between 1 (extremely satisfied) and 2 (very satisfied).

The surgeons considered that patients made “very important improvement” in 90.6% of the cases, an “important improvement” in 6.3% of the cases, and an “improvement” in 3.1% of the cases utilizing Motiva Implants in the implanted population (Figure 4). In other words, an optimal result of the implantation was achieved in > 90% of the cases, and only 3 patients described their results as good or very good. The mean surgeon satisfaction level was  $1.25 \pm 0.42$ , with a 95% level of confidence; hence, the average value set of surgeon satisfaction with the aesthetic results in the implanted population was between 1 (very important improvement) and 2 (important improvement).

**Satisfaction Following Reoperations**

To date, satisfaction data are available for only 2 of the 3 reoperation cases. For these 2 cases, patients report being

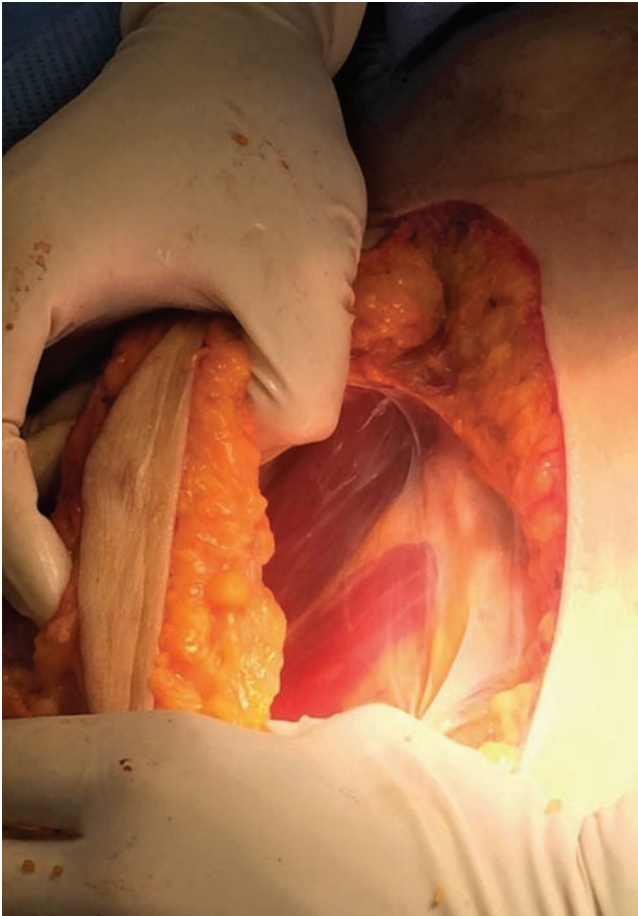at least “very satisfied” with the breast augmentation and surgeons considered that patients had made a “very important improvement.”

**Quality of Life and Self-Esteem**

Preoperatively, the patients' average score on the 9 self-esteem and QoL variables evaluated was 8.86 on a scale of 1 to 10 (with 1 being lowest and 10 highest). Average scores increased following breast augmentation (Figure 5). Overall, a 0.89% increase in self-esteem/QoL scores was observed 72 months after the implantation compared to baseline.

**DISCUSSION**

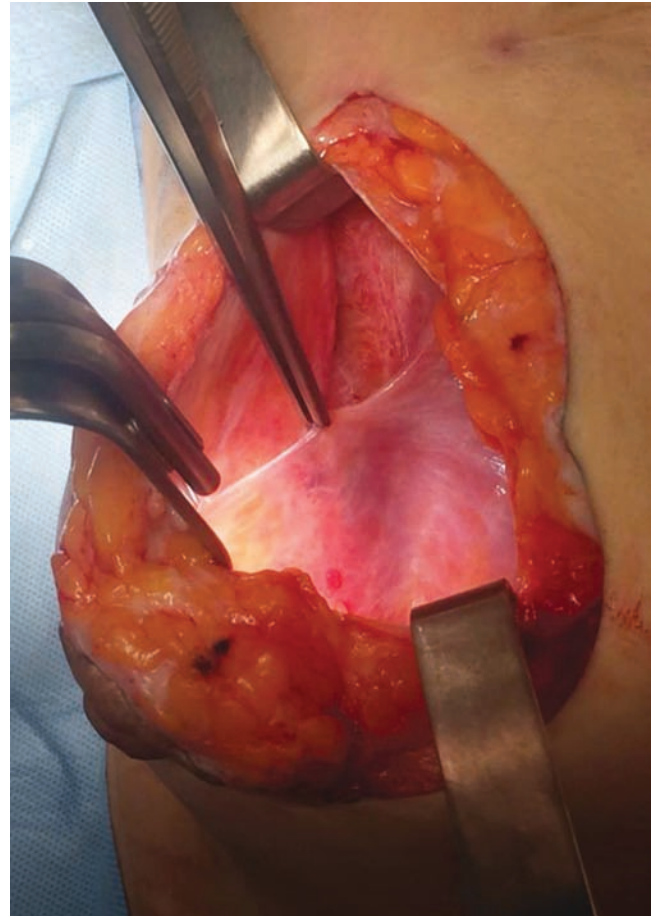
The results of this long-term, follow-up study demonstrate the safety and effectiveness of the Motiva silicone breast implants in primary breast augmentation through 6 years of follow-up and are also because of consciously following the best surgical practices. There were no serious adverse events and no cases of implant rupture, capsular contracture, double capsules, rotation, late seromas, or ALCL. Satisfaction and QoL scores indicated very



**Figure 6.** Pseudocapsule of explanted SmoothSilk/SilkSurface Motiva Implants Silicone Breast Implants in a patient who requested reoperation for aesthetic reasons at 3 months.

high levels of satisfaction with Motiva Implants among patients and surgeons and very low rates of reoperation. A limitation of our study is that patients' satisfaction measurement was subjective because it was not anonymously requested.

Motiva Implants are 100% filled with highly viscoelastic, form-stable silicone gel. They use a proprietary TrueMonobloc configuration with similar durometer value between patch and shell, which eliminates the gap in the patch-shell interface and allows it to act as a single structure with uniform tensile strength. As a result, even pressure distribution is achieved, and the shell adjusts to changes in position and pressure without irregularities or deformation. In general, mechanical performance exceeds regulatory standards in all tests performed on the shell, such as elongation, break force, tear resistance, tensile set, and patch joint integrity.<sup>8,9</sup> This model also makes insertion easier and improves implant mechanical qualities when under stress. Patch joint exhibits a high level of strength, with a very low risk of rupture. In this study,



**Figure 7.** Pseudocapsule of explanted SmoothSilk/SilkSurface Motiva Implants Silicone Breast Implants in a patient who requested reoperation for aesthetic reasons at 6 months after the primary surgery.

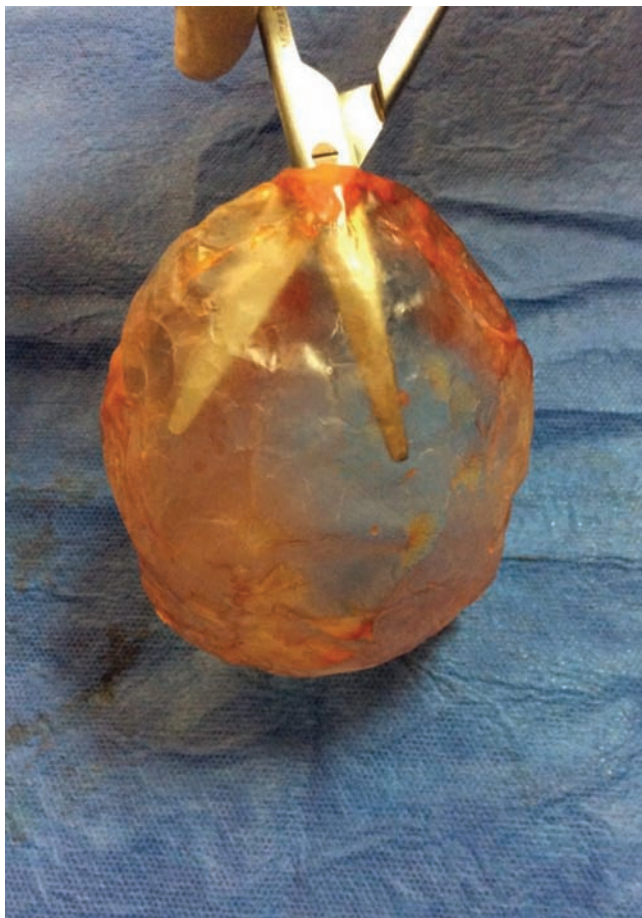there were no instances of rupture evidenced in the group that received an MRI at 6 years after implantation.

The 6-year outcomes reported in this study identified minimal adverse events and no implant-related events (Table 3). The most commonly reported adverse events were ptosis (53.3%) and change in nipple sensitivity (9.4%). Other minor events were reported by almost 6.3% of subjects. None of these outcomes led to reoperation.

Only 3 of the 35 subjects underwent reoperation. Of these 3 revision patients, reoperation was elected by the patient and surgeon only for aesthetic reasons. The Kaplan-Meier risk rate for implant replacement due to volume changes was 9.4%. The main reason for requesting a new surgical procedure was the patient's or surgeon's criteria for possible improvement of aesthetic results obtained with the primary surgery. The rate of implant replacement for safety reasons remains 0% through 6 years.

These safety results are comparable or superior to outcomes reported by studies of other silicone breast implants in the published literature. For example, an analysis of





**Figure 8.** Pseudocapsule of explanted SmoothSilk/SilkSurface Motiva Implants Silicone Breast Implants in a patient who requested reoperation for aesthetic reasons at 71 months after the primary surgery. The very thin capsule evident in this image demonstrates the positive clinical outcome of these surfaces.

prospectively collected registry data from Denmark covering 5373 women who had primary breast augmentation between 1999 and 2007 reported a total adverse event rate of 16.7%.<sup>10</sup> The most common adverse events within 30 days of operation were surgeon related such as hematoma (1.1%) and infection (1.2%); within 5 years, the most common events were change in tactile sense (8.7%) and asymmetry/displacement of the implant (5.2%). The rate of severe capsular contracture, a more implant-related complication, at 5 years was 1.7%. More recently, a long-term study (N = 9217 devices) reported a 0.3% risk of nipple sensation changes at 4 weeks and 6 months and 0.4% risk at 10 years following placement of form-stable silicone implants.<sup>2</sup>

Qualities of the implant and operative technique have been shown to influence complications, and both the surface of Motiva Implants and surgical best-practices likely contributed to the excellent safety results of our study. For example, in the case series described above, utilization of

inframammary incisions and shaped textured gel implants was associated with the lowest rates of complications. Furthermore, textured, shaped gel implants and submuscular implant site were associated with the lowest rates of capsular contracture. Other studies have also reported lower rates of capsular contracture with inframammary incision compared to other sites and with submuscular vs subglandular implant placement.<sup>11,12</sup>

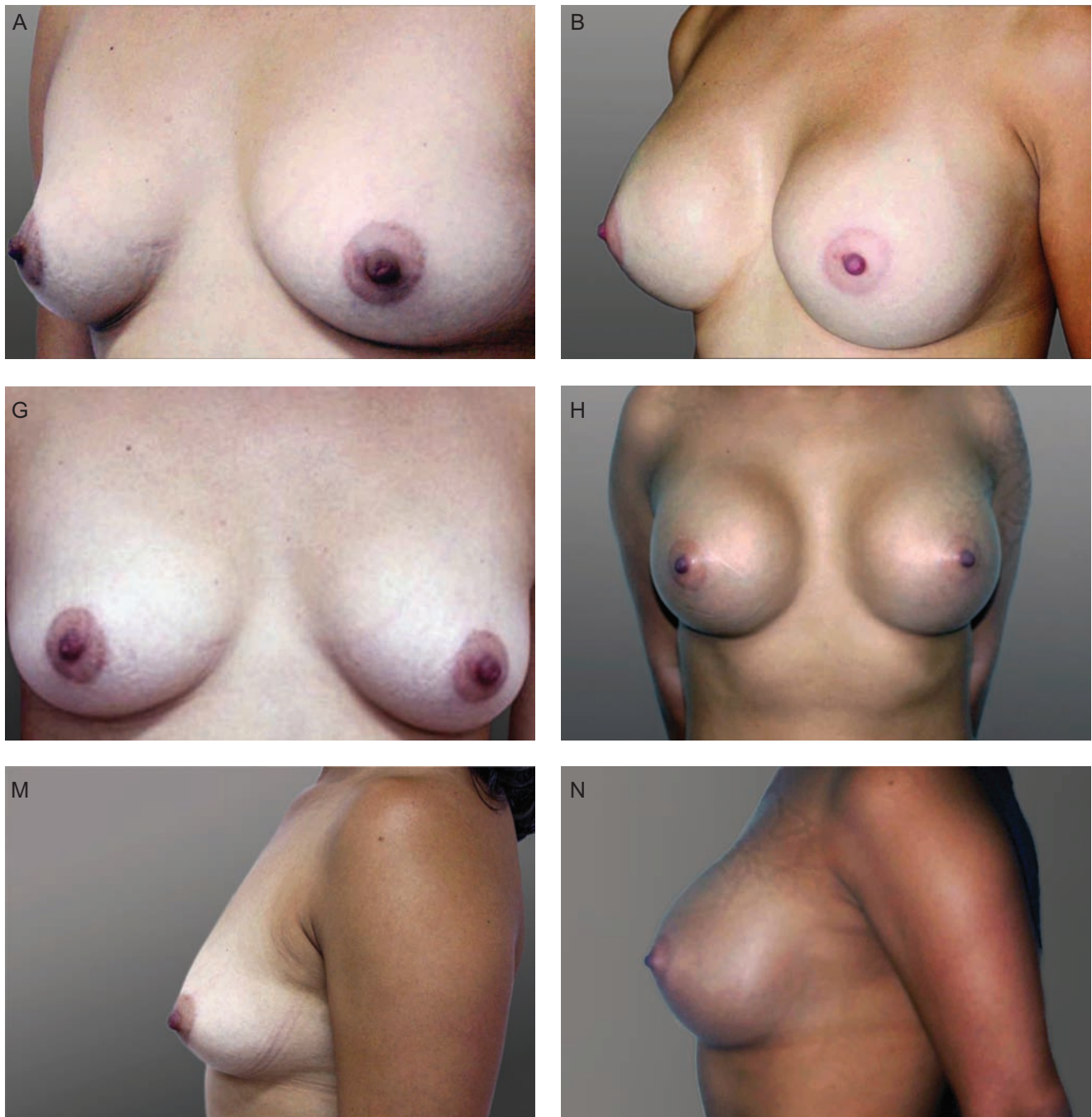
In our study, the most common incision site was inframammary (96.9%) and the most common implant placement was submuscular (71.9%). These characteristics of the surgical approach may have contributed to the absence of adverse events and of capsular contracture.

Capsular contracture and implant rupture are two of the most important potential adverse outcomes of breast augmentation, and contracture is the most common reason for revision surgery.<sup>13</sup> Many studies have reported relatively high rates of capsular contracture, particularly with smooth (nontextured) implants. For example, a 6-year outcomes study of the Allergan (formerly Inamed) silicone breast implants in 940 patients (half of whom were augmentation patients, most of whom received smooth implants) reported capsular contracture rates of 15% to 20% and an implant rupture rate of 3.5%.<sup>14</sup> Long-term studies and meta-analyses comparing smooth and textured implants have reported significantly higher risk for capsular contracture with smooth vs textured implants.<sup>11,12,15,16</sup> SmoothSilk/SilkSurface Motiva Implants used in the study have a hierarchical micro-/nanotopographical structure on their surface. It feels like a smooth implant, but, when viewed under a microscope, it exhibits a complex architecture of structures at the cellular scale.

Texturing was originally developed to minimize capsular contracture. However, the aggressive texturization used in the manufacture of many implants has been associated with risk for seroma and double capsule formation.<sup>17</sup> Furthermore, many textured implants are still associated with a reduced but significant rate of capsular contracture. For example, a 5-year follow-up study of 1010 textured silicone breast implants reported a 6.6% rate of capsular contracture in the overall study population and a Kaplan-Meier risk of contracture of 10.7% following primary augmentation.<sup>18</sup> At 5 years, 8.5% of implants were removed following primary augmentation. The rates of infection and seroma in this study were 0.6% and 0.2%, respectively. A second study reported an 8% rate of capsular contracture at 9 years following implantation of form-stable textured silicone implants.<sup>19</sup> These studies suggest somewhat improved risk for contracture with textured surfaces, but many patients remained at risk for this adverse outcome.

The SmoothSilk/SilkSurface surface of Motiva Implants differs substantially from textured implants. Rather than being textured with the application of salt or sugar crystals onto the implant, like many other implants, SilkSurface/

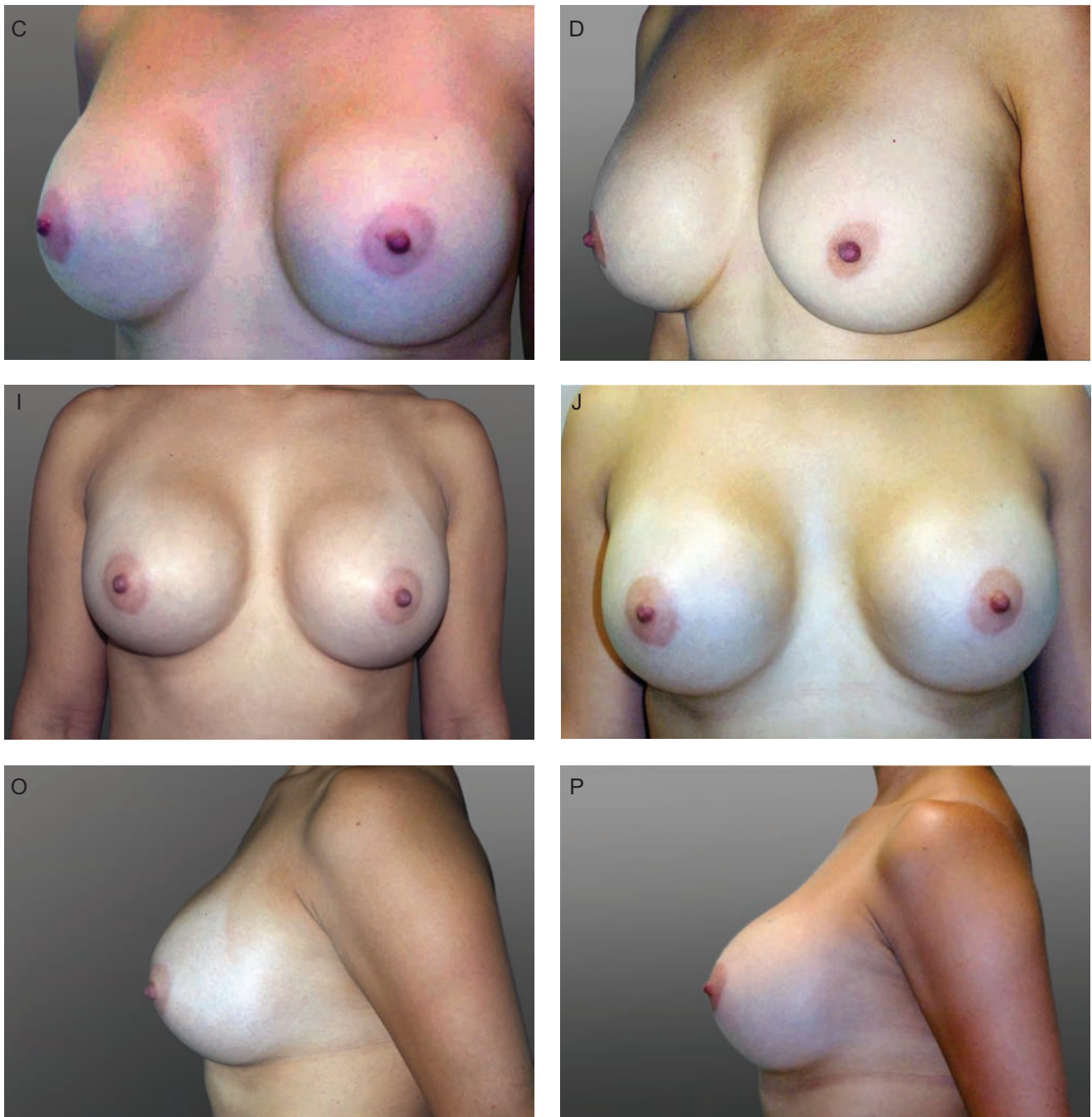




**Figure 9.** This 28-year-old woman with hypoplastic breasts underwent primary breast augmentation utilizing Motiva Implant 355 cc Full Projection breast implants. (A, G, M) Preoperative, (B, H, N) 12-month postoperative, (C, I, O) 24-month postoperative, (D, J, P) 36-month postoperative, (E, K, Q) 48-month postoperative, and (F, L, R) 72-month postoperative photographs are shown.

SmoothSilk is manufactured using 3D inverted negative imprinting technology. The manufacturing process is particle free and uses no foreign particle projection to create the surface, also allowing a uniform and controlled shell thickness. The resulting micro/nano surface is unique: it has very low roughness parameters featuring an average

measurement of  $3600 \pm 400$  nm, which implies low friction coefficient and, consequently, no loose particles.<sup>20</sup> It was engineered to promote a cell-friendly interaction between the implant and surrounding tissues, potentially reducing inflammation in the postoperative period and chronic inflammation after recovery. Furthermore,




**Figure 9.** Continued

this topography seems to affect foreign body response by reducing planar arrangement of adherent cells such as fibroblasts and promoting optimum adhesion based on stable focal contacts.<sup>21,22</sup> This improved interaction with native tissues may limit risk for capsular contraction and allow the implant to better adapt to the normal movement of the breast. This surface's unique characteristics may have contributed to the absence of capsular contracture in the current study.

The impact of this micro/nano surface is evidenced by the very thin pseudocapsules identified during the reoperations performed in this investigation (Figures 6-8). In all cases, the very thin pseudocapsule is the result of a breast implant surface characterized by a multitude of contact points with low roughness. It is significant that the surgeons participating in this study followed a best-practices protocol for breast augmentation that, in combination with these surfaces, resulted in no capsular contracture or rupture cases through 6 years.





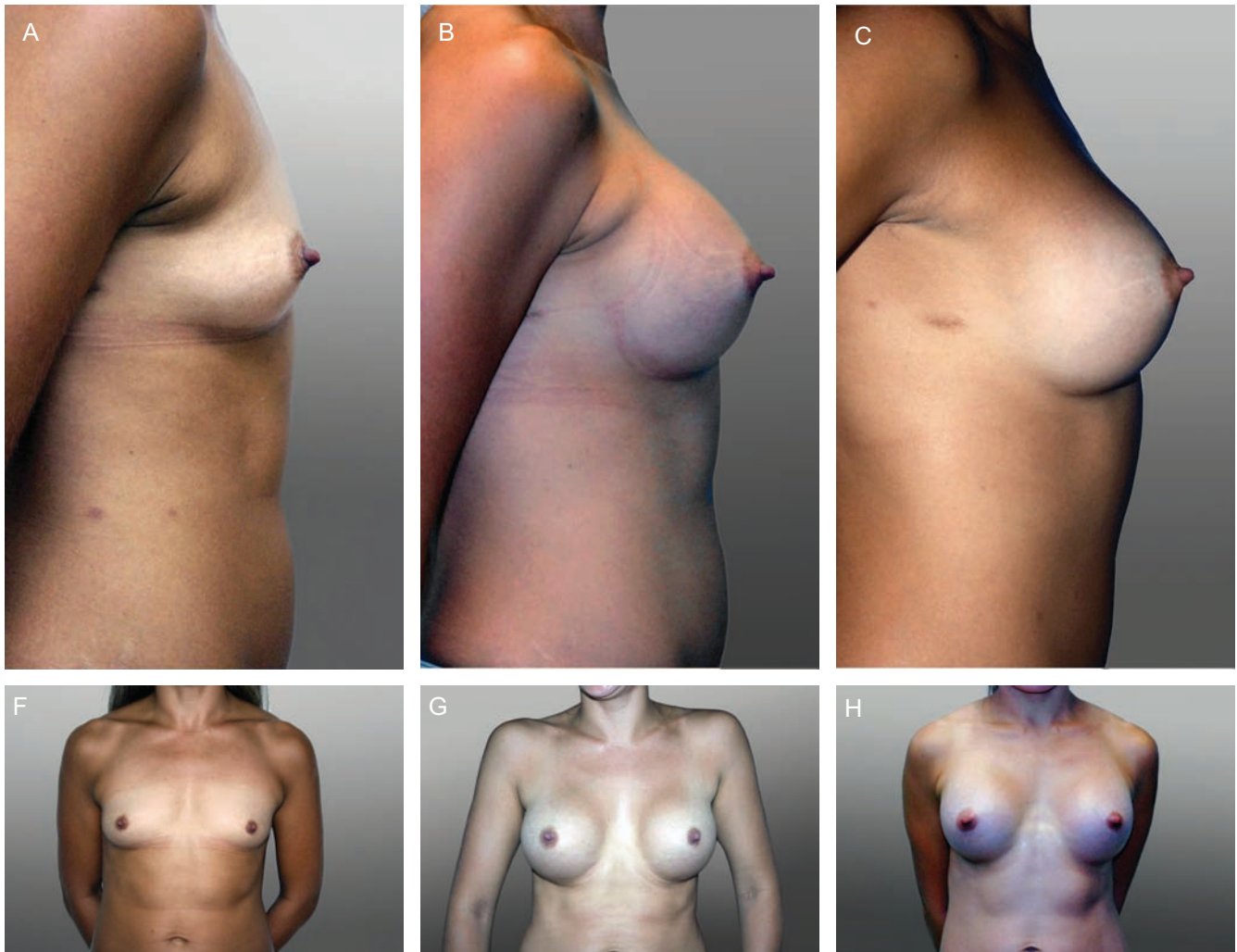
**Figure 9.** Continued

Based on their experience with these implants, the authors recommend that they should be treated like a traditional smooth implant for surgical planning and surgical technique.

The excellent aesthetic outcomes with SmoothSilk/SilkSurface Motiva Implants are illustrated in representative cases in the [Figures 9](#) and [10](#). For the 32 patients (64 implants) evaluated at 6 years, patients reported a high rate of satisfaction with the aesthetic results; 100% of the patients were somewhat satisfied, very satisfied, or

extremely satisfied with the results. The surgeons considered that patients made a very important or an important improvement in 96.9% of the cases with utilization of Motiva Implants in the implanted population. These uniformly high satisfaction scores indicate the effectiveness of the Motiva Implants for primary breast augmentation.

A recently published study with more than 5000 patients utilizing the same devices reported equivalent data with no capsular contracture, late seromas,



**Figure 10.** This 31-year-old woman with hypoplastic breasts underwent primary breast augmentation utilizing Motiva Implant 325 cc Corse Projection breast implants. (A, F) Preoperative, (B, G) 24-month postoperative, (C, H) 36-month postoperative, (D, I) 48-month postoperative, and (E, J) 72-month postoperative photographs are shown.

or double capsules.<sup>23</sup> The congruence of these findings is reassuring because the positive outcomes from the use of these new implants seem to be consistent and reproducible.

Scores on self-esteem/QoL scales also improved from baseline throughout the 6-year study period. A reduction in mean scores was observed 72 months after implantation compared to previous follow-up visits (except for the 4-year value, which is the lowest in the observation period). We believe that this reduction at 72 months was due to individual patient variables such as weight gain, pregnancies, and other personal situations at the time of evaluation. In fact, 6 of the 32 evaluated patients reported a significant weight gain and significant reductions in their self-esteem/QoL scores, causing the average scores to be lower.

It is of particular importance that between 2010 and 2017, the authors implanted a total of 1082 patients in

the same institution (excluding the implants belonging to the investigation presented in this paper) with very low complication rates (Table 4). These complication rates are statistically consistent with those found in the 6-year outcomes from the prospective, 10-year follow-up study to confirm the safety and effectiveness of Motiva Implants silicone breast implants in 35 patients who underwent breast augmentation. Given both the prospective and retrospective experience of the authors with these implants, we believe that in the future there will be enough clinical evidence that these devices can lead to more positive outcomes for patients. Although prospective long-term safety and efficacy in a larger series of patients has yet to be determined for this implant, completing this extended study will be an important contribution to draw its profile. A limitation of this study is the number of patients, which is inadequate to make final claims on capsular contracture or seroma rates.



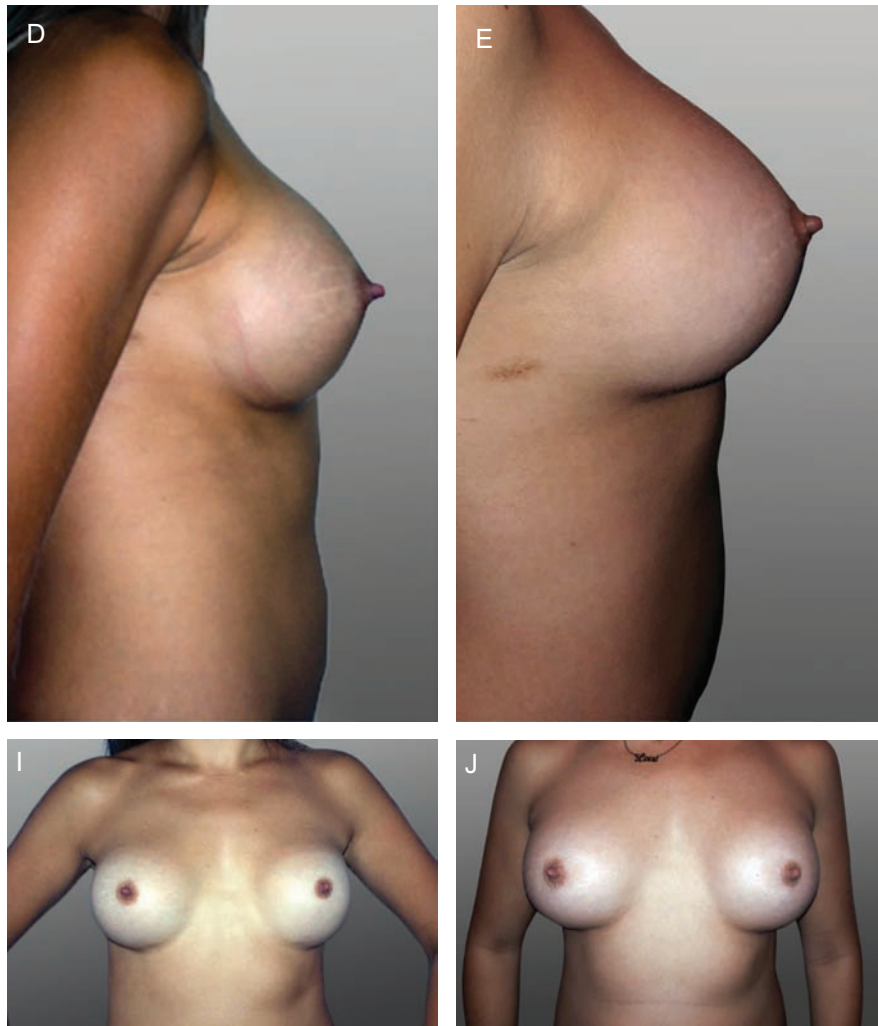


Figure 10. Continued

Table 4. Complication Rates for Motiva Breast Implants Between 2010 and 2017

Complication	% (N)*
Capsular contracture	0.27 (3)
Implant replacement for aesthetical reasons	0.64 (7)
Implant rupture	0.09 (1)
Postsurgical hematoma	0.55 (6)
Postsurgical seroma	0.09 (1)
Wound necrosis	0.09 (1)

Moreover, the authors would expect that additional studies will further validate the hypothesis that these implants amalgamate the best characteristics of a smooth implant with the positive expectations of a textured device.

## CONCLUSIONS

The SmoothSilk/SilkSurface Motiva Implants used in this study demonstrated an optimal safety profile and excellent aesthetic results in both the MRI and non-MRI cohorts. At 6 years, there were no cases of implant rupture or malposition, no cases of capsular contracture, and a very low rate of reoperation, which was performed only for aesthetic reasons. This ongoing study will continue to evaluate outcomes with these patients, but the clinical results to date are promising for this innovative technology.

## Supplementary Material

This article contains supplementary material located online at [www.aestheticsurgeryjournal.com](http://www.aestheticsurgeryjournal.com).

## Acknowledgments

Editorial support for manuscript development was provided by Joshua Kilbridge of Kilbridge Associates (San Francisco, CA).

## Disclosures

Dr Manuel Chacón Quirós and Dr Manuel Chacón Bolaños are relatives of the CEO of Establishment Labs. Dr Chacón Quirós has been a member of the Medical Advisory Board of Establishment Labs since 2015. Dr Fassero declared no potential conflicts of interest with respect to the research, authorship, and publication of this article. Patients received the implants free of charge from Establishment Labs S.A. All reports from every patient's visit were independently audited by Dr. Alfredo Vargas, Plastic Surgeon from the Plastic and Reconstructive Surgery Department, Hospital Mexico (San Jose, Costa Rica).

## Funding

Establishment Labs Holdings Inc. (New York, NY) funded the manuscript development in terms of medical writing, editing assistance, and statistical analysis.

## REFERENCES

1. Cosmetic Surgery National Data Bank Statistics. *Aesthet Surg J.* 2017;37(Suppl 2):1-29.
2. Lund HG, Turkle J, Jewell ML, Murphy DK. Low risk of skin and nipple sensitivity and lactation issues after primary breast augmentation with form-stable silicone implants: follow-up in 4927 subjects. *Aesthet Surg J.* 2016;36(6):672-680.
3. Somogyi RB, Brown MH. Outcomes in primary breast augmentation: a single surgeon's review of 1539 consecutive cases. *Plast Reconstr Surg.* 2015;135(1):87-97.
4. Mathur A. *Nanotechnology in Cancer.* Amsterdam, Netherlands: Elsevier Science and Technology Books; 2017.
5. Barr S, Hill EW, Bayat A. Functional biocompatibility testing of silicone breast implants and a novel classification system based on surface roughness. *J Mech Behav Biomed Mater.* 2017;75:75-81.
6. ISO 14607:2018. *Non-active surgical implants – Mammary implants particular requirements.* Geneva, Switzerland: International Organization for Standardization.
7. Bengtson BP, Van Natta BW, Murphy DK, Slicton A, Maxwell GP; Style 410 U.S. Core Clinical Study Group. Style 410 highly cohesive silicone breast implant core study results at 3 years. *Plast Reconstr Surg.* 2007;120(7 Suppl 1):40S-48S.
8. Establishment Labs. *Technical Study Report Surface Characterization Method Motiva VelvetSurface®, Motiva SilkSurface®, and Eurosilicone: TS-15-003.R.* 2017.
9. Establishment Labs. *Technical Study Report: Roughness Test Metrology with μsurf Mobile TS-16-011.R.* 2017.
10. Hvilsom GB, Hölmich LR, Henriksen TF, Lipworth L, McLaughlin JK, Friis S. Local complications after cosmetic breast augmentation: results from the Danish Registry for Plastic Surgery of the Breast. *Plast Surg Nurs.* 2010;30(3):172-179.
11. Namnoum JD, Largent J, Kaplan HM, Oefelein MG, Brown MH. Primary breast augmentation clinical trial outcomes stratified by surgical incision, anatomical placement and implant device type. *J Plast Reconstr Aesthet Surg.* 2013;66(9):1165-1172.
12. Stevens WG, Nahabedian MY, Calobrace MB, et al. Risk factor analysis for capsular contracture: a 5-year Sientra study analysis using round, smooth, and textured implants for breast augmentation. *Plast Reconstr Surg.* 2013;132(5):1115-1123.
13. Forster NA, Künzi W, Giovanoli P. The reoperation cascade after breast augmentation with implants: what the patient needs to know. *J Plast Reconstr Aesthet Surg.* 2013;66(3):313-322.
14. Spear SL, Murphy DK, Slicton A, Walker PS; Inamed Silicone Breast Implant U.S. Study Group. Inamed silicone breast implant core study results at 6 years. *Plast Reconstr Surg.* 2007;120(7 Suppl 1):8S-16S; discussion 17S.
15. Wong CH, Samuel M, Tan BK, Song C. Capsular contracture in subglandular breast augmentation with textured versus smooth breast implants: a systematic review. *Plast Reconstr Surg.* 2006;118(5):1224-1236.
16. Barnsley GP, Sigurdson LJ, Barnsley SE. Textured surface breast implants in the prevention of capsular contracture among breast augmentation patients: a meta-analysis of randomized controlled trials. *Plast Reconstr Surg.* 2006;117(7):2182-2190.
17. Hall-Findlay EJ. Breast implant complication review: double capsules and late seromas. *Plast Reconstr Surg.* 2011;127(1):56-66.
18. Duteille F, Perrot P, Bacheley MH, Stewart S. Eight-year safety data for round and anatomical silicone gel breast implants. *Aesthet Surg J.* 2018;38(2):151-161.
19. Stevens WG, Calobrace MB, Harrington J, Alizadeh K, Zeidler KR, d'Incelli RC. Nine-year core study data for Sientra's FDA-approved round and shaped implants with high-strength cohesive silicone gel. *Aesthet Surg J.* 2016;36(4):404-416.
20. Munhoz AM, Santanelli di Pompeo F, De Mezerville R. Nanotechnology, nanosurfaces and silicone gel breast implants: current aspects. *Case Reports Plast Surg Hand Surg.* 2017;4(1):99-113.
21. Barr S, Hill E, Bayat A. Current implant surface technology: an examination of their nanostructure and their influence on fibroblast alignment and biocompatibility. *Eplasty.* 2009;9:e22.
22. Barr S, Bayat A. Breast implant surface development: perspectives on development and manufacture. *Aesthet Surg J.* 2011;31(1):56-67.
23. Sforza M, Zaccheddu R, Alleruzzo A, et al. Preliminary 3-year evaluation of experience with silksurface and velvetsurface motiva silicone breast implants: a single-center experience with 5813 consecutive breast augmentation cases. *Aesthet Surg J.* 2018;38(Suppl 2):S62-S73.