

Contents lists available at [ScienceDirect](http://www.sciencedirect.com)

## International Journal of Surgery Case Reports

journal homepage: [www.casereports.com](http://www.casereports.com)

## Metastatic ovarian carcinoma presenting as an incarcerated femoral hernia



Suzanne M. Beecher\*, Donal Peter O'Leary, Ray McLaughlin

Department of Surgery, University College Hospital Galway, Galway, Ireland

## ARTICLE INFO

## Article history:

Received 28 January 2015  
 Received in revised form 20 April 2015  
 Accepted 20 April 2015  
 Available online 22 April 2015

## Keywords:

Femoral hernia  
 Incarcerated  
 Cancer  
 Ovarian  
 Bowel obstruction  
 Strangulated

## ABSTRACT

**INTRODUCTION:** Incarcerated femoral hernias usually contain a simple loop of bowel. Occasionally other abdominal structures may be found within the hernial sac. Rarely femoral hernias may contain metastatic tumour deposits.

**PRESENTATION OF CASE:** We report the case of an 82 year old lady with a background of ovarian carcinoma, who presented with acute small bowel obstruction and an irreducible right groin mass. CT imaging revealed an incarcerated loop of small bowel within a femoral hernia sac. The patient proceeded to theatre for hernia repair. Upon opening the hernial sac an adherent incarcerated small bowel loop was discovered. Interestingly, the sac itself was lined with metastatic deposits, which were later histologically proven to be ovarian in origin. The sac was reduced and the hernia was repaired. The patient's post-operative course was uneventful.

**DISCUSSION:** As abdominal wall hernias communicate with the abdominal cavity there is the potential for malignant cells to seed the peritoneal lining of the hernia sac. If the sac also contains bowel wall, this may become involved in the tumour mass. This may result in small bowel incarceration & obstruction.

**CONCLUSION:** In cases, where there is a known intra-abdominal malignancy & the presence of an incarcerated hernia, there should be a high index of suspicion for the presence of tumour within the hernial contents.

© 2015 The Authors. Published by Elsevier Ltd. on behalf of Surgical Associates Ltd. This is an open access article under the CC BY-NC-ND license (<http://creativecommons.org/licenses/by-nc-nd/4.0/>).

## 1. Introduction

Femoral hernias are most prevalent in elderly females [1]. They are particularly prone to incarceration & strangulation [2]. Femoral hernias usually become incarcerated & strangulated when a loop of bowel becomes trapped in the hernia sac. The bowel wall becomes oedematous and becomes irreducible if there is a narrow hernia neck. As femoral hernias have a narrow hernia orifice, they are particularly prone to incarceration.

Intra-abdominal malignancies may metastasize trans-coelomically to implant in any area of the peritoneum. As abdominal wall hernias are in connection with the abdominal cavity there is the potential for malignant cells to seed the peritoneal lining of the hernia sac.

## 2. Presentation of case

We report the case of an 82 year old lady, who presented with a two day history of nausea and intractable vomiting in November 2013. Her medical history was significant for metastatic ovarian

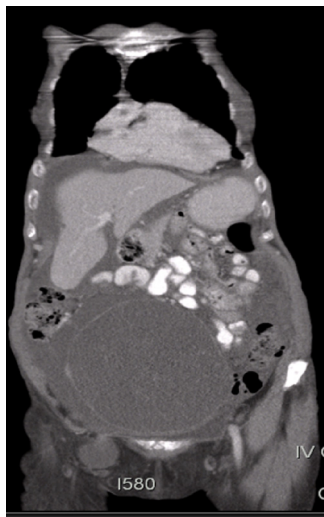
cancer – with liver, spleen and peritoneal deposits noted on a recent CT scan. She had previously undergone an ovarian debulking procedure, with a concomitant appendicectomy, TAH & BSO performed in August 2012. Fig. 1 illustrates the femoral hernia prior to debulking surgery. The debulking surgery was performed by the gynaecological team. The general surgeons were not consulted for management of the femoral hernia at that time.

She demonstrated a non-tender, distended abdomen upon examination with visible small bowel loop peristalsis on the anterior abdominal wall. A right groin mass was apparent which was clinically irreducible and non-tender. No cough impulse was present. The initial impression was that this was a small bowel obstruction secondary to an incarcerated femoral hernia.

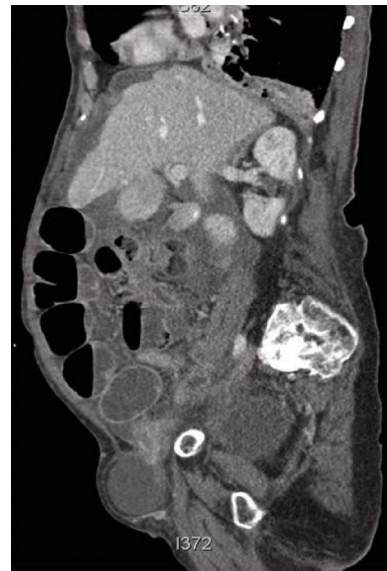
Routine blood tests were sent upon admission including full blood count, urea and electrolytes and a coagulation profile. These were monitored during the admission and remained within normal limits. Plain film of the abdomen showed marked dilatation of small bowel loops with an absence of air in the colon consistent with distal small bowel obstruction (Fig. 2). No pneumoperitoneum was evident.

CT scan of the abdomen and pelvis was performed to ensure there was no other cause of obstruction evident given, this patient had a previous debulking procedure for ovarian cancer (Fig. 3). The CT scan confirmed a 4.7 × 3.3 cm femoral hernia containing a loop

\* Corresponding author. Tel.: +353 87 6888388.  
 E-mail address: [suzub@hotmail.com](mailto:suzub@hotmail.com) (S.M. Beecher).



**Fig. 1.** CT scan: large ovarian mass & right femoral hernia – imaged prior to debulking surgery.



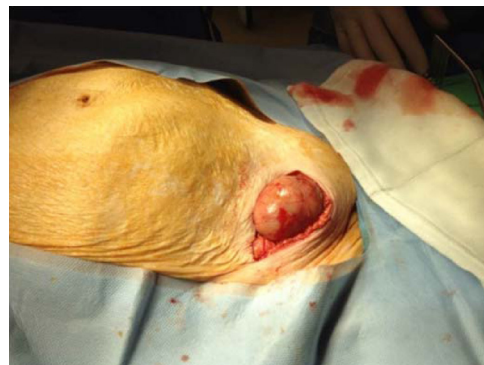**Fig. 3.** CT images showing sagittal views of the right femoral hernia.

of ileum with dilated small bowel proximal to this, measuring up to 3.7 cm. A moderate amount of ascites was also present.

A wide bore naso-gastric tube was sited and she was fluid resuscitated preoperatively. Thrombo-prophylaxis was commenced and her analgesia requirements were managed in accordance to the WHO pain ladder.

She was brought to the operating theatre with a diagnosis of acute distal small bowel obstruction secondary to incarcerated small bowel within her femoral hernia. The approach was made through an oblique skin incision over the swelling. Operative findings demonstrated a loop of bowel adherent to the femoral hernia sac (Fig. 4). Ascitic fluid, tumour deposits and dusky haemorrhagic tissue were noted in the sac. The hernia was not deliverable in this approach and it was decided to open the external oblique and approach the sac through transversalis fascia in the pre-peritoneal space. The sac was dissected and opened, and the segment of ileum was deemed to be viable. The sac was reduced and the hernia repaired although with some difficulty due to the friability of the surrounding tissues.

The postoperative course was uneventful and the patient was managed through a multidisciplinary approach facilitating a return to normal diet and baseline mobility with analgesia requirements addressed appropriately. Histology revealed the specimens taken intra-operatively to be of ovarian origin. She was reviewed in clinic

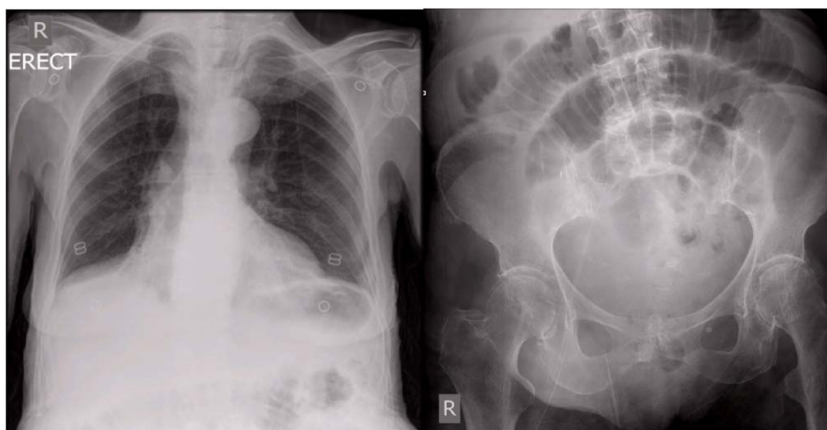


**Fig. 4.** Hernia sac exposed with prominent small bowel loops visible on the abdominal wall.

post-operatively and was continuing to recover, with continued follow-up under the Oncology service.

### 3. Discussion

Cases such as this are not well described in the literature. To our knowledge this is the first case of an incarcerated femoral hernia



**Fig. 2.** Plain films of the abdomen and chest demonstrating dilated central loops of small bowel without evidence of perforation.

due to the adherence of bowel to the hernial sac secondary to tumour involvement.

Rarely, incarcerated femoral hernias may contain, contents other than a simple bowel loop. There have been multiple cases reported, where, an ovary has been found to be present within a femoral hernial sac [3]. A few reports of de Garengeot's hernia exist in the literature – defined as the presence of an appendix within the femoral hernial sac [4,5]. One case reports the presence of a de Garengeot hernia in conjunction with a Littre hernia within a hernial sac, while another describes it in conjunction with a Richter's hernia [6,7]. There are also reports of the unusual herniation of a fallopian tube and a bladder diverticulum through a femoral hernial sac [8,9]. These are all important considerations when diagnosing and treating femoral hernias.

Generally femoral hernias can be diagnosed on physical examination & radiological investigation is not warranted [10]. Although in this case CT did not aid her diagnosis, it is an important investigation to consider when there is concurrent significant abdominal pathology.

The femoral hernia was previously present on her original CT scan at the time of debulking surgery. A multi-disciplinary approach was not taken at this time, and therefore the femoral hernia was not repaired at that time. Femoral hernias have a high risk of complications requiring emergency management, and therefore, should be repaired in an elective setting where possible [2]. Certainly, has the hernia been operated on at the time of debulking surgery, this presentation may have been avoided.

Gately et al. have previously reported that ovarian pathology can cause recurrent femoral hernia due to increased abdominal pressure, and indeed her ovarian pathology may have played a role in the initial development of her femoral hernia [11]. It is exceptionally rare, however, to encounter a case where the primary tumour has proliferated to such an extent that it causes herniation of bowel into the femoral canal. Although a case has been described where a single ovarian omental metastasis was discovered within the femoral hernial sac, to our knowledge this is the first case to describe a hernial sac containing bowel and extensive tumour debris [12].

Even with those without a previously diagnosed intra-abdominal malignancy, the occurrence of a hernia may be a presenting feature of cancer [13–15]. Surgeons must remain vigilant when repairing hernias, both electively and as an emergency. If grossly abnormal pathology is visualised at the time of hernia repair, then the hernia sac should be examined histologically.

#### 4. Conclusion

In cases where there is a known intra-abdominal malignancy and the presence of an incarcerated hernia, there may be tumour present within the hernial contents. Suspicious hernial sacs should be sent for histopathological analysis to exclude metastatic disease.

#### Conflict of interest

No conflict of interest.

#### Consent

Written informed consent was obtained from the patient for publication of this case report and accompanying images. A copy of the written consent is available for review by the Editor-in-Chief of this journal upon request.

#### Sources of funding

No funding received.

#### Authors contribution

Suzanne Beecher – drafting paper.  
D.P. O'Leary – data collection and Drafting paper.  
R. McLaughlin – editing paper.

#### References

- [1] J.J. Arenal, P. Rodríguez-Vielba, E. Gallo, et al., Hernias of the abdominal wall in patients over the age of 70 years, *Eur. J. Surg.* 168 (8-9) (2002) 460–463.
- [2] U. Dahlstrand, S. Wollert, P. Nordin, et al., Emergency femoral hernia repair: a study based on a national register, *Ann. Surg.* 249 (4) (2009) 672–676.
- [3] D. Coyle, N. Kavanagh, A. Mahmoud, et al., Incarcerated femoral hernia containing ovary and fallopian tube in a 54-year-old, *BMJ Case Rep.* (2011).
- [4] A. Hussain, A.A.P. Slessor, S. Monib, et al., A De Garengeot hernia masquerading as a strangulated femoral hernia, *Int. J. Surg. Case Rep.* 5 (10) (2014) 656–658.
- [5] S.S. Rajan, H.R.S. Girn, W.G. Ainslie, Inflamed appendix in a femoral hernial sac: de Garengeot's hernia, *Hernia* 13 (5) (2009) 551–553.
- [6] M. Racy, S. Ramesh, Littre meets de Garengeot: Meckel's diverticulum and appendix in a femoral hernia, *Ann. R. Coll. Surg. Engl.* 95 (6) (2013) e97–e98.
- [7] H.D. Le, S.R. Odom, A. Hsu, et al., A combined Richter's and de Garengeot's hernia, *Int. J. Surg. Case Rep.* 5 (10) (2014) 662–664.
- [8] J.F. Devane, Fallopian tube found in femoral hernia, *Lancet* 188 (4862) (1916) 805.
- [9] A.H. Omari, M.A. Alghazo, Urinary bladder diverticulum as a content of femoral hernia: a case report and review of literature, *World J. Emerg. Surg.* 8 (1) (2013) 20.
- [10] J. Rosenberg, T. Bisgaard, H. Kehlet, et al., Danish Hernia Database recommendations for the management of inguinal and femoral hernia in adults, *Dan. Med. Bull.* 58 (2) (2011) C4243.
- [11] R.P. Gately, E.S. Concannon, A. Hogan, et al., Recurrent femoral hernia and associated ovarian pathology, *BMJ Case Rep.* (2012).
- [12] S.J. Matthews, H.R. McClelland, Saved by a hernia: an unusual presentation of ovarian cancer, *Int. J. Clin. Practice* 52 (2) (1998) 127–128.
- [13] J.F. Val-Bernal, M. Mayorga, F.A. Fernández, et al., Malignant epithelial tumors observed in hernia sacs, *Hernia* 18 (6) (2014) 831–835.
- [14] R. Qin, Q. Zhang, J. Weng, et al., Incidental finding of a malignant tumour in an inguinal hernia sac, *Wspolczesna Onkologia* 18 (2) (2014) 130–133.
- [15] C.C. Yen, M.C. Lee, C.H. Lin, et al., A case of pseudomyxoma peritonei presenting as ventral and femoral hernia, *Tzu Chi Med. J.* 23 (3) (2011) 93–95.

#### Open Access

This article is published Open Access at [sciendo.com](http://sciendo.com). It is distributed under the [IJSCR Supplemental terms and conditions](#), which permits unrestricted non commercial use, distribution, and reproduction in any medium, provided the original authors and source are credited.