



Short Communication

# Platelet rich fibrin as a gingival tissue regeneration enhancer



Bianca Nausica Petrescu <sup>a</sup>, Ioana Codruta Mirica <sup>a\*</sup>,  
Richard Miron <sup>b</sup>, Radu Septimiu Campian <sup>a</sup>, Ondine Lucaciu <sup>a</sup>

<sup>a</sup> Department of Oral Health, Faculty of Dentistry, "Iuliu Hațieganu" University of Medicine and Pharmacy, Cluj-Napoca, Romania

<sup>b</sup> Department of Periodontology, University of Berne, Berne, Switzerland

Received 1 August 2020; Final revision received 26 August 2020

Available online 8 September 2020

## KEYWORDS

Choukroun's PRF;  
Gingival chemical  
burn;  
Platelet rich fibrin;  
Regeneration;  
Wound healing

**Abstract** Tissue regenerative procedures aim to enhance regeneration of altered tissue. Extensive research has been carried out in this area and all proposed procedures present limitations. In this context the area of platelet-rich fibrin (PRF) research has gained tremendous awareness in the latest years. PRF is a low-cost regenerative modality that facilitates soft tissue regeneration derived from 100% autologous sources. It forms a fibrin mesh that liberates growth factors in a slow and prolonged manner and also contains supra-physiological concentrations of leukocytes. Reports from the literature have suggested that these leukocyte-rich blood-preparations are capable of improving wound healing, diminishing post-operative pain, and additionally minimizing the risk of infection. In our article we present the first clinical case where PRF was used as a wound healing accelerator of gingival lesions in a chemical soft tissue burn after teeth whitening.

© 2020 Association for Dental Sciences of the Republic of China. Publishing services by Elsevier B.V. This is an open access article under the CC BY-NC-ND license (<http://creativecommons.org/licenses/by-nc-nd/4.0/>).

## Introduction

Platelet-Rich Fibrin (PRF) was developed as a platelet concentrate (PC) without anti-coagulant, by centrifuging the blood immediately after collection, prior to clotting. This led to the formation of a PC entrapped in a fibrin mesh. The advantages of Platelet-Rich Fibrin treatment include a

slower and more gradual release of growth factors: transforming growth factor- $\beta$ 1 (TGF- $\beta$ 1), vascular endothelial growth factor (VEGF), epidermal growth factor (EGF), insulin-like growth factor (IGF), and platelet-derived growth factor (PDGF-AB) over time.<sup>1</sup> In addition, it is well-known that the entrapment of leukocytes in the PRF matrix contributes to infection defense and matrix reshaping during the healing process.<sup>2</sup> The fibrin provides clot flexibility and elasticity in order to be pressed into a membrane for improved clinical handling.<sup>3</sup>

\* Corresponding author.

E-mail address: [mirica\\_codruta@yahoo.com](mailto:mirica_codruta@yahoo.com) (I.C. Mirica).

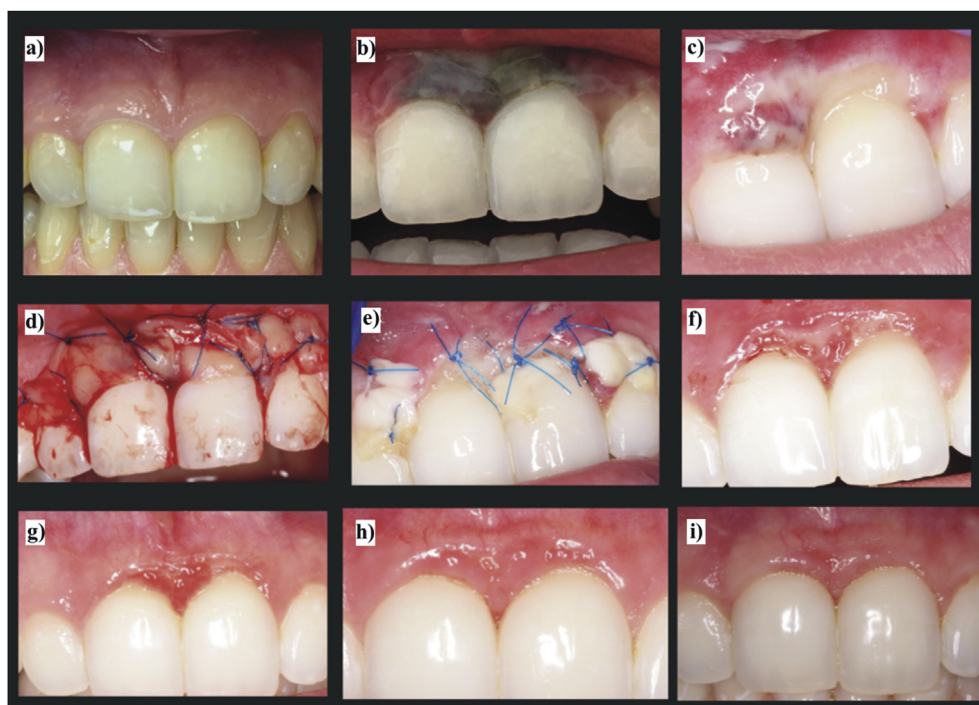
Studies in literature have yielded evidence that PRF provides short preparation time, low costs, and no foreign antibody formation or potential adverse immune responses.<sup>3</sup> PRF has also been shown to decrease<sup>4</sup> or eradicate post-operative pain.<sup>5</sup> However, the most common clinical indication of PRF use is soft tissue regeneration.<sup>6</sup>

To the best knowledge of the authors, this is the first report on the use of PRF as a regeneration enhancer in the management of gingival lesions such as chemical burns associated with teeth whitening.


## Materials and methods

A female patient, 28 years old, was referred to our dental office due to chemical burns of the keratinized gingiva. The medical history of the case revealed that one day after a bleaching session performed in a dental office with inappropriate gingival isolation, the patient observed a color change, to violet, of the mucosa (Fig. 1b) in the upper frontal area, with lack of sensation at the level of the left upper central incisor. The intraoral exam, performed 10 days after the bleaching session, revealed a white mucosa in the region of the upper incisors, with bone exposure (Fig. 1c). The left upper incisor tested negative at the vitality test. The patient declared no comorbidities and gave an informed consent. As there is

no standard treatment for chemical burns induced by teeth whitening, and based on the reported positive effects of PRF in chronic full-thickness burns,<sup>7</sup> we decided to use PRF for the treatment of burn injuries. PRF was obtained prior to the surgical procedure by collecting the patient's blood in 9 mL plastic tubes (IntraLock, Boca Raton, FL, United States), without anticoagulants, and immediately centrifuging the samples at 1500 rpm for 8 min using an IntraSpin centrifugation system (IntraLock). After centrifugation, the lids were removed to aerate the PRF, which resulted in a fibrin clot rich in platelets, trapped between an acellular plasma layer and erythrocytes (Fig. 2a). The solid fibrin clot was then gently removed (Fig. 2b) and condensed in the metal PRF box (IntraLock) in order to obtain a solid membrane approximately 1–2 mm in thickness (Fig. 2c). The treatment of the burn was initiated 10 days after the injury. After performing loco-regional anesthesia the PRF membrane was placed on the necrosis region and secured by using sling sutures (Fig. 1d, e). The patient was advised on maintaining oral hygiene and no antibiotics or analgesics were prescribed. The sutures were removed after 5 days. Considering the improvement in patient outcomes the procedure was repeated at 3 weeks, 5 weeks and 8 weeks after the injury. Throughout the healing process, the patient was monitored weekly and the healing occurred eventless, without pain.



**Figure 1** The use of PRF for gingival burn treatment after a teeth whitening procedure: (a) Aspect of frontal upper gingival mucosa before the dental whitening procedure; (b) Aspect of the lesion 5 days after dental whitening procedure. Swelling of the gingival mucosa with purple appearance at the level of the two upper incisors; (c) Aspect of the lesion 10 days after dental whitening procedure, white lesion around the gingiva of the two upper incisors, with exposed alveolar bone; (d) Aspect of the PRF membranes covering the mucosal lesion; (e) Aspect of the PRF membranes 3 days after positioning; (f) Aspect of the mucosal lesion 6 weeks after PRF application; (g) Aspect of the mucosal lesion 2 months after PRF application; (h) Aspect of the mucosal lesion 4 months after PRF application; (i) Aspect of the mucosal lesion 12 months after PRF application.



**Figure 2** PRF obtaining protocol: (a) PRF after centrifugation; (b) Texture of the fibrin clot; (c) The flattened fibrin membrane prepared after metal box compression.

## Results

At 6 weeks (Fig. 1f) and 2 months (Fig. 1g) after surgical intervention, the aspect of the gingival mucosa revealed the regenerated gingival tissue and covering of exposed bone. At 4 months (Fig. 1h) after initiation of treatment, almost all of the lost gingival keratinized tissue was regenerated and the left upper incisor tested positive at the vitality test. The aspect of the mucosal lesion at 12 months after PRF application is shown in Fig. 1i, compared to the initial aspect before chemical burn of the gingiva (Fig. 1a).

## Discussion

Compared to other techniques, this original approach in the treatment of chemical burns offers an easier, cost-effective and time-conservative method for soft tissue regeneration. PRF provides all the advantages of using 100% autologous tissue grafts in an easily sourced method that does not elicit any sort of foreign body reaction which may be created with non-autologous tissue substitutes.<sup>1</sup> Furthermore, the process of blood collection for the PRF does not cause damage to other tissues, in contrast with connective tissue grafts which imply additional morbidity of the donor site. In a systematic review published by Miron et al., the authors highlighted the positive effects of PRF on wound healing for the management of various soft tissue defects in medicine and dentistry.<sup>6</sup> In the latest review addressing the use of PRF in the treatment of gingival recessions, Miron et al. underlined the fact that the use of PRF appeared to improve patient-related outcomes such as postsurgical discomfort and pain.<sup>8</sup>

The PRF membrane placed at the injury site forms a solid fibrin matrix that slowly remodels in a natural concentrated blood clot. Platelets and cytokines are effectively retained and released gradually over a period up to 10 days post-surgery favoring regeneration.<sup>3</sup> The PRF membrane may be left exposed in the oral cavity decreasing the pain level during the healing process due to the high content in bacteria-fighting leukocytes,<sup>5</sup> which also provides antibacterial properties to the membrane.<sup>2</sup>

During the past years, studies have shown<sup>5,6,9,10</sup> that PRF significantly improves the migration and proliferation of periodontal progenitor cells,<sup>9</sup> increasing the healing speed of gingival grafts.<sup>10</sup> Miron et al.<sup>6</sup> acknowledge that PRF enables soft tissue regeneration in all but one of the 18 *in vivo* and *in vitro* studies. Furthermore, Mihailova et al. suggest

that PRF stimulates soft tissue wound healing after tooth extraction.<sup>10</sup> In a review of human clinical trials, Zumaran et al. highlight that 4 out of 5 studies using PRF report that it significantly improves soft tissue regeneration and reduces post-operative pain and edema.<sup>5</sup> Also, Ghanaati et al. provide further support to the role of PRF in periodontology, especially its pain-relieving effects, as patients who received PRF therapy experienced lower pain levels.<sup>9</sup>

The results of all the above-mentioned studies concur with the outcomes of our present research and validate the effectiveness of PRF in the management of chemical gingival burns. Moreover, as PRF was also successfully used in full-thickness skin burns<sup>7</sup>, it is important to emphasize that this study may contribute to the development of a new clinical approach to chemical gingival burns. However, this case report is not without limitations, particularly reflected in the fact that the efficiency of the PRF was not directly compared with other therapeutic approaches such as healing without PRF or healing associated with the use of antimicrobial rinsing.

In conclusion, the obtained results demonstrate that the use of PRF for chemical burns induced by teeth whitening provides adequate clinical and aesthetic final outcomes. This study also identifies the need for further research into the regenerative potential of PRF, underpinning the importance of a prospective randomized clinical trial designed to assess the efficiency of PRF in chemical burn regeneration.

## Declaration of competing interest

The authors have no conflicts of interest relevant to this article.

## Acknowledgments

This work was funded by the Doctoral Research Project (PCD 2016) of "Iuliu Hațieganu" University of Medicine and Pharmacy, Cluj-Napoca – Contract no. 7690/15.04.2016. Nausica B. Petrescu, Ioana C. Mirica and Ondine Lucaciu have equally contributed to the current manuscript.

## References

1. Su CY, Kuo YP, Tseng YH, Su CH, Burnouf T. *In vitro* release of growth factors from platelet-rich fibrin (PRF): a proposal to

- optimize the clinical applications of PRF. *Oral Surg Oral Med Oral Pathol Oral Radiol Endod* 2009;108:56–61.
2. Moojen DJ, Everts PA, Schure RM, et al. Antimicrobial activity of platelet-leukocyte gel against *Staphylococcus aureus*. *J Orthop Res* 2008;26:404–10.
  3. Choukroun J, Adda F, Schoeffler C, Vervelle A. Une opportunité en paro-implantologie: le PRF. *Implantodontie* 2000;42:55–62.
  4. Bilginaylar K, Uyanik LO. Evaluation of the effects of platelet-rich fibrin and piezo-surgery on outcomes after removal of impacted mandibular third molars. *Br J Oral Maxillofac Surg* 2016;54:629–33.
  5. Zumarán CC, Parra MV, Olate SA, Fernández EG, Muñoz FT, Haidar Z. The 3 R's for Platelet-Rich Fibrin: a "super" tri-dimensional biomaterial for contemporary naturally-guided oro-maxillo-facial soft and hard tissue repair, reconstruction and regeneration. *Materials* 2018;11:1293.
  6. Miron RJ, Fujioka-Kobayashi M, Bishara M, Zhang Y, Hernandez M, Choukroun J. Platelet-rich fibrin and soft tissue wound healing: a systematic review. *Tissue Eng B Rev* 2017;23: 83–99.
  7. Andreone A, den Hollande DA. Retrospective study on the use of dermis micrografts in platelet-rich fibrin for resurfacing of massive and chronic full-thickness burns. *Stem Cell Int* 2019; 15:1–9.
  8. Miron RJ, Moraschin V, Del Fabbro M, et al. Use of platelet-rich fibrin for the treatment of gingival recessions: a systematic review and meta-analysis. *Clin Oral Investig* 2020;24: 2543–57.
  9. Ghanaati S, Herrera-Vizcaino C, Al-Maawi S, et al. Fifteen years of platelet rich fibrin in dentistry and oromaxillofacial surgery: how high is the level of scientific evidence? *J Oral Implantol* 2018;44:471–92.
  10. Mihaylova Z, Mitev V, Stanimirov P, Isaeva A, Gateva N, Ishkitiev N. Use of platelet concentrates in oral and maxillofacial surgery: an overview. *Acta Odontol Scand* 2017;75. 1-1.