



Case report

Castleman disease: Report of a case and review of literature on role of preoperative embolization

Meshal B. Albeshar^{*}, Saeed Alqahtani, Fareed R. Alghamdi

Department of Otorhinolaryngology Head and Neck Surgery, Prince Sultan Military Medical City, Riyadh, 12233, Saudi Arabia

ARTICLE INFO

Keywords:

Castleman
Lymphoproliferative
Unicentric
Embolization
Hyaline-vascular

ABSTRACT

Introduction: Castleman disease, which was first described by Dr. Castleman in 1954, is relatively rare and represents a spectrum of heterogeneous lymphoproliferative disorders with characteristic histological features on biopsy. It is classified based on body location and histology with variable clinical presentations. Its treatment depends on the subtype, and preoperative embolization for Castleman disease has rarely been discussed in the literature.

Presentation of case: A 22-year old man presented to the ENT clinic with a four-week history of a mass on the left side of the neck, which was associated initially with headache, fever, and fatigue for 2 days. Contrast tomography and magnetic resonance imaging revealed a hypervascular mass located at levels two and three of the left side of the neck with feeding vessels from the external carotid artery. Preoperative embolization was planned; however, the neurointerventionist considered it a lymph node that did not need embolization. Surgical excision was performed with relatively increased operative time and bleeding. A biopsy confirmed a hyaline-vascular type Castleman disease.

Discussion: We reviewed the evidence-based management of CD. We reviewed the available literature on the role of preoperative embolization in management.

Conclusion: Based on published articles and the hypervascular nature of the disease, we believe that preoperative embolization helps decrease morbidity.

1. Introduction and importance

Castleman disease (CD), giant lymph node hyperplasia, and angio-follicular lymph node hyperplasia are different terminologies for a disease entity that represents a spectrum of heterogeneous lymphoproliferative disorders, sharing common pathological features in biopsy [1]. It is a nonclonal lymphoproliferative disorder, which causes non-neoplastic lymphadenopathy [2]. CD has a broad spectrum of manifestations, associated diseases, and an intersection with neoplastic and autoimmune conditions. Therefore, CD has a wide differential diagnosis, which represents a diagnostic challenge for physicians [3]. CD is commonly classified based on the region of lymph node involvement and histological features. CD can be localized and unicentric, involving a single lymph node, or multicentric, involving a group of lymph nodes in different body locations [3]. Unicentric CD is rarely associated with systemic manifestations. By contrast, multicentric CD has systemic manifestations and constitutional symptoms, such as weight loss, fever, and generalized fatigue, and is associated with other

conditions [4]. Histologically, CD is classified as hyaline-vascular, plasma-cell, or mixed-type. Hyaline-vascular (HV) lesions are the most common, and approximately 90% of unicentric CD (UCD) lesions are eventually diagnosed as HV-UCD [2]. Clinically, it is confined to a single lymph node or a lymph node region in the body, with the mediastinum being the most common location. Other locations include the retroperitoneum, pelvis, neck, axilla, and rarely, extra-nodal locations [5]. Treating CD depends on the disease subtype. Generally, the gold standard treatment for UCD is surgery, with a high curative rate, while that for multicentric CD (MCD) is monoclonal immunotherapy [6,7]. Due to the high vascularity of CD, angioembolization plays a substantial role in its management. However, the role of preoperative embolization in CD remains insufficiently discussed in the literature. Thus, this study aimed to review its role in CD.

2. Case presentation

We report a case of CD in a previously healthy 22-year old male Saudi

^{*} Corresponding author.

E-mail address: meshalbassam@gmail.com (M.B. Albeshar).

<https://doi.org/10.1016/j.ijscr.2022.107222>

Received 23 April 2022; Received in revised form 14 May 2022; Accepted 15 May 2022

Available online 18 May 2022

2210-2612/© 2022 The Authors. Published by Elsevier Ltd on behalf of IJS Publishing Group Ltd. This is an open access article under the CC BY-NC-ND license (<http://creativecommons.org/licenses/by-nc-nd/4.0/>).

living in Pakistan, who presented to the clinic with a four-week history of a mass in the left side of the neck. The mass was initially associated with a brief history of headache, fever, and fatigue. The associated symptoms resolved within 2 days with persistence of the neck mass and a subjective decrease in the size of the mass. On examination, the patient had left-sided neck swelling expanding to levels two and three. The mass was firm in consistency, not tender, mobile, and not associated with skin changes or fluctuations. Other ENT, head and neck, cranial nerves, and flexible nasopharyngolaryngoscopy were all unremarkable. Contrast-enhanced computed tomography (CT) and magnetic resonance imaging (MRI) were performed on the patient, which demonstrated a hypervascular mass located at levels two and three of the left side of the neck lateral to the internal jugular vein (Fig. 1). The mass indicated increased density after contrast CT scan and hyperintensity with multiple flow voids on T2 MRI scans resembling a salt-and-pepper appearance (Figs. 2 and 3). MRI angiography revealed feeding vessels mainly from the branches of the external carotid artery (Fig. 4). The primary differential diagnosis was paraganglioma. The plan was to excise the mass with preoperative angioembolization. The patient was admitted 2 days preoperatively, and an interventional radiologist was consulted for preoperative embolization; however, he assumed that the mass did not require embolization. The patient underwent a transcervical approach with a left half-apron incision from the mastoid to the midline. The subplatysmal flaps were raised superiorly and inferiorly. The sternocleidomastoid muscle was skeletonized, and the mass was inspected as matted and attached to the surrounding structure and internal jugular vein. The mass was dissected from the surrounding structures, with observation of multiple feeding vessels. Multiple surgical clips and instrumental ligations were required during the procedure. The mass was completely excised and histopathologically evaluated. The mass measured 5 cm × 3 cm (Fig. 5). A Jackson–Pratt surgical drain was then inserted. The surgical wound was closed in layers. The estimated blood loss was approximately 300 ml, and the surgery time was 3 h. The patient had an uneventful postoperative course. The drain was removed on postoperative day 2. Patient was discharge home and instructed. At the outpatient follow-up, a clean surgical wound was observed without postoperative concerns. The histopathological results were consistent

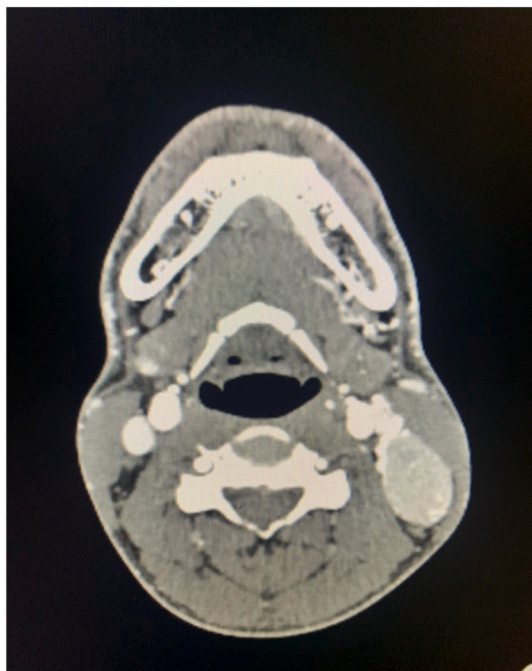


Fig. 1. Contrast-enhance axial CT scan demonstrates hyperdense enhancing mass.

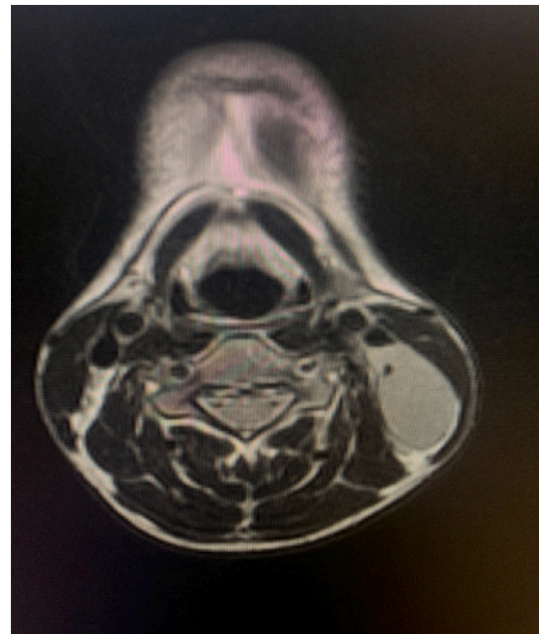


Fig. 2. T2 MRI demonstrates a hyper-intense mass with flow void.

with an HV variant of CD. The patient underwent chest, abdominal, and pelvic CT to exclude other systemic lesions that were unremarkable. The plan was to follow up the patient in 6 months for clinical evaluation. We believe that preoperative embolization would have helped decrease intraoperative blood loss and operative time.

3. Clinical discussion

Recent international guidelines on the diagnosis and management of UCD were published by the American Society of Hematology in 2020 [6]. Several factors, including the location of the disease, resectability of the lymph node, and presence of symptoms due to the mass effect on adjacent structures or systemic inflammatory symptoms, impact management options in UCD [6]. In resectable UCD, based on guidelines and level 2A evidence (no available high-quality randomized controlled trial), complete surgical excision is the standard of care [6]. After surgical excision of resectable tumors, the overall survival rate reached 91% over 5 years [4]. Recurrence of UCD after surgical excision is uncommon but has been previously reported [8]. According to the International Consensus Guidelines for UCD, recurrent UCD should be managed with surgery if feasible. For asymptomatic unresectable lesions, careful monitoring is necessary, and these cases were better managed by a multidisciplinary team. For symptomatic unresectable lesions, when symptoms are attributed to a mass effect on adjacent structures, debulking surgery may result in an asymptomatic state. Medical therapy includes rituximab with or without steroids [6]. After medical therapy, some tumors are amenable to surgery, and complete or partial excision may be considered [9]. Radiotherapy may be reserved for persistent symptomatic unresectable UCD [6].

The role of IL-6 in MCD has been implicated in this disease. The first-line treatment is monoclonal antibodies targeting IL-6, such as siltuximab and tocilizumab [7]. In cases of human herpes virus-8 positive MCD, rituximab with or without additional chemotherapy agents is generally adopted [1].

Preoperative embolization should be considered due to the vascular nature of the tumor [6]. Preoperative embolization in CD was first reported by Walter et al. in 1978 [10], where they reported two cases of mediastinal hypervascular masses with considerable intraoperative blood loss. One mass was resected without angioembolization with 4 units of blood loss. The other patient's surgery was aborted after biopsy

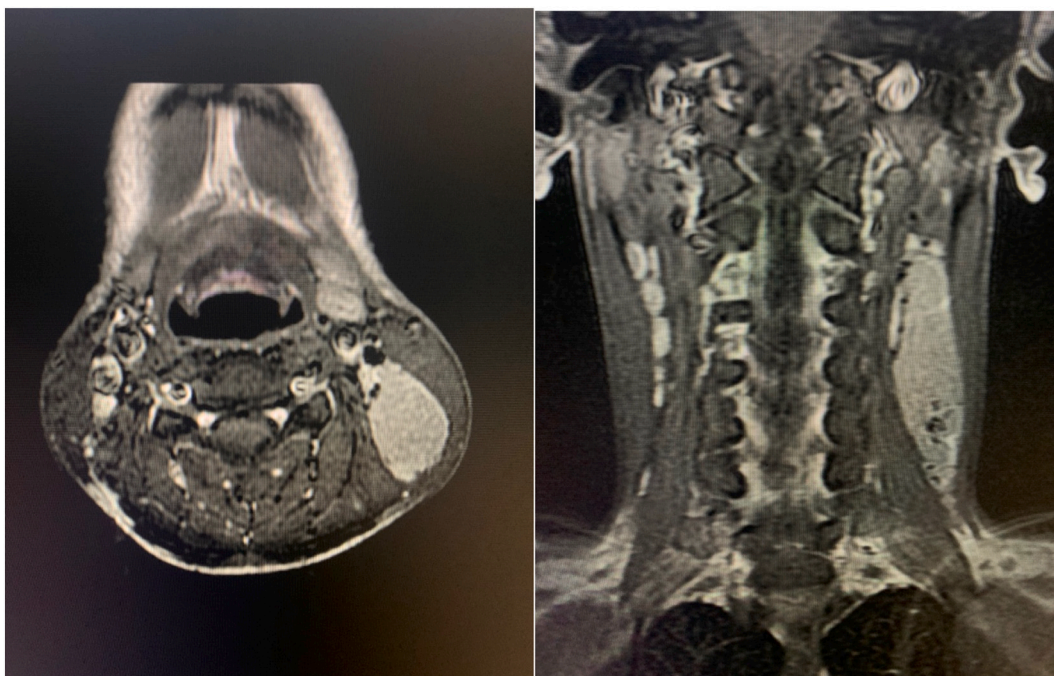


Fig. 3. T1 MRI after contrast injection demonstrates a hyper-intense mass with multiple flow voids resembling salt and pepper appearance.

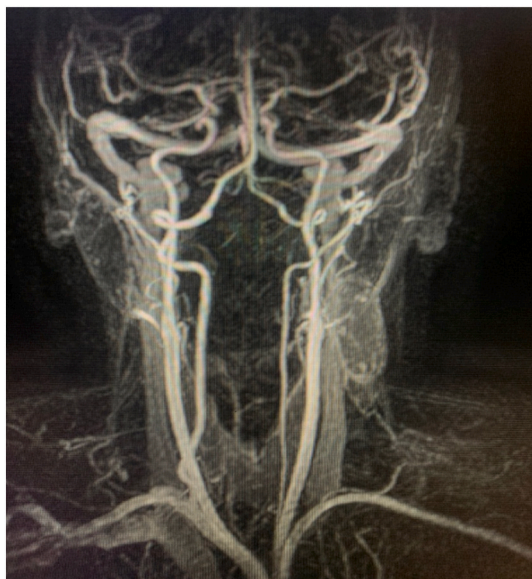

Fig. 4. MRI angiography revealed feeding vessels mainly from the branches of the external carotid artery.

due to intraoperative bleeding. The patient underwent surgery after a few days, preceded by angioembolization with an intraoperative report of controlled hemostasis. Shawn et al. observed controlled intraoperative hemostasis for mediastinal CD and supported the use of preoperative angioembolization [11]. In their case series of three patients with CD treated surgically, Newlon et al. suggested that embolization may be helpful prior to excision. They suggested that the disease is typically not diagnosed before excision, which makes the consideration of preoperative embolization debatable [12]. When considering angioembolization, Robert et al. recommended the use of micro-particles between 350 and 700 μm in diameter to prevent distal occlusion or to prevent passage of small particles, causing local tissue infarction or systemic embolism [13]. Regarding different embolizing

agents, Swee et al. have reported that triasacryl gelatin microsphere agents are superior to polyvinyl alcohol agents (PVA) because of their irregular shapes and the possibility of clumping of the latter [14]. Sanchez et al. have reported the use of PVA in cervical CD in embolizing feeding vessels of thyrocervical trunk branches for left cervical supra-clavicular CD, resulting to decreased intraoperative bleeding and uneventful post-operative care [15]. Literature on the role of embolization in CD is limited to case reports and observational impressions of decreased intraoperative bleeding. No retrospective cohort studies have compared the outcomes of preoperative angioembolization in CD. Outcomes in the reported cases, such as estimated blood loss, effect on tumor size, time interval between angioembolization and surgery, postoperative complications, and use of a surgical drain have been reported. Table 1 lists the literature review on the role of preoperative angioembolization in CD [16–21].

Available data on the role of angioembolization in CD as a stand-alone treatment are insufficient. However, the crucial role of embolization in symptomatic unresectable CD is rarely reported. Lorenz et al. described the use of angioembolization alone in symptomatic unresectable large mediastinal CD to control hemoptysis [22]. Immediate control of hemoptysis and relative shrinkage of the mass were observed, so patients with symptomatic unresectable or recurrent disease could be candidates for embolization. In 2018, Mohan et al. published a case series of six cases of unresectable symptomatic UCD [23]. A combination of medical, surgical, embolization, and cryoablation techniques has been widely used. Two patients received embolization twice in adjunct to failed chemotherapy, and one patient received embolization without a chemotherapy regimen but needed irradiation due to recurrence. Follow-up angiography demonstrated marked shrinkage of tumor size in all the six patients, except for one patient who underwent irradiation. Embolization in three patients rendered the tumor resectable, which was then surgically excised. Four patients needed another embolization with a 2–3-month interval.

4. Conclusion

CD has a clinical presentation similar to that of several differential diagnoses. Surgical excision is the mainstay of treatment for unicentric

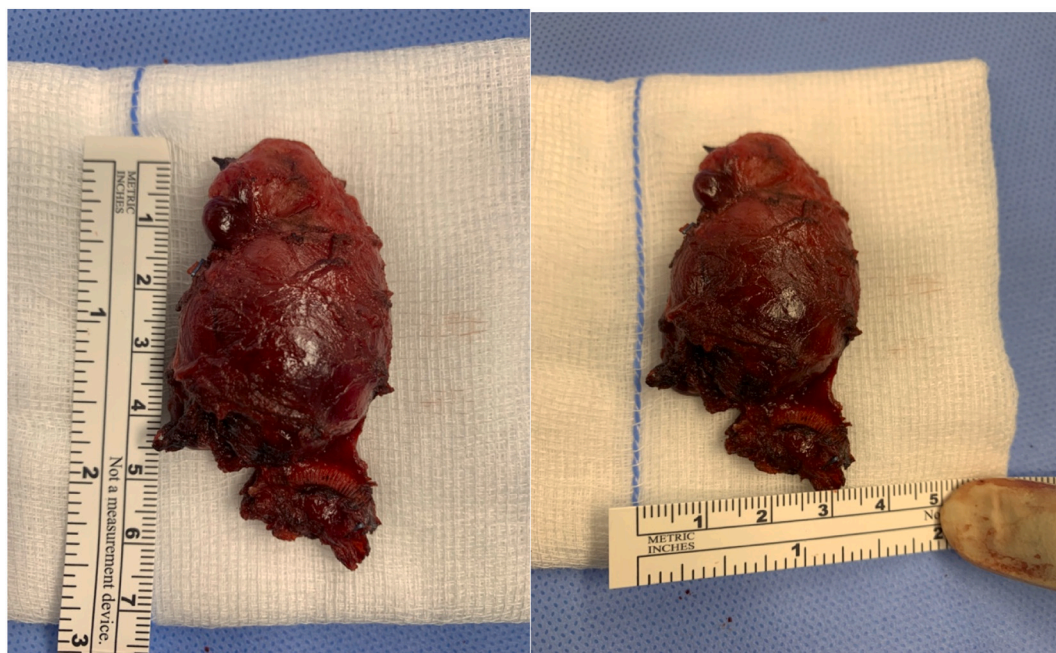

Fig. 5. Mass was excised completely and measured 5 cm × 3 cm.

Table 1

Literature review on the role of preoperative angioembolization in CD.

Case	Article	Disease location	Disease type	Material used for embolization	Estimated blood loss	Time interval between embolization and surgery
1	Walter et al. ¹	Mediastinum	CD, subtype not classified	Surgical gelfoam	Not specified	4 days
2	Safford et al. ²	Mediastinum	Hyaline-vascular UCD	Ivalon particles and 2 tracker coils	<50 ml	1 day
3	Newlon et al. ³	Supraclavicular	Hyaline-vascular UCD	Not specified	Not specified	Not specified
4	Robert et al., 2008	Mediastinum	Hyaline-vascular UCD	Gelatin cross-linked tris-acryl microspheres	<200 ml	7 days
5	Swée et al. ⁴	Mediastinum	Hyaline-vascular UCD	Microspheres	50 ml	Not specified
6	Sanchez et al., 2012	Cervical/supraclavicular	Hyaline-vascular CD	Polyvinyl alcohol particles and platinum-fibered coils	Not specified	1 day
7	Nagano et al. ⁵¹⁶	Retroperitoneal	Hyaline-vascular CD	Porous gelatin particles	940 ml	1 day
8	Gorsope et al., 2015 ¹⁷	Mediastinum	Hyaline-vascular CD	Microspheres	Minimal	Not specified
9	Guanyu Yu et al., 2019 ¹⁸	Mesorectum	Mixed type, mainly hyaline-vascular UCD	Digital subtraction angiography and injection of dexamethasone, epirubicin, and gelatin sponge	Not specified	7 days
10	Amano et al. ⁶¹⁹	Mediastinum	hyaline-vascular UCD	Gelatin sponge and microcoils	400 ml	1 day
11	Kitakaze et al. ⁷²⁰	Pelvic retroperitoneum	Hyaline-vascular UCD	DMSO	160 ml	1 day
12	Aydemir et al. ⁸²¹	Mediastinal	Hyaline-vascular UCD	Polyvinyl alcohol	Not specified	14 days

tumors. Pre-operative angio-embolization might have a crucial role in management of CD. Further high evidence research is needed

This work has been reported in line with the SCARE 2020 criteria [24].

Consent

Written informed consent was obtained from the patient for publication of this case report and accompanying images. A copy of the written consent is available for review by the Editor-in-Chief of this journal on request.

Provenance and peer review

Not commissioned, externally peer-reviewed.

Sources of funding

None.

Guarantor

Dr. Meshal Albeshier.

Ethical approval

None.

Registration of research studies

N/A.

CRediT authorship contribution statement

Dr. Meshal Albeshar: writing, literature review, review, corresponding and first author.

Dr. Fareed Alghamdi: writing, literature review, review.

Dr. Saeed Alqahtani: writing, literature review, review.

Declaration of competing interest

None.

Acknowledgment

None.

References

- [1] A. Carbone, M. Borok, B. Damania, A. Gloghini, M.N. Polizzotto, R.K. Jayanthan, et al., Castleman disease, *Nat. Rev. Dis. Primers* 7 (2021) 84.
- [2] D.M.P. Cronin, R.A. Warnke, Castleman disease: an update on classification and the spectrum of associated lesions, *Adv. Anat. Pathol.* 16 (2009) 236–246.
- [3] D. Bonekamp, K.M. Horton, R.H. Hruban, E.K. Fishman, Castleman disease: the great mimic, *RadioGraphics* 31 (2011) 1793–1807.
- [4] A. Dispenzieri, D.C. Fajgenbaum, Overview of Castleman disease, *Blood* 135 (2020) 1353–1364.
- [5] H.P. McAdams, M. Rosado-de-Christenson, N.F. Fishback, P.A. Templeton, Castleman disease of the thorax: radiologic features with clinical and histopathologic correlation, *Radiology* 209 (1998) 221–228.
- [6] F. van Rhee, E. Oksenhendler, G. Srkalovic, P. Voorhees, M. Lim, A. Dispenzieri, et al., International evidence-based consensus diagnostic and treatment guidelines for unicentric Castleman disease, *Blood Adv.* 4 (2020) 6039–6050.
- [7] D.C. Fajgenbaum, T.S. Uldrick, A. Bagg, D. Frank, D. Wu, G. Srkalovic, et al., International, evidence-based consensus diagnostic criteria for HHV-8-negative/idiopathic multicentric Castleman disease, *Blood* 129 (2017) 1646–1657.
- [8] S. Mitsos, A. Stamatopoulos, D. Patrini, R.S. George, D.R. Lawrence, N. Panagiotopoulos, The role of surgical resection in unicentric Castleman's disease: a systematic review, *Adv. Respir. Med.* 86 (2018) 36–43.
- [9] D. Boutboul, J. Fadlallah, S. Chawki, C. Fieschi, M. Malphettes, A. Dossier, et al., Antoine dossier, and Laurence, *Br. J. Haematol.* 186 (2019) 269–273.
- [10] J.F. Walter, R.W. Rottenberg, W.B. Cannon, L.A. Sheridan, J. Pizzimenti, J.T. Orr, Giant mediastinal lymph node hyperplasia (Castleman's disease): angiographic and clinical features, *AJR Am. J. Roentgenol.* 130 (1978) 447–450.
- [11] S.D. Safford, A.S. Lagoo, S.A. Mahaffey, Preoperative embolization as an adjunct to the operative management of mediastinal Castleman disease, *J. Pediatr. Surg.* 38 (2003) E21–E23.
- [12] J.L. Newlon, M. Couch, J. Brennan, Castleman's disease: three case reports and a review of the literature, *Ear Nose Throat J.* 86 (2007) 414–418. PMID: 17702325.
- [13] J.H. Robert, G. Sgourdos, N. Kritikos, D. Didier, S. Terraz, Preoperative embolization of hypervascular Castleman's disease of the mediastinum, *Cardiovasc. Intervent. Radiol.* 31 (2008) 186–188.
- [14] W. Swee, A.M. Housseini, J.F. Angle, D.R. Jones, T.M. Daniel, U.C. Turba, et al., Preoperative embolization of Castleman's disease using microspheres, *Ann. Thorac. Surg.* 88 (2009) 1999–2001.
- [15] A. Sanchez-Ros-Sanchez, P. Infante-Cossio, A. Gonzalez-Garcia, J.-J. Borrero-Martin, Preoperative embolization for the treatment of cervical Castleman disease, *J. Craniofac. Surg.* 23 (2012) e257–e259.
- [16] S. Nagano, M. Yokouchi, T. Yamamoto, H. Kaieda, T. Setoguchi, T. Hiraki, et al., Castleman's disease in the retroperitoneal space mimicking a paraspinal schwannoma: a case report, *World J. Surg. Oncol.* 11 (2013) 108.
- [17] L. Gorospe, A.P. Valdebenito-Montecino, G.M. Muñoz-Molina, Preoperative embolization of mediastinal Castleman's disease presenting with stroke, *Asian Cardiovasc. Thorac. Ann.* 25 (2017) 158–159.
- [18] G. Yu, Cao Fuao, H. Gong, P. Liu, G. Sun, W. Zhang, Embolization of blood-supply artery followed by surgery for treatment of mesorectal Castleman's disease: case report and literature review, *Gastroenterol. Rep. (Oxf.)* 7 (2019) 141–145.
- [19] Y. Amano, Takai Daiya, N. Ohishi, A. Shinozaki-Ushiku, M. Fukayama, M. Akahane, et al., Successful treatment of mediastinal unicentric Castleman's disease using video-assisted thoracoscopic surgery with preoperative embolization, *Case Rep. Med.* (2013), 354507, 2013.
- [20] M. Kitakaze, N. Miyoshi, S. Fujino, T. Ogino, H. Takahashi, M. Uemura, et al., Surgical resection for pelvic retroperitoneal Castleman's disease: a case report and review literature, *Biomed. Rep.* 14 (2021) 29.
- [21] B. Aydemir, T. Okay, O. Imamoglu, S. Sahin, I. Dogusoy, Preoperative embolization in mediastinal Castleman's disease, *Thorac. Cardiovasc. Surg.* 58 (2010) 496–498.
- [22] J.M. Lorenz, S.M. Zangan, J.A. Leef, Mediastinal Castleman disease: embolization without surgery, *J. Vasc. Interv. Radiol.* 20 (2009) 1393–1394.
- [23] M. Mohan, J.C. Meek, M.E. Meek, R.L. Broadwater, K. Stone, A. Greenway, et al., Treatment of unresectable unicentric Castleman disease with therapeutic embolization, *Blood* 132 (Supplement 1) (2018) 2415.
- [24] R.A. Agha, T. Franchi, C. Sohrabi, G. Mathew, for the SCARE Group, The SCARE 2020 guideline: updating consensus Surgical CASE REport (SCARE) guidelines, *Int. J. Surg.* 84 (2020) 226–230.