

Successful ablation of a concealed accessory pathway in the coronary sinus in a patient with mechanical mitral valve



Lisa Albertini, MD, Andrew Ha, MD, Krishnakumar Nair, MD

From the Toronto General Hospital, University Health Network Toronto, Toronto, Canada.

Introduction

Patients treated with cardiac surgery often present with supraventricular arrhythmias, classically atrial fibrillation and atrial flutter. Accessory pathways (APs) are a rare finding in these patients, except for congenital heart disease (eg, Ebstein anomaly). Only a few case reports of AP ablation at the site of previous valve surgery have been published.¹ Ablation in this setting is challenging and carries the risk of injuring the prosthetic valve. We report a successful ablation of a concealed left-side AP in the coronary sinus (CS) in a patient with previous mechanical mitral valve replacement for rheumatic valve disease.

Case report

A 47-year-old woman was referred to our hospital for management of recurrent supraventricular tachycardia. She had a history of rheumatic valve disease and she had undergone mitral valve replacement with a mechanical prosthesis for severe mitral regurgitation at the age of 36 years. Her recurrent palpitations were initially managed with amiodarone and beta blockers, although without complete tachycardia suppression.

Her baseline electrocardiogram (ECG) showed sinus rhythm, nonspecific ST-T abnormalities, QT prolongation, and no evidence of preexcitation (Figure 1A). During palpitations, the 12-lead ECG demonstrated a regular narrow QRS tachycardia at a rate of 130 beats per minute (Figure 1B).

An electrophysiological study was performed under conscious sedation using a 3-dimensional mapping system (CARTO system; Biosense Webster, Diamond Bar, CA). The electrophysiological study was performed on

KEY TEACHING POINTS

- Patients treated with cardiac valve surgery often present with supraventricular arrhythmias, but atrioventricular reciprocating tachycardia is uncommon, except in the congenital population.
- Accessory pathway mapping and ablation close to a mechanical valve is challenging and carries the risk of damage and thrombosis of the prosthesis.
- Left-side accessory pathways in patients with previous mechanical mitral valve replacement may be mapped and ablated in the coronary sinus. A transseptal/transaortic approach may be pursued only in case of failure.

uninterrupted anticoagulation and the international normalized ratio was 2.5 on the day of the procedure. A decapolar catheter was placed in the CS, a quadripolar catheter in the right ventricular apex, and a 4 mm nonirrigated ablation catheter in the His bundle region. Incremental ventricular pacing showed a retrograde eccentric pattern of atrial activation in the CS, earliest at the level of CS electrodes 5–6. Retrograde AP refractory period was obtained at 600/370 ms. Incremental atrial pacing did not show ventricular preexcitation. Programmed atrial pacing induced narrow QRS tachycardia with a ventricular-atrial (VA) time of 90 ms. VA linking was noticed after atrial overdrive pacing during tachycardia, ruling out atrial tachycardia. Ventricular overdrive pacing (Figure 2) elicited a VAV response with a postpacing interval minus tachycardia cycle length (PPI–TCL) of 60 ms. The stimulus-atrial minus ventriculoatrial interval difference was 60 ms. A premature ventricular contraction, delivered from the right ventricular apex 50 ms before the His depolarization, advanced the subsequent atrial deflection by 50 ms. A diagnosis of orthodromic atrioventricular (AV) reentrant tachycardia through a concealed left-sided AP was made.

Mapping the mitral annulus using either the transseptal approach or the retrograde approach would have been

KEYWORDS Mechanical mitral valve; Accessory pathway; Radiofrequency catheter ablation; Orthodromic atrioventricular reciprocating tachycardia; Coronary sinus
(Heart Rhythm Case Reports 2022;8:558–561)

Funding Sources: This research did not receive any specific grants from funding agencies in the public, commercial, or not-for-profit sectors. **Disclosures:** None. **Address reprint requests and correspondence:** Dr Krishnakumar Nair, Peter Munk Cardiac Centre, Toronto General Hospital, University of Toronto, 200 Elizabeth St, Toronto, M5G 2C4, Canada. E-mail address: Krishnakumar.Nair@uhn.ca.

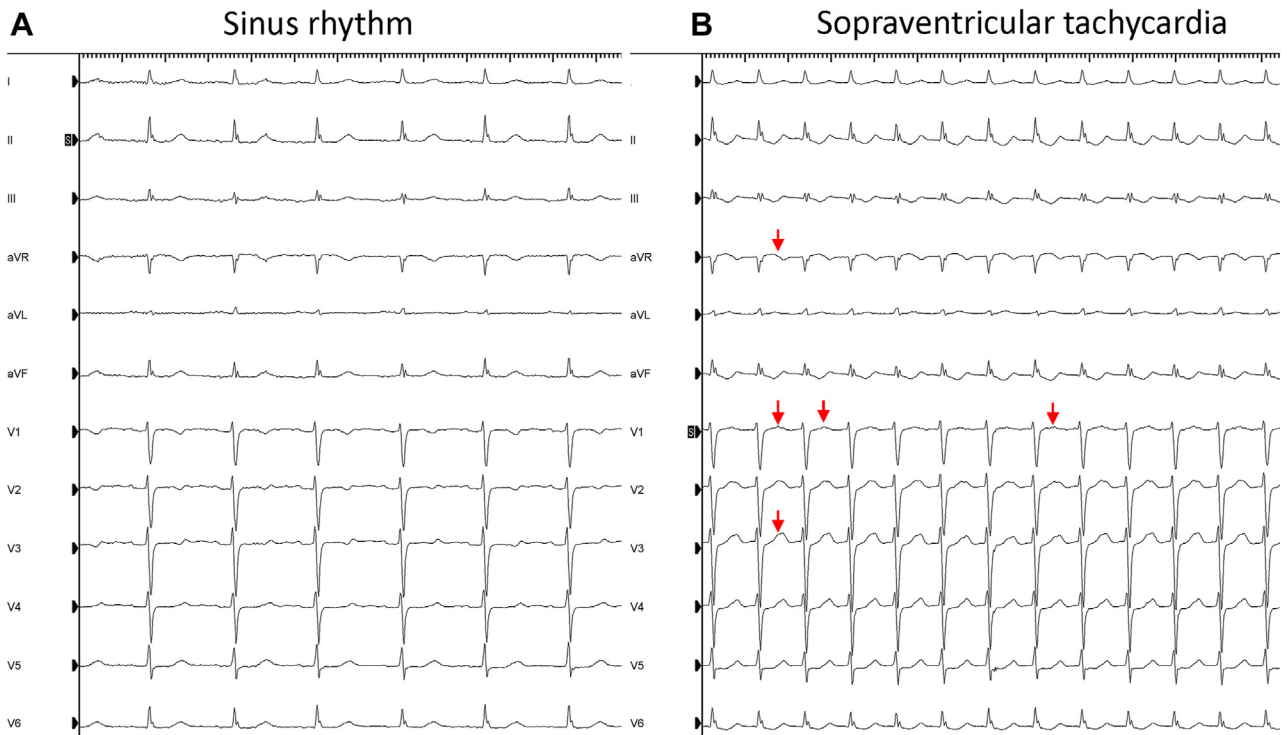


Figure 1 A 12-lead electrocardiogram during sinus rhythm and supraventricular tachycardia. **A:** Sinus rhythm with normal QRS axis and no evidence of pre-excitation. **B:** In the electrophysiology lab, a regular tachycardia (130 beats/min) was observed with the same QRS morphology as sinus. Retrograde P waves were noticed during tachycardia (red arrowheads).

extremely challenging owing to difficulties in obtaining true annular signals and the risk of catheter entrapment or interference with the mechanical valve. We therefore decided to map

the CS with a PentaRay catheter (Biosense Webster, Diamond Bar, CA) (Figure 3B). During tachycardia, the earliest atrial signal with VA fusion was observed

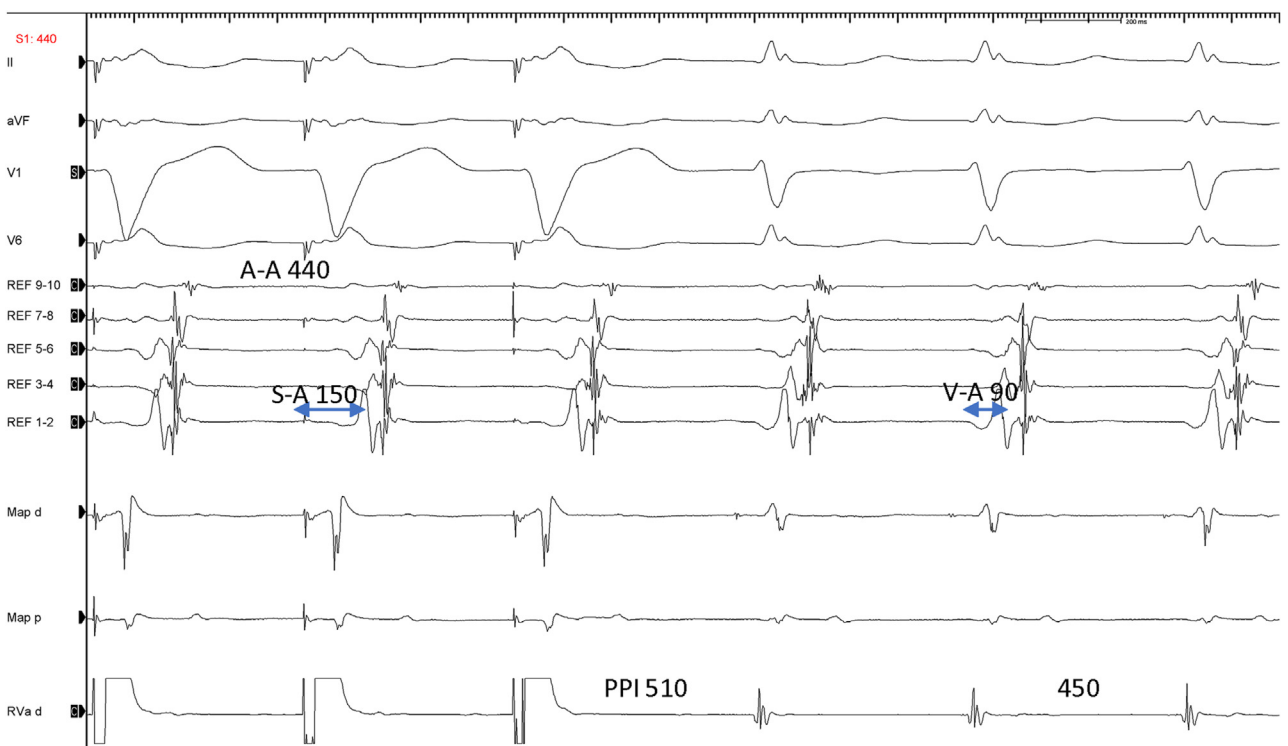


Figure 2 V-A-V response and a postpacing interval (PPI) minus tachycardia cycle length of 60 ms after overdrive ventricular pacing during tachycardia. All findings were diagnostic of orthodromic atrioventricular reentrant tachycardia.

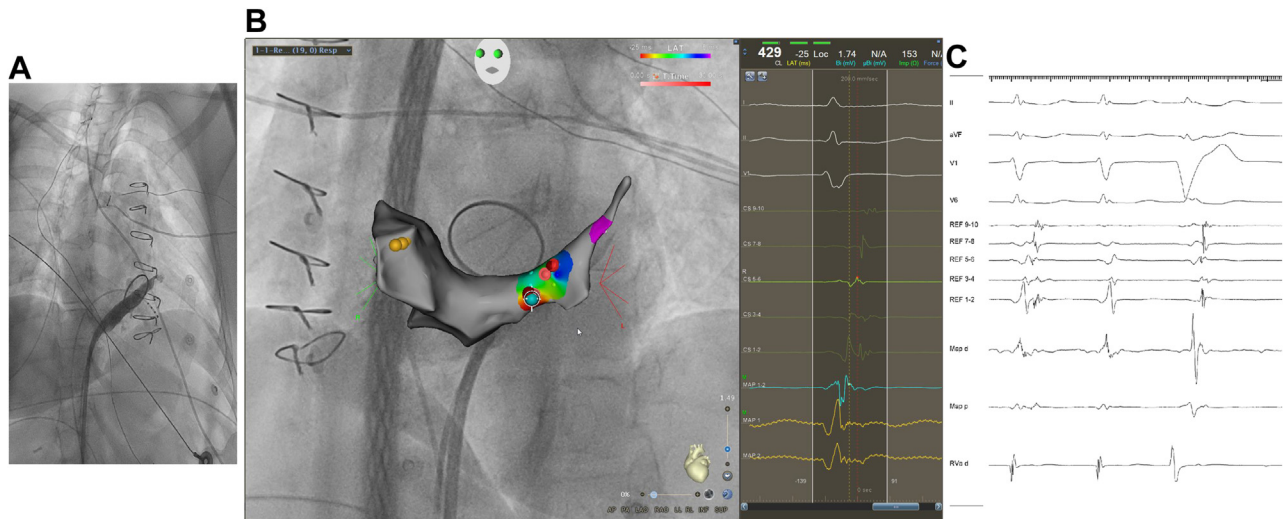


Figure 3 A: Coronary sinus (CS) venogram in right anterior oblique projection. No CS diverticulum was observed. B: Atrial activation mapping during tachycardia. Right panel shows the earliest activation potential mapped by ablation catheter. Yellow dots represent His bundle location. C: Tachycardia termination after 4 seconds of ablation; however, the pathway is still retrogradely conducting.

close to CS electrodes 5–6. A CS venogram was performed and no CS diverticulum was seen (Figure 3A). We decided to start ablating using a nonirrigated catheter, carefully monitoring the ECG for ST-T changes. Ablation at the site of earliest atrial electrogram with a power of 20 watts and a temperature limit of 60°C terminated the tachycardia after 4 seconds; however a premature ventricular contraction showed the pathway was still conducting retrogradely (Figure 3C). No ST-T changes on the ECG and no impedance rise were observed during ablation, so 40 additional seconds of ablation were performed at the same location. Subsequently, VA block was observed during ventricular incremental pacing and tachycardia was no more inducible with programmed and incremental atrial pacing. The tachycardia did not reoccur during a 10-month follow-up period after catheter ablation.

Discussion

The prevalence of manifest APs in the general population is estimated to be at 0.25%, and around 20% of the APs, depending on the clinical series, demonstrate retrograde-only conduction.² So, except for congenital heart disease patients, the odds of finding a concealed AP in a patient who underwent valve surgery are low. During surgery, direct trauma secondary to stitching and debridement, tissue remodeling, and ischemia have been identified in pathologic studies as the mechanism of postoperative AV nodal conduction block.³ During mitral valve surgery, the same factors might impair conduction through an AV AP anatomically close to the endocardial side of the mitral annulus.⁴ Despite this, we report a case of a concealed left-side AP in a 47-year-old woman with previous mechanical valve replacement. Only anecdotal cases of successful AP ablation at the site of previous valve surgery have been reported.¹ Epicardial AV pathways or valve

deployment on the atrial aspect of the annulus, rather than on the true annulus, might explain intact AP conduction after valve surgery. Interestingly, surgical creation of AV connections has been reported after cardiac surgeries in congenital heart disease patients^{5–7} and might be conceivable after rheumatic valve surgery. In patients with a mitral mechanical valve, few isolated cases of endocardial ablation of an AP have been reported, making this approach potentially feasible.¹ Nonetheless, a transprosthetic approach carries life-threatening risks of catheter entrapment, thrombosis, and prosthesis damage.^{8–11} Adverse events have been reported mainly in patients with caged-ball or tilting-disc valves^{9,11}; however complications of crossing a bileaflet mechanical valve might be unreported, and therefore this approach is not recommended. Mapping above or below the prosthesis with a transeptal or transaortic approach may be an option, especially if the prosthesis is located slightly toward the atrial side. However, it is difficult to determine the exact position of the mechanical valve based on imaging alone, and so planning the right approach is extremely challenging. In a case series of left-side AP ablation in patients with mechanical mitral valve, a transaortic approach was successful in 2 cases and CS ablation and bipolar ablation obtained AP suppression in another 2 patients. Aslani and colleagues¹² reported catheter ablation of an AP within the Marshall vein in a patient with mechanical mitral valve after a failed transeptal approach. In patients with mechanical mitral valve the chances of an AP lying deep in the atrioventricular groove might be higher than the general population. This factor, together with the risks related to catheter manipulation through or close to the mechanical prosthesis, might justify mapping the CS as the first step. In the early seventies, mapping and ablation in the CS was proposed as a first-line approach for left-side pathways, aiming to avoid all the risks related to the arterial access, transaortic, and transeptal approach.¹³ Nonetheless, ablating

in the CS carries risks as well, including coronary arterial injury¹⁴ that could manifest as acute myocardial ischemia or chronic coronary stenosis.¹⁵ Appropriate precautions must be adopted to perform a successful and reasonably safe ablation in the CS.¹⁶ An irrigated ablation catheter is likely to have superior efficacy and less likelihood of char and thrombus formation, particularly in a low-flow structure as the CS. We were successful in this case with ablation with a nonirrigated catheter and did not need to switch to an irrigated ablation catheter. Ablations should be started at low power (10–15 W) and the power increased gradually to 25 W, until conduction block occurs across the AP.¹⁶ Careful monitoring of impedance and prompt termination of ablation in case of impedance rise ($\geq 5 \Omega$) or ST-T changes is warranted. Ideally a preablation coronary angiogram should be performed, and ablation aborted in case of proximity (less than 5 mm) to the coronary arteries.¹⁷

In conclusion, this case emphasizes successful ablation of a concealed left-side AP in the CS in a patient with previous mitral valve replacement with a mechanical prosthesis. Mapping in the CS and ablation in case of satisfactory signals may represent a first-line strategy in these patients. A transseptal/transaortic route may be pursued only in case of failure.

Acknowledgments

We would like to thank Omar Ayaz for editing the figures of this manuscript.

References

- Uhm JS, Kim J, Jin MN, et al. Radiofrequency catheter ablation of accessory pathways at the site of prior valve surgery. *J Arrhythm* 2019;35:645–653.
- Chispin J, Calkins H. Accessory pathways-related tachycardias: Wolff–Parkinson–White syndrome and atrioventricular reentrant tachycardias. In: *ESC CardioMed*. Oxford University Press; 2018. p. 1–24.
- Lev M, Fell EH, Arcilla R, Weinberg MH. Surgical injury to the conduction system in ventricular septal defect. *Am J Cardiol* 1964;14:464–476.
- Ito R, Kajiyama T, Kondo Y, Nakano M, Kobayashi Y. Simultaneous conduction disturbance of an atrioventricular accessory pathway and nodal pathway after a mitral valve replacement: a case report. *HeartRhythm Case Rep* 2020;6:827–830.
- Peinado R, Gnoatto M, Merino JL, Oliver JM. Catheter ablation of multiple, surgically created, atrioventricular connections following Fontan-Björk procedure. *Europace* 2007;9:848–850.
- Hager A, Zrenner B, Brodherr-Heberlein S, Steinbauer-Rosenthal I, Schrieck J, Hess J. Congenital and surgically acquired Wolff-Parkinson-White syndrome in patients with tricuspid atresia. *J Thorac Cardiovasc Surg* 2005;130:48–53.
- Razzouk AJ, Gow R, Finley J, Murphy D, Williams WG. Surgically created Wolff-Parkinson-White syndrome after Fontan operation. *Ann Thorac Surg* 1992;54:974–977.
- Mehta D, Love B. Successful transcatheter removal of entrapped ablation catheter in mitral valve prosthesis. *Heart Rhythm* 2007;4:956–958.
- Bridgewater BJ, Levy RD, Hooper TL. Mitral valve prosthesis disk embolization during transeptal atrioventricular junction ablation. *J Interv Cardiol* 1994;7:535–537.
- Horstkotte D, Jehle J, Loogen F. Death due to transprosthetic catheterization of a Björk-Shiley prosthesis in the aortic position. *Am J Cardiol* 1986;58:566–567.
- Kober G, Hilgermann R. Catheter entrapment in a Björk-Shiley prosthesis in aortic position. *Cathet Cardiovasc Diagn* 1987;13:262–265.
- Aslani A, Moradi M, Kheirkhah J, Haghjoo M. Catheter ablation of an accessory pathway within the Marshall vein in a patient with mechanical mitral valve. *Pacing Clin Electrophysiol* 2013;36:e132–e135.
- Giorgberidze I, Saksena S, Krol RB, Mathew P. Efficacy and safety of radiofrequency catheter ablation of left-sided accessory pathways through the coronary sinus. *Am J Cardiol* 1995;76:359–365.
- Garabelli PJ, Stavrakis S, Po SS. A case series and review of the literature regarding coronary artery complications associated with coronary sinus catheter ablation. *HeartRhythm Case Rep* 2015;1:315–319.
- Paul T, Bökenkamp R, Mahnert B, Trappe HJ. Coronary artery involvement early and late after radiofrequency current application in young pigs. *Am Heart J* 1997;133:436–440.
- Stavrakis S, Jackman WM, Nakagawa H, et al. Risk of coronary artery injury with radiofrequency ablation and cryoablation of epicardial posteroseptal accessory pathways within the coronary venous system. *Circ Arrhythm Electrophysiol* 2014;7:113–119.
- Mao J, Moriarty JM, Mandapati R, Boyle NG, Shivkumar K, Vaseghi M. Catheter ablation of accessory pathways near the coronary sinus: value of defining coronary arterial anatomy. *Heart Rhythm* 2015;12:508–514.